19th WCBIP / WCBE World Congress

JOINT MEETING OF THE WORLD ASSOCIATION FOR BRONCHOLOGY AND INTERVENTIONAL PULMONOLOGY & THE INTERNATIONAL BRONCHOESOPHAGOLOGICAL SOCIETY

May 8-11, 2016

Florence (Italy)

ABSTRACT Book

Venue
Fortezza da Basso
Viale Filippo Strozzi 1
Florence, Italy

Endorsed by ERS EUROPEAN RESPIRATORY SOCIETY · EABIP · CHEST AMERICAN COLLEGE of CHEST PHYSICIANS · AIPO ASSOCIAZIONE ITALIANA PNEUMOLOGI OSPEDALIERI

Organizing Secretariat

AIPO RICERCHE | Via Antonio da Recanate, 2 | 20124 MILANO | Phone +39 02 36590364 | Fax +39 02 67382337 | info@wcbipwcbe2016.org | www.aiporicerche.it

ABSTRACT BOOK

AIPO RICERCHE
via A.Da Recanate, 2
20124 Milano
edizioni@aiporicerche.it
www.aiporicerche.it

Abstract Submission System and Abstract Book design
Powered by:

sintex

SINTEX SERVIZI S.R.L.
Via Antonio da Recanate, 2
20124 Milano
Phone +39 02 66703640
www.sintexservizi.it

Stefano GASPARINI
President of 19th WCBIP
Polytechnic University of Marche Region
Pulmonary Diseases Unit,
Azienda Ospedaliero-Universitaria "Ospedali Riuniti", Ancona, Italy

Dear Collegues, Dear Friends,

6 years have been passed since, in 2010, Florence was designated by the WABIP Board of Regents to host the 19th World Congress of the World Association for Bronchology and Interventional Pulmonologists. It seems only yesterday, as time flyies, but now we are all together in Florence and the Congress is ready to start.
It is a huge pleasure and a great honor for me to welcome all the participants coming from more than 50 different Countries, as a demonstration that Interventional Pulmonology arouses more and more interest among Pulmonologists and that WABIP is continuously growing. Thanks to the recent development of technical innovations and new procedures, interventional techniques have broadened their indications and today they play a major role in the diagnostic and therapeutical management of most thoracic diseases.
When we proposed Italy as the location for the 19th WCBIP, we suggested "Interventional Pulmonology in the multidisciplinary patient care setting" as the main theme of the Congress, with the aim of developing the integration of our procedures in patient care pathways, providing the best possible management for patients suffering from lung, airway and pleural diseases. Interventional Pulmonology should no longer be thought of as a speciality for few experts, but must be considered as one of the main pillars of Pulmonary Medicine. I sincerely hope that this goal has been reached by the programme of the Congress, that has been developed thanks to the great and enthusiastic support of all the Members of the Scientific Committee.
All the participants could enrich their experience choosing among more than 60 different Symposia, key note lectures, lessons from mentors and workshops, covering all the fields of Interventional Pulmonology. Furthermore, approximately 400 abstracts have been accepted and will be presented as oral communication or posters, providing an exciting chance to meet Collegues and to discuss the many topics of our fascinating speciality.
I would also like to thank the Italian Association of Hospital Pulmonologists (AIPO) and its Organizing Secretariat (AIPO Ricerche) for all the great support that they provided for the organization of the Congress and for making this event unforgettable.
I thank all the participants and I hope that everybody will enjoy these days in Florence, not only from the scientific point of view, but also appreciating the italian food, music, and culture in one of the art capitals of the world.

Welcome to Florence and enjoy the Congress!

Stefano Gasparini
President of the 19th WCBIP

Massimo TORRE
President of 19th WCBE
Thoracic Surgery Department
ASST Grande Ospedale Metropolitano Niguarda, Milan, Italy

Dear Friends, Colleagues and especially all IBES Member,

it is truly a delight to welcome you in Florence for the prestigious 19th WCBIP/WCBE. This congress is continuing in the tradition of the extremely successful 2014 congress held in Kyoto by Prof Koichi Tomoda and by previous congresses held by many other of our illustrious predecessors in the specialty of bronchoesophagology. Our aim has been to organize an open-minded scientific and educational conference with the intent to enlarge the borders of our society as much as possible. The attendance of top level faculty in the world of thoracic and airway surgery, pulmonologists, intensivists, gastroenterologists and such a large international audience coming from 50 different countries, emphatically demonstrates that this goal is becoming ever more close with each congress.

The scientific committee has planned a truly fascinating and intriguing programme, ranging across the spectrum of laryngotracheal diseases, thoracic surgery, lung transplantation, upper oesophageal disorders and many other pathological conditions.

Florence, the driving force of the Renaissance, with its rich historical, artistic and cultural heritage is the perfect location to host this extremely important international and multidisciplinary congress. The Fortezza da Basso, the site of our meeting, is a masterpiece of Renaissance military architecture, built in the mid-1500s at the time of the birth of the poet Dante Alighieri. By the end of this congress, I hope that all participants will feel that they have accessed the most up-to-date information available in their own particular field of bronchoesophagology.

I would also like to thank Prof. Stefano Gasparini for his help, the Organizing Secretariat AIPO Ricerche and all its staff for their great support in making this event a success. I am sure the 19th WCBIP/WCBE will be a profound experience for us all, in one of the most beautiful cities in the world.

I am honoured to be able to personally extend to all of you my best welcome to Florence and look forward to the further flourishing of the IBES.

Massimo Torre
President of the 19th WCBE

19th WCBIP / WCBE World Congress
JOINT MEETING OF THE WORLD ASSOCIATION FOR BRONCHOLOGY AND INTERVENTIONAL PULMONOLOGY & THE INTERNATIONAL BRONCHOESOPHAGOLOGICAL SOCIETY
www.wcbipwcbe2016.org
Fortezza da Basso
May 8-11, 2016
Florence (Italy)

Rare foreign body of left main bronchus

Alexey Korotkevich

Endoscopy, Advanced Medical School for Doctors - Russian Federation

Introduction

Long-existing foreign bodies of the tracheobronchial tree are particular problem as from the position of adequate diagnosis, and from the standpoint of treatment.

Methods

Case report. Man, 60 years old, hospitalized in May with typical clinic of left side pneumonia. From history we know that more than 6 months ago, drinking alcohol in large quantities on a fishing trip. Since that time disturbed periodic cough, shortness of breath transient, medical care is not addressed. Treated independently. About a week ago there was hyperthermia, nonproductive cough, shortness of breath, weakness. On the radiograph in a straight line (A) and lateral (B) projection revealed inflammatory infiltration and metallic foreign body (B). When fiber optic bronchoscopy revealed a wooden foreign body with metallic thread (C), occlusive left main bronchus at the mouth of the total upper lobe bronchus. During rigid bronchoscopy (operating tube of Karl Storz bronchoscope) foreign body removed by forceps, in the place of foreign body fixing were the proliferation of granulation, profuse purulent discharge, signs of atelectasis. A series of treatment bronchoscopy and conservative treatment of pneumonia - achieved recovery. Granulation were regressed, part of them were coagulated by contact application of silver nitrate solution 10%. Bronchial stenosis have arisen.

Conclusions

An elderly patient's age, weakened cough reflex, the tendency to use alcohol and low compliance have led to late diagnosis of a foreign body. Radiographic diagnosis was effective only for the presence of metal. However, therapeutic bronchoscopy in adjuvant therapy showed high diagnostic and therapeutic effectiveness of endoscopy.

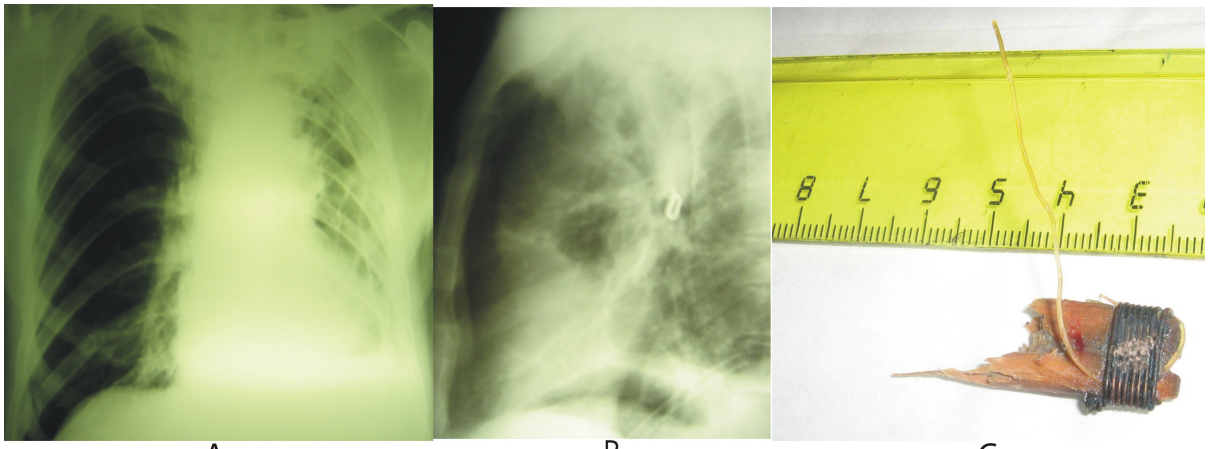

A B C

id 1

Predicting the risk of complications of bronchoscopy at patients in intensive care unit

Alexey Korotkevich[1], Gennady Komarov[2]

[1]Endoscopy, Advanced Medical School for Doctors - Russian Federation
[2]Endoscopy, City Hospital Nr.1 - Russian Federation

Introduction

The true incidence of complications of bronchoscopy, especially in patients during intensive care, remains largely unexplored.

Objective

Study the reaction of systemic hemodynamics on bronchoscopy as a predictor of the risk of complications of endoscopy.

Methods

Prospective trial of 2008 - 2013 years. Hemodynamic parameters were studied in 111 surgical patients in critical conditions under mechanical ventilation. 182 fiber optic bronchoscopy were made. The main reasons of intensive care include emergency complications of pancreatic necrosis (30), severe concomitant injury (26), severe burn injury (15), insult hematoma (40). Men was 84, there were 27 women. The average age (M ± m) was from 58,6 ± 1,8 years in group I to 40,1 ± 3,2 years in Group IV. Arterial and venous hemodynamic were studied by invasive measurement of cardiac output monitor PiCCO (PULSION, Germany).

Results

The overall incidence of complications of fiber optic bronchoscopy in surgical patients in critical conditions significantly exceed the published data, ranging from 3.3% to 14.8%. Structure and frequency of complications of bronchoscopy differ from the underlying disease and included acute hypoxia on the background of oxygenation, uncontrolled hypotension, decreased cardiac index, the development of purulent endobronchitis, clinical death. The use of fiber optic bronchoscopy in surgical patients in most cases contributed to the progress of respiratory failure - in necrotizing pancreatitis and abdominal sepsis in 93.5%; in operated patients with acute insult hematoma in 75%; at severe concomitant injury of 100% and at severe burn injury with termo inhalation damage in 53.3%. Decrease in cardiac index less than 3.7 L / min / m2 in combination with a low index of total peripheral vascular resistance is always combined with the development of complications during bronchoscopy. However, the communication index changes in total peripheral vascular resistance, with the development of complications during bronchoscopy, is not revealed.

Conclusions

Determination of cardiac index is a sensitive predictor of complications of bronchoscopy. It should be used to justify the rejection of invasive rehabilitation and / or revision of the tracheobronchial tree in critically ill patients.

Bibliography

1. Estella A. Med Intensiva. 2012 Aug-Sep;36(6):396-401. 2. Prebil SE, Andrews J, Cribbs SK, Martin GS, Esper A. J Crit Care. 2014 Dec;29(6):961-4.

Comparison of GeneXpert MTB/RIF assay in Broncho Alveolar Lavage and Gastric Lavage samples

Ashok Kumar[1], Ravi Mahat[2], Nadeem Rizvi[2]

[1]Chest, Jinnah Postgraduate Medical Centre - Pakistan
[2]Chest Medicine, Jinnah Postgraduate Medical Centre - Pakistan

Introduction

About 50% of suspected tuberculosis patients present with dry cough . In these situations either bronchoscopy with BAL, Induced sputum or GL are performed to make diagnosis.Bronchoscopy and BAL requires special facilities, trained staffs and is not accessible in many regions because of the limited resources. Additionally, due to its invasive nature many patients may not prefer and tolerate this.(1) Although yield of induced sputum has favorable results but its use requires isolation rooms with negative pressure which may not be available in many health care facilities.(1, 2) The GL method is preferred in diagnosis of TB in children who swallow their sputum and cannot expectorate. Many studies has shown good result of GL for AFB smear and culture.(1, 2) In the centers where who has provided GeneXpert machine, it can be very helpful to make bacteriological diagnosis within 2 hours.

Objective

To compare the yield from gastric lavage (GL) and Broncho alveolar lavage (BAL) samples in adult patient suspected case of TB but not producing sputum.

Methods

Total 80 consecutive adults with suspected case of tuberculosis who were not producing sputum were recruited. 72 patients prospectively subjected to one gastric lavage and followed by Broncho-alveolar lavage on the same morning. The collected samples were subjected to GeneXpert MTB/RIF Assay.

Results

Sample of 72 patients were collected. Mean age was 38.6±18.3. 41(56.9%) were male and 31(43.1%) were female. History of TB contact was present in 34.8%. Total 37 (51.4%) patients had GeneXpert MTB/RIF positive on BAL and/or GL samples. The GeneXpert MTB/RIF of BAL fluid was positive on 35(48.6%), which was not significantly greater than that for specimens from GL i.e. 28 (38.9%) ($p > 0.05$). In 26 (36.1%) cases GeneXpert MTB/RIF was positive both in both BAL and GA samples.

Conclusions

This study showed that the yield of GeneXpert MTB/RIF in GL was equally effective to BAL to detect Mycobacterium Tuberculosis complex. Patients who can’t produce sputum, GL can be a good alternative to BAL to detect Mycobacterium Tuberculosis complex in resource poor areas and patient who doesn’t tolerate Bronchoscopy.

Bibliography

1.Brown M: an official publication of the Infectious Diseases Society of America. 2007;44(11):1415-1420. 2.Larson JL Am J Respir Crit Care Med. 2001;163(5):1279-1280.

By the reasonableness of the time of interventional bronchoscopy at postintubation tracheal stenosis

Anton Leontev[1], Alexey Korotkevich[2], Paul Aksenov[3], Elena Zakharchenko[1], Natalia Chechulina[4], Michael Merzljakov[5], Vitaly Koljadov[6]

[1]Endoscopy, Municipal City Hospital Nr.29 - Russian Federation
[2]Endoscopic surgery, Postgraduate Training Physician Institute - Russian Federation
[3]Pathological anatomy, Municipal City Hospital Nr.29 - Russian Federation
[4]Pathological anatomy, Bureau of Medicolegal Examination - Russian Federation
[5]Endoscopy, Regional clinical hospital Nr.1 - Russian Federation
[6]Pathological anatomy, Regional Pathoanatomical Bureau - Russian Federation

Introduction

Morphological investigations of tracheal stenoses, problems in choice of treat-ment‘s method and results of surgical treatment force to search for a way of differential diagnostics of kind of tracheal stenoses for ground of adequate treat-ment method.

Objective

Justify the timing and extent of interventional bronchoscopy in the treatment of postintubation stenosis.

Methods

Serial morphological investigations of resected tracheal segments at 22 patients. Before the surgery, performed bronchoscopy. At endoscopy evaluated the degree of inflammation, the degree of stenosis, the possibility of dilatation and stenting.

Results

In 5 patients was mixed stenosis in up to 30 days after extubation. In 17 patients there was a scar stenosis in terms of more than 30 days after extuba- tion/decanulation. All patients underwent preoperative bougienage of stenosis. At operated patients frequency of morphological changes essentially no differed in terms till 30 day and over 30 day from the moment of extubation/decanulation (ANOVA Chi Sqr. (N = 14, df = 1) = 0,000000 p <1,00000; Coeff. of Concor-dance = 0,0000 Aver. rank r = -,0769). 1 patient with mixed stenosis (20%) had restenosis. In 1 case at cicatricial stenosis (6%) had restenosis (Chi-square (df=1) =1,03; p= 0, 3106).

Conclusions

Frequency and type of microscopic changes of a trachea in terms of month and more from the end of tracheal intubation have no significant differences. Optimum conditions for endoscopic intervention are early terms after an intubation.

id 5

Local impedance in the evaluation and prognosis of postintubation tracheal stenoses

Anton Leontev[1], Alexey Korotkevich[2], Elena Zakharchenko[1]

[1]Endoscopy, Municipal City Hospital Nr.29 - Russian Federation
[2]Endoscopic surgery, Postgraduate Training Physician Institute - Russian Federation

Introduction

Morphological investigations of tracheal stenoses, problems in choice of treatment‘s method and results of surgical treatment at tracheal stenoses force to search for a way of differential diagnostics of kind of a tracheal stenoses for ground of adequate treatment method.

Methods

Endoscopic reports of 70 patients with postintubation tracheal stenoses and of 34 patients with chronic tracheal diseases were investigated. In these patients at bronchoscopy local impedance at different levels of a trachea was investigated.

Results

Endoscopic view of cicatricial and inflammatory tracheal stenoses (ITS) did not differ irrespective of terms of their occurrence. At inflammatory tracheal stenoses among men and women significant distinctions between parameters of impedance in all level of trachea are not revealed. Impedance parameters at men with ITS are much higher in all levels of trachea, than at women. Among men with cicatricial tracheal stenoses in stenosis zone the impedance was significantly above, as against patients with inflammatory stenoses and from women. Significant distinctions of impedance between levels of measurement and from other diseases are revealed only among men with tracheomalacia between the low and middle parts of a trachea. In middle and low parts of a trachea the impedance at cicatricial tracheal stenoses did not differ from an impedance at chronic endobronchitis. At an estimation of average indices of an impedance at women in upper third of trachea the impedance at tracheomalacia was essentially higher in all cases. The impedance at women at ITS and cicatricial tracheal stenoses did not differ from chronic endobronchitis. In middle part of trachea at women the impedance at tracheomalacia essentially differed only from cicatricial tracheal stenoses. In the low part of trachea at women the impedance essentially differed from inflammatory tracheal stenoses and tracheomalacia.

Conclusions

Measurement of local impedance at tracheal stenoses allows to determine a kind of tracheal stenosis - cicatricial or inflammatory. The tracheal impedance differs at men and women. The tracheal impedance at chronic bronchitis at men and women does not differ from an impedance at cicatricial tracheal stenoses and can be considered as one of risk factors of cicatricial tracheal stenoses development. Measurement of local impedance at tracheomalacia specifies, that the tracheomalacia at men can serve as predictor of cicatricial stenosis, and at women of inflammatory stenosis. The impedance at tracheomalacia essentially differs at gender.

id 6

19th WCBIP / WCBE World Congress
JOINT MEETING OF THE WORLD ASSOCIATION FOR BRONCHOLOGY AND INTERVENTIONAL PULMONOLOGY & THE INTERNATIONAL BRONCHOESOPHAGOLOGICAL SOCIETY
www.wcbipwcbe2016.org
Fortezza da Basso
May 8-11, 2016
Florence (Italy)

Morphological changes of the trachea with postintubation stenosis

Anton Leontev[1], Alexey Korotkevich[2], Paul Aksenov[3], Elena Zakharchenko[1], Natalia Chechulina[4], Michael Merzljakov[5], Vitaly Koljadov[6]

[1]Endoscopy, Municipal City Hospital Nr.29 - Russian Federation
[2]Endoscopic surgery, Postgraduate Training Physician Institute - Russian Federation
[3]Pathological anatomy, Municipal City Hospital Nr.29 - Russian Federation
[4]Pathological anatomy, Bureau of Medicolegal Examination - Russian Federation
[5]Endoscopy, Regional clinical hospital Nr.1 - Russian Federation
[6]Pathological anatomy, Regional Pathoanatomical Bureau - Russian Federation

Introduction

Morphological investigations of tracheal stenoses, problems in choice of treatment‘s method and results of surgical treatment force to search for a way of differential diagnostics of kind of tracheal stenoses for ground of adequate treatment method.

Objective

Justify the timing and extent of interventional bronchoscopy in the prevention of postintubation stenosis.

Methods

Serial morphological research of trachea at 59 died patients, who taking place on long tracheal ventilation till 85 day and resected tracheal segments at 18 patients. Prospective randomized research of 50 patients with sever head injury. At 25 from them the complex early endoscopic treatments (treatment fiberbronchoscopy, magneto therapy) is used. At all 50 patients estimated changes of trachea before extubation/decanulation by fiberbronchoscopy.

Results

Morphologic signs of acute inflammation took place during all period of research. Signs of chronic inflammation are revealed since 4 day of intubation. Frequency of destructive changes progressively increased with 3 for 10 day of intubation. In one case it is not revealed destruction of tracheal cartilages. In the first 10 day of intubation essentially high frequency and severity of morphological changes are revealed depending on available stress - hyperglycemia for a moment of intubation. At operated patients frequency of morphological changes essentially differed in terms till 30 day and over 30 day from the moment of extubation/decanulation. Early endoscopic treatment has allowed to avoid in 92 % of cases tracheal complications.

Conclusions

The first 10 day of intubation are determining in frequency and severity of morphological changes of trachea, is especial at patients about stress - hyperglycemia for a moment of intubation. The complex early endoscopic preventive treatment allows to avoid late complications of long intubation /tracheostomy at the overwhelming majority of patients/

id 7

Foreign body of the trachea 20 years ago

Anton Leontev[1], Alexey Korotkevich[2]

[1]Endoscopy, City Hospital Nr.29 - Russian Federation
[2]Endoscopic surgery, Advanced Medical School for Doctors - Russian Federation

Introduction

Long-existing foreign bodies of the trachea present a problem both from the point of activation of compensatory mechanisms, and from the standpoint of treatment.

Methods

. Male, 36 years old, operated on for cystic hypoplasia of the right lung in 1987. After surgery the symptoms of laryngitis for several days, which were successfully treated. During the life of marked shortness of breath during physical activity, there was a weakness, marked laboratory signs of anemia. Multiple screening (chest x-ray, CT scan, bronchoscopy) have not identified the cause of the respiratory deficiency. In January 2014 completed videobronchoscopy: in the subglottic space was tight smooth circular stenosis of up to 7 mm in diameter, suspected foreign body. The patient is sent to our hospital. During bronchoscopy revealed a plastic foreign body in the subglottic space. The foreign body is not removed, but managed to turn it and move to the second tracheal ring. When muscle relaxation during repeated rigid bronchoscopy (operating tube bronchoscope (Karl Storz) the foreign body is fixed with two forceps and extracted with technical difficulties. In place of fixing of a foreign body deep ulcerative defects to the level of the first tracheal ring. Conservative prevention of stenosis of the trachea and larynx. At the control examination after a year marked by positive dynamics: the patient gained weight, became involved in the sport, no speech, no stenosis.

Conclusions

Unusual localization of a foreign no radiopaque foreign body leading to late diagnosis. Explanation of the clinic laryngitis response to endotracheal tube resulted in a decline in the quality of life of the patient in the postoperative period. The removal of long-existing foreign bodies of the trachea and larynx may and comprehensive prevention of stenosis of the larynx and trachea helped to restore the health of the patient.

id 8

19th WCBIP / WCBE World Congress
JOINT MEETING OF THE WORLD ASSOCIATION FOR BRONCHOLOGY AND INTERVENTIONAL PULMONOLOGY & THE INTERNATIONAL BRONCHOESOPHAGOLOGICAL SOCIETY
www.wcbipwcbe2016.org
Fortezza da Basso
May 8-11, 2016
Florence (Italy)

Transbronchial needle aspiration: thin prep vs conventional smear in the diagnosis of lung cancer

Valentina Conti[1], Martina Marchi[2], Irene Marchi[2], Claudio Cavicchi[3], Rosa Rinaldi[3], Marco Contoli[2], Alberto Papi[2], Franco Ravenna[4]

[1]Pneumology Unit, State Hospital, Republic of San Marino - Republic Of San Marino
[2]Pneumology Unit, Department of Emergency., University Hospital Arcispedale S. Anna of Ferrara. - Italy
[3]Pathology Unit, Department of Diagnostic Imaging and Laboratory, University Hospital Arcispedale S. Anna of Ferrara - Italy
[4]Pneumology Unit, CardioToracoVascolare Department., Carlo Poma Hospital. - Italy

Introduction

Almost 70% of patients with lung cancer present theirselves at an advanced stage of their disease, therefore are unresectable. Bronchoscopy is often first procedure performed and the diagnosis is usually based on biopsies and cytology specimens. Cytology is assuming an relevant role to obtain a biomolecular profile of the cancer. Liquid based cytology as Thin Prep(TP), unlike conventional smear(CS) technique, consents to preserve enough material, such as immunochemistry and molecular tests.

Objective

Evaluate the role of TP compared to CS in the diagnosis of lung cancer, using transbronchial needle aspiration(TBNA) to obtain the samples.

Methods

Bronchoschopy was performed on 101 patients with suspicious pulmonary lesion. For each patient were collected 4 cytological samples using TBNA. The 4 samples were examined alternating TP and CS. For each patient, the method employed in the examination of the first sample was decided by using a randomized list. The cytopathologic results from each method were compared to the definitive diagnosis.

Results

In 81 of 101 cases(81%) lung cancer diagnosis was confirmed. In 20 cases(19%) the disease was benign. CS and TP have shown respectively sensitivity of 57% and 58%; specificity of 100% and 100%; positive predictive value of 100% and 100%; negative predictive value of 39% and 46% and accuracy of 66% and 74%. ROC curves were then used to compare the two methods; the difference was found statistically not significant(p=0,415). Inadequate material was observed in 7 cases with CS and in no cases with TP. In 19 patients (19%) a rapid on-site evaluation (ROSE) was also performed; in these cases sensitivity, negative predictive value and accuracy of TBNA were respectively of 85%,75% and 90% while, in the remaining 82 cases in which ROSE wasn't employed, the results of CS and TP were respectively of 54%, 33% and 62%. In particular, the difference detected is statistically significant in NPV($p<0.0005$) and accuracy($p<0.05$) compared ROSE to CS or TP alone using Fischer's exact test.

Conclusions

The diagnostic yield of TP is substantially equal to the one made with CS in lung cancer disease. TP offers advantages in terms of reproducibility, easier slide evaluation, and above all the possibility of molecular testing. On the other hand CS allows the use of ROSE, which improves considerably accuracy of TBNA. The two methods could be used together in the diagnosis of lung cancer, integrating their respective advantages, in order to choose the most appropriate and personalized treatment for the patient.

Bibliography

-Kobayashi Y, et al Acta Cytol 2011;55:69-78 -Petriella D, et al Mol Biotechnol 2013 Jul;54(3):913-9. -P. Konofaos, et al Surgical Oncology 2006; 15: 173-178.

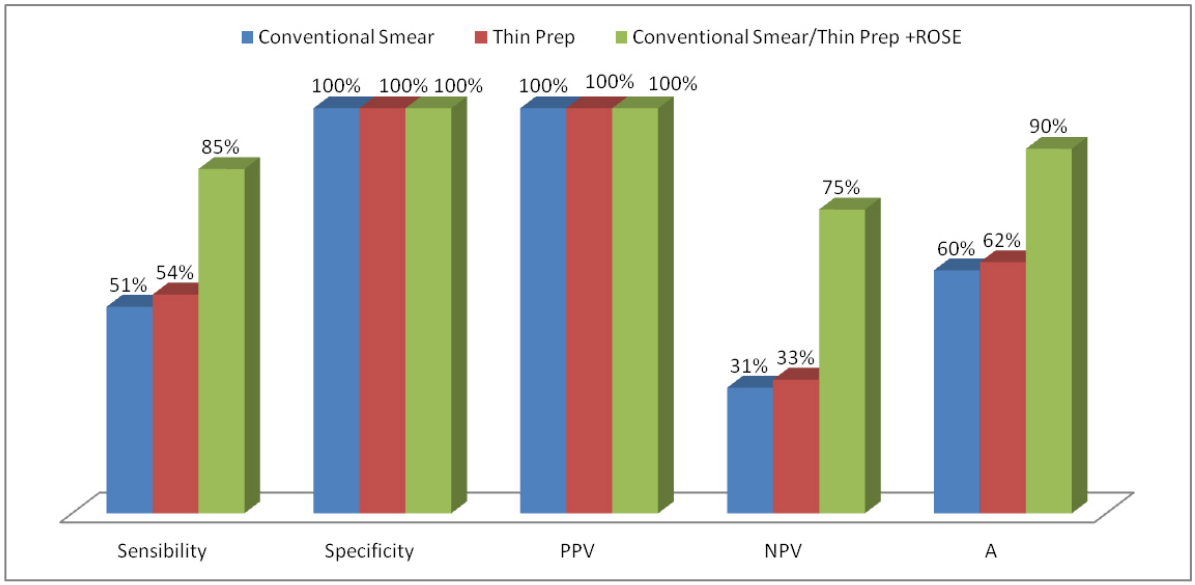

Comparison between CS/TP without ROSE and CS/TP with ROSE.

Data are presented as:

%: per cent; PPV: positive predictive value; NPV: negative predictive value; A: accuracy; TP: thin prep; CS: conventional smear; ROSE: rapid on site evaluation.

id 9

19th WCBIP / WCBE World Congress
JOINT MEETING OF THE WORLD ASSOCIATION FOR BRONCHOLOGY AND INTERVENTIONAL PULMONOLOGY & THE INTERNATIONAL BRONCHOESOPHAGOLOGICAL SOCIETY
www.wcbipwcbe2016.org
Fortezza da Basso
May 8-11, 2016
Florence (Italy)

Presentation of pleural effusion in Dengue fever

Murwan Mohamed Saeed

Pulmonology, Port Sudan Teaching Hospital - Sudan

Introduction

Dengue fever is a flue like viral infection, caused by flavivirus.It transmitted by Aedes aegypti mosquito. The virus has four different genetic serotypes. DF has three different presentation, these are DF, DHF, DSS. It diagnosed clinically, and confirmed serologically. Pleural effusion is common in dengue fever; its mechanism is increased vascular permeability, and plasma leakage. Usually pleural effusion resolve spontaneouslybut, pleurocentesis is considered in severe respiratory compromise condition. Dengue fever was firstly recognized in 1950 in Philippine and Thailand. WHO estimate about 50 - 100 million case of dengue fever per year. In Red sea state, east Sudan cases started to be recorded in significant number from 2002, and considered endemic since 2005.

Objective

To know the presentation of dengue fever in Port Sudan, eastern Sudan, and to detect the common causes.

Methods

This is a descriptive study, done in Port Sudan, from January to December 2014. In 42patients, who were hospitalized with dengue fever, and developed pleural effusion. History was taken and clinical examination done, this followed by, laboratory, radiological investigations, and ECG. And data analyzed manually.

Results

From those 42 patients (71.1%) female and (28.9%) male . (85.7%) admitted with DF, (9.5%) DHF, and (4.8%) DSS. Respiratory symptoms was cough (100%), SOB(80.2%), chest pain(42.9%), haemoptysis (9.5%). Pleural effusion was serous (92.9 %), haemorrhagic (7.1 %), Exudative(52.4 %) and transudative(47.6%).Platelets was decreased in (90.5%), normal in (9.5%).Liver enzymes elevated in(52.4%) , normal in(47.6%). S.albumin decreased in(73.8%),normal in(26.2%).CXR showed unilateral effusion (66.7%), bilateral effusion(33.3%),cardiomegaly (28.6%),consolidation (19%), collapse(14.3%), hilar shadow(4.8%). ECG showed sinus tachycardia (90.5%), T- inversion (38.3%), RT axis (7.1%), and S1Q3T3 (4.8%).Causes of effusion was pneumonia (28.6%), CCF(28.6%) , hypoalbuminaemia (19%),PE(9.5%), and (14.3%) remain unknown.

Conclusions

Pleural effusion may complicate dengue fever either as a consequent of fluid over load or as features of other pulmonary or non pulmonary complication. It occurs despite normal platelets count , but more with thrombocytopenia. It affects both morbidity and mortality of dengue fever. PE appears as a cause of pleural effusion in significant number, despite it is rare to complicate dengue fever.

Bibliography

1-Red sea state epidemiology department record.

The presenting author has the following conflicts of interest that relate to this abstract: *The author is a consultant pulmonologist in Port Sudan, eastern Sudan, where dengue fever is endemic and usually complicated with resoiratory problems.*

id 10

19th WCBIP / WCBE World Congress
JOINT MEETING OF THE WORLD ASSOCIATION FOR BRONCHOLOGY AND INTERVENTIONAL PULMONOLOGY & THE INTERNATIONAL BRONCHOESOPHAGOLOGICAL SOCIETY
www.wcbipwcbe2016.org
Fortezza da Basso
May 8-11, 2016
Florence (Italy)

Transesophageal tracheal dilatation and intubation for large TEF with non-tumor tracheal stenosis

Rusakov Mikhail[1], Parshin Vladimir[2], Titov Viktor[3]

[1]Department of endoscopy, I.M. Sechenov First Moscow State Medical University, Moscow, Russia - Russia
[2]Department of Thoracic Surgery, I.M. Sechenov First Moscow State Medical University, Moscow, Russia - Russia
[3]Department of Anesthesiology, I.M. Sechenov First Moscow State Medical University, Moscow, Russia - Russia

Introduction

Surgery is the only standard treatment for patients with an iatrogenic tracheoesophageal fistula (TEF). When a TEF occurs with tracheal stenosis, the tracheal lumen must be expanded prior to intubation. Generally, stenosis widening is achieved with rigid bronchoscope tubes under general anesthesia.

Methods

We treated a 45-year-old woman and 55-year-old woman with iatrogenic TEFs longer than 2 cm with tracheal stenosis in February and December of 2014, respectively. Both patients were cachectic (body mass indices of 16.8 and 12.5, respectively). Both were eating through the gastrostomy tube and had trouble breathing through a tracheostomy tube. The patients' tracheal walls were absent near the fistula, resulting in a common luminal cavity at the level of the fistula. The lumens at the cranial and caudal portions of the tracheas communicated with the cavity through apertures (diameters, 5~6 mm). The length of each constriction was 0.5–1.5 cm. General anesthesia could not be administered due to inadequate breathing and diversion of mechanical ventilation by any method to the stomach, the path of the least resistance (Fig. 1). Therefore, in both cases, we extended the hole between the general cavity and distal trachea with balloon dilators (Boston Scientific, USA) under local anesthesia and endoscopic observation. To simplify and hasten the procedure, access to the caudal trachea was performed through the unobstructed lumen of the esophagus, rather than through the proximal trachea. And intubation of the distal trachea was made through the esophageal lumen too, guided by a flexible bronchoscope. Both patients were operated successfully. Sleeve tracheal resection with end-to-end anastomosis and lateral suturing of the esophagus was performed in both cases. Normal breathing was restored through the tracheostomy tube immediately after surgery, and oral food consumption was resumed 6 days postoperatively in both cases.

Conclusions

An unconventional approach to dilatation and intubation tracheal stenosis by transesophageal access can reduce the risk of general anesthesia in patients with a large TEF and severe tracheal stenosis.

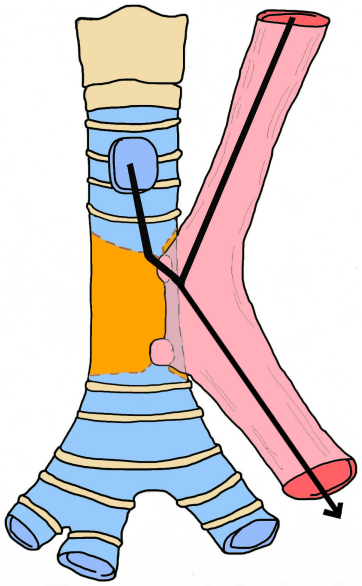

A unique case of tumor track seeding following bronchoscopic fiducial marker placement

Rafael Alba Yunen, Md[1], Robert Bertoli, Md[2], Paul Branca, Md[1]

[1]Department of Medicine, Division of Pulmonary, Critical Care & Interventional Pulmonology, University of Tennessee Graduate School of Medicine - U.S.A
[2]Department of Radiology, Division of Radiation Oncology, University of Tennessee Graduate School of Medicine - U.S.A

Introduction

Stereotactic body radiation therapy (SBRT) delivers a targeted dose to a tumor, with precision and less damage of healthy tissues. SBRT has been shown to be effective for medically inoperable early stage non-small cell lung carcinoma (NSCLC)(2). To track the tumor, fiducial markers (FM), can be implanted bronchoscopically or percutaneously in the lesion or around it. FM placement has complications such as bleeding, pneumothorax and migration (1). We present a case of tumor seeding around a FM after bronchoscopic insertion.

Methods

67 year-old male, smoker, presented with a left upper lobe (LUL) squamous cell lung carcinoma, stage I (Fig.1A). Not considered a surgical candidate (FEV1 0.9lt, 27% predicted), 5 fiducials (superLock Cobra) were placed bronchoscopically and 4 stages of Cyberknife SBRT were completed (Fig.1B). A year later he presented with weight loss. Imaging showed an enlarging, new nodular focus surrounding a FM in the anterior LUL (Fig.1C). PET/CT confirmed a hypermetabolic focus (SUV 14.5) with mildly hypermetabolic adenopathy (Fig.1D). Sampling the nodular focus seemed reasonable but was not considered due to anti- platelet therapy for recent coronary event. Transbronchial needle aspirates under endobronchial ultrasound were performed of the mediastinal and hilar nodes. Both were negative for malignancy. Broad-spectrum antimicrobials were given empirically. Microbiologic and cytology workup were unremarkable. Cyberknife SBRT was performed to treat the left lung hypermetabolic lesion for presumed recurrent NSCLC. Subsequent PET/CT showed decreased SUV from 14.5 to 3.1(Fig.1F).

Conclusions

Tumor track seeding after fiducial placement has been uniquely described via CT-guided percutaneous approach in a single case-report. To the best of our knowledge, implantation metastasis via the bronchoscopic approach after fiducial placement has not yet been reported and represents the uniqueness of this case. These FM were optimally placed on different planes. We believe that placing the FM distal to the tumor but through it may have led to seeding malignant cells at the end of the track leading to the development of a new focus around the FM. We believe that part of the FM might have collected these malignant cells. This rare complication should not dissuade the placement of FM. However, techniques to avoid tracking malignant cells should be explored.

Bibliography

1. Nikhil Bhagat et al. Cardiovasc Intervent Radiol. 2010; 33(6): 1186–1191. 2. Shibamoto Y et al. Cancer. 2012; 118(8): 2078-84.

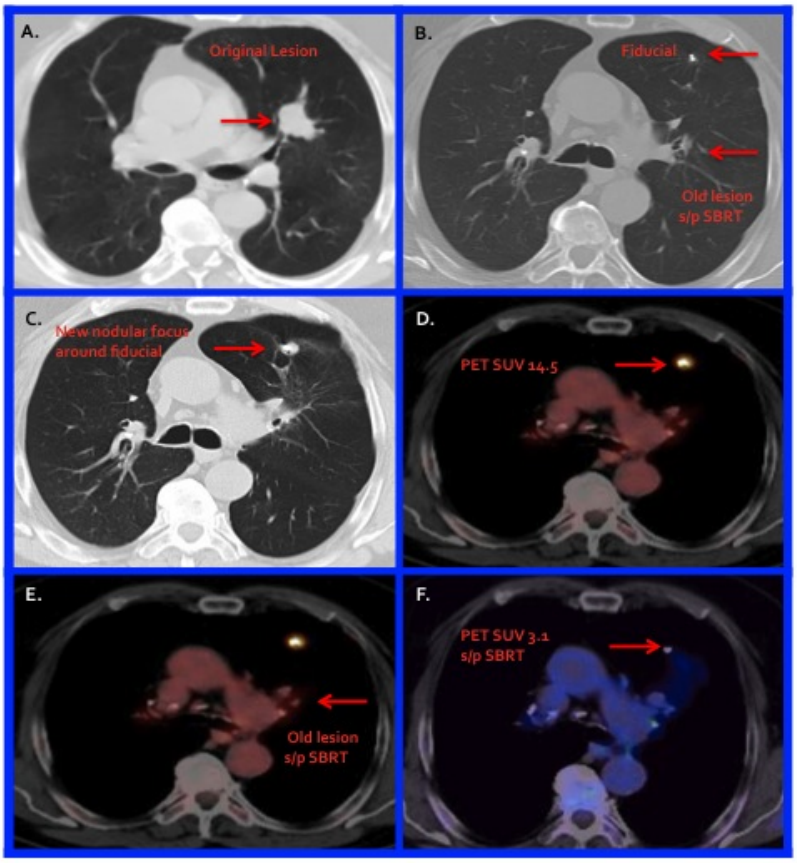
A.
Original Lesion
B.
Fiducial
Old lesion
s/p SBRT
C.
New nodular focus
around fiducial
D.
PET SUV 14.5
E.
Old lesion
s/p SBRT
F.
PET SUV 3.1
s/p SBRT

id 12

19th WCBIP / WCBE World Congress
JOINT MEETING OF THE WORLD ASSOCIATION FOR BRONCHOLOGY AND INTERVENTIONAL PULMONOLOGY & THE INTERNATIONAL BRONCHOESOPHAGOLOGICAL SOCIETY
www.wcbipwcbe2016.org
Fortezza da Basso
May 8-11, 2016
Florence (Italy)

Role of bronchoscopy in carinal procedures

Rajan Santosham[1], Rajiv Santosham[1], Deepthi Morais[2], Sweta Ramani Salla[1], Roshan Santosham[3], Ravi Santosham[3]

[1]Thoracic Surgery, Santosham Chest Hospital - India
[2]Anaesthesia, Santosham Chest Hospital - India
[3]Pulmonary Medicine, Santosham Chest Hospital - India

Introduction

Both rigid and fibreoptic bronchoscopy is extremely useful in preoperative assessment to determine the extent and length of tumors, to plan anesthetic management and in extensive inoperable cases for the placement of stents (silastic Y stents after fulguration). Peroperatively it is helpful in assessing the anastomotic site. Carinal surgeries considered challenging in view of the limits in the exposure, mobilization, resection as well as anaesthetic and surgical management. Postoperatively Bronschoscopy is useful in removing retained secretions.

Objective

The aim is to provide a good airway for patients with carinal lesions either surgically or with diathermy fulgration with dilatation. The objective is to report our experience in careful management of carinal tumours with pre,per and postoperative Bronchoscopy.

Methods

A retrospective study conducted from 1990 to 2015, we had 49 cases of carinal mass lesions. 36 cases (73.4%) requiring surgical intervention and 13 cases (26.5%) were treated medically. During the same period we have performed 450 tracheal resections. Preoperative evaluation with Bronchoscopy, CT scan plain and contrast with 3D reconstruction was done to determine the extent of the disease and operability. Extent of resection limited to 3.5cm. Anastomosis by absorbable 3-0 PDS using interrupted everted suturing technique with knots outside the tracheal wall.

Results

Carinal mobilization was done in 36/49 cases: 9 cases (25%) of right sleeve resection , 6 (50%) traumatic bronchial rupture, 8 (22.23%) low tracheal tumours, 6 (50%) carinal tumours, 2 (5.6%) carinal right pneumonectomy, 2 (5.6%) carinal left pneumonectomy. 33 cases were performed through right thoracotomy, 1 case median sternotomy and 2 by Bilateral thoracotomy approach. 17/49 cases were carinal tumours – 11 cases needed palliative treatment with Diathermy fulguration and dilatation . The range of follow up in these patients was 1-25 yrs with a mean follow up period of 10 yrs. The overall mortality is 2/36 (5.6%) with 1 early mortality (done through right pneumonectomy) due to Tracheo-bronchial disruption with necrosis and 1 late mortality (done through left pneumonectomy) after 10 years post procedure with extensive metastasis in both lungs.

Conclusions

Carinal surgery is technically demanding and needs careful preoperative preparation and anaesthetic support to reduce the significant morbidity. Careful surgical planning is mandatory and aim must be to get a tension free anastomosis with preferably negative margin. The role of brochoscopy is key for assessment pre and postoperatively. Better results are obtained as the experience of the surgical team increases.

19th WCBIP / WCBE World Congress
JOINT MEETING OF THE WORLD ASSOCIATION FOR BRONCHOLOGY AND INTERVENTIONAL PULMONOLOGY & THE INTERNATIONAL BRONCHOESOPHAGOLOGICAL SOCIETY
www.wcbipwcbe2016.org
Fortezza da Basso
May 8-11, 2016
Florence (Italy)

Tracheobronchial Smooth Muscle Atrophy and Separation (TB-SMAS)

Atul C. Mehta

Pulmonary Medicine, Cleveland Clinic - Usa

Introduction

To describe a new entity of Tracheobronchial smooth muscle or pars membranacea atrophy and its separation from the cartilaginous rings (TB-SMAS) .

Objective

To describe a new entity of Tracheobronchial smooth muscle or pars membranacea atrophy and its separation from the cartilaginous rings (TB-SMAS)

Methods

Materials and Methods: Four cases of TB-SMAS will be presented with the bronchoscopic as well as radiographic findings to establish the entity. Review of the literature related to the pathophysiology of airway smooth muscle atrophy will be discussed.

Results

Results: Tracheobronchomalcia (TBM) and Excessive Dynamic Collapse (EDC) are being recognized with increased frequency in the recent years. This is likely as a result of increasing number of CT scans and bronchoscopy being performed. Atrophy of the airway smooth muscles and their separation from the tracheonronchial wall cartilages could be a likely extension of TBM and EDC. Reviewing the literature, it is found that bronchial smooth muscle atrophy is present in cases with Atrophic Bronchitis (Deformans), Mounier-Kuhn Syndrome and Bronchial Diverticuli. However none of our patients suffered with such conditions. Further review suggests that TB-SMAS could be related to increasing use of high dose inhaled corticosteroids

Conclusions

Conclusions: TB-SMAS patients demonstrate features of bronchial smooth muscle atrophy and separation due to unknown etiology. As evident on bronchoscopy and CT images, TB-SMAS causes airway collapse and may lead to airway obstruction in these patients. TB-SMAS also carries a risk of rupture of the trachea especially in patients undergoing rigid bronchoscopic interventions. Therefore, potential prevention and early diagnosis of TB-SMAS has a major clinical significance. Future studies aimed at evaluating the association of Inhaled Corticosteroids with TB-SMAS and elucidating the underlying mechanisms should be considered.

Bibliography

Mehta AC, Zaki KS, Banga A, Singh J, Gildea T, Arrossi V, Tracheobronchial Smooth Muscle Atrophy and Separation, Respiration, DOI: 10.1159/000431381

19th WCBIP / WCBE World Congress
JOINT MEETING OF THE WORLD ASSOCIATION FOR BRONCHOLOGY AND INTERVENTIONAL PULMONOLOGY & THE INTERNATIONAL BRONCHOESOPHAGOLOGICAL SOCIETY
www.wcbipwcbe2016.org
Fortezza da Basso
May 8-11, 2016
Florence (Italy)

Epidemiological profile and Clinical Characteristics of the Childhood Asthma among School Students

Hamid Hussain Hussain

DHA, Dubai residency training program - Uae

Introduction

Asthma is the third-ranking cause of hospitalization among children under 15 In the UAE

Objective

To study the prevalence, clinical and epidemiological profile, and socio demographic risk factors of the childhood asthma in Dubai.

Methods

A cross-sectional study was conducted among students in preparatory and secondary schools “Governmental and Private” in Dubai, U.A.E. A sample of 1639 students was selected randomly by multistage stratified random sampling technique.

Results

16.7% have had an asthma attack at some point of time. About 38.5% had asthma at age of less than 3 years, 28.6% from 3 to less than 6 years, 19% from 6 to less than 9 years and only 13.9% at an age of 9 years or more with a mean of 5.0 ± 2.9 years. most of the studied students had no wheezing or whistling in the chest at any time in the past (83.5 while 72.9% had wheezes within the last 12 months. Amongst those who had wheezes in the last 12 months 59.8% had 1 to less than 4 attacks during this period, 23.6% had 4 to 12 attacks and 8.5% had more than 12 attacks. As regards the frequency of asthma symptoms per week it can be noted that 8.5% had the symptoms over the day, another 11.1% had daily symptoms, 49.2% had the symptoms 2 times or less / week and another 31.2% had the symptoms frequency of more than 2 times / week but not daily. Regarding the sleeping it was disturbed less than once weekly in 35.2% while it was disturbed once or more per week in 19.1%. Studying the frequency of nocturnal symptoms; 6.5% had frequent nocturnal symptoms, 11.1% had these symptoms more than once per week, 20.1% experienced the nocturnal symptoms 3-4 times a month and the vast majority experienced the symptoms less than twice monthly. Speech limitation due to wheezing was reported by 42.2%, and 66.8% experienced wheezes during and after exercise. As regards using inhalers, the frequency of use ranged from less than or twice weekly in 57.8% and several times/ day in 8%, while it was used daily in 8.5% and used more than twice weekly in 25.6%.

Conclusions

The prevalence of asthma among secondary school student in Dubai is high.

id 15

A rare cause of haemoptysis in a middle aged lady

Samuel Lee, Yu Wai Wong, Colin Lui

Medicine, Tseung Kwan O Hospital - Hong Kong Sar China

Introduction

Tracheobronchial amyloidosis is a rare disease. We are reporting a case of distal tracheobronchial amyloidosis in a middle aged lady with haemoptysis as the presenting feature.

Methods

A 41 years old lady presented with first episode of haemoptysis. She is healthy all along. She complained of on and off dry cough for one month and attended emergency department when she found blood in the sputum. No other symptom wae reported. Physical examination and investigations, including chest x ray, blood tests and sputum examination were all normal. Flexible bronchoscopy was then performed. A tiny soft tissue nodule was seen at the bronchus intermedius of right lung which was removed with forcep. Histological examination showed deposition of pink amorphous tissue compatible with the diagnosis of tracheobronchial amyloidosis. CAT scan of thorax did not reveal other site of involvement and lung function was normal. Bone marrow examination and serum immunoglobulins studies showed negative result. The lady is being followed up at our clinic and is welL and stable.

Results

Amyloidosis is a disease characterized by the deposition of abnormal proteins in extracellular tissue. In respiratory tract, it can be classified as systemic, which accounts for 80% of cases and localized. Tracheobronchial amyloidosis, while is the commonest form of localized diseases, is very rare with about 150 cases reported worldwide in 2008. It affects men more than women and typically presents in the 5th-6th decade. Common presenting symptoms include progressive dyspnea, wheezing/stridor, cough, hoarseness and haemoptysis. Chest X ray is normal in 50% of cases. Computed axial tomography (CAT) is more sensitive in detection of narrowing in airway and associated atelectasis. Definite diagnosis is usually made by tissue biopsy during bronchoscopic examination. The appearance ranged from circumscribed, superficial yellow lesions to erythematous, raised cobblestone infiltration of mucosa. O'Regean et al had identified 3 patterns of involvement: proximal, mid and distal. Proximal disease was found to be assoicated with early respiratory death with mortality rate of 30% within 7-12 years after diagnosis while distal and most mid airway involvement usually had stagnant disease. Both CAT thorax and pulmonary function tests are advocated for disease progress monitoring. No definite treatment has been found. Rigid bronchoscopic debridement and laser treatment had been used for symptomatic relief but did not prevent disease progression.

Conclusions

Tracheobronchial amyloidosis is a rare but one of the important causes of hameoptysis and involvement of proximal airway might be associated with significant morbidity and mortality.

Bibliography

O'Regan et al Medicine 2000 79:69-79 Saleiro et al J Bronchol. 2008 15:95-99

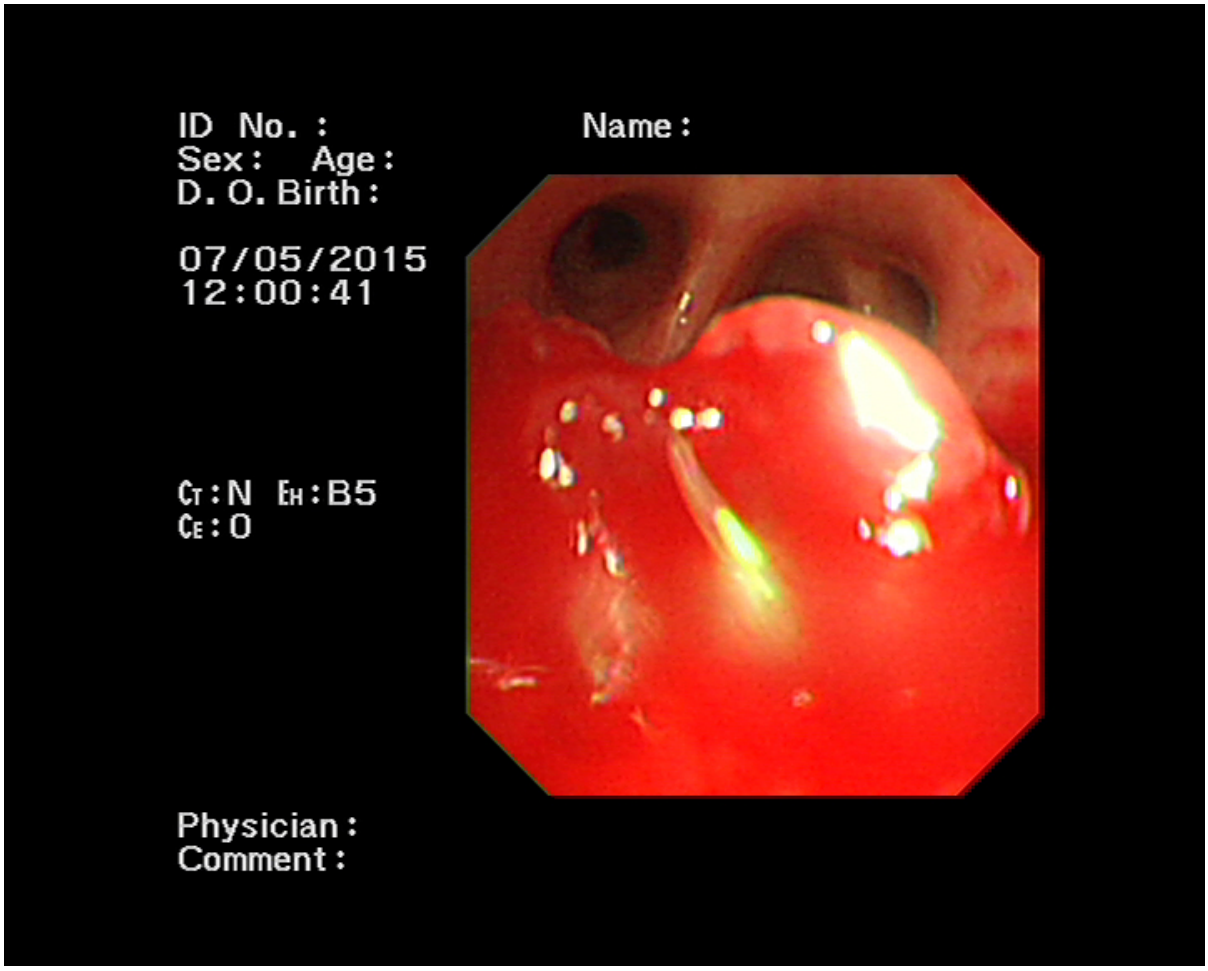
ID No. :
Name :
Sex : Age :
D. O. Birth :
07/05/2015
12:00:41
CT : N EH : B5
CE : 0
Physician :
Comment :

id 16

Evaluation of Pulmonary Nodules in Asian Population

Chee Kiang Phua, Albert Lim, Dessmon Tai, Soon Keng Goh, Ai Ching Kor, Benjamin Ho, John Abisheganaden, Akash Verma

Respiratory and Critical Care Medicine, Tan Tock Seng Hospital - Singapore

Introduction

Pulmonary nodules are common and may be of malignant or benign aetiology. They are managed according to the American College of Chest Physicians (ACCP) guidelines. However, it remains unclear if current guidelines for evaluating pulmonary nodules would be applicable in the Asian context where TB endemicity is higher.

Objective

We studied our current pattern of clinical practice in the managing pulmonary nodules examining the strengths and limitations of using (ACCP) guidelines in managing them.

Methods

We retrospectively reviewed the medical records of patients diagnosed with lung cancer in 2010 and collected clinical data, demographic data, nodule characteristics, histology, staging, treatment received, and survival in patients presenting with a single solitary pulmonary nodule (SPN) or multiple pulmonary nodules (MPN).

Results

We had total 60 nodules in 32 patients. Incidental nodules were detected on routine imaging in 21.9%. TB contact and pre-employment screening were other common ways in which nodules were incidentally detected. Over one third were non-smokers. Majority of nodules were 1 to 3 cm in diameter, and most commonly located in the right lung, with right upper lobe, left upper lobe and right lower lobe being frequently involved lobes. Apico-posterior segment of Left upper lobe & apical and anterior segment of right upper lobes were most frequently involved segments. In a retrospective analysis of malignancy risk with the probability calculator, 62.5% of patients were low-moderate risk whilst 32.5% were high risk. Adenocarcinoma was the most common histological type. Only few patients had positron emission tomography (PET) scan for staging purposes. There were no difference in survival between patients who presented with single or multiple nodules.

Conclusions

The clinical practice of managing pulmonary nodules in Singapore differs from the ACCP guidelines. None of the patient had pre-test probability calculated and few had PET scan. This was partly because a non-smoking history does not have any weight in discounting malignancy risk where many of our Asian lung cancer patients are non-smokers and partly secondary to the local endemicity of TB and its confounding effect on radiological findings of CT scan and PET scan.

id 17

19th WCBIP / WCBE World Congress
JOINT MEETING OF THE WORLD ASSOCIATION FOR BRONCHOLOGY AND INTERVENTIONAL PULMONOLOGY & THE INTERNATIONAL BRONCHOESOPHAGOLOGICAL SOCIETY
www.wcbipwcbe2016.org
Fortezza da Basso
May 8-11, 2016
Florence (Italy)

Sequelae of tuberculosis with recurrent hemoptysis: a case report

Isnin Marhana, Amin Muhammad, Kowiy Akbar

Pulmonology and Respiratory Medicine, Airlangga University - Indonesia

Introduction

The occurrence of chronic foreign body in the tracheobronchial tree is rare, with nonspesific respiratory symptoms that often constitutes a diagnostic challenge. Late detection of this disease can cause chronic inflammation and granulation tissue formation around the foreign body, which sometimes presents as an intrabronchial mass.

Objective

We present the case of a 21 year old male who had chronic respiratory symptoms (hemoptysis, cough, wheezing, recurrent pneumonia) caused by foreign body aspiration 7 years before

Methods

Plain thorax film initially showed lobar consolidation on right inferior lobe. CT Scan showed ground glass opacity and multiple rim enhanced lesion in right inferior lobe. Bronchoscopy revealed intrabronchial mass accompanied by increased vascularization on NBI (narrow band imaging). From EBUS Guide Sheath, we find appearance like 'within the lession' that allowing the overview of lung tumor.

Results

Lobectomy of the right inferior lobe finally revealed a radioluscent foreign body (plastic cylindrical whistle) lodged at the bifurcation of the right inferior bronchus, surrounded by granulation tissue, and accompanied with pus-filled multiple cysts in the right inferior lobe. The patient experienced a swift recovery and was well at follow up.

Conclusions

It is concluded that chronic, unexplained respiratory symptoms should warrant further investigation to exclude foreign bodies despite negative history and misleading clinical manifestations

Bibliography

Kurimoto N, Fielding D, Musani A.I, Diagnosis of Peripheral Pulmonary Lession in Endobronchial Ultrasonography, Willey Blackwell Publishing, 2011; 89-95.

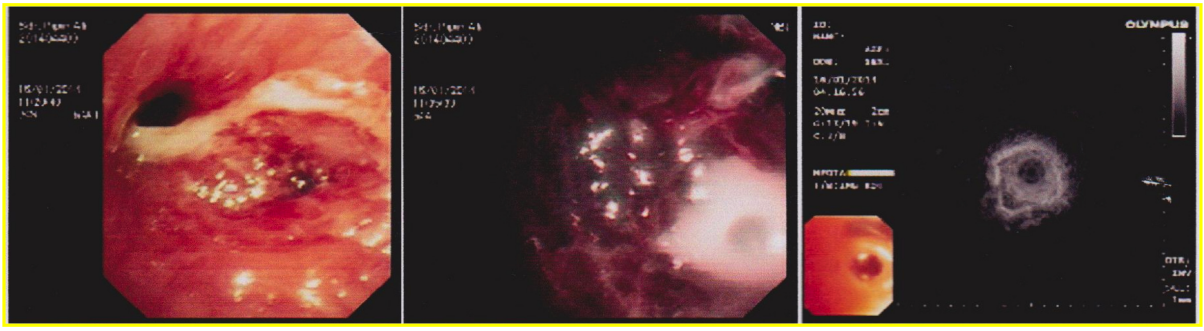

19th WCBIP / WCBE World Congress
JOINT MEETING OF THE WORLD ASSOCIATION FOR BRONCHOLOGY AND INTERVENTIONAL PULMONOLOGY & THE INTERNATIONAL BRONCHOESOPHAGOLOGICAL SOCIETY
www.wcbipwcbe2016.org
Fortezza da Basso
May 8-11, 2016
Florence (Italy)

Chronic foreign body aspiration manifesting as intrabronchial tumor: a case report

Isnin Anang Marhana Anang Marhana, Isnu Pradjoko, Desilia Atikawati

Pulmonology and Respiratory Medicine, Airlangga University - Indonesia

Introduction

Various sequelae and complications can occur in treated or untreated tuberculosis (TB). One of complications in the lungs is hemoptysis, due to alterations of pulmonary vascular structure. Hemoptysis as TB sequelae can happen recurrently and massively.

Objective

We present the case of 31-year-old man with recurrent hemoptysis since 1 year before admitted to hospital. Patient had a history of receiving antituberculosis drugs (ATD) before.

Methods

Chest x-ray showed pleural thickening and opacity in right hemithorax with signs of loss of volume. Bronchoscopy showed active bleeding in lateral segment of right lung middle lobe. Chest CT showed destroyed right lung. Hemoptysis still existed despite the given conventional therapy, thus patient underwent pulmonary arteriography. The result showed extensive vascular abnormality in the right lung with arteriovenous fistula on right bronchial artery and aneurysmatic branch of superior bronchial and inner intercostal arteries. During the procedure, there was no active bleeding, so bronchial artery embolization was adjourned. Patient then experienced recurrent and massive hemoptysis.

Results

Right pneumonectomy was done. During the surgery, there was uncontrolled active bleeding that caused the patient’s death.

Conclusions

This case illustrates recurrent hemoptysis as one of severe TB sequelae. In extensive pulmonary vascular abnormality, pneumonectomy can cause uncontrolled active bleeding. Bronchial artery embolization can be used as an alternative to treat patients with recurrent homptysis.

Bibliography

Lordan JL, Gascoigne A, Corris PA. (2003). The pulmonary physician in critical care: assessment and management of massive hemoptysis. BMJ Thorax, 58: 814-9.

Use of Amplatzer device for endobronchial closure of right main bronchial stump dehiscence

Asma Navasakulpong[1], Supaporn Roymanee[2]

[1]Medicine, Prince of Songkla university - Thailand
[2]Pedriatric, Prince of Songkla university - Thailand

Introduction

Postpneumonectomy bronchopleural fistulas (BPFs) or main bronchial stump dehiscence is a severe complication and difficult to manage with a high rate of morbidity and mortality. Some of patients have limited performance status for reoperation. We have used a minimally invasive method with Amplatzer vascular plug II (AVP II)device,that was originally designed for the transcatheter closure of vascular structures or atrial septal defect, for main bronchial stump dehiscence closure.

Objective

To evaluate the efficacy and safety for the first time use of AVP for bronchoscopic closure of postoperative main bronchial stump dehiscence.

Methods

A 61 year-old male patient with metastasis renal cell carcinoma, who had right main bronchial stump dehiscence from right pneumonectomy, was treated under general anesthesia (GA) by bronchoscopic closure of stump dehiscence using AVP II device. After located the stump dehiscence lesion under flexible bronchoscopic visualization, the first self-expanding nitinol made AVP II occluder No. 16 was delivered under bronchoscopic guidance over a loader wire into the middle hole of fistulas and followed by fluoroscopy to assure proper device positioning and sealing of the fistulas. The second AVP II occluder No.8 was placed to the residual fistula later, using the same technique. Checking the complete occlusion of fistulars under direct bronchoscopic view and fluoroscopy was done at the end to confirm the position of devices.

Results

After procedure, patient was extubated and discharged home the day after. No complication occurred. Patient returned to work and improved dyspnic symptom. The chest x-ray showed the decrement of pneumothorax in 2 months. No pulmonary infection occurred after procedure.

Conclusions

Endobronchial closure using the AVP is a minimally invasive procedure which is safe and effective for treatment of main bronchial stump dehiscence. It is easily placed by using flexible bronchoscopy under GA or moderate conscious sedation.

Bibliography

Gulkarov I, et al. Interactive CardioVascular and Thoracic Surgery 2009;9:901-2. Fruchter O, et al. Respiration 2014;87:227-233.

id 20

19th WCBIP / WCBE World Congress
JOINT MEETING OF THE WORLD ASSOCIATION FOR BRONCHOLOGY AND INTERVENTIONAL PULMONOLOGY & THE INTERNATIONAL BRONCHOESOPHAGOLOGICAL SOCIETY
www.wcbipwcbe2016.org
Fortezza da Basso
May 8-11, 2016
Florence (Italy)

Mycobacterium Avium Complex Presenting as an Endobronchial Mass in an Immunocompromised Patient

Chuen Peng Lee, Carmen Tan, Kar Mun Eu, Caroline Choong, Kuan Sen Tee, Dessmon Tai, John Abisheganaden

Respiratory and Critical Care Medicine, Tan Tock Seng Hospital - Singapore

Introduction

Mycobacterium Avium Complex (MAC) is a ubiquitous bacterium found in the environment. It rarely causes disease in immunocompetent hosts. Disseminated MAC can occur in patients with acquired immunodeficiency syndrome (AIDS). Pulmonary MAC can present as fibrocavitary lesions, nodules and interstitial infiltrates(1). Endobronchial MAC is very rare(2).

Methods

A 50 year old lady presented to the hospital with a 3 months history of cough and loss of weight of 10kg over the past 1 year. She was tested positive for human immunodeficiency virus (HIV). CD4/CD8 ratio was 0.25. HIV viral load was undetectable. She was also started on highly active antiretroviral therapy. Initial computed tomography (CT) of the thorax revealed bilateral confluence consolidation. Bronchoscopy and transbronchial lung biopsies yield pneumocystis jirevoci which was treated. She was readmitted 6 months later with persistence of symptoms and infiltrates on CXR. A repeat CT thorax (See Figure) revealed persistence and new bilateral consolidative changes. Bronchoscopy revealed whitish plaque-like lesions within the airways (See Figure). Bronchial washings and brushings were suggestive of granulomatous inflammation. Endobronchial biopsies yield necrotising granulomatous inflammation with presence of acid fast bacilli, later identified to be MAC.

Conclusions

Common endobronchial masses in an HIV host include mycobacterium tuberculosis complex, malignancies (i.e. Kaposi sarcoma, lymphomas and lung cancers) and fungal infections (i.e. aspergillus airway disease, pneumocystis jiroveci). Endobronchial MAC has been associated with immune reconstitution and treatment usually lead to good outcomes.

Bibliography

1. Griffith DE et al. AJRCCM. 2007;175(4):367-416. 2. Kim et al. The Korean journal of internal medicine. 2007;22(3):215-9.

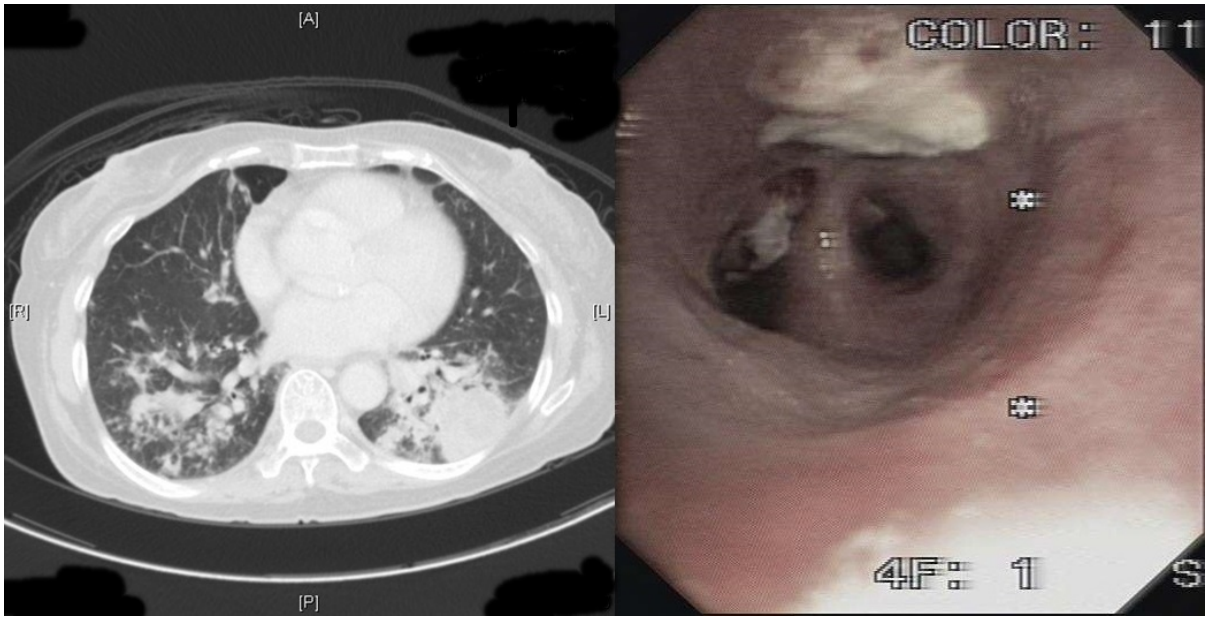

19th WCBIP / WCBE World Congress
JOINT MEETING OF THE WORLD ASSOCIATION FOR BRONCHOLOGY AND INTERVENTIONAL PULMONOLOGY & THE INTERNATIONAL BRONCHOESOPHAGOLOGICAL SOCIETY
www.wcbipwcbe2016.org
Fortezza da Basso
May 8-11, 2016
Florence (Italy)

The 4 Views of the Fluoroscopic-Guided Transbronchial Lung Biopsy

Chuen Peng Lee, Carmen Tan, Caroline Choong, Kar Mun Eu, Kuan Sen Tee, Akash Verma, John Abisheganaden

Respiratory and Critical Care Medicine, Tan Tock Seng Hospital - Singapore

Introduction

Transbronchial lung biopsy (TBLB) was first introduced by Howard Anderson in 1965 when the procedure was performed in 13 patients(1). It still remained widely employed as the diagnostic method of choice in diagnosis of peripheral lung diseases.

Methods

Diagnostic accuracy of TBLB can be as high as 60% in skilled hands in well selected patients. Newer technologies such as electromagnetic navigation, navigation bronchoscopy, and radial endobronchial ultrasound have challenged the use of fluoroscopic-guided TBLB. However, the current cost benefit ratio does not justify the routine use of these novel techniques. Though the diagnostic yield from a combination of thee novel techniques may be as high as 88%(2), this is unlikely in centres with low volume and in inexperienced hands. Advantages of TBLB over such newer techniques include higher cost effectiveness, shorter endoscopy time and a less steep learning curve. Advantages of newer methods include less or no radiation exposure and higher diagnostic yield with the more precise imaging techniques.

Conclusions

Despite its widespread use, there is a paucity of literature correlating the 4 basic views of fluoroscopic guided TBLB i.e radiologic (coronal and sagittal CT cuts), fluroscopic and bronchoscopic views. We compiled a collection of these views for some of the commonly accessed bronchopulmonary segments (Figure 1) for a series of known peripheral lung diseases.

Bibliography

1. Andersen HA, et al. CHEST Journal. 1965;48(2):187-92. 2. Memoli et al. CHEST Journal. 2012;142(2):385-93.

EBUS-TBNA for Nodal Staging in Non-Small Cell Lung Carcinoma

Daniel Coutinho[1], Ana Oliveira[1], Sérgio Campainha[1], Sofia Neves[1], José Miranda[2], Antónia Furtado[3], David Tente[3], Agostinho Sanches[3], José Almeida[1], João Moura E Sá[1]

[1]Pulmonology, Centro Hospitalar de Vila Nova de Gaia/Espinho - Portugal
[2]Cardiothoracic Surgery, Centro Hospitalar de Vila Nova de Gaia/Espinho - Portugal
[3]Pathology, Centro Hospitalar de Vila Nova de Gaia/Espinho - Portugal

Introduction

Lung cancer staging has recently evolved to include endobronchial ultrasound- guided transbronchial needle aspiration (EBUS-TBNA) biopsies of the hilar and mediastinal lymph nodes, with good accuracy in expert centers.

Objective

The aim of our work was to determine the effectiveness of EBUS-TBNA as a key component of a staging algorithm for NSCLC.

Methods

Patients undergoing EBUS-TBNA for NSCLC staging at our institution between April 1, 2010 and December 31, 2014 were consecutively included with prospective data collection. EBUS-TBNA was performed under general anesthesia through a rigid scope. Rapid on-site evaluation was available in 97% of the procedures.

Results

A total of 123 patients, 83% males, median age 65. Histological type: 78 (63.4%) adenocarcinoma, 34 (27.6%) squamous cell carcinoma, 11 (8.9%) undifferentiated/other NSCLC. 437 nodes were punctured, median number of nodes per patient of 4. EBUS-TBNA nodal staging: 64 (52%) N0; 8 (6.5%) N1; 34 (27.6%) N2, and 17 (13.8%) N3. 16 N0/N1 and 1 N2 patients were submitted to mediastinoscopy – in all patients EBUS-TBNA findings were confirmed. 25 patients were submitted to curative intent surgery - N0/N1 status was confirmed in 22 patients, in 1 patient N2 undetected by EBUS, and in 2 patients N2 unreachable by EBUS or mediastinoscopy. No complications were attributable to the procedure.

Conclusions

A comprehensive lung cancer staging strategy that includes EBUS-TBNA seems to be safe and effective. In this study mediastinoscopy did not detect false negative nodes. More invasive surgical procedures (mediastinoscopy/resection surgery) were avoided in 49 patients with N2/N3 nodal staging, thus confirming the importance EBUS-TBNA in this setting.

id 24

Bronchoscopy Reduces Health-Care Utilization in ICU Patients with Central Airway Obstruction

Akash Verma[1], Wen Yuan Sim[2], Chee Kiang Phua[1], Benjamin Ho[1], Dessmon Tai[1], Soon Keng Goh[1], Ai Ching Kor[1], Sennen Lew[1], John Abisheganaden[1]

[1]Respiratory and Critical Care Medicine, Tan Tock Seng Hospital - Singapore
[2]Tan Tock Seng Hospital, Tan Tock Seng Hospital - Singapore

Introduction

Intensive care is a substantial financial burden on the US health care system, with spending on critical illness exceeding $80 billion per year, approximately 3% of all health care spending and nearly 1% of the gross domestic product. It has been reported that hospital stays that involve time in an intensive care unit (ICU) are 2.5 times more costly than other hospital stays, and the highest rate of ICU use (93.3 percent) is for respiratory disease with ventilator support.

Objective

To assess the effect of bronchoscopy on discontinuation of mechanical ventilation, Extubation, and reduced ICU resource utilization in our institution.

Methods

Retrospective review of medical records of all patients referred for bronchoscopic intervention for acute respiratory failure from malignant or benign central airway obstruction requiring ICU admission.

Results

Thirteen (5 females, and 8 males) critically ill patients, intubated and mechanically ventilated (n=11), or sufficiently ill to warrant close observation in High dependency unit prior to intervention (n=2) were referred for bronchoscopic therapy. Median (range) age was 63 (35-85) years. Eight (61.52%) had endotracheal tube inserted on an emergent basis to manage acute onset of respiratory failure, three (23%) had tracheostomy tube one of which was inserted on an emergent basis, and two (15.3%) although closely monitored, did not require airway intubation. Seven (63.6%) of 11 patients could be liberated from mechanical ventilation. This included 6 of 8 (75%) with endotracheal tubes and 1 of 3 (33.3%) with tracheostomy tubes. Eight (72.7%) of 11 intubated patients (8 with ETT, and 3 with tracheostomy tube), were successfully extubated. Nine (69.2%) of 13 patients admitted to ICU and High dependency, could be transferred to general ward after median (range) interval of 2 (1-7) days following the day of intervention. Physiologically, Median (range) pre-bronchoscopy and post-bronchoscopy PaO2 level was 51.4 (49.6-164) mmHg and 89 (64.8-190) mmHg respectively with significant improvement noted post-intervention (p=0.003). Radiologicaly, all 8 patients with lung atelectasis on presentation (100%), experienced complete re- expansion of the lung following bronchoscopic intervention.

Conclusions

Majority of patients in our cohort (more than 69%) could be promptly (within 2 days post-bronchoscopy) transferred out from ICU to general ward after successful discontinuation of mechanical ventilation and Extubation following bronchoscopic intervention. Bronchoscopic intervention reduces health-care utilization in patients who require ICU for central airway obstruction of benign or malignant aetiology. Correspondingly, it is advisable to recognize, refer, and perform the bronchoscopic intervention early in suitable patients.

Bibliography

1. Rebecca A et al. JAMA. 2014; 311(6):567-568. 2. Marguerite L. Barrett et al. Utilization of Intensive Care Services, 2011.

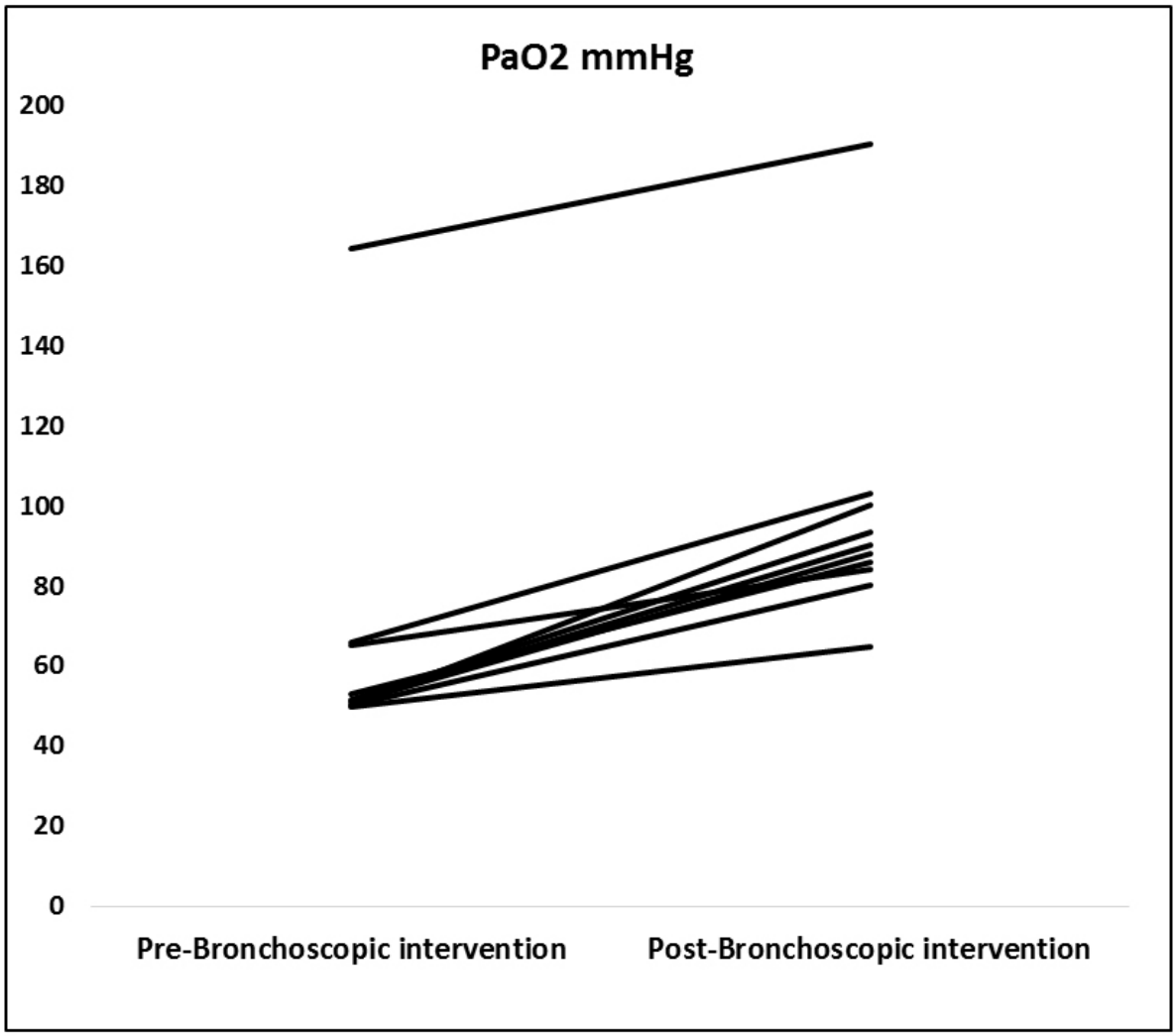
PaO2 mmHg
200
180
160
140
120
100
80
60
40
20
0
Pre-Bronchoscopic intervention
Post-Bronchoscopic intervention

id 25

19th WCBIP / WCBE World Congress
JOINT MEETING OF THE WORLD ASSOCIATION FOR BRONCHOLOGY AND INTERVENTIONAL PULMONOLOGY & THE INTERNATIONAL BRONCHOESOPHAGOLOGICAL SOCIETY
www.wcbipwcbe2016.org
Fortezza da Basso
May 8-11, 2016
Florence (Italy)

Self-expanding Metal Stent for Malignant Central Airway Obstruction in Singapore

Chee Kiang Phua, Wen Yuan Sim, John Abisheganaden, Qiu Mei Wu, Akash Verma

Respiratory and Critical Care Medicine, Tan Tock Seng Hospital - Singapore

Introduction

Interventional bronchoscopy with airway stenting provides immediate relief of dyspnoea, and resolves radiological and physiological changes in patients with malignant central airway obstruction. It confers clinical stability to allow definite treatment directed at the cancer to take place by reversing the life threatening respiratory failure. Survival benefit has also been described if the intervention is performed early.1

Objective

We studied the safety, effectiveness, limitations, and the effect on survival of the airway stenting using Self-expanding Metal Stent (SEMS) in patients with malignant central airway obstruction.

Methods

Retrospective review of records of patients undergoing stenting for malignant central airway obstruction during year 2014 was done.

Results

Fifteen patients (11 males and 4 females) underwent stenting in one year. Median (range) age was 66 (54-78) years. No perioperative or immediate post- operative complications were seen except acute myocardial infarction (AMI) in one patient. Three patients were transferred to intensive care unit (ICU) for closer monitoring after the procedure and were discharged the next day. All 4 patients with lung atelectasis on presentation experienced complete re- expansion of the lung post-stenting. The dyspnea was substantially relieved in 13 (86.6%) patients. Two of the three patients who had been intubated were weaned off from the ventilator following stent insertion. During follow-up, granulation tissue and tumor ingrowth were the most frequently encountered complications leading to the loss of long-term benefit. Median survival from the date of diagnosis and stent placement was 220 (54-514), and 86 (14-355) days respectively. The survival was unchanged from the expected survival based on the life expectancy of the underlying malignancy.

Conclusions

Airway stents confer clinical stability to patients by recanalization of un- resectable malignant central airway obstruction with low complication risk. This allows definite treatment directed at the cancer to take place. They also help to preserve the expected cancer related life expectancy by preventing patients from dying pre-maturely from respiratory failure associated with central airway obstruction (CAO). Major factor that impedes long-term benefit from re-canalization is the granulation tissue formation and tumor in-growth.

Bibliography

1. Razi SS etal. 2010 Oct 1088-93

	Expected Life expectancy (Median)	Actual life expectancy (survival) in days (Diagnosis to death time)	Stenting to death time in days
Lung cancer (n=8)	8 months (245 days)	257 (54-514)	93.5 (14-355)
1		74	58
2		220	178
3		362	355
4		54	14
5		347	331
6		514	101
7		89	86
8		294	23
Esophageal cancer (n=5)	9 months (270 days)	288 (80-419)	61 (60-171)
1		419	96
2		360	61
3		288	171
4		80	60
5		117	61
Anaplastic thyroid cancer (n=2)	3.8 months (114 days)	129 (71-187)	67 (16-118)
1		71	16
2		187	118
All (n=15)		220 (54-514)	86 (14-355)

id 26

A Novel Approach to complete Subglottic Stenosis

Michael Machuzak, Thomas Gildea, Sonali Sethi, Francisco Almeida

Respiratory Institute, Cleveland Clinic - Usa

Introduction

A complete subglottic or high tracheal stenosis is difficult for both patient and practitioner. Loss of phonation and secretion management adversely affects quality of life. The dense scar associated with a Cotton-Meyer IV obstruction is formidable. We present a novel approach to re-establish a patent airway allowing for phonation, improved mucus clearance and quality of life. Historically this stenosis is re-opened proximally. However, we have developed a retrograde approach that is reliable, safe and effective. This report will cover our initial experience reported in WCBIP 2012 as well as the continued success over the past 4 years.

Objective

To describe a novel approach that has been shown to be safe and effective in regaining a completely occluded subglottic, supra-stomal or high tracheal airway.

Methods

A rigid bronchoscope is inserted above the obstruction. The tracheostomy tube is removed and under apneic conditions a large gauge central line needle is used to penetrate the stricture and localize the lumen. The needle is directed in a retrograde, cephalad direction guided by the rigid scope. Once the needle has penetrated the stricture and can be seen in a central position a guide-wire is introduced in a retrograde fashion to maintain this tract. Serial dilations with a balloon and rigid scope are performed, often in concert with an endobronchial cutting device. Once a lumen is obtained sequential rigid dilations establish a pathway and begin to “train” the airway into a more normal size and shape. The sequential rigid dilation also allows for tamponade of bleeding and uninterrupted ventilation. A T-tube or subglottic stent is then placed.

Results

Retrograde recanalization was attempted in 11 patients and was successful in re-establishing patency in all. T-tube placement was successful in 9/11 on the initial procedure and in 2 one month later. Long term follow-up reveals two patients were decannulated. Two died due to co-morbidities. One patient was transitioned back to a tracheostomy due to continued smoking (our protocol prohibits smoking with a T-tube). Patency and phonation remains in all patients.

Conclusions

This technique requires continued evaluation but over 7 years has been a reliable, safe and effective alternative for a formidable problem. Our opinion does not differ from the common perception that a surgical reconstruction should be considered in every patient, but occasionally surgery is not an option. Retrograde recanalization is a novel technique previously unavailable that can significantly impact our patients’ health and quality of life.

id 27

Triple-tyrosine kinase inhibition attenuates airway remodeling in mice

Malarvizhi Gurusamy[1], Saeed Nasseri[1], Birgit Jung[2], Henri Doods[2], Dongmei Wu[1]

[1]Department of BIN Convergence Technology, Chonbuk National University - South Korea
[2]Department of Respiratory Diseases Research, Boehringer Ingelheim Pharma GmbH - Germany

Introduction

Airway remodeling is an important pathological feature of chronic asthma, which leads to a progress decline in lung function. Various growth factors contributing to airway remodeling process include platelet-derived growth factor (PDGF), vascular endothelial growth factor (VEGF), basic fibroblast growth factor (b-FGF), and transforming growth factor (TGF). These factors have been shown to affect proliferation of airway smooth muscle cell and fibroblast, extracellular matrix production, and promote airway inflammation, contributing in many processes of airway remodeling.

Objective

The present study examined the effects of BIBF100, a small molecule orally active triple-tyrosine kinase inhibitor that simultaneously targets VEGF, PDGF and FGF receptor signaling in an experimental model of chronic asthma-induced airway remodeling in mice.

Methods

Male Balb-c mice (8-10 week old) were randomly assigned into three study groups: 1) sham control, 2) OVA + vehicle, and 3) OVA +BIBF1000. Mice were immunized intraperitoneally on days 0 and 12 with 50µg ovalbumin plus 1mg of AL(OH)3 in 200ul saline. Intranasal OVA challenges (20 µg/50 µl in PBS) were administered on days 26, 29, and 31, and were repeated twice a week for 3 months. Animals received vehicle or BIBF1000 (25 mg/kg, b.i.d.) through gavage from day 26 to the end of fourth months. On day 120, bronchoalveolar lavage (BAL) was collected and analyzed for inflammatory cell influx. Lung tissues were analyzed for airway remodeling, degree of mucus plugging of goblet cells (PAS-Periodic Acid Schiff) and peribronchial collagen deposition.

Results

There was an excessive increase in total inflammatory influx into the lungs of OVA-challenged animals compared to sham control. However, the numbers of eosinophils, macrophages, neutrophils, and lymphocytes in the BAL were reduced by 70.0%, 57.9%, 47.5% and 63.0%, respectively, in mice treated with BIBF1000, compared to vehicle treated mice. Treatment with BIBF1000 reduced airway remodeling with a 48.3% reduction in airway wall thickness compared to vehicle treated animals. Furthermore, histological analysis with PAS and Masson's trichrome staining revealed marked reduction in the amount of mucus secretion of goblet cells and fibrosis of peribronchial areas in mice treated with BIBF1000, compared to vehicle treated mice (Figure 1). Treatment with BIBF1000 also reduced TNF-? (? by 24.0%) in plasma, cysteinyl leukotriene production (? by 16.7%) in BAL, and muc5AC content (? by 40.9%) in lung tissues.

Conclusions

Simultaneous inhibition of VEGF, PDGF and FGF receptor signaling with BIBF1000 represents an effective approach for the treatment of airway remodeling associated with chronic asthma.

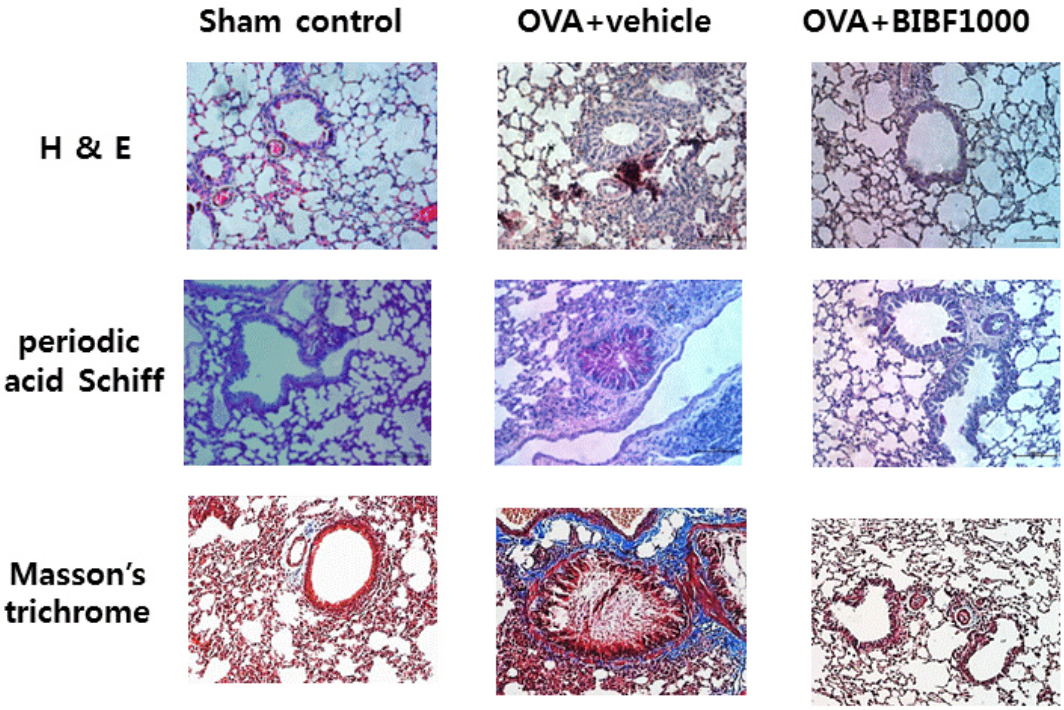

Figure 1. Representative staining of lung sections of each study group for haematoxylin and eosin, periodic acid Schiff, and masson's trichrome collagen staining in a mice model of OVA-induced chronic asthma.

id 28

Thoracoscopic pleurodesis using doxycycline poudrage in malignant pleural effusion

Ayman Baess[1], Eman Hatata[1], Rasha Daabis[1], Bassma Elsabaa[2], Inas Abd El-rahman[3]

[1]Chest, Faculty of medicine, University of Alexandria - Egypt
[2]Pathology, Faculty of medicine, University of Alexandria - Egypt
[3]Chest, University Students Hospital - Egypt

Introduction

Malignant pleural effusion (MPE) increases morbidity and mortality in patients with advanced malignancy. To the time being, thoracoscopic talc poudrage is the recommended palliative method but asbestos-free talc is unavailable in many countries including Egypt. Doxycycline oral forms are widely available, cheap and as effective as its parenteral forms in inducing pleurodesis.

Objective

To assess the efficacy, safety and outcome of thoracoscopic poudrage using oral forms of doxycycline in MPE.

Methods

We prospectively enrolled 30 patients with MPE in the period between March, 2013 and March, 2014. Medical thoracoscopic pleurodesis was performed using oral doxycyclines (Vibramycin 100 mg capsule, Pfizer). Patients were observed for 90 days after the procedure. Efficacy was judged both clinically and radiologically. Procedure-related complications were recorded.

Results

Patients were 20 males and 10 females. Mean age ±SD was 57.67 ± 13.29 years. The most common primary neoplasms were lung cancer and breast cancer (both, n =11).After 90 days, 19 out of 22 surviving patients (86.4%, 95%CI=59.8 – 94.8%) had successful pleurodesis. No procedure-related major complications were recorded. Minor adverse effects included pain (28.6%), fever (25%) and wound infection (10.7%). Survival rate at 90 days was 78.6%.Mean duration of hospitalization was 1.93 ± 0.92 days.

Conclusions

Thoracoscopic doxycycline poudrage is a safe and effective method of pleurodesis in recurrent MPEs

Bibliography

Bilaceroglu S, et al. Chest 2005; 128:3750-6

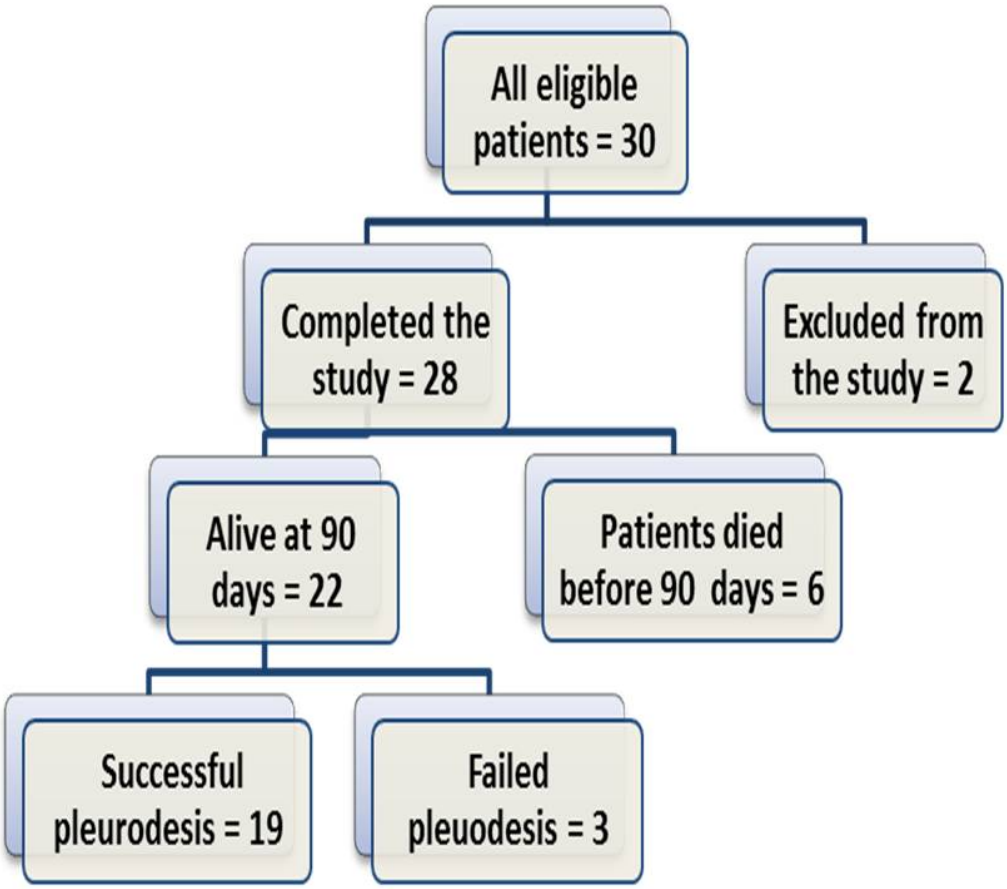
All eligible patients = 30
Completed the study = 28
Excluded from the study = 2
Alive at 90 days = 22
Patients died before 90 days = 6
Successful pleurodesis = 19
Failed pleuodesis = 3

id 29

The effect of Tiotropium on Human Bronchial Ciliary Movement Using Bronchoscopic Sample

Toshiyuki Sawa[1], Tsutomu Yoshida[2], Takashi Ishiguro[2], Akane Horiba[2], Yohei Futamura[2], Takaaki Hasegawa[3], Takashi Nakahari[4]

[1]Cancer Center, Gifu Municipal Hospital - Japan
[2]Respiratory Medicine and Oncology, Gifu Municipal Hospital - Japan
[3]Respiratory Medicine and Oncology, Gifu Municipal Hospital - Jaoan
[4]Molecular Cell Physiology, Kyoto Prefectural University of Medicine - Japan

Introduction

The Evaluation of medicine on mucocilliary function of individual patients is useful clinically because mucociliary transport (MCT) of airway is different in each individual or disease although MCT plays an important role as a defense mechanism in lower respiratory tract infection, In previous congress, We reported the newly developed simple method to evaluate patients bronchial mucoculliary movement using bronchoscopic sample. To evaluate the effect of Tiotropium, anticholinergic bronchodilator on human bronchial ciliary movement, the human bronchial ciliary movement and clinical applications was evaluated by our method using bronchoscope sample before and after inhalation of bronchodilators.

Objective

Ninety eight patients with respiratory disease were enrolled who had met the following eligibility criteria. 1) necessity of bronchoscopic biopy by the medical reason, 2) Adult and written informed consent, 3) tolerable organ function to perfume bronchoscopy.

Methods

When the bronchoscopy was performed in the patients with respiratory disease, bronchial lavage to the transbronchial biopsy site was examined to collect peripheral bronchial epithelial cells. After ciliary motion were observed to identify with microscopy, the cilliary beat were captured at 240 frames per second using a high-speed photographing function of the general-purpose digital video camera on the market. After inhalation of clinical dose of tiotropium, the cilliary beat were captured again. By software analysis, frequency and amplitude of the ciliary movement was measured.

Results

Human ciliary epithelium in the patients with respiratory disease was confirmed in the amplitude of 4 ~ 8?m and frequency of 5 ~ 20bps. It was observed that ciliary movement is activated by inhale bronchodilater (Tiotropium), from 6.4 to 8.3 beat per second as frequency, and from 6.0 to 6.7 micrometer as amplitude.

Conclusions

Even in general hospitals without specialized equipment, it is possible to observe easily and directly the movement of human airway ciliary epithelium using a bronchoscopic sample, to evaluate effect of medicine on the frequency of ciliary movement. It was suggested.that the anticholinergic bronchodilater may improve the ciliary movement in the clinical dose.

Effect of Ciliary Motion by Tiotropium

Frequency by Tiotropium

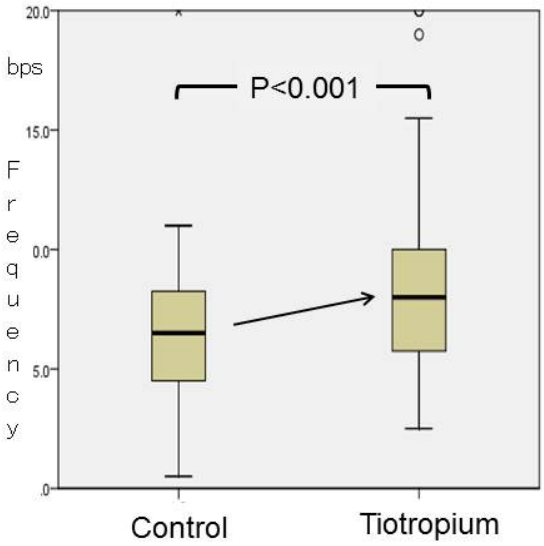

6.4±3.1bps 8.3±3.8bps

Amplitude by Tiotropium

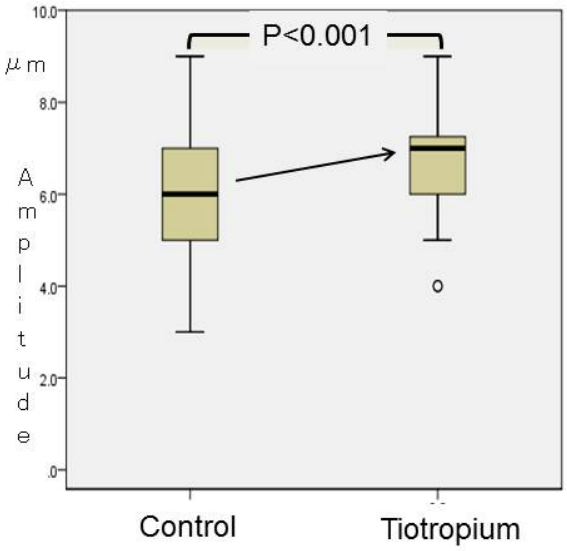

6.0±1.3μm 6.7±1.2μm

id 30

19th WCBIP / WCBE World Congress
JOINT MEETING OF THE WORLD ASSOCIATION FOR BRONCHOLOGY AND INTERVENTIONAL PULMONOLOGY & THE INTERNATIONAL BRONCHOESOPHAGOLOGICAL SOCIETY
www.wcbipwcbe2016.org
Fortezza da Basso
May 8-11, 2016
Florence (Italy)

Concurrent EBUS-TBNA & Conventional Bronchoscopy in Concomitant Peripheral and Mediastistinal Lesion

Kee San Goh, Akash Verma, Kuan Sen Tee, Huey Ying Lim, Albert Lim, John Abisheganaden

Respiratory and Critical Care Medicine, Tan Tock Seng Hospital - Singapore

Introduction

The diagnostic yield of various bronchoscopic techniques such as bronchoalveolar lavage, trans-bronchial biopsy, endobronchial biopsy, and endobronchial ultrasound guided trans-bronchial needle aspiration (EBUS-TBNA) vary.

Objective

To study the difference in the diagnostic yield between convex-probe EBUS- TBNA and bronchoalveolar lavage (BAL) with bronchial biopsy performed concurrently in patients with concomitant peripheral or endobronchial, and EBUS-TBNA amenable mediastinal lesions.

Methods

Retrospective review of records of 93 patients who underwent diagnostic bronchoscopy and EBUS-TBNA during 1st August 2014-31st July 2015.

Results

Forty nine out of 93 patients underwent convex probe EBUS-TBNA and conventional bronchoscopy concurrently for concomitant peripheral or endobronchial, and mediastinal lesion. Thirty seven (75.5%) were males. The median (range) age was 62 (33-80) years. After the combined diagnostic convex probe EBUS-TBNA and bronchoscopy, 34 patients were diagnosed with malignancy, tuberculosis (n=3), fungal infection (n=2), atypical cells (n=6) and 4 were undiagnosed. Diagnosis (benign or malignant) could be detected in greater number 33 (67.3%) of patients by convex probe EBUS-TBNA than BAL and bronchial biopsy which detected diagnosis in 22 (44.9%) of patients (p=0.04). Among patients undergoing bronchial biopsy of endobronchially visible lesion, the diagnosis detection rate was 13/24 (54%) vs. 33/49 (67.3%) with convex probe EBUS-TBNA (p=0.36). Two patients (4%) experienced airway bleeding after convex probe EBUS-TBNA whereas 10 (20.4%) experienced airway bleeding after endobronchial or trans-bronchial biopsy (p=0.02).

Conclusions

In patients with concomitant peripheral/endobronchial and mediastinal lesion undergoing convex probe EBUS-TBNA and conventional bronchoscopy (BAL with bronchial biopsy) concurrently, convex probe EBUS-TBNA provides a higher diagnosis detection rate than conventional bronchoscopy. The detection rate of bronchial biopsy of the endobronchially visible lesion is similar to the detection rate of convex probe EBUS-TBNA for the mediastinal lesion. However, since EBUS-TBNA confers added advantage of providing nodal stage information, and safety by avoiding bleeding into the airways associated with endobronchial or transbronchial biopsy, it should be preferred over the conventional bronchoscopy in patients with concomitant peripheral/endobronchial and mediastinal lesion. This may also help to shorten the procedure time.

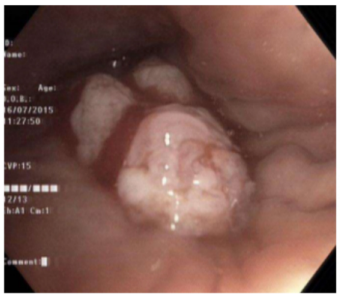
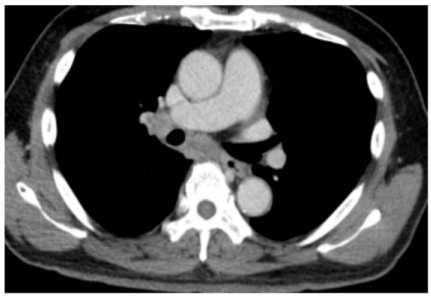
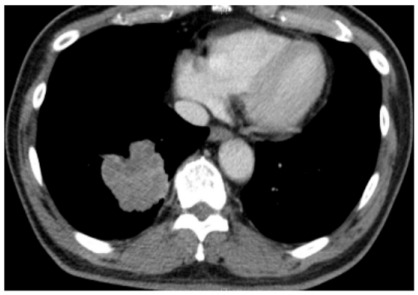

19th WCBIP / WCBE World Congress
JOINT MEETING OF THE WORLD ASSOCIATION FOR BRONCHOLOGY AND INTERVENTIONAL PULMONOLOGY & THE INTERNATIONAL BRONCHOESOPHAGOLOGICAL SOCIETY
www.wcbipwcbe2016.org
Fortezza da Basso
May 8-11, 2016
Florence (Italy)

Phonosurgical resection via the submucosal infusion; therapeutic method for laryngeal precancerosis

Takeyuki Kono[1], Koichiro Saito[2], Kaoru Ogawa[1]

[1]Otolaryngology Head and Neck Surgery, Keio University School of Medicine - Japan
[2]Otolaryngology Head and Neck Surgery, Kyorin University - Japan

Introduction

Laryngeal leukoplakia is a frequent pathology in the ENT clinic with diverse precancerous histopathology. However the management and follow-up policy for this pathology has not yet defined a gold standard. Submucosal infusion is a common phonomicrosurgical technique to hydrodissect epithelial basement membrane away from vocal ligament for less instrumental trauma of superficial lamina propria. Theoretically, when combined with microflap dissection, this phonomicrosurgical technique with complete lifting by mucoligamentous hydrodissection could offer histopathologically complete excision of the intraepithelial lesion.

Objective

The purpose of this study was to assess the feasibility of phonosurgical microflap dissection as a radical therapeutic and diagnostic option for precancerous laryngeal leukoplakia.

Methods

From Jan.2007 to March 2013, 25 patients with unilateral laryngeal leukoplakias were diagnosed with either severe dysplasia or CIS after phonomicrosurgical dissections. Fifteen patients preferred no additional surgery (observation group), while residual 10 patients preferred further laser subligamental cordectomy (additional surgery group). Relation between initial surgical margin and histopathology of additionally excised tissues were assessed to evaluate reliability of initial margin study as a diagnostic method. Recurrence rate of precancerous lesion and number of invasive transformation cases were also assessed. GRBAS scale, aerodynamic/acoustic parameters, and laryngeal videostroboscopic images were evaluated as the objective assessment of postoperative glottal function. Furthermore, V-RQOL and VHI were utilized for the subjective measurement of voice-related QOL. GRBAS scale and videostroboscopic findings were evaluated at multiple time points for the sequential assessment of their laryngeal function.

Results

After initial phonomicrosurgical resection, 3 residual dysplastic lesions were observed in near the vocal process and anterior commissure. In the observation group, 3 patients presented lesions suspicious for recurrence after the first procedure. No postoperative malignant transformation was observed in all the patients. While well-preserved vocal function was observed in the observation group as measured by GRBAS scale, deterioration of vocal quality appeared shortly after laser surgery in the additional resection group. Stroboscopic findings also proved relatively quick functional recovery of vocal cord structure in the observation group. Regarding acoustics, aerodynamics and QOL evaluations, statistically equivalent scores between the observation group and the control group were observed while the additional surgery group was inferior than the control group.

Conclusions

Phonomicrosurgical resection could be one of the therapeutic options with oncologic radicality against precancerous laryngeal leukoplakia. This radical management might further achieve satisfactory postoperative vocal function and voice-related QOL of the patients.

Bibliography

Zeitels S. Laryngoscope 1995; 105: 1-44 Weller MD, et al. Clin Otolaryngol 2010; 35: 364-372

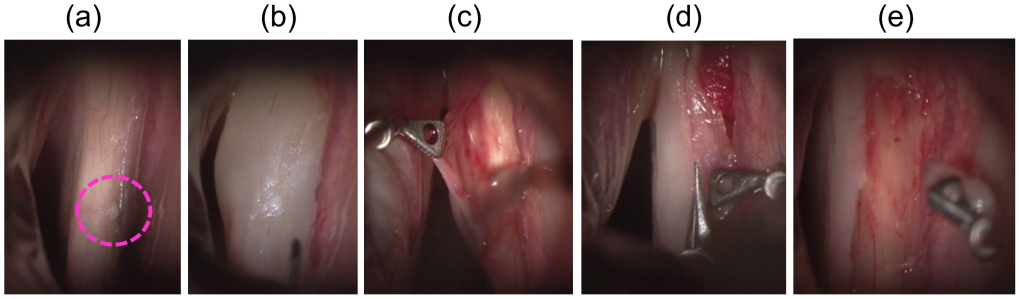

Fig1 Phonosurgical microflap resection of laryngeal leukoplakia via the submucosal infusion technique

In this patient, a leukoplakia lesion was observed in the upper surface of the right vocal fold (dotted circle) (a).
After submucosal saline infusion (b), phonosurgical microflap technique was used to dissect the intraepithelial pathology (c, d)
Well-preserved SLP and vocal ligament was observed after removal of the white lesion (e).

id 32

Efficacy of percutaneous small-bore catheters in the management of empyema thoracis

Maged Hassan, Ayman Saadany, Hatem Essam

Chest Diseases Department, Faculty of Medicine, Alexandria University - Egypt

Introduction

The size of chest drain is one of the unresolved issues in the management of empyema. Proponents of small drains argue they are less painful to insert and cause less complications while supporters of large drains find these more effective in draining thick pus. The most recent British Thoracic Society guidelines for pleural infections did not propose firm recommendations regarding this issue.

Objective

To propectively study the outcomes of using small-bore catheters in managing empyema.

Methods

The clinical outcome of patients receiving 12-14 F pigtail catheter insertion for drainage of frank empyema during the period November 2014 till April 2015 were observed. Thoracic ultrasound was used to exclude patients with complex- septated effusions and to guide the place of catheter insertion done by Seldinger technique.

Results

Sixteen patients were included in the study. Fourteen patients had pigtail insertion as the primary treatment. Two patients had the treatment after failure of medical thoracoscopy and chest tube to achieve complete drainage. Ten patients (63%) had right empyema and 9 (56%) were females. The mean (SD) age of patients was 40.2 (17.7) years. The median duration of catheter drainage was 6 days (minimum 2 and maximum 20 days). Twelve patients (75%) were ultimately cured with pigtail catheter. The remaining 4 patients were referred for decortication either due to recurrence after catheter removal (3 patients) or failure of lung re-expansion after pus drainage. Failure of drainage was not encountered in any of the cases. There was no statistical difference in the duration of tube drainage between the successful and failure cases. No complications were reported in case.

Conclusions

In addition to being less traumatic, and more suitable for loculated pleural collections, pigtail catheters seem effective in draining empyemas. Randomized controlled trials are needed to ascertain its efficacy in comparison to ordinary chest tubes.

Bibliography

Davies HE, Davies RJO, Davies CWH, on behalf of the BTS Pleural Disease Guideline Group. Management of pleural infection in adults: British Thoracic Society pleural disease guideline 2010. Thorax 2010;65:ii41–ii53.

19th WCBIP / WCBE World Congress
JOINT MEETING OF THE WORLD ASSOCIATION FOR BRONCHOLOGY AND INTERVENTIONAL PULMONOLOGY & THE INTERNATIONAL BRONCHOESOPHAGOLOGICAL SOCIETY
www.wcbipwcbe2016.org
Fortezza da Basso
May 8-11, 2016
Florence (Italy)

Larynx-sparing treatment based on induction chemotherapy and its response in hypopharyngeal cancer

Nobuhiro Hanai, Takuma Matoba, Hidenori Suzuki, Daisuke Nishikawa, Yujiro Fukuda, Yasuhisa Hasegawa

head and neck surgery, Aichi Cancer Center Hospital - Japan

Introduction

Although the NCCN guidelines recommended concurrent chemoradiotherapy (CRT) for larynx preservation as organ preservation treatment, the use of induction chemotherapy has also been described as an optional treatment strategy. This is additionally recommended by the ESMO guidelines. In this study, we therefore performed larynx-sparing treatment based on induction chemotherapy and evaluated its response over a long period of time.

Objective

The aim of this study was to investigate the outcome of hypopharyngeal cancer cases administered induction chemotherapy.

Methods

From January 2000 to December 2014, 225 cases that underwent induction chemotherapy out of all hypopharyngeal cancer patients treated at our hospital were included. A thrice weekly FP regimen (5-FU 800 mg/m2 days 1-5, CDDP 80 mg/m2 day 6, 2 courses) or weekly FP regimen (5-FU 1000 mg/m2 days 1- 2, CDDP 25 mg/m2 day 1, 6 courses) was carried out as induction chemotherapy. When the response to induction therapy was more than PR, radiation therapy (RT)/CRT was performed. In the cases less than SD, surgical treatment was performed.

Results

Two hundred and six males and 19 females were included. The mean age was 63 years (range: 36-82 years). There were 161 (72%) cases of Stage IV diseases. After induction chemotherapy, 78 patients (35%) were treated by surgery and 147 patients (65%) were treated by RT/CRT. The 5-year OS and DFS were 61.9% and 45.8%, respectively. The 5-year OS in the surgery group was 48.8% and in the radiation group was 68.1% (P = 0.06). The 5-year DFS in the surgery group was 36.1% and in the radiation group was 50.8% (P = 0.09).

Conclusions

Although the majority of cases have Stage IV diseases, induction chemotherapy shows an excellent outcome in that the 5-year OS rate is 61.9%. The cases that underwent surgery after induction chemotherapy tended to demonstrate a poor prognosis, because the response of induction chemotherapy were less than SD. On the other hand, the cases that underwent RT/CRT after induction chemotherapy instead showed a good prognosis. However, when comparing these two groups, not statically significant difference was observed in the survival curve. As a result, it is considered to be advantageous to select the treatment for such patients based on their response to induction therapy.

id 34

Bronchoscopic re-biopsy for mutational analysis of non-small cell lung cancer

Keisuke Kirita[1], Yuji Matsumoto[2], Yoshihisa Hiraishi[2], Takaaki Tsuchida[2], Takehiro Izumo[2]

[1]Division of Thoracic Oncology, National Cancer Center Hospital East - Japan
[2]Department of Endoscopy, Respiratory Endoscopy Division, National Cancer Center Hospital - Japan

Introduction

Currently, several acquired resistance mechanisms and rare driver oncogenes are identified in non- small cell lung cancer (NSCLC) relapses. Re-biopsy increases valuable information to guide treatment strategies, but the utility and feasibility of bronchoscopic re-biopsy has not been investigated.

Objective

The purposes of the present study were to determine the utility of bronchoscopic re-biopsy and to examine its accuracy, reasons for failure to obtain samples, and complications.

Methods

We studied 70 patients who underwent transbronchial biopsy including EBUS–GS and EBUS– TBNA for re-biopsy of NSCLC that was resistant to at least one regimen of chemotherapy or molecular targeted therapy between January 2013 and December 2014. We assessed clinical data, technical success rate, and mutational analysis.

Results

Procedures performed were transbronchial biopsy (n= 52) and endobronchial ultrasound-guided transbronchial needle aspiration (EBUS–TBNA) (n= 18). Median age was 63 yrs (range 35–85 yrs), with a preponderance of female patients (n= 41, 59%); 46 (61%) were never smokers or light smokers. Majority of the histological subtype was adenocarcinoma (n= 62, 89%); EGFR mutation was confirmed at initial diagnosis in 45 (64%) patients. The number of re-biopsy cases per year increased from 19 in 2013 to 61 in 2014. Overall detection rate of re-biopsy for malignant cells was 87% (83% for TBB and 100% for EBUS–TBNA). Mutational analysis was possible in almost all technically successful cases except in one. We investigated EGFR mutation in 37 de novo EGFR- mutated cases (exon 19 deletion in 23, L858R point mutation in 13, and L861Q point mutation in 1). Among these, 21 had T790M acquired mutation and 16 were negative. One initial EGFR- mutated tissue revealed SCLC transformation. Other driver mutations were seen in four cases, including ALK fusion gene (n= 2) and ROS1 fusion gene (n= 2). The procedures and pathological details of the nine cases from which adequate tissue could not be obtained were analyzed. In five cases, R–EBUS findings were “adjacent to” or “invisible”, factors that have been reported to cause difficult localization of target lesions. For target lesions that were easily reached (R–EBUS “within”), pathological diagnosis was atypical cells in four cases.There were no associated severe complications.

Conclusions

This study provides important information on the feasibility and safety of re-biopsy by bronchoscopy in patients with chemotherapy-resistant NSCLC. Its role in the development of novel treatment strategies for advanced NSCLC patients has potential.

19th WCBIP / WCBE World Congress
JOINT MEETING OF THE WORLD ASSOCIATION FOR BRONCHOLOGY AND INTERVENTIONAL PULMONOLOGY & THE INTERNATIONAL BRONCHOESOPHAGOLOGICAL SOCIETY
www.wcbipwcbe2016.org
Fortezza da Basso
May 8-11, 2016
Florence (Italy)

Modification of Mehta's Mucosal Sparing Technique for Treating Post-Intubation Tracheal Stenosis

Hafaruzi Harun[1], Mona Zaria Nasharudin[1], Mubarak Mohd Yusuf[2], Yusri Mohammed[2], Jamalul Azizi Abdul Rahaman[1]

[1]Pulmonology Division, Serdang Hospital - Malaysia
[2]Radiology Department, Serdang Hospital - Malaysia

Introduction

Post-intubation tracheal stenosis (PITS) occurs in 1-4% of ventilated patients. Management options are between endoscopic and open reconstructive procedures. Mucosal sparing technique are for web-like stenosis whereby radial incisions in the membranous stenosis are done followed by gentle dilatation. Bronchoscopic dilatation alone is associated with high risk of stenosis recurrence due to excessive excessive granulation tissue formation and scar contracture. Mitomycin-C (MMC) is anti-fibroblastic agent that modulate wound healing and scarring which may improve the success rate and reduce the need for frequent procedures in PITS

Objective

The Results of Modification of this technique by the incorporation of topical Mitomycin application after bronchoscopic balloon dilatation is illustrated by the case series on 2 patients.

Methods

First patient is a 14 years old teenager developed PITS, 2 months post-prolonged intubation due to road traffic accident (RTA). His symptoms were stridor, chronic cough and reduced effort tolerance. CT Thorax showed short segment tracheal stenosis, 3 cm below vocal cord with circumferential mucosal thickening. Bronchoscopic balloon dilatation was done via rigid tube under general anaesthesia. Tracheal lumen pre- dilatation was 6mm. Post-dilatation lumen was 16mm. Topical MMC (dose of 0.2mg/ml) was applied on the dilated stenotic segment using rigid forceps via rigid tube. Monthly surveillance bronchoscopy for 9 months showed no stenosis recurrence with symptomatic improvement. Serial spirometry also showed improvement. The second patient is a man aged 22 with PITS after 2 weeks of intubation due to stab injury to chest with hemopneumothorax. His symptoms were also similar. Spirometry pre-intervention showed fixed airway obstruction pattern. CT thorax showed short segment tracheal stenosis at C7/T1, 0.5cm wide, 4cm distal to vocal cord. Bronchoscopy showed weblike tracheal stenosis. Pre-dilatation tracheal lumen was 6mm. Radial Incision was made before Bronchoscopic balloon dilatation was done and Post-dilatation lumen was 14mm. Topical MMC at higher dose (0.4mg/ml) was applied. Monthly bronchoscopy showed no stenosis recurrence with symptomatic improvement in tandem with serial spirometry improvement.

Results

Serial Bronchoscopy on these 2 patients showed no stenosis recurrence with sustained improvement in lumen diameter Serial Spirometry showed normalisation of the flow volume loop with normalisation of FEV1 values in tandem with symptomatic improvement

Conclusions

Modification of the Mucosal Sparing Technique by incorporation of Topical MMC application following Bronchoscopic Balloon Dilatation showed good results as adjuvant therapy in selected PITS patients with early stenosis responding better than mature fibrotic stenosis obviating the need for tracheal sleeve resection surgery.

19th WCBIP / WCBE World Congress
JOINT MEETING OF THE WORLD ASSOCIATION FOR BRONCHOLOGY AND INTERVENTIONAL PULMONOLOGY & THE INTERNATIONAL BRONCHOESOPHAGOLOGICAL SOCIETY
www.wcbipwcbe2016.org
Fortezza da Basso
May 8-11, 2016
Florence (Italy)

Analysis of the lifetime of voice prostheses

Takuma Matoba, Nobuhiro Hanai, Daisuke Nishikawa, Hidenori Suzuki, Yujiro Fukuda, Yusuke Koide, Yasuhisa Hasegawa

head and neck surgery, Aichi Cancer Center Hospital - Japan

Introduction

From 1980s, the indwelling concept of voice restoration became the gold standard of tracheoesophageal voice restoration in industrial nations as it allows supplying also older and less skilful patients with voice prosthesis. Disadvantages of the indwelling concept are the need for a physician to change the voice prostheses. Due to patient comfort, safety and economical aspects, in the past years, several voice prostheses with additional features intended to prolong device life have become available.

Objective

Since device life is an important factor in clinical and economical decision making, the aim of this study was to investigate the device life and analyzed the factors that influence on the device life time.

Methods

We retrospectively reviewed the lifetime of indwelling voice prostheses (Groningen® voice prosthesis, Povox®2) used in 33 outpatients, and analyzed influences of the type of prostheses, surgical procedure and irradiation on device lifetime.

Results

We replaced 771 prostheses, and the median device lifetime was 91 days. Surgical procedure (TE shunt or TJ shunt) was significantly associated with the device lifetime (p=0.003). Groningen® voice prostheses tended to have longer device lifetime compared to Provox®2 (p=0.059). There were no significant differences in device lifetime between the patients with or without radiation therapy (p=0.466).

Conclusions

Results of this analysis gives yardstick of the interval of replacement depends on each situation. However, further examination is necessary about methods to reduce unplanned replacement.

id 37

19th WCBIP / WCBE World Congress
JOINT MEETING OF THE WORLD ASSOCIATION FOR BRONCHOLOGY AND INTERVENTIONAL PULMONOLOGY & THE INTERNATIONAL BRONCHOESOPHAGOLOGICAL SOCIETY
www.wcbipwcbe2016.org
Fortezza da Basso
May 8-11, 2016
Florence (Italy)

Metalic stent placement in central airway obstruction without using flouroscopy or guidewires

Cengiz Özdemir[1], Sinem Nedime Sökücü[1], Levent Karasulu[1], Seda Tural Önür[1], Levent Dalar[2]

[1]Pulmonology, Yedikule Chest Disease and Chest Surgery Training and Education Hospital - Turkey
[2]Pulmonology, Bilim University - Turkey

Introduction

Self expandable metallic stents (SEMS) can be used in the treatment of malign central airway obstructions. There are different methods of SEMS placement. SEMS were type of stents used in central airway stenosis with the guideness of either fluoroscopy, which leads to significant radiation exposure for patients and staff, or guidewires which increases the cost (1) Recently a technique was defined for stent placement through rigid bronchoscope without using fluoroscopy (2).

Objective

We retrospectively evaluated our patients for which SEMS were applied through rigid broncoscopy with the help of fiberoptic bronchoscope but without guidewire or fluoroscopy guideness to show the effectiveness and intraprocedure and post procedure complications of this method.

Methods

Data between January 2014 to July 2015 were retrospectively evaluated. Ethical committee approval was taken from the hospital.

Results

Mean age of the patients were 58.4 (44-77)and 13 of them were male. From the 15 patients included 13 of them have lung cancer, 1 thyroid papillary carcinoma with bronchomediastinal fistula, and 1 is eosophageal carcinoma with tracheoeosophageal fistula. For all of the patients except one (full covered tracheal metallic stent), different sizes of covered metallic Y stents were placed. Before stent placement, argon plasma coagulation was used in 2, diode laser was used in 4, and desobstruction was done in 9 of the patients. No procedure related mortality was observed. Only 2 of the patients were followed up in the intensive care unit after the procedure and then both of them were taken in to board after 2 days. None of the patients need stent replacement or repositioning. Most frequent early complications was mucus plugging.

Conclusions

Our study showed that endobronchial placement of covered self-expandable metallic stents was safe and easily performed in patients with airway obstruction without flouroscopy and guidewire guidence. This saves radiation exposure to patients and to staff and also decrease the cost of guidewires so lead to a more cost-effective procedure.

Bibliography

1-Herth F, et al. Chest. 2001 Jun;119(6):1910-2. 2-Husain SA, et al. Ann Thorac Surg. 2007 Apr;83(4):1251-6.

Exposure to Mycobacterium tuberculosis during bronchoscopy in patients with unexpected tuberculosis

Jung Seop Eom[1], Geewon Lee[2], Jeong Ha Mok[1], Min Ki Lee[1]

[1]Department of Internal Medicine, Pusan National University School of Medicine - South Korea
[2]Department of Radiology, Pusan National University School of Medicine - South Korea

Introduction

Recent guidelines recommend the use by healthcare personnel of a fit-tested N95 particulate respirator or higher-grade respiratory precaution when pulmonary tuberculosis (PTB) is suspected in a patient undergoing bronchoscopy. However, Mycobacterium tuberculosis (MTB) infection may be unsuspected in this setting and therefore not evaluated, resulting in the unexpected exposure to MTB by healthcare workers in the bronchoscopy suite.

Objective

We examined the incidence of unexpected exposure to MTB during flexible bronchoscopy and determined the exposure-related factors.

Methods

Between 2011 and 2013, a retrospective study was conducted based on 1650 patients who underwent flexible bronchoscopy for the evaluation of suspicious respiratory disease other than PTB. The results of bronchial washing, bronchoalveolar lavage, and post- bronchoscopic sputum were reviewed.

Results

PTB was unexpectedly diagnosed in 76 patients (4.6%). The presence of anthracofibrosis [odds ratio (OR), 3.878; 95% confidence interval (CI), 1.291–11.650; P = 0.016)], bronchiectasis (OR, 1.974; 95% CI, 1.095–3.557; P = 0.024), or atelectasis (OR, 1.740; 95% CI, 1.010–2.903; P = 0.046) as seen on chest CT scan was independently associated with unexpected PTB. Patients with both anthracofibrosis and atelectasis were at much higher risk of unexpected PTB (OR, 4.606; 95% CI, 1.383–15.342; P = 0.013).

Conclusions

The risk of MTB exposure by healthcare personnel in the bronchoscopy suite due to patients with undiagnosed PTB has been underestimated. Therefore, higher-grade respiratory precaution, such as a fit-tested N95 particulate respirator, should be considered in the bronchoscopic evaluation of patients with CT-confirmed anthracofibrosis, bronchiectasis, or atelectasis.

19th WCBIP / WCBE World Congress
JOINT MEETING OF THE WORLD ASSOCIATION FOR BRONCHOLOGY AND INTERVENTIONAL PULMONOLOGY & THE INTERNATIONAL BRONCHOESOPHAGOLOGICAL SOCIETY
www.wcbipwcbe2016.org
Fortezza da Basso
May 8-11, 2016
Florence (Italy)

Animal Studies about The Inhibition Function of Paclitaxel Drug-eluting Stent on Trachea-restenosis

Ting Wang, Jie Zhang, Juan Wang, Ying-hua Pei, Xiao-jian Qiu, Yu-ling Wang

Department of Respiratory, Beijing Tiantan Hospital, Capital Medical University - China

Introduction

Benign tracheal stenosis is not uncommon in clinical. For long segment benign tracheal stenosis with collapse, tracheal stent placement through bronchoscopy is the only treatment method. But regardless of metal stents or silicone stents, granulation proliferation is the main complication, which lead to restenosis and affect long-term efficacy. Drug-eluting stent is a method which to solve this problem. Our previous experiments in vitro found that paclitaxel-eluting stents can make paclitaxel (an anti-proliferative drug) locally and slowly release in trachea [1], thereby inhibiting the fibroblast proliferation after tracheal mucosa injury and reducing granulation tissue proliferation. But it has not yet to confirm its efficacy and safety in vivo.

Objective

In this study, paclitaxel drug-eluting stents were placed into dog's trachea. Their inhibition efficacy on tracheal granulation tissue and their safety in vivo were observed. The release of coating drug and its pharmacokinetics in animal were analyzed.

Methods

Six beagles were used and they were randomly divided into a control group (bare-metal stent group) and an experimental group (paclitaxel-eluting stent group). Each group has 3 animals respectively. Bare-metal stents and paclitaxel-eluting stents were placed into two groups respectively, and the observation period is 5 months. Proliferation of granulation tissue and changes of tracheal mucosa between two groups were compared. At different observing time, the paclitaxel-eluting stents were removed. Coating drugs were eluted to evaluate the drug release. Drug concentrations in serum, trachea and its surrounding tissues were measured to evaluate the safety of paclitaxel-eluting stent.

Results

Compared with the control group, the degree of granulation tissue proliferation in experimental group was significantly reduced. Most of the stent surface was epithelialization and has coverage of normal cilia. The drug release of paclitaxel-eluting stent was fastest in the first month after placement, which is up to 70.85%. Then the release slowed down gradually. To the fifth months, the release reach to 98.46%. During the observation period, paclitaxel concentration in animal serum, tracheal and lung are all within the safe range, and gradually reduce with time. No related complications occur.

Conclusions

Paclitaxel-eluting stent can effectively inhibit the proliferation of granulation tissue after stent implantation, reducing the formation of restenosis, and it is safe in vivo.

Bibliography

Yingying Kong, et al. Chinese Medical Journal; 2014; 127:2236-2240

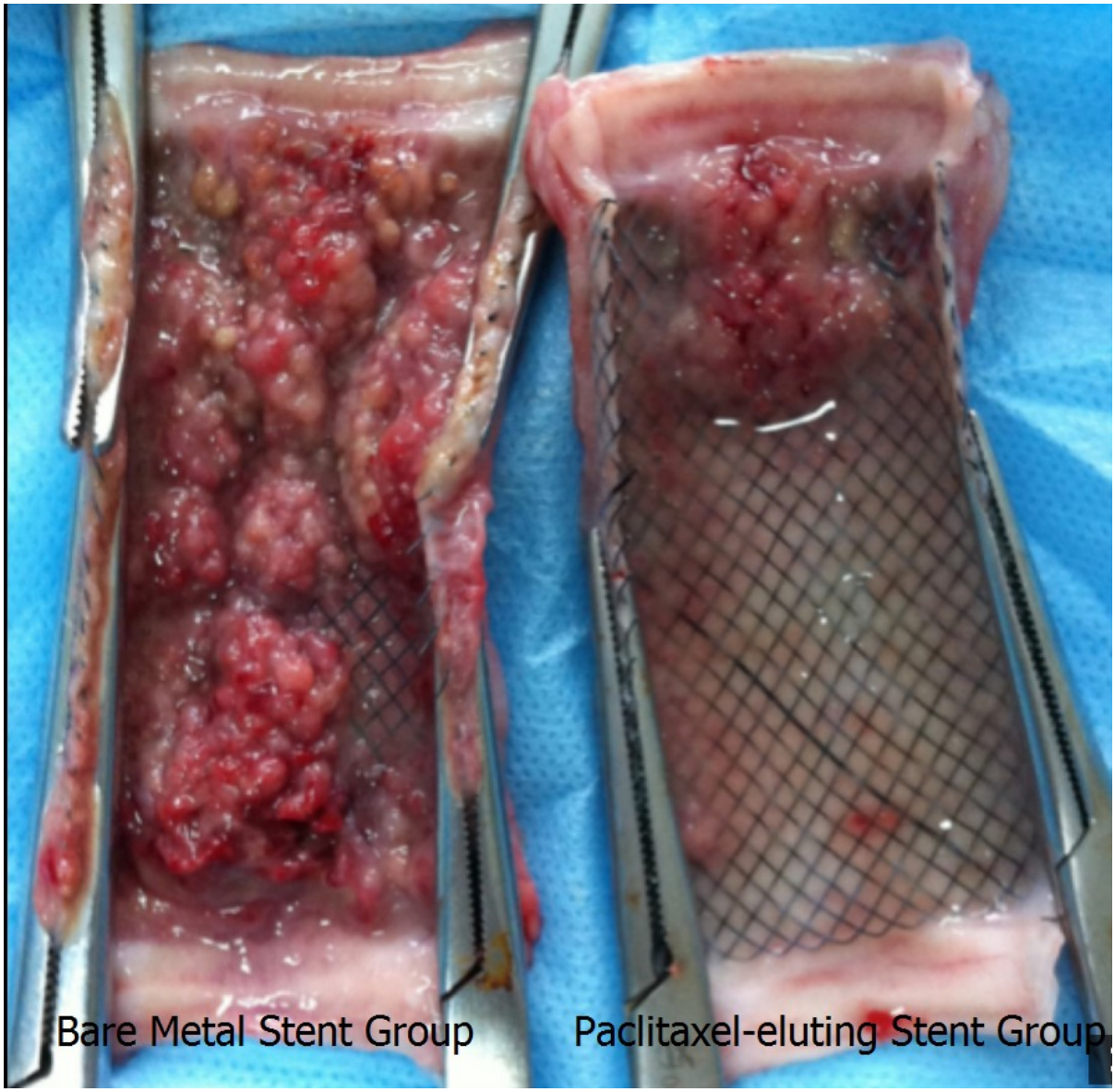

The presenting author has the following conflicts of interest that relate to this abstract: *This study is supported by the Fund of Clinical Technical Innovation Project from Beijing Hospital Authority (NO. XMLX 201314).*

id 40

19th WCBIP / WCBE World Congress
JOINT MEETING OF THE WORLD ASSOCIATION FOR BRONCHOLOGY AND INTERVENTIONAL PULMONOLOGY & THE INTERNATIONAL BRONCHOESOPHAGOLOGICAL SOCIETY
www.wcbipwcbe2016.org
Fortezza da Basso
May 8-11, 2016
Florence (Italy)

Importance of Selection of Diameter for Self-Expanding Airway Stent: An Animal Experiment

Ting Wang, Jie Zhang, Juan Wang, Ying-hua Pei, Xiao-jian Qiu, Yu-ling Wang

Department of Respiratory, Beijing Tian Tan Hospital, Capital Medical University - China

Introduction

With the advancement in therapeutical bronchoscopy, the use of self-expanding metal stents has been increasingly seen, especially for the treatment of malignant airway stenosis. However, there is a lack of universal standard for the selection of self-expanding airway stents. Most interventional physicians make choices according to their experiments and habits. The selection of diameter for self-expanding airway stents challenges interventional physicians.

Objective

Animal experiment are presented in this paper, in order to provide useful information that allows for a more reasonable choice for self-expanding airway stents.

Methods

In this experiment, four healthy beagles with similar weight and size were chosen. Chest CT scan was performed and the diameters of animals' middle trachea were determined according to the following formula: trachea diameter = (Anteroposterior diameter + transverse diameter)/2. Then beagles were divided into four groups (16, 18, 20 and 22mm stent group, respectively). Self-expanding uncovered metal stents of different diameters (16, 18, 20 and 22mm, respectively) were placed in the trachea of these beagles for 3 months and their impacts on normal trachea were investigated.

Results

About the diameters of trachea, no statistical differences were seen among four groups. As the stent diameter increasing (the stent-to-airway diameter ratio was 103%?116% and 129% in the 16mm stent group,18mm stent group and 20mm stent group, respectively), the proliferation of tracheal granulation tissues increase. However, if the stent-to-airway diameter ratio beyond certain ranges (22mm stent group, stent-to-airway diameter ratio was 142%), the proliferation of tracheal granulation tissues decrease, but damages caused by mechanical expansion force on the trachea aggravate, and complications (such as tracheal perforation) may occur.

Conclusions

For patients with tracheal stenosis, self-expanding metal stent should be placed with great caution. Where necessary, full consideration should be given according patient's tracheal diameter, and stents of inappropriate diameters should be avoided.

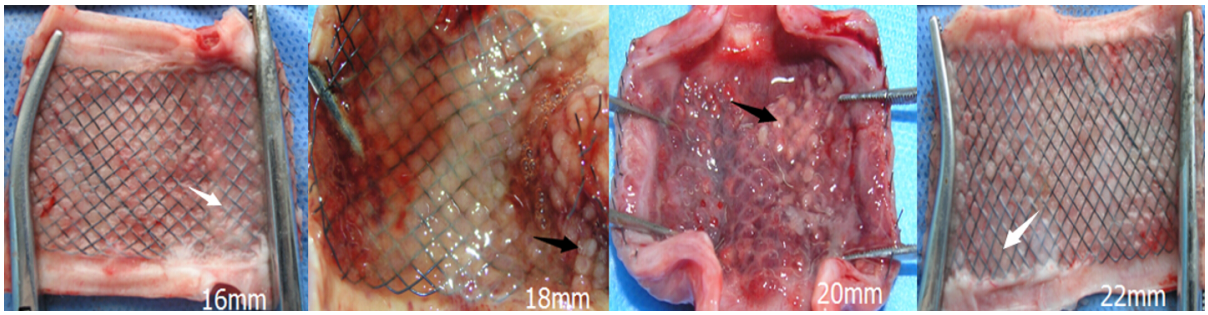

The presenting author has the following conflicts of interest that relate to this abstract: *This study is supported by the Fund of Clinical Technical Innovation Project from Beijing Hospital Authority (NO. XMLX 201314).*

Aspirin Use and the Risk of Bleeding Complications after Therapeutic Bronchoscopy

Kassem Harris[1], Jad Kebbe[2], Kush Modi[2], Abdul Hamid Alraiyes[1], Abhishek Kumar[2], Kristopher Attwood[3], Samjot Singh Dhillon[1]

[1]Medicine, Roswell Park Cancer Institute, University at Buffalo, State University of New York - Usa
[2]Department of medicine, Division of Pulmonary, Critical Care and Sleep Medicine, University at Buffalo, State University of New York - Usa
[3]Department of Biostatistics and Bioinformatics, Roswell Park Cancer Institute - Usa

Introduction

Aspirin is considered safe for patients undergoing certain diagnostic bronchoscopy procedures such as transbronchial biopsies and endobronchial ultrasound guided transbronchial needle aspiration. However, there are no reports on the safety of aspirin in patients undergoing therapeutic bronchoscopy.

Objective

The aim of this study is to evaluate whether aspirin increases the risk of bleeding following therapeutic bronchoscopy.

Methods

This was a retrospective study to determine if there was higher bleeding risk associated with the use of aspirin in patients undergoing therapeutic bronchoscopy while they were on aspirin as compared to those not on aspirin. Patient characteristics were reported by cohort using the mean, median, and standard deviation for continuous variables; and using frequencies and relative frequencies for categorical variables.

Results

108 patients were included in the analysis, 17 (15.7%) had multimodality therapeutic bronchoscopy while on aspirin and 91 (84.3%) had therapeutic bronchoscopy off of aspirin. Patients in the aspirin group were older than those in the no-aspirin group (median age: 66 vs 60 years, p=0.007). The treatment modalities were similar in both groups except that more patients in the no-aspirin group were treated with argon plasma coagulation (APC) compared to the aspirin group (60.4% vs 29.4%, p=0.031). The estimated blood loss (EBL) between the aspirin and no- aspirin groups was not significantly different (mean: 6.0 vs 6.7ml; median: 5.0 vs 5.0, p= 0.36). Overall, there was no difference in complications between both groups.

Conclusions

In our study, aspirin was not associated with increased risk of bleeding or procedure complications after therapeutic bronchoscopy.

Bibliography

1. Aspirin does not increase bleeding complications after transbronchial biopsy. Chest. 2002;122(4):1461-1464. 2. Effect of routine clopidogrel use on bleeding complications after transbronchial biopsy in humans. Chest. 2006;129(3):734-737.

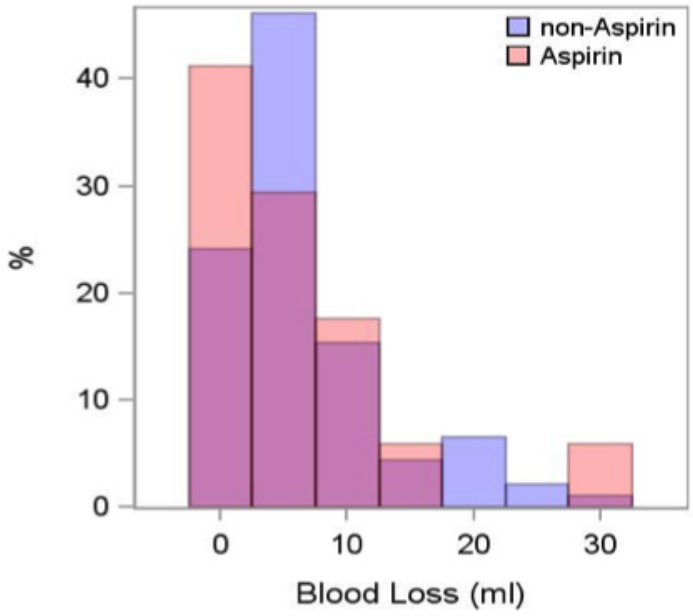

Aspirin mean EBL (SE)	No Aspirin mean EBL (SE)	Mean difference (95% CI)	P-value
6.7 (1.7)	6.4 (0.8)	0.3 (-3.2, 3.8)	0.582

The presenting author has the following conflicts of interest that relate to this abstract: *Consultant for Cook Medical.*

id 42

Is there a place remaining for TBNA?

Gorbatai Bogdan[1], Homsi Toifik[2], Auliac Jean Bernard[1]

[1]Pneumologie, CH Francois Quesnay - France
[2]Anatomopathology, CH Francois Quesnay - France

Introduction

We report our experience using blind TBNA.

Objective

We started using TBNA in our center in january 2010, and till now 300 patients had this procedure.

Methods

Most frequently punctured areas were LN station 7 followed by bulky LN station 4R and 4L. We started with a cytology (22 or 21 gauge) needle and actually we utilize histology (19 gauge) needle. We try to obtain at least 4 adequate TBNA samples/station. In accord with our pathologist we smear the specimen from the needle directly in alcoholic solution. We don't use ROSE.

Results

No major complications occur. The diagnosis was easy in neuroendocrine lung cancer; the accuracy of sarcoidosis was 65%; for the adenocarcinoma we could proceed AGFR and ALK mutation; one case of mantle lymphoma.

Conclusions

I think this method is an underused diagnostic modality with a good efficacy and safety; it is cheaper than EBUS and it would be realized in routine bronchoscopy.

id 43

19th WCBIP / WCBE World Congress
JOINT MEETING OF THE WORLD ASSOCIATION FOR BRONCHOLOGY AND INTERVENTIONAL PULMONOLOGY & THE INTERNATIONAL BRONCHOESOPHAGOLOGICAL SOCIETY
www.wcbipwcbe2016.org
Fortezza da Basso
May 8-11, 2016
Florence (Italy)

Bronchoscopic Transparenchymal Approach to Lung Nodules

Daniel Nader, Kendal Hervert

Pulmonary Division, Cancer Treatment Centers of America - Usa

Introduction

There are several bronchoscopic approaches to the diagnosis of solitary pulmonary nodules (SPN). Each has limitations in diagnostic accuracy. This report describes a single arm study of a bronchoscopic transparenchymal approach to the biopsy of lung nodules.

Objective

Report of novel bronchoscopic approach to biopsy of lung nodules utilizing a a transparenchymal approach via the airway.

Methods

SPN 8- 30 mm and at least 10 mm from the pleura, without endobronchial involvement are included in this study. Chest CT scan was imported into the Archimedes Virtual Bronchoscopy Navigation System, (Broncus Medical, San Jose, CA). CT data is reconstructed into a 3D model, which includes airways, vasculature, ribs and lungs. The target lesion is marked and the system calculates an endobronchial "point of entry" (POE) and a vasculature free path to the target lesion. The POE and path can be user modified. The Archimedes System integrates real time fluoroscopic data with 3D CT data to assist guidance of a sheath catheter from the POE to the target. Airway puncture at the POE allows the sheath catheter to be advanced thru the airway wall into lung parenchyma using fluoroscopy in 3 planes to guide advancement. At the target site, the sheath stylus is removed and 2 mm biopsy tools are employed to sample tissue.

Results

4 patients had successful navigation to the target with histologic specimens obtained. 3 patients were enrolled in the study but terminated early.

Conclusions

Bronchoscopic transparenchymal approach to the diagnosis of lung nodules is a promising approach to obtaining tissue for histologic diagnosis and ample tissue for genomic studies.

id 44

19th WCBIP / WCBE World Congress
JOINT MEETING OF THE WORLD ASSOCIATION FOR BRONCHOLOGY AND INTERVENTIONAL PULMONOLOGY & THE INTERNATIONAL BRONCHOESOPHAGOLOGICAL SOCIETY
www.wcbipwcbe2016.org
Fortezza da Basso
May 8-11, 2016
Florence (Italy)

Primary culture of cancer cells and chemosensitivity testing using samples obtained by EBUS-TBNA

Takahiro Nakajima[1], Terunaga Inage[1], Yuji Tada[2], Isao Miyagawa[3], Hisayuki Kobayashi[3], Hiroyuki Asano[3], Fumie Saegusa[4], Taiki Fujiwara[1], Hironobu Wada[1], Hidemi Suzuki[1], Takekazu Iwata[1], Shigetoshi Yoshida[1], Yuichi Takiguchi[5], Koichiro Tatsumi[2], Ichiro Yoshino[1]

[1]Department of General Thoracic Surgery, Chiba University Graduate School of Medicine - Japan
[2]Department of Respiratory Medicine, Chiba University Graduate School of Medicine - Japan
[3]Technical Research Laboratory, KURABO INDUSTRIES LTD. - Japan
[4]Department of Pathology, Chiba University Hospital - Japan
[5]Department of Medical Oncology, Chiba University Graduate School of Medicine - Japan

Introduction

Although molecular target therapeutic agents have dramatically changed the strategy of chemotherapy for lung cancer, cytotoxic chemotherapy is still one of the gold standard treatments. The chemosensitivity test using the CD-DST method has been developed and performed using surgically resected materials. The results were used for the selection of chemotherapy regimen; however, this can be done only for the patients after thoracotomy. Hence the novel technique which can be applied for the inoperable patients is warranted.

Objective

The aim of this study was to examine the feasibility of establishing primary tumor cell culture using the samples obtained by EBUS-TBNA. In addition, in the case of primary culture success, chemosensitivity testing using CD-DST method was also performed and compared with the clinical outcomes.

Methods

Patients who underwent EBUS-TBNA for the diagnosis of lung cancer were candidates for this study. The patients who required nodal staging were excluded. Written consent was obtained prior to EBUS-TBNA. We performed rapid on-site cytology for all cases. If we obtained enough sample for pathological diagnosis as well as molecular testing with 1-2 passes, we asked the patients for an additional three passes for the culture of tumor cells. The sample for the primary culture was stored at 4? in the cell preservative solution. Primary cell culture was done using the commercially available kit (Primaster, Kurabo, Japan) and the chemosensitivity test using CD-DST method was used following the standard instructions.

Results

16 cases were enrolled and underwent EBUS-TBNA for the targeted lesion including 12 mediastinal nodes, 2 hilar nodes, and 2 lung tumors. The mean short axis of targeted lesion was 15.6 mm (range 8.1-36.0 mm). The histology showed 13 cases of adenocarcinoma, 2 cases of squamous cell carcinoma and one case of small cell carcinoma. We could obtain 33.4x10E4 tumor cells on average. Pre-conditioning culture was successful in 14 cases and eventually 12 out of 16 cases (75%) could achieve primary tumor cell culture. The reason for unsuccessful cases were 2 cases having a small number of tumor cells, one case of tumor cell detachment from collagen gel and one case of fungal contamination.

Conclusions

Primary tumor cell culture using the Primaster kit with the samples obtained by EBUS-TBNA was feasible and the success rate was similar to the previous report which used surgically resected materials. The chemosensitivity testing using EBUS-TBNA samples may be beneficial for the patients who require cytotoxic chemotherapy.

Bibliography

Higashiyama M et al. Lung Cancer 2010; 68: 472–477

The presenting author has the following conflicts of interest that relate to this abstract: *This study was done under the collaboration with KURABO INDUSTRIES LTD. (P.I. Takahiro Nakajima). Takahiro Nakajima received honoraria and lecture fee for the seminar and hands-on training course of EBUS-TBNA from Olympus Medical Systems.*

Holter ECG Monitoring of Sympathovagal Fluctuation During Bronchoscopy

Abdellah Hamed Khalil Ali[1], Kazuya Kondo[2]

[1]Respiratory, Sohag university - Egypt
[2]Thoracic surgery, Tokushima university - Japan

Introduction

The changes of autonomic nervous activity during bronchoscopic procedures are closely related to the development of cardiovascular complications.

Objective

We aimed to evaluate the changes of autonomic nervous activity during bronchoscopic procedures using R-R interval variability from electrocardiograms obtained during diagnostic bronchoscopy.

Methods

Twenty-four patients who underwent bronchoscopy were included. Continuous electrocardiogram was recorded prior to, during, and after the bronchoscopic procedure. Time- and frequency-domain analyses of Heart rate variability (HRV) were performed. Heart rate increased significantly after premedication compared with that before premedication and increased further during endoscopy

Results

The CVRR values after premedication and during endoscopy were significantly higher than those before premedication (P , 0.031 and P , 0.041, respectively). LF power decreased during bronchoscopy. LF powers obtained after endoscopy were significantly lower than those obtained before endoscopy (P < 0.041). The HF power was found to be decreased during bronchoscopy. In particular, HF powers obtained after endoscopy (were significantly lower than those obtained before endoscopy (P < 0.019). Although the LF/HF ratios increased after premedication, they decreased temporarily during the endoscope insertion.

Conclusions

This study shows for the first time that Holter ECG monitoring during diagnostic bronchoscopy was associated with activation of cardiac sympathetic and withdrawal of cardiac parasympathetic regulation which may contribute to the occurrence of cardiac events during endoscopic procedures. So, Holter ECG monitoring during endoscopic procedures may confer reduction in cardiovascular events.

id 46

19th WCBIP / WCBE World Congress
JOINT MEETING OF THE WORLD ASSOCIATION FOR BRONCHOLOGY AND INTERVENTIONAL PULMONOLOGY & THE INTERNATIONAL BRONCHOESOPHAGOLOGICAL SOCIETY
www.wcbipwcbe2016.org
Fortezza da Basso
May 8-11, 2016
Florence (Italy)

Typhoid fever (ascities with abnormal chest chest X ray)

Omer Elgaili Yousif Elhag

internal medicine, Alneelain University - Sudan

Introduction

Introduction Typhoid fever is a bacterial disease, caused by Salmonella typhi. It is transmitted through the ingestion of food or drink contaminated by the faeces or urine of infected people.

Objective

Objective The goal of this case presentation is to reinforce and highlight common concepts, situations, and presentations that clinicians will encounter on a regular basis in our setting.

Methods

A 32-year-old Sudanese woman presents to the emergency department with a 1-week history of nausea, vomiting, diarrhea, lower abdominal pain,and hallucination. She has 5 children, all of who were normal vaginal deliveries and were born healthy. She has a 1-year history of menstrual irregularity and dysmenorrhea. She is a nonsmoker and is not taking any medications on a regular basis. Her family history is unremarkable. On physical examination, the patient appears toxic. Confused. Her oral temperature is (38.8°C). Her pulse is regular with a rate of 110 bpm. Her blood pressure is 110/60 mm Hg. She is noted to have generalized pallor, but no clubbing, jaundice, or cyanosis is detected. Her abdominal examination reveals distension with mild generalized tenderness. Hepatospleenomegaly There is a mild-to-moderate amount of ascitis. The chest examination bilateral coarse crackles . The remainder of the physical examination is unremarkable. The patient's investigations reveal a normocytic normochromic anemia with a hemoglobin level of 9 g/dL; (ESR) of 50 mm/hr; Rapid test for HIV was negative; normal liver and renal function was impaired with high urea and creatinine; and a urinalysis that is positive for red blood cells, white blood cells, and protein. A chest CT and x-ray showed bilateral multinodular shadow (Figure 1); A brain CT scan was normal .Mantoux skin testing is negative. Ultrasonographic imaging of the abdomen and pelvis demonstrates ascitis,(Figure 2); peritoneal deposits and moderate ascitis are found. A sample of the ascitic fluid sent for analysis reveals exidative ascites, with a predominance of Neutrohpils (80%). No organism is found on culture or Gram staining, and no malignant cells are noted on cytology. Carcinoembryonic antigen levels are found to be normal,alfa fetoprotein also normal. CT scanning of the abdomen and pelvis is performed, which confirms the presence of moderate ascites and liver and spleen modularity (Figure 3). Widal test for Salmonella was positive, blood culture was positive

Results

We start Levofloxacine 500 Mg infusion bid,Azythromycine Caps 500 Mg od normal chest Xray after one week of treatment

Conclusions

enteric fever is one of differential diagnosis in diffuse lung diseases

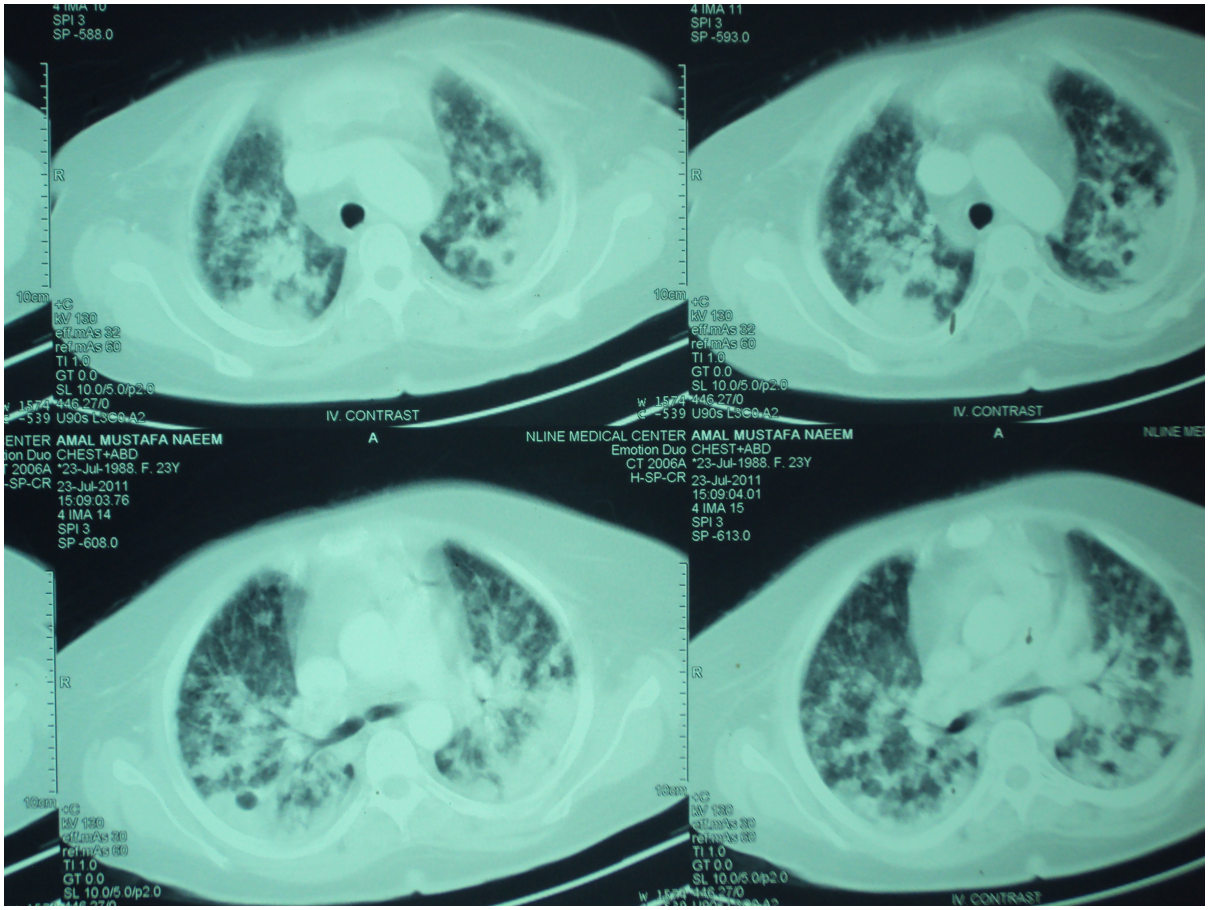
4 IMA 10
SPI 3
SP -588.0
R
10cm
+C
kV 130
eff.mAs 32
ref.mAs 60
TI 1.0
GT 0.0
SL 10.0/5.0/p2.0
w 1574 *46.27/0
c -539 U90s LSC0.A2
IV. CONTRAST
A
AMAL MUSTAFA NAEEM
CHEST+ABD
*23-Jul-1988, F, 23Y
23-Jul-2011
15:09:03.76
4 IMA 14
SPI 3
SP -608.0
4 IMA 11
SPI 3
SP -593.0
NLINE MEDICAL CENTER
Emotion Duo
CT 2006A
H-SP-CR
23-Jul-2011
15:09:04.01
4 IMA 15
SPI 3
SP -613.0

id 47

Radial endobronchial ultrasound images for ground-glass opacity (GGO) pulmonary lesions

Takehiro Izumo, Yuji Matsumoto, Shinji Sasada, Takaaki Tsuchida

Department of Endoscopy, Respiratory Endoscopy Division, National Cancer Center Hospital - Japan

Introduction

Since the introduction of low-dose helical computed tomography (CT) scanning for lung cancer screening, the frequency of detecting pulmonary ground-glass opacity (GGO) has been about 20%. GGOs commonly represent a variety of diseases such as interstitial pneumonia, pulmonary lymphoproliferative disease, organizing pneumonia, and pre-invasive, minimally invasive or moderately/poorly differentiated carcinoma. Thus, definitive diagnosis is very important to choose an appropriate therapy. Radial endobronchial ultrasound (R-EBUS) is a useful tool for precise localization of peripheral pulmonary lesions, but there have been no detailed reports about the use of R-EBUS images for GGO.

Objective

This study focused on the EBUS images of pure and part-solid GGO lesions and correlated these findings with thin section CT findings and surgical histopathology. From its current use in solid lesions, we aim to extend the capability of EBUS to GGOs, because these lesions, especially part-solid GGOs, that do not resolve after 3 months are often malignant. The eventual goal is to improve the diagnostic yield of bronchoscopy for PPLs, including GGO.

Methods

The R-EBUS images of 116 patients with GGO, who were diagnosed as having adenocarcinoma by R-EBUS with a guide sheath (EBUS-GS), were compared with the respective chest computed tomography findings. In 103 patients, R-EBUS images were correlated with the histological surgical specimens.

Results

R-EBUS images of GGO were identified based on the internal structure of the lesion and classified into two groups. Blizzard showed an enlarged, diffuse hyperintense acoustic shadow. Mixed blizzard showed a combination of blizzard and some diffuse heterogeneity with several hyperechoic dots and vessels. All pure GGO lesions (nine out of nine) were blizzard on R-EBUS. For part-solid GGOs, the percentage of mixed blizzard was inversely related to the amount of the GGO component. Histological findings from surgery revealed that all blizzard lesions were on the spectrum of adenocarcinoma in situ to well differentiated adenocarcinoma while majority (33 out of 64) of mixed blizzard lesions were moderately to poorly differentiated adenocarcinoma.

Conclusions

R-EBUS image classification of GGOs as blizzard and mixed blizzard can be one of the useful tools to detect the correct location of GGOs during EBUS-GS. In a part-solid GGO lesion, mixed blizzard sign may represent the area which is preferable to biopsy and, thus, is important to identify. Correlation of thin- section CT findings with each R-EBUS type may potentially affect accurate pathological diagnosis, leading to correct prognostication and application of novel minimally invasive bronchoscopic therapy for peripheral early-stage lung cancer.

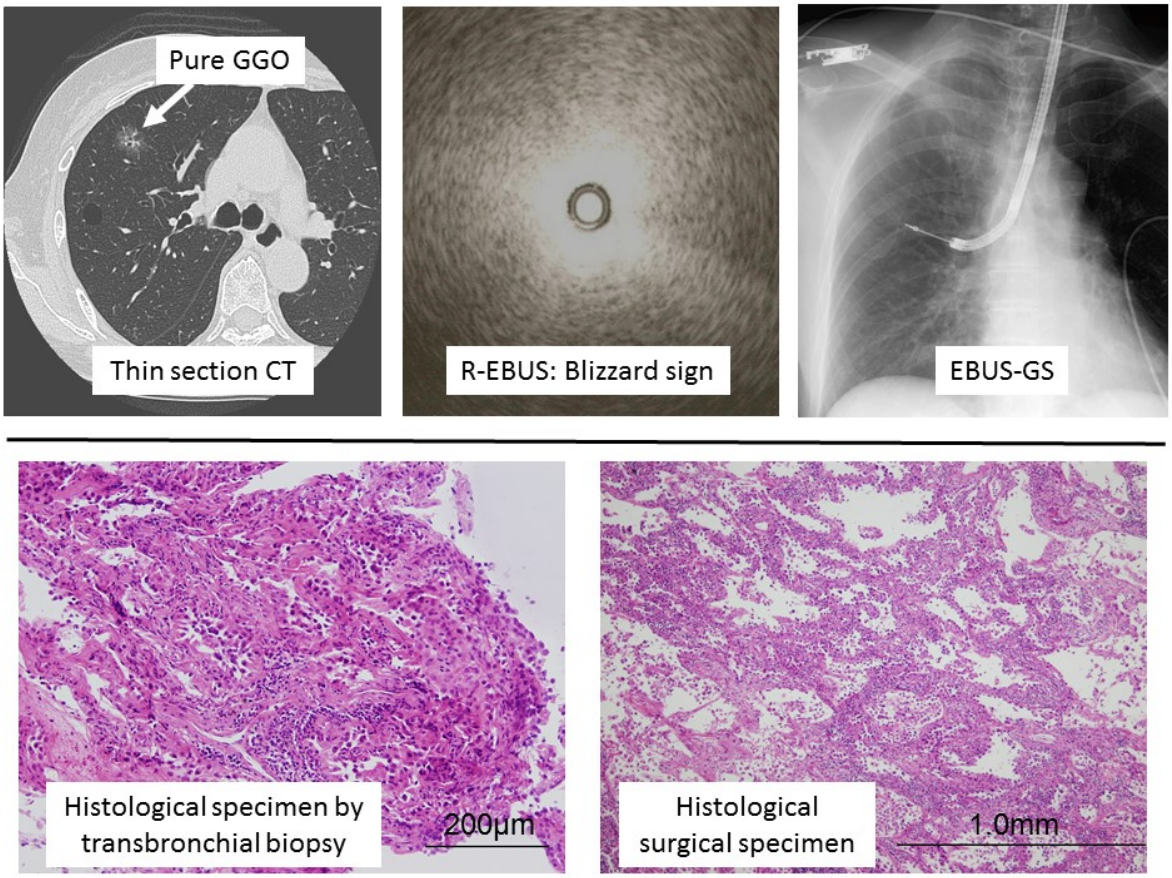
Pure GGO
Thin section CT
R-EBUS: Blizzard sign
EBUS-GS
Histological specimen by transbronchial biopsy
200μm
Histological surgical specimen
1.0mm

id 48

From aperitif to...empyema!

Gaia Cappiello[1], Michele Giovannini[1], Alessandro Marchioni[2], Paolo Corradini[2], Alessandro Andreani[2]

[1]Respiratory Diseases, ASL Modena - Italy
[2]Respiratory Diseases, Azienda Policlinico di Modena - Italy

Introduction

Foreign body aspiration is a serious medical problem. Clinical presentations range from acute suffucation and death to chronic and subtle respiratory symptoms. Here we present a case report where the diagnosis of foreign body aspiration was easy but where the removal of the foreign body was not resolutive for the patient.

Methods

An outpatient 49 years old man came to our attention referring dry cough that started one month before when he was having an aperitif with his friends (drinking beer and eating pumpkin seed): he referred that when he was laughing he probably inhaled a pumpkin seed. Few days before coming to our attention, his general practitioner prescribed directly a chest X ray that showed the presence of a moderate left lower lobe infiltration (Fig. 1A). At our attention (one week later) physical examination revealed the presence of left basilar crackles. We so prescribed thoracic computed tomography (CT) that showed a suspect tickening of the wall of the left lower lobe bronchus (Fig. 1B) and a dense air space consolidation in the left lower lobe (Fig. 1C). A fiberoptic bronchoscopy was performed with visualisation of a foreign body covered with purulent secretions occluding completely the left lower lobe bronchus (Fig. 1D). The obstruction was removed using a biopsy forcep; after removal of the foreign body (Fig. 1E: the Pathologist said later to be compatible with plant material: pumpkin seed exactly) the left lower lobe bronchus appeared partially stenotic for important mucosal edema (Fig. 1F). After bronchoscopy the patient symptomatically improved with immediately reduction of his cough; he was discharged home with levofloxacina for 15 days and with steroid therapy (Prednisone 25 mg) for at least 1 month. In that period his physical conditions further improved; after one month, during the follow up visit in fact, his cough disappeared and the physical examination revealed resolution of left basilar crackles. We so decided for the gradual reduction of steroid therapy. After 20 days however his physical conditions worsened: he came to our attention referring fever, cough and dyspnea. The chest X ray (Fig. 1G) showed the presence of a wide left lower lobe consolidation with pleural effusion that was confirmed also at the following thoracic CT (Fig. 1H); the thoracic ultrasonography showed the presence of multiloculated large left pleural effusion compatible with empyema. We so decided to entrust the patient to the Thoracic Surgeon who perfomed a video-assisted thoracoscopy for pleural decortication.

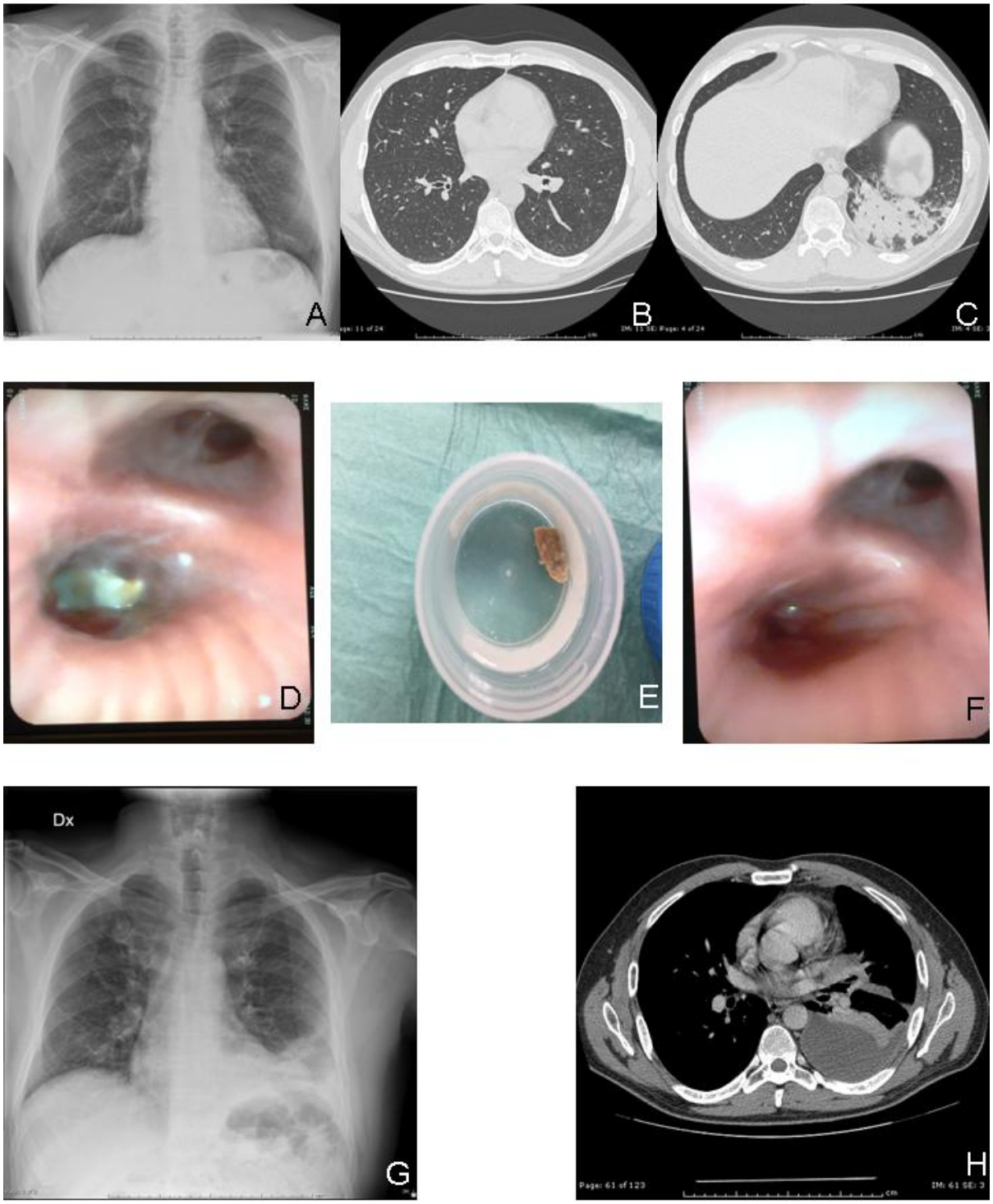

id 49

19th WCBIP / WCBE World Congress
JOINT MEETING OF THE WORLD ASSOCIATION FOR BRONCHOLOGY AND INTERVENTIONAL PULMONOLOGY & THE INTERNATIONAL BRONCHOESOPHAGOLOGICAL SOCIETY
www.wcbipwcbe2016.org
Fortezza da Basso
May 8-11, 2016
Florence (Italy)

Medical thoracoscopic application of autologous blood patch for persistent secondary pneumothorax

Jacky Chung-chieh Huang

Thoracic Surgery Division, Show Chwan Memorial Hospital, Asian Institute of TeleSurgery - Taiwan

Introduction

Secondary pneumothorax is a common complication of advanced chronic obstructive pulmonary disease (COPD). Prolonged air leakage may occur because the lung tissues are too fragile to heal spontaneously. Persistent pneumothorax itself causes serious morbidity and mortality. Management of persisted secondary pneumothorax is difficult and challenging. Autologous blood patch (ABP) for sealing lung air leaks have been reported since 1980s. But it seems not to be widely accepted because of the doubt of effectiveness and the possible infectious complications due to repeated instillation of amount blood into the thorax. We believe that identification the air leaking locations by thoracoscopy and application of right amount of ABP on the right location under guidance, rather than blind instillation of large amount of ABP, the effectiveness could be improved and complications be reduced. Medical thoracoscopy is considered to be competent for these procedures. We hereby try to treat prolonged pneumothorax complicating advanced COPD with medical thoracoscopy and autologous blood patches.

Objective

To analyze the safety, effectiveness and outcomes of Medical Thoracoscopic Interventions with guided application of auto in the treatment of persistent secondary pneumothorax.

Methods

We have collected ten patients with persistent secondary pneumothorax with air leak more than 5 days. Medical thoracoscopy was used to inspect the pleural space and found out the air leakage locations with normal saline instillation. Then, 25 -30cc autologous blood was applied on the lesion sites to seal the leaks. The underlying lung diseases, duration of chest drainage, peri-operation pain scores, adverse reactions and clinical outcomes were analyzed.

Results

Air leaking locations were clearly identified in 8 patients during thoracoscopic inspection. Immediate sealing-off was gained in those 8 well-localized patients with guided ABP and all air leaks stop during the first 24 hours for the other two patients. All patients tolerated the operations well. The average pain score was 3. No major adverse effect, infection or mortality complicated the procedures. Chest tubes were removed successfully within 3-7 days after operations. The follow-up periods were 2 to 30 months. Only one patient had recurrence and received one more time of ABP.

Conclusions

Medical thoracoscopy is a safe modality for pleural inspection and air leaks localization. Once the lesions were identified, scope-guided application of ABP can get rapid recovery of secondary pneumothorax. Because it’s reliable safety and dramatic effectiveness, medical thoracoscopic application of ABP should be considered as the treatment modality of priority in management of prolonged secondary pneumothorax in advanced COPD patients.

Bibliography

Pagan V. et al. Chir Ital. 2006;58(4):413-21 Manley K. et al. Curr Opin Pulm Med 2012;18:333–338

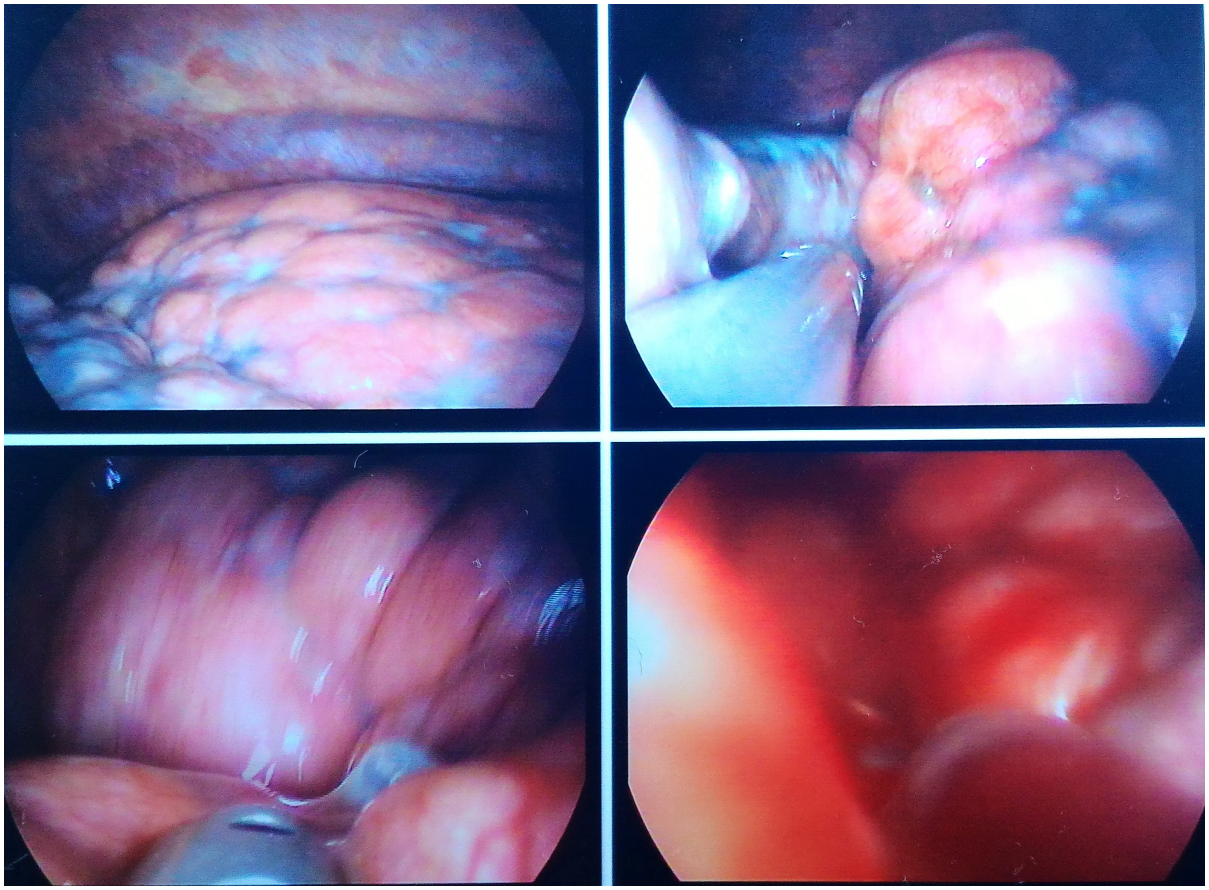

id 50

19th WCBIP / WCBE World Congress
JOINT MEETING OF THE WORLD ASSOCIATION FOR BRONCHOLOGY AND INTERVENTIONAL PULMONOLOGY & THE INTERNATIONAL BRONCHOESOPHAGOLOGICAL SOCIETY
www.wcbipwcbe2016.org
Fortezza da Basso
May 8-11, 2016
Florence (Italy)

Impact of EBUS-TBNA rinse fluid PCR in the diagnosis of intrathoracic tuberculous lymphadenitis

Viboon Boonsarngsuk

Medicine, Ramathibodi Hospital, Mahidol University - Thailand

Introduction

Intrathoracic tuberculous (TB) lymphadenitis is a diagnosis challenge for the clinician. Although endobronchial ultrasound-guided transbronchial needle aspiration (EBUS-TBNA) can obtain the sample from the affected lymph node, the diagnostic yield of cytopathalogy remains low.

Objective

To evaluate the efficacy of EBUS-TBNA rinse fluid TB polymerase chain reaction (PCR) assay for diagnosis of intrathoracic TB lymphadenitis.

Methods

A retrospective study was conducted on 79 patients who underwent EBUS-TBNA for diagnostic evaluations of intrathoracic lymphadenopathy. EBUS-TBNA specimens were evaluated by cytopathological examination. Rinse fluid of the needle was routinely submitted to AFB stain, Mycobacterium culture, and TB PCR by using the AnyplexTM MTB/NTM real-time detection kit.

Results

Of 79 patients, 13 patients were finally diagnosed as intrathoracic TB lymphadenitis by either microbiology, cytopathology, or clinical ground. Among TB patients, 8 (61.5%), 6 (46.2%), 2 (15.4%), and 6 (46.2%) patients were positive for TB PCR, mycobacterium culture, AFB smear, and necrotizing granulomatous inflammation, respectively. The sensitivity, specificity, positive predictive value, and negative predictive value of TB PCR assay were 61.5%, 100.0%, 100.0%, 93.0%, respectively. Using the area under the ROC curve (AUC) as a measure of a diagnostic performance, TB PCR was highest, compared with mycobacterium culture, AFB smear, and finding of necrotizing granulomatous inflammation (0.808, 0.731, 0.569, and 0.731, respectively). Combination of TB PCR, mycobacterium culture, and finding of necrotizing granulomatous inflammation provided the best diagnostic performance (sensitivity, specificity, positive predictive value, negative predictive value, and AUC of 84.6%, 100.0%, 100.0%, 97.1%, and 0.923, respectively).

Conclusions

EBUS-TBNA rinse fluid TB PCR assay is useful in the diagnosis of intrathoracic TB lymphadenitis. Combine TB PCR to mycobacterium culture and cytopathological finding helps improvement in TB diagnosis.

19th WCBIP / WCBE World Congress
JOINT MEETING OF THE WORLD ASSOCIATION FOR BRONCHOLOGY AND INTERVENTIONAL PULMONOLOGY & THE INTERNATIONAL BRONCHOESOPHAGOLOGICAL SOCIETY
www.wcbipwcbe2016.org
Fortezza da Basso
May 8-11, 2016
Florence (Italy)

A combination of smears and cell block preparations provides high diagnostic accuracy for EBUS-TBNA

Jick Hwan Ha[1], Byeong-ho Jeong[2], Kyung Jong Lee[2], Hojoong Kim[2], O Jung Kwon[2], Sang-won Um[2]

[1]Department of Internal Medicine, College of Medicine, The Catholic University of Korea - Korea
[2]Department of Medicine, Samsung Medical Center, Sungkyunkwan University School of Medicine - Korea

Introduction

During endobronchial ultrasound-guided transbronchial needle aspiration (EBUS- TBNA), aspirated and tissue coagulum clot are obtained from patients.

Objective

The objective of this study was to compare the combined diagnostic sensitivity of aspirate cytology and tissue coagulum clot histology with each method alone.

Methods

Between May 2009 ~ May 2014, EBUS-TBNA database was analyzed retrospectively. The cytopathological examination was based on aspirtate cytology and tissue coagulum clot histology.

Results

A total of 3107 lymph nodes were evaluated in 1367 patients with primary lung cancer. A total of 1207 lymph node was confirmed as malignant lymph nodes. The sensitivity was 94.5% (1093/1157) for histology and 83.8% (970/1157) for cytology ($p<0.0001$). The combined diagnostic sensitivity of histology and cytology was 100 % (1207/1207). 5.5% (64/1157) of malignant lymph node was negative histology / positive cytology and 16.2% (187/1157) of malignant lymph node was negative cytology / positive histology. This negative histology/positive cytology group showed significantly shorter short axis diameter of lymph node ($p=0.0049$) and less needle passes per lymph nodes ($p=0.0015$) compared with other groups.

Conclusions

The combination of cytology and histology can increase the diagnostic sensitivity of EBUS-TBNA. Aspirate cytology and tissue coagulum clot histology should be included in cytopathological evaluation together.

id 52

19th WCBIP / WCBE World Congress
JOINT MEETING OF THE WORLD ASSOCIATION FOR BRONCHOLOGY AND INTERVENTIONAL PULMONOLOGY & THE INTERNATIONAL BRONCHOESOPHAGOLOGICAL SOCIETY
www.wcbipwcbe2016.org
Fortezza da Basso
May 8-11, 2016
Florence (Italy)

Thoracoscopic diaphragmatic repair under local anesthesia for refractory hepatic hydrothorax

Jacky Chung-chieh Huang

Division of Thoracic Surgery, Show Chwan Memorial Hospital and Asian Institute of TeleSurgery - Taiwan

Introduction

Hepatic hydrothorax (HH) is a common complication of late-staged liver cirrhosis. It may cause significant respiratory distress and even mortality. Conservative managements are of little effectiveness. Influx of ascites into pleural space through diaphragmatic defects has been identified as the major patho-physiological mechanism. Surgical repair of the diaphragmatic defects with suture or mesh coverage have been reported to be an effective palliation for refractory hepatic hydrothorax. However, such surgical interventions usually have to be performed under general anesthesia, but most of the hepatic failure patients can not tolerate these procedures because of the physiological stress of general anesthesia. Based on our prior clinical experience and literature reports, many simple thoracic procedures could be operated by video-assisted thoracic surgery (VATS) and local anesthesia. We hereby conduct a pilot minimally invasive method using VATS plication of the diaphragm and meshing pleurodesis operated under local anesthesia for palliative management of refractory hepatic hydrothorax.

Objective

To identify the safety and effectiveness of VATS diaphragmatic defects repair by suture plication of the central portion of diaphragm and reinforcement with meshing pleurodesis under minimally invasive anesthesia for liver cirrhosis patient with refractory hepatic hydrothorax.

Methods

Five liver cirrhosis patients with hepatic hydrothorax refractory to conservative treatment were enrolled in this study. Thoracoscopic interventions were performed under local anesthesia setting in operation room. Endoscopic suture plication of the central dome of the diaphragm followed by mesh overlay on the diaphragmatic surface in order to create additional pleurodesis was performed through two small port wounds. The patient characters, operation blood loss, peri-operation pain score, operation-related complications, clinical success defined as no more recurrence of effusion for at least 3 months were collected and analyzed.

Results

One of the five patients was Child-Pugh's class B and the other 4 patients were class C. All had received conservative treatment, but in vain. Eventually repeated thoracocentesis or tube drainage was needed before operation. The average operation time was 95 minutes and blood loss less than 50cc. There were no operation-related complications or mortality. The clinical success rate was 100 percent for average 7 months interval. Moderate-to-massive ascites developed after operation as manifestation of liver decompensation.

Conclusions

For patients with hepatic hydrothorax, aggressive surgical intervention might improve survival. Minimally invasive anesthesia and surgical intervention with plication and meshing method is simple, safe and effective for management of refractory hepatic hydrothorax.

19th WCBIP / WCBE World Congress
JOINT MEETING OF THE WORLD ASSOCIATION FOR BRONCHOLOGY AND INTERVENTIONAL PULMONOLOGY & THE INTERNATIONAL BRONCHOESOPHAGOLOGICAL SOCIETY
www.wcbipwcbe2016.org
Fortezza da Basso
May 8-11, 2016
Florence (Italy)

A study on the treatment of airway stenosis by using the flexible bronchoscope via laryngeal mask

Yinghua Pei, Jie Zhang, Juan Wang, Yuling Wang, Xiaojian Qiu, Min Xu, Chenyang Zhang

Pulmonary Medicine, Beijing Tian Tan Hospital, Capital Medical University - China

Objective
The indications, technologies and complications associated with the use of the laryngeal mask for airways ventilation during flexible bronchoscopy interventional therapy under general anesthesia were evaluated in a retrospective analysis of a large sample of clinical data. The results of this study provide more choice of interventional methods for airway stenosis.

Methods
Patients treated by using flexible bronchoscopy via the laryngeal mask under general anesthesia , from March 2005 to March 2015 in our hospital, were included in this study. The types, locations, and severity of airway stenosis disease as well as the effects and related complications associated with the intervention technologies were analyzed.

Results
In total, 372 patients (223(59.95%) males and 149(40.05%) females) with a mean age of 52±18 years (range, 12–86years) were included in this study. The most common disease was airway tumors, with 179(48.12%) cases including 111(29.84%) cases of primary malignant airway tumors, 39(10.48%) cases of secondary malignant airway tumors and 29(7.80%) cases of benign airway tumors. The second most common disease was benign cicatricial airway stenosis, with 146 (39.25%)cases. There were 47(12.63%) cases of other airway diseases. The lesions were subglottic, with 196 (52.69%) located in the upper and middle trachea, 163(43.82%) and 163 (43.82%) located in the lower trachea, carina and bronchus. In terms of the degree of stenosis, 474 (85.25%) cases reached stages III–IV. 393 (70.68%) cases required recanalization and 121 (21.76%) required partial recanalization, interventions that are considered to be clinically effective. The complications reported 29 (5.22%) cases of throat discomfort, 3 (0.54%) cases of hoarseness, 10 (1.8%) cases of glottic edema, 2 (0.36%) cases of laryngeal spasm, and 3 (0.54%) cases required repeat endotracheal intubation because of leakage.

Conclusions
This interventional method for airway stenosis by using flexible bronchoscopy via the laryngeal mask under general anesthesia is safe, few complications and good curative effect. It can deal with almost all of the tracheal, bronchial lesions, especially suitable for subglottic lesions. The method is simple, effective, safe, and easy to operate and is suitable for popularized use as an alternative to rigid bronchoscopy in most cases.

19th WCBIP / WCBE World Congress
JOINT MEETING OF THE WORLD ASSOCIATION FOR BRONCHOLOGY AND INTERVENTIONAL PULMONOLOGY & THE INTERNATIONAL BRONCHOESOPHAGOLOGICAL SOCIETY
www.wcbipwcbe2016.org
Fortezza da Basso
May 8-11, 2016
Florence (Italy)

An evalution on interventional therapeutic bronchoscopy for malignant airway carinal stenosis

Yinghua Pei, Jie Zhang, Juan Wang, Yuling Wang, Xiaojian Qiu, Ting Wang, Min Xu, Chenyang Zhang

Pulmonary Medicine, Beijing Tian Tan Hospital, Capital Medical University - China

Objective
To explore safe and effective methods of bronchoscopic interventional therapy for malignant airway carinal stenosis.

Methods
We performed a retrospective analysis of the clinical data of 58 cases of patients who received bronchoscopic interventional therapy for malignant airway carinal stenosis.

Results
Squamous cell carcinoma was the most common cause of airway carinal stenosis (58.6%). Intraluminal lesions were the most common followed by mixed type and external pressure type. All patients had general anesthesia and tracheal intubation for ventilation and some used the laryngeal mask or rigid bronchoscope. One or multiple ablation techniques (mainly thermal ablation) were performed on intraluminal lesions. 38 patients with severe airway obstruction were implanted with 42 China-made nickel titanium memory alloy stents (9 Y-shaped, 7 cone-shaped, 26 straight tube) and 1 Y-shaped Dumon silicone stent. Endoscopy showed the recanalization rate of the airway was 94.8%. Symptoms were relieved rapidly after the operation (Borg scale: pre- operation, 4.12±0.37 and post-operation, 1.25±0.67; $P < 0.01$). The main intra-operative adverse reaction was hemorrhage. No severe adverse effects or death were observed.

Conclusions
General anesthesia is recommended during the therapeutic bronchoscopy for the airway carinal lesions to overcome the ventilation difficulty and risk encountered in the local anesthesia. Tracheal intubation is the safest option for ventilation although the laryngeal mask is a suitable alternative. Rigid bronchoscopy is preferred for implantation of a Y-shaped stent. Because carnial tumor often congests both left and right primary bronchi, death is possible due to the choke caused by hemorrhaging during the ablation of the tumor. It would be advised to choose the thermal ablation such as laser, electrotomy or APC to ablate the neoplasm for fear that bleeding. Cryoablation or mechanical cutting under rigid bronchoscopy are not recommended for it can cause severe hemorrhaging. Customization and Adapatability to the peculiar anatomical situations of carinal lesion is better in China-made nickel titanium memory alloy stents than in Dumon silicone stents. However, in emergency, one or two regular stents should be placed immediately in order to save patient’s life instead of Y-shaped or cone-shaped stent which is relatively difficult to place.

id 55

19th WCBIP / WCBE World Congress
JOINT MEETING OF THE WORLD ASSOCIATION FOR BRONCHOLOGY AND INTERVENTIONAL PULMONOLOGY & THE INTERNATIONAL BRONCHOESOPHAGOLOGICAL SOCIETY
www.wcbipwcbe2016.org
Fortezza da Basso
May 8-11, 2016
Florence (Italy)

The clinical analysis of airway metal stents removal by rigid bronchoscopy

Lianqing Wang, Jie Zhang, Juan Wang, Yinghua Pei, Yuling Wang, Xiaojian Qiu, Ting Wang, Min Xu, Chenyang Zhang

Pulmonary Medicine, Beijing Tian Tan Hospital, Capital Medical University - China

Objective

To explore techniques and related complication managements of airway metal stents removal with rigid bronchoscope under generalanesthesia.

Methods

We reviewed 20 patients who underwent rigid bronchoscopic stents removal under general anesthesia from Jan. 2008 to Jan. 2015. The clinical data of those cases were analyzed retrospectively. The assessment of the indications for stents removal and difficulties possibly encountered, the relationship between techniques and related complications of stents removal were discussed and analyzed, and the experience are summarized.

Results

The indications for airway metal stents removal are mainly include: stent migration, fracture, and granulation related in-stent restenosis. 19 airway metal stents were removed from 20 patients. All 9 covered metal stents were removed successfully, 6 without fragmentation and 3 with fragmentation. Average duration of stenting before removal was 7.41±6.94 months (5 days-24months); Among 11 uncovered metal stents which stayed in airway for 10.15±7.03 months (20 days-24months), 10 were removed successfully and 1 was unremoved. 3 of those stents were removed intactly and 7 stents were fragmented. Complications were as follows: airway bleeding need for management (n = 11), airway collapse (n = 6), re-obstruction requiring temporary stent placement (n = 5), postoperative tracheal intubation (n = 1), mucosal tear with tracheoesophageal fistula (n = 1), airway firing (n = 1), airway obstruction, and death as a result of attempted stent removal (n = 1).

Conclusions

The metal stent removal is a high-risk operation. Indications for stents removal should be evaluated thoroughly and all the advantages and disadvantages should be added up. Once stent removal was decided, the type of the metal stent, the position of the stent implanted, the duration of stenting, and the extent of the stent embedded in granulation tissue should be considered previously to assess the difficulty of the procedure. Dissection of the stent from the airway wall before extracting it can reduce complications such as airway bleeding, mucosal tear and airway obstruction. At the same time, a standby stent is needed to deal with possible airway collapse after stent removal. Removal of metal airway stents should only be performed by a proficient and experienced interventional pulmonology team to ensure successful operation and to improve patient safety.

19th WCBIP / WCBE World Congress
JOINT MEETING OF THE WORLD ASSOCIATION FOR BRONCHOLOGY AND INTERVENTIONAL PULMONOLOGY & THE INTERNATIONAL BRONCHOESOPHAGOLOGICAL SOCIETY
www.wcbipwcbe2016.org
Fortezza da Basso
May 8-11, 2016
Florence (Italy)

Application of paclitaxel as adjuvant treatment for benign cicatricial airway stenosis

Xiaojian Qiu, Jie Zhang, Juan Wang, Yinghua Pei, Yuling Wang, Ting Wang, Min Xu, Chenyang Zhang

Pulmonary Medicine, Beijing Tian Tan Hospital, Capital Medical University - China

Objective
Benign cicatricial airway stenosis (BCAS), usually resulting from tracheal intubation, tracheotomy, endobronchial tuberculosis, tracheobronchial anastomosis, and other etiologies, is a potentially life-threatening health problem in China. Recurrence occurs frequently after endoscopic treatment. The drug paclitaxel is known to prevent restenosis, but clinical evidence of its efficacy and safety is needed. Therefore, we investigated the efficacy, and associated complications, of paclitaxel as adjuvant treatment for BCAS of different etiologies.

Methods
The study cohort included 28 patients with BCAS resulting from tuberculosis, intubation, tracheotomy, and other etiologies. All patients were treated at the Department of Respiratory Diseases, Beijing Tiantan Hospital, Capital Medical University, China, between January 2009 and August 2013. After primary treatment by balloon dilation, cryotherapy, and/or high-frequency needle-knife, paclitaxel was applied to the airway mucosa at the site of stenosis using a newly developed local instillation catheter. The primary outcome measures were the therapeutic efficacy of paclitaxel as adjuvant treatment and the incidence of complications, such as changes in blood cell counts, liver and kidney functions.

Results
According to our criteria for evaluating the clinical effects on BCAS, BCAS was cured in 24 of the 28 paclitaxel-treated cases, remission was achieved in three cases, and one case showed no remission. Thus, the cure rate was 85.7%, and the combined effective cure rate was 96.4%. No differences in outcomes were observed among the different BCAS etiologies (p=0.144), and few complications were observed.

Conclusions
Paclitaxel as adjuvant treatment showed greater efficacy than previously reported BCAS treatment methods.

id 57

19th WCBIP / WCBE World Congress
JOINT MEETING OF THE WORLD ASSOCIATION FOR BRONCHOLOGY AND INTERVENTIONAL PULMONOLOGY & THE INTERNATIONAL BRONCHOESOPHAGOLOGICAL SOCIETY
www.wcbipwcbe2016.org
Fortezza da Basso
May 8-11, 2016
Florence (Italy)

Experience of 37 cases (39 procedures) of medical thoracoscopy in Seoul National University Hospital

Young Sik Park, Sun Mi Choi, Jinwoo Lee, Chang-hoon Lee, Sang-min Lee, Jae-joon Yim, Chul-gyu Yoo, Young Whan Kim, Sung Koo Han

Internal Medicine, Seoul National University Hospital - South Korea

Introduction

Medical thoracoscopy (MT) is invasive endoscopic procedure for exploration of pleural cavity under conscious sedation and local anesthesia. MT has been performed in Seoul National University Hospital since Feb 2014.

Objective

We will summarize the cases with their outcomes.

Methods

Consecutive patients who underwent MT were included. MT was all performed by pulmonologists in the bronchoscopy room. Both rigid and semi-rigid scopes were used under conscious sedation with fentanyl and midazolam. Medical records were reviewed for clinical data.

Results

From Feb 2014 to Oct 2015, a total of 37 cases (39 procedures) were performed (diagnostic MT 22 cases, therapeutic MT 15 cases). Median age was 63 (25 – 85) years old and 33 (89.2%) were male. Median procedure time (from skin incision to insertion chest tube) was 37 min. Median dosages of fentanyl and midazolam were 50 ?g and 5 mg, respectively. All procedures were done without any unexpected events. Sixteen out of 22 cases of pleural diseases with unknown cause were successfully diagnosed by MT and malignancy (9 cases) was the most common diagnosis. Therapeutic MT was very effective for empyema treatment. The median days with chest tube drainage were 7, and it was different between diagnostic (4 days) and therapeutic (8 days) MT.

Conclusions

MT is very useful and necessary procedure for both diagnosis and treatment of pleural diseases.

id 58

19th WCBIP / WCBE World Congress
JOINT MEETING OF THE WORLD ASSOCIATION FOR BRONCHOLOGY AND INTERVENTIONAL PULMONOLOGY & THE INTERNATIONAL BRONCHOESOPHAGOLOGICAL SOCIETY
www.wcbipwcbe2016.org
Fortezza da Basso
May 8-11, 2016
Florence (Italy)

Endobronchial embolization using a Watanabe Spigot for persistent air leakage with serious condition

Terunaga Inage

General Thoracic Surgery, Graduate School of Medicine Chiba University - Japan

Introduction

The pneumothorax and empyema with persistent air leakage in patients with serious respiratory condition are often challenging. Endobronchial Watanabe Spigot (EWS) was introduced by Watanabe et al in 1991 for treatment of bronchopleural f?stula. Endobronchial embolization is an alternative strategy for the management of pneumothorax or empyema with persistent air leakage.

Objective

The aim of this study was to evaluate the feasibility of occlusion using an Endobronchial Watanabe Spigot (EWS) to treat persistent air leakage in patients with poor performance status.

Methods

We performed retrospective chart review of the 10 patients who underwent endobronchial occlusion using EWS for the management of persistent air leakage at Chiba University Hospital between March 2013 and April 2014.

Results

Ten patients comprised 7 men and 3 women, with a mean age of 64.4 years (45 - 71). All patients underwent chest tube drainage, and air leakage was manifested. All patients had chronic pulmonary disease ; 8 patients had parapneumonic empyema. Every patient required supplemental oxygen, 2 of whom which were managed under mechanically ventilation for acute respiratory distress syndrome. The Eastern Cooperative Oncology Group performance status (PS) was 3 in 6 patients and 4 in 4 patients. Nine of 10 patients showed marked decrease of air leakage during the balloon occlusion test, and the bronchi corresponding to the air leakage were identified. EWS placement at the corresponding bronchus successfully reduced air leakage for all patients, and PS improved in 8 patients. After insertion of EWS devices, the chest tube was successfully removed in 1 patient, and lung expansion was achieved in 3 patients with removal of the chest tube following picibanil pleurodesis. The amount of air leakage decreased after EWS insertion into 5 patients, then general condition was recovered and underwent radical surgery for empyema. One postesophagectomy patient died of acute respiratory distress, and 2 patients with interstitial lung disease due to rheumatoid arthritis died of chronic respiratory failure after fenestration for empyema. Eventually, 7 of 10 patients were discharged from the hospital. There were no serious complications associated with to EWS insertion.

Conclusions

Endobronchial embolization using an EWS for persistent air leakage appeared to be safe and effective, even for compromised patients.

Bibliography

Watanabe Y, et al. The Journal of the Japan Society for Bronchology 10:264-7,2003 Sasada S, et al.Intern Med 2011; 50: 1169-73.

Patient No	Age	Sex	Localiszation	PS	Etiology	Pre-treatment respiratory condition				Previous treatment	Days prior to EWS	Number of spigot	Pre-treatment PS	Post-treatment PS	Chest tube removed after embolization	Additional treatment	Surgical treatment	Outcome
						Pneumoniae	ARDS	Ventilator	Empyema									
1	54	F	RLL	3	RA-ILD	yes	no	no	yes	Pleurodesis,Fenestration	153	7	3	2	No		Thoracoplasty	Discharge
2	71	M	LUL	3	IPF	no	no	no	no	Fibrogammin P	14	3	3	2	Yes	Pleurodesis		Discharge
3	65	M	LUL	3	RA-ILD	yes	no	no	yes	Fibrogammin P	32	10	3	2	No		Fenestration	Death
4	46	F	RUL	4	Empyema	yes	yes	yes	yes	Pleurodesis,Fibrogammin P	55	10	4	3	Yes	Pleurodesis		Discharge
5	70	M	RUL	4	COPD・Esophagial surgery	yes	yes	yes	yes	no	29	5	4	4	No			Death
6	71	F	RUL	3	RA-ILD・Aspergillosis	yes	no	no	yes	no	8	7	3	2	No		Fenestration	Discharge
7	67	M	RUL	3	COPD・Esophagial surgery	yes	no	no	yes	no	12	2	3	2	Yes	Fibrogammin P		Discharge
8	65	M	LUL+S6	4	RA-ILD・Aspergillosis	yes	no	no	yes	Intrapleural administration of fibrin glue	22	3	4	3	No		Fenestration	Death
9	69	M	RMLL	3	COPD	yes	no	no	yes	no	12	9	3	3	No		Fenestration	Discharge
10	67	M	RUL	4	COPD	yes	no	no	no	no	20	5	4	3	Yes	Pleurodesis		Discharge

LLL = Left lower lobe; LUL = left upper lobe; RUL = right upper lobe; RMLL = right middle and lower lobe.

RA-ILD = rheumatoid arthritis related interstitial lung disease. COPD = chronic obstructive pulmonary disease.

ARDS = acute respiratory distress syndrome

Rigid tru-cut transbronchial core-biopsy in the diagnosis of mediastinal diseases

Giovanni Galluccio, Gabriele Lucantoni, Sandro Batzella, Paolo Battistoni, Raffaele Dello Iacono, Umberto Caterino, Manuela Palazzolo

Center of Thoracic Endoscopy, San Camillo-Forlanini Hospital - Italy

Introduction

An invasive procedure is mandatory in CT scan positive for enlarged lymphnodes or mediastinal masses in order to obtain tissue for histological examination. At present time several invasive tests are available. These include mediastinoscopy, anterior mediastinotomy, transthoracic needle aspiration (TTNA), transbronchial needle aspiration (TBNA), endobronchial ultrasound (EBUS) with needle aspiration (NA), esophageal endoscopic ultrasound (EUS) with NA, and video-assisted thoracic surgery (VATS).

Objective

We report our experience with a modified rigid tru-cut needle to bioptize mediastinal masses by rigid bronchoscope; we investigated the diagnostic accuracy of this new endoscopic technique as a possible alternative to surgery and when TBNA has failed.

Methods

156 selected patients with radiographic evidence of lymphadenopathy or mediastinal masses (subcarinal and paratracheal with a short-axis diameter >3cm) were studied in our center. Once the site for biopsy has been reached a 18 Gauge Quick Core® Biopsy Needle(Cook Medical Incorporated, Bloomington IN, USA) was introduced through the rigid bronchoscope. The needle is a modified 60cm lenght tru-cut rigid tool composed by a plunger, a cutting cannula that covers a distal 20mm specimen notch and a stylet (Figure 1). The tracheobronchial wall was punctured with the stylet retracted, the specimen notch was pushed inside the lesion for 2 cm to expose the notch to the area to be biopsied, then the cutting cannula was fired down by pushing the plunger in order to capture the tissue within the specimen notch. The bioptic tissue was harvested and stored in formalin tubes for histopathological examination.

Results

The procedures were respectively 124 trans-carinal-needle -biopsies (79,4%) in subjects with subcarinal involvement (n° 96 anterior and 28 posterior site) and 32 trans-tracheal-needle-biopsies (20,6%) in paratracheal lesions (n° 24 at 4R site, n° 8 at 4L). In 140 cases (89.7%) a histological diagnosis has been reached , avoiding further invasive surgical approach and addressing the clinician / surgeon to a correct therapeutic strategy: 99 patients (70.7%) with primary lung cancer, 15 cases (10.7%) mediastinal localization of different malignant cancers, 26 (18.5%) non-neoplastic diseases. No peri or post operative complications were detected.

Conclusions

Our results show that transbronchial needle core-biopsy of lymphadenopathy / mediastinal masses could be considered a valid alternative to more invasive surgical investigations in selected patients when flexible needle techniques (TBNA, EBUS-TBNA) failed.

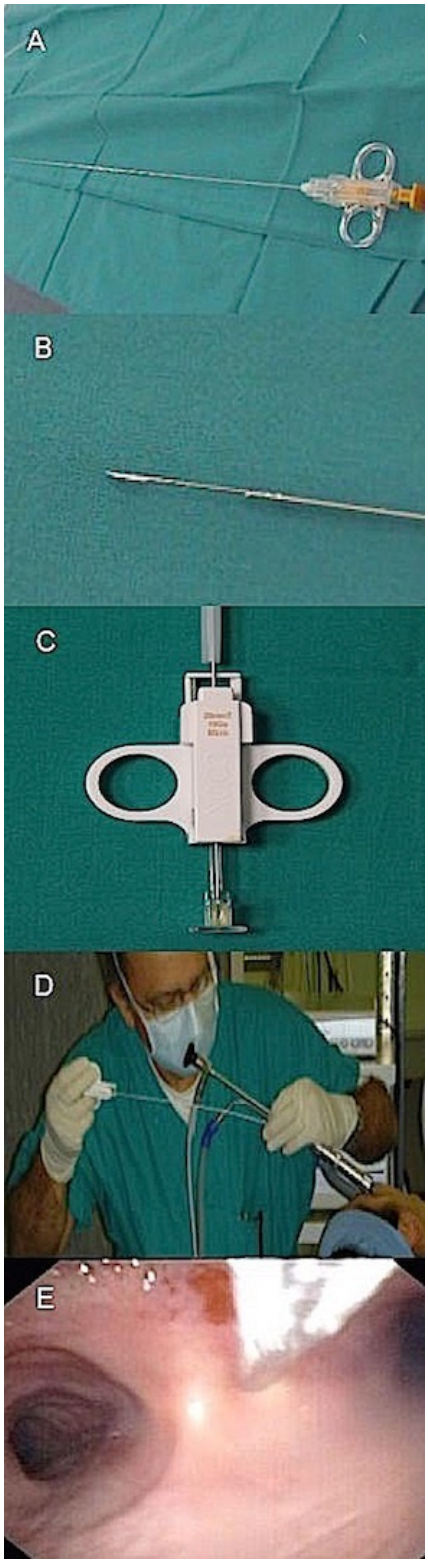

id 60

19th WCBIP / WCBE World Congress
JOINT MEETING OF THE WORLD ASSOCIATION FOR BRONCHOLOGY AND INTERVENTIONAL PULMONOLOGY & THE INTERNATIONAL BRONCHOESOPHAGOLOGICAL SOCIETY
www.wcbipwcbe2016.org
Fortezza da Basso
May 8-11, 2016
Florence (Italy)

Use of Polyvinyl Alcohol Sponge and Cyanoacrylate Glue in the treatment of Bronchopleural Fistula

Giovanni Galluccio, Paolo Battistoni, Raffaele Dello Iacono, Sandro Batzella, Gabriele Lucantoni

Center of Thoracic Endoscopy, San Camillo-Forlanini Hospital - Italy

Introduction

Bronchopleural fistulas represent a relatively frequent complication of pulmonary resections (1.8%) that may lead to patients' death. This pathology may be treated by pleural drainage, open surgery, endoscopy, depending on the morphology of the fistulas, on the site, on the time of onset after resection. An endoscopic less invasive treatment may be desirable especially in suffering patients with co morbidities, in whom a new surgery may be risky. Otherwise the endoscopic approach is sometimes difficult, depending on the dimensions of the leak. Many different techniques have been proposed, with a good rate of success in smaller and recent fistulas. In larger and older ones an effective may be difficult to achieve, and complex procedures have been proposed.

Objective

The authors present a new endoscopic method, that proved to be efficient in a series of patients with larger and chronic fistulas.

Methods

Through a rigid bronchoscope, a small cylinder of PVA (polyvinyl alcohol) sponge is inserted to the fistula and then charged with a very fluid, slow activated cyanoacrylate. The cylinder increases its volume by two to four times, acquiring an hourglass shape, while the cyanoacrylate gradually polymerizes and solidifies, with tight adherence to the walls of the fistula. The immediate result is the occlusion of it, but the sponge also induces inflammatory reaction, as a foreign body, which brings ,in the following weeks, to a granuloma (Figure 1).

Results

We treated 7 patients with post resection fistulas ranging from 4 to 8 mm. The site was the bronchial surgical suture in 6/7 patients and in one case the right wall of distal trachea, after N4R lymphectomy. A complete occlusion of the fistulas was achieved in 7/7 patients and a definitive result in 5/7. The procedure took 40±5 minutes to be performed. The mean hospital stay was 2 days. No severe complications occurred after the interventional endoscopic procedures.

Conclusions

The new technique we experienced may represent an effective treatment in patients with larger fistulas, but also on difficult sites like trachea.

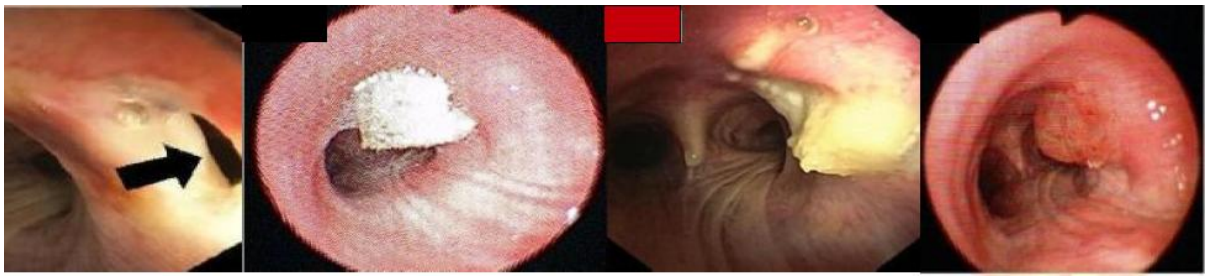

19th WCBIP / WCBE World Congress
JOINT MEETING OF THE WORLD ASSOCIATION FOR BRONCHOLOGY AND INTERVENTIONAL PULMONOLOGY & THE INTERNATIONAL BRONCHOESOPHAGOLOGICAL SOCIETY
www.wcbipwcbe2016.org
Fortezza da Basso
May 8-11, 2016
Florence (Italy)

Medical thoracoscopy in undiagnosed exudative pleural effusion: last 10 years of our experience

Luigi Di Stefano[1], Giovanni Trucco[1], Patrizia Zoccali[1], Claudio Demichelis[2]

[1]Interventional Pulmonology, Hospital - Italy
[2]Head Respiratory Diseases Unit, Hospital - Italy

Introduction

The differential diagnosis of pleural effusions can present a considerable challenge for pneumologist. The thoracentesis do not provide a definitive diagnosis. The medical thoracoscopy is the “gold standard “ technique for diagnosis and management of exudative pleural effusions with unknown aetiology. The diagnosis yield is more then 90 percent of patients.

Objective

This study aimed to assess the efficacy and safety of medical thoracoscopy in the diagnosis of patients with undiagnosed pleural effusion.

Methods

Between January 2006 and October 2015 ,medical thoracoscopy ,using rigid instruments, was performed in 415 patients with unknown pleural effusion by a pneumologist in our hospital under local anesthesia and conscious sedation, visualizing pleural surfaces, to perform parietal biopsies and effective pleurodesis, in one sitting when required , in the broncoscopy room.

Results

Of the 415 patients (290 male and 125 female) total malignancy was confirmed in 226 cases (the 54% of pleural exudative effusion). The majority are the result of metastases from primaries in the lung 114 (67%), when adenocarcinoma was most common with 96 cases, from breast 28 cases (16%),genito-urinary tract with 12 cases(7%),gastroenteric tract with 11cases (5%) , so representing with 168 cases il 74% of total malignancy. Mesothelioma was identifyed in 58 cases (26% of total malignancy, 38 male,20 female). Benign pleural effusion was detected in 189 patients (46% of pleural effusion): tubercolosis 25 (13%),pathological findings of non specific pleuritis 102 (53%), parapneumonic effusion 35 (18%), empyema 27 (14%).

Conclusions

The medical thoracoscopy is a relatively simple ,safe and effective examination for a definitive diagnosis of unknown aetiology pleural exudative effusion and should be performed as early as possible. Our most common minor complication was transient chest pain (50% of patients) for tube insertion of pleurodesis

19th WCBIP / WCBE World Congress
JOINT MEETING OF THE WORLD ASSOCIATION FOR BRONCHOLOGY AND INTERVENTIONAL PULMONOLOGY & THE INTERNATIONAL BRONCHOESOPHAGOLOGICAL SOCIETY
www.wcbipwcbe2016.org
Fortezza da Basso
May 8-11, 2016
Florence (Italy)

Successful bronchoscopic removal of endobronchial fibroepithelial polyp: A case report

Seung Hun Jang[1], Joo-hee Kim[1], Sunghoon Park[1], Yong Il Hwang[1], Ki-suck Jung[1], Jinwon Seo[2]

[1]Department of Pulmonary, Allergy and Critical Care Medicine, Hallym University Sacred Heart Hospital - South Korea
[2]Departments of Pathology, Hallym University Sacred Heart Hospital - South Korea

Introduction

Fibroepithelial polyps are a common type of tumor in the skin or genitourinary tract, but very rare in the tracheobronchial tree. Chronic inflammation has been suggested for its etiology. There is no consensus regarding the treatment of endobronchial fibroepithelial polyps. Basically, treatment varies according to the size and hardness of the lesion, bronchoscopic resection such as forceps biopsy, electrosurgical snare, cryotherapy, or endobronchial laser therapy was widely chosen. We report a bronchoscopic resection case of a small endobronchial fibroepithelial polyp.

Methods

A 31-year old woman without any respiratory symptoms was consulted to the department Pulmonary Medicine from the department of General Surgery. She underwent right thyroid lobectomy and isthmectomy two years ago because of papillary thyroid carcinoma (pT1aN0M0, stage I). Postoperative routine regular check-up with chest computed tomography (CT) detected a small endobronchial nodule (4mm diameter) in distal right lower lobar bronchus without lung atelectasis. The small nodule has also been present at the same location and size when we retrospectively reviewed PET-CT performed 1 year before. At fiberoptic bronchoscopic examination, an endobronchial lobulated and pedunculated polyp with white glossy surface was arising from the medial wall of distal right lower lobar bronchus. Its pedunculated portion was successfully resected by using biopsy forceps with minimal amount of bleeding. A histopathologic examination showed the specimen to be a small papillary polyp covered with flattend epithelium and mild subepithelial lymphocytic infiltration. The stromal component is composed of dense collagenous materials and scattered fibroblasts. The pathological diagnosis was fibroepithelial polyp. Follow up bronchoscopic examination at 1 week, the bronchial mucosa of the polyp-bed was under healing process without any complications, and follow up bronchoscopic examination at 6 months, the bronchial mucosa of the polyp-bed showed subtle scar without recurrence.

Conclusions

Fibroepithelial polyp is a rare endobronchial benign tumor. Although treatment varies according to the size, endobronchial resection is the treatment of choice in most cases. In this case, we presented a patient with small endobronchial fibroepithelial polyp which was successfully removed by using biopsy forceps with minimal amount of bleeding.

Bibliography

Li M, et al. Intern Med. 2013; 52:373-6.

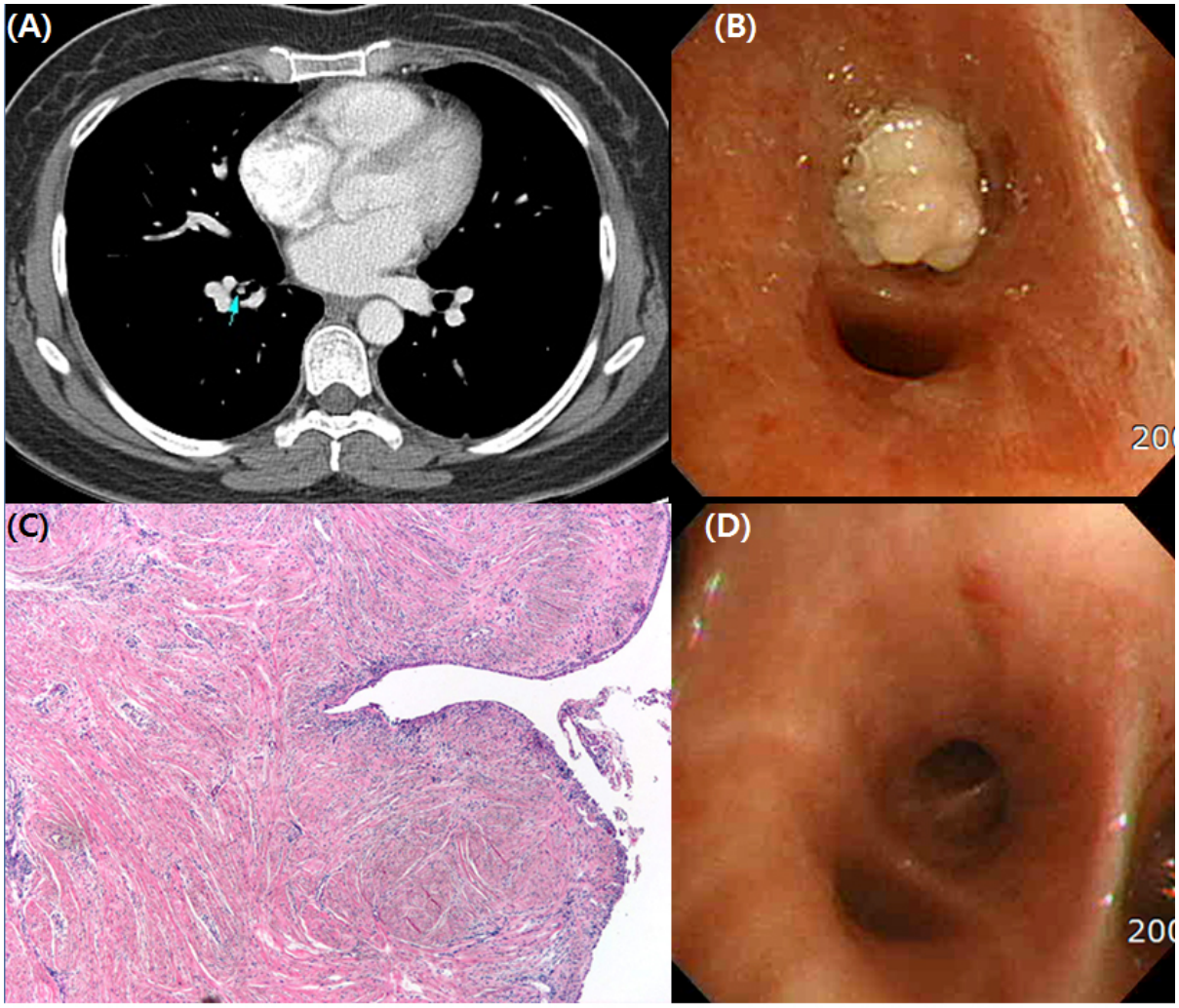

Figure 1. (A) A small nodule in the distal right lower lobar bronchus, (B) An endobronchial lobulated polyp with white glossy surface, (C) Polypoid lesion covered with flattend epithelium and mild subepithelial lymphocytic infiltration. The stromal component is composed of dense collagenous materials and scattered fibroblasts, hematoxylin and eosin staining (x40), (D) Follow up bronchoscopic finding at 6 months after removal of polyp.

Successful application of interventional bronchoscopy in management of a severe inhalation injury

Chengshui Chen, Yuping Li, Min Ye, Jinshen Ouyang, Yupeng Xie

Department of Pulmonary Medicine, The First Affiliated Hospital of Wenzhou Medical University - China

Introduction

Interventional bronchoscopy plays very important role in inhalation injury. But its application in severe inhalation injury with sulfuric acid induced airway stenosis is seldom reported. Currently,one case of inhalation injury with sulfuric acid induced severe airway stenosis have been reported,the patient was successfully treated with interventional bronchoscopy.

Objective

The aim is to validate the different interventional bronchoscopy procedures used for different stage in treatment of severe inhalation aiway stenosis.

Methods

A 40 years old male worker.On 19th December,2014,the patient accidentally fell into a tank filled with 30% sulfuric acid,he climbed out of the tank and with breathing difficulties. He was sent to our emergency department.Where he was given wound debridement and preventive tracheotomy.

Results

On 20th January 2015, patient developed dyspnea and received bronchoscopy examination, showed the tracheal mucosal edema and granulation profileration,the lumen was narrowed (Fig1),the right main bronchus was completely obstruction (Fig2).We resected the majority of pseudomembranes with cryotherapy,the airway lumen was significant stenosed (Fig3).His dyspnea improved partialy.On the 28th January 2015,He went into respiratory distress and confused, ABG showed: PH 7.09, PaCO2 90.2mmHg.He was received emergency bronchospy,after clean the psedomembrane,a temporary metallic stent was placed in the main brochus.His respiratory distress was resolved,however he still needed MV support.During follow ups,intralumen of trachea and right intermediate bronchus was progressive narrowed.Balloon dilatation was used to. On 9th February 2015,considered the patient intermediate bronchus was severe stenosis.The initial temporary stent was removed.A more long metallic stent was placed from the right main bronchus to the opening of right middle and lower lobe bronchus (Fig4).Followed bronchoscopy showed the middle area of trachea was narrowed (Fig5).On 4th march 2015,A tracheal Dumon stent was placed?Fig6).Afterwards the patient was sucessfully weaned off the ventilator.He improved and was followed-up by bronchoscopy,showed significant proliferation of the granulation in the proximal and distal area of the metal stent(Fig7, Fig8).On the 30th march,2015,the metal stent was removed,the airway of the right middle lobe segment and the right lower basal segment of the bronchus was dilatated ,after which a Dumon silicon stent was placed in the intermediate bronchus (Fig 9), a Y type Dumon silicon stent was placed in the bifurcation of trachea and bronchus(Fig10 Fig11).Fig12 shows initial Dumon trachea stent.Patient improved markedly.He was discharge and follow up bronchoscopy examinations in clinic.

Conclusions

Cryotherapy is the important therapy,Dumon silicone stent can be used carefully. An exact measurement of the stenoses should be considered to avoid aggravating mucosal damage and granulation hyperplasia.

Bibliography

Chong Bai,Haidong Huang,Xiaopeng Yao,et al. Application of flexible bronchoscopy in inhalation lung injury[J].Diagnostic Pathology 2013, 8:174

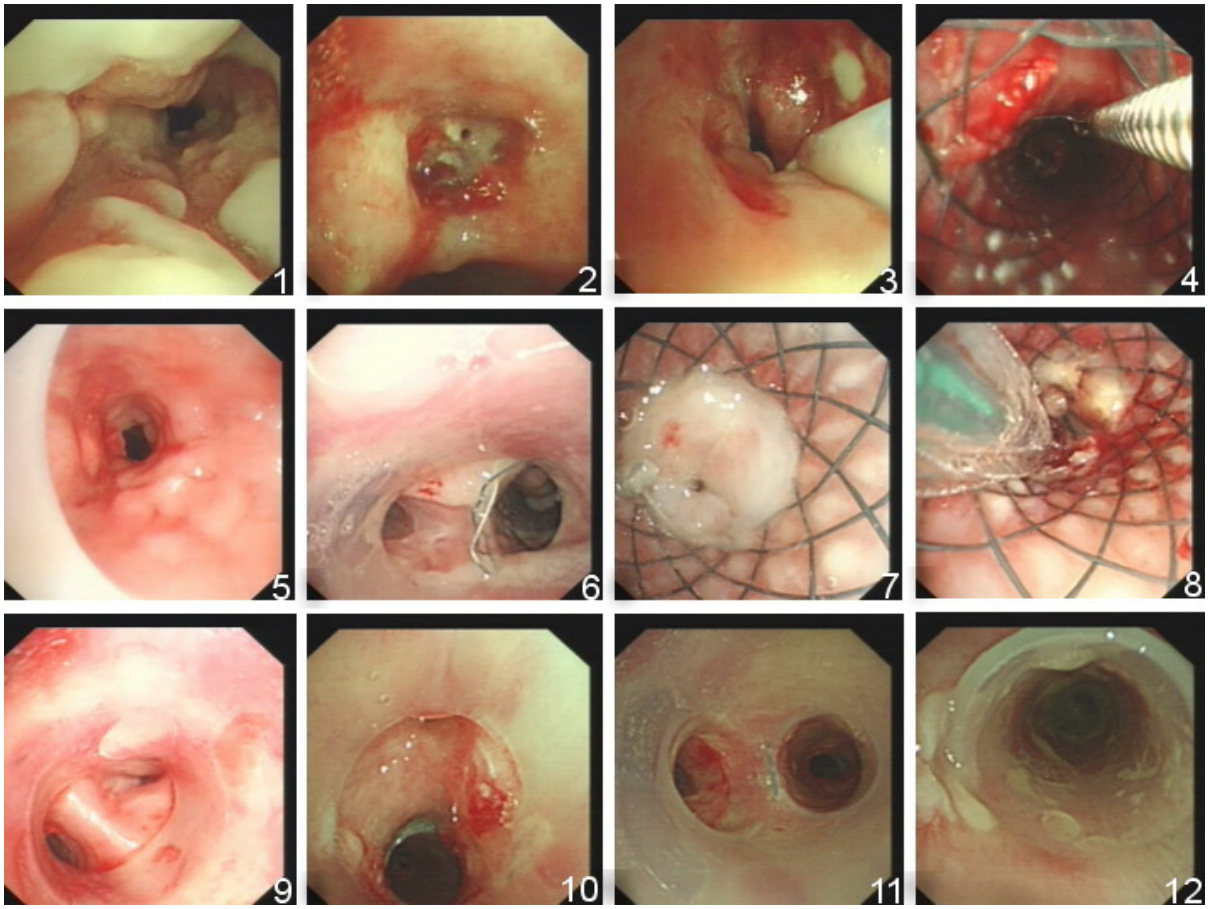

id 66

19th WCBIP / WCBE World Congress
JOINT MEETING OF THE WORLD ASSOCIATION FOR BRONCHOLOGY AND INTERVENTIONAL PULMONOLOGY & THE INTERNATIONAL BRONCHOESOPHAGOLOGICAL SOCIETY
www.wcbipwcbe2016.org
Fortezza da Basso
May 8-11, 2016
Florence (Italy)

Endoscopic placement of covered metallic stents and the observation of stent-related complications

Hongwu Wang

Pulmonary Dept, Meitan General Hospital - Pr China

Introduction

Stent has been widely used in China.It should be paid more attention to the complications which are quite different in early and late stage of intertion.

Objective

To observe sequentially the stent-related complications of covered metallic airway stents in patients with airway disorders for different stages of stenting.

Methods

A retrospective analysis of 47 patients with airway disorders was analysed, who presented with an indication for placement of covered metallic stents(CMS) in our hospital. 60 CMS had been placed guided by flexible bronchoscopy or / and fluroscopy. Argon plasma coagulation (APC), balloon dilatation, and CO2 cryoablation were given for the treatment of severe airway strictures prior to airway stenting in 38 patients,.

Results

28 CMS were eventually placed in 21 patients with benign airway disorders, and 32 CMS in 26 patients with malignant airway disorders. Secretions could been found in all patients after second day of stenting, severe mucus inflammation after 4 to 35 days. Granulation tissue happened after fourth day which was severer in patients with benign than those with malignant. Stent migration was found in patients with stenting less than 1 week. 54.5% of CMS was removed due to granulation tissue in 22 stents for retrieval in patients with benign, which average duration of stenting before removal was 1 month, while 196.9±56.6 days in another group of 10 patients for anticipated stent retrieval. Only 2 of 9 stents were removed for cure in patients with malignant after 4 months of stenting. The average duration of stenting before removal was 2 months in another 7 of 9 stents, while another 23 stents could not be retrieval for different reasons.

Conclusions

Secretion, mucus inflammation and stent migration were the common recent complications after stenting in both groups. Granulation tissue happened severely in patients with benign. Endoscopic examination should be given if necessary, especially less than 1 month.

Bibliography

1.Lund ME,etal Chest, 2007;131(2): 579-587 ,PMID: 17296664 2.Lemaire A, et al.Ann Thorac Surg, 2005;80:434-438

19th WCBIP / WCBE World Congress
JOINT MEETING OF THE WORLD ASSOCIATION FOR BRONCHOLOGY AND INTERVENTIONAL PULMONOLOGY & THE INTERNATIONAL BRONCHOESOPHAGOLOGICAL SOCIETY
www.wcbipwcbe2016.org
Fortezza da Basso
May 8-11, 2016
Florence (Italy)

Chinese Covered Metalic Stents for sealing of esophagorespiratory Fistulas

Hongwu Wang

Pulmonary Dept, Meitan General Hospital - Pr China

Introduction

Esophagorespiratory fistula (ERF) is the most common airway fistula?which is very difficult to be treated.

Objective

This study is to evaluate the safety and clinical efficacy of Chinese covered metallic stents (CMS) for sealing of airway fistulas.

Methods

76 Patients with 91 ERFs were retrospectively reviewed for the treatment of 81 CMS by the guidance of bronchoscopy or fluroscopy. The fistulas were caused by esophageal?n=56??bronchogenic (n = 13) and thyroid ?n=2?carcinomas and so on.

Results

There were 91 ERFs in 79patients with fistula size from 0.5 cm to 7.0cm. Most of ERFs were located in middle & lower trachea or bilateral bronchial orifices. 81 CMS ?56 Y-shaped ?11 L-shaped and 14 I-shaped?and 30 esophagus metal stents had been placed. The sealing effects of fistulas were complete response 4.9%? clinical complete response ? cCR?59.3%, partial response(PR) 24.7%, no response(NR) 11.1%. The effective rate was 88.9%.The median survival duration of all patients was 6 months.

Conclusions

The use of CZTS appears to be safe and feasible for the palliative treatment of ERF?BPF and TMF. Airway stent placement should be of choice in patients with ERF, and then esophagus stents should be given if airway stents were failed. Airway bifurcation stents were especially suitable for the sealing of fistulas near trachea carina.

Bibliography

1.Balazs A, et al.Eur J Cardiothorac Surg, 2008,34(5): 1103-1107. 2.Herth FJ, et al. Eur Respir J, 2010,36(6): 1370-1374

19th WCBIP / WCBE World Congress
JOINT MEETING OF THE WORLD ASSOCIATION FOR BRONCHOLOGY AND INTERVENTIONAL PULMONOLOGY & THE INTERNATIONAL BRONCHOESOPHAGOLOGICAL SOCIETY
www.wcbipwcbe2016.org
Fortezza da Basso
May 8-11, 2016
Florence (Italy)

Clinical implications of differentiating between the types of post-tracheostomy tracheal stenosis

Byeong-ho Jeong[1], Kang Kim[1], Beomsu Shin[1], Jung Seop Eom[2], Kyung-jong Lee[1], Sang-won Um[1], Hojoong Kim[1]

[1]Division of Pulmonary and Critical Care Medicine, Department of Medicine, Samsung Medical Center, Sungkyunkwan University School of Medicine - South Korea
[2]Department of Internal Medicine, Pusan National University School of Medicine - South Korea

Introduction

Post-tracheostomy tracheal stenosis (PTTS) can be divided into four subtypes according to the stenosis mechanism and site: subglottic, stoma, cuff, and tip granuloma. However, there is little information on the clinical differences of the subtypes of PTTS.

Objective

To evaluate the clinical differences of the subtypes of PTTS.

Methods

We retrospectively evaluated 88 patients of PTTS who underwent interventional bronchoscopy under general anesthesia between 2004 and 2013 at the Samsung Medical Center. Patients with PTTS were divided into three groups according to the pathophysiological similarity as follows: “subglottic or stoma type”, “cuff or tip granuloma type”, and “mixed type”. We compared the patient and stenosis characteristics, treatment modalities, and clinical outcomes between the subtypes of PTTS.

Results

From the 88 patients with PTTS, 48 (54%), 28 (32%), and 12 (14%) patients were classified to subglottic or stoma type, cuff or tip granuloma type, and mixed type, respectively. There were no differences in patient characteristics such as age, gender, and etiology of tracheostomy between the groups. Although the length and morphologies of stenosis were similar among the subtypes of PTTS, patients with mixed type PTTS tended to have more severe stenosis than those with the subglottic or stoma type or the cuff or tip granuloma type (patients with > 70% stenosis of the lumen; 100% vs. 87% vs. 75%, P = 0.112, respectively). Patients with the subglottic or stoma type required a greater number of silicone stents (81%) to maintain the airway patency than did those with the cuff or tip granuloma type (61%), or the mixed type (58%); however, there was no statistical significance (P = 0.081). Although there were no differences in the rates of complication and procedure- or disease-related death, patients with subglottic or stoma type had a more favorable outcome, measured by the successful removal of tracheostomy tube and closure of the stoma without surgical intervention or death, than did patients with cuff or tip granuloma type or mixed type (37/48 [77%] vs. 15/28 [54%] vs. 5/12 [42%], P = 0.023).

Conclusions

Although there were no significant differences in patient and stenosis characteristics among the subtypes of PTTS, patients with the mixed type had the worst clinical outcomes and patients with the subglottic or stoma type had the best clinical outcome. Therefore, it could be important to distinguish the subtypes of PTTS to assess clinical outcomes.

19th WCBIP / WCBE World Congress
JOINT MEETING OF THE WORLD ASSOCIATION FOR BRONCHOLOGY AND INTERVENTIONAL PULMONOLOGY & THE INTERNATIONAL BRONCHOESOPHAGOLOGICAL SOCIETY
www.wcbipwcbe2016.org
Fortezza da Basso
May 8-11, 2016
Florence (Italy)

Electrocautery and APC for the Therapy of Central Airway Tumor with Respiratory Insufficiency

Yi –ping Zhou, Xiao-ke Chen, Hui Liu, Li-ping Xia, Hai-qiong Yu, Nian Liu, Ai-fen Li, Hai-rong Lin

Department of respiration, Affiliated Shenzhen Futian Hospital of Guangdong Medical College - China

Introduction

Interventional broncoscopy is an important therapy for central airway tumor. As central airway tumor always complicated with respiratory insufficiency, the effect and safety of the procedure are both need to be considered.

Objective

To investigate the efficacy and safety of electrocautery and argon plasma coagulation(APC) for the therapy of central airway tumor with respiratory insufficiency.

Methods

To analyze the efficacy of electrocautery and APC for the therapy of 22 pathologically confirmed advanced central airway tumor with respiratory insufficiency from Sept 2010 to Oct 2015 in our hospital

Results

f the 22 patients with a total of 42 treatments, 8 patients and 8 periods in the operating room under general anesthesia; the other 34 periods were in the bronchoscopy room under potical anesthesia with sedation, 26 periods with assisted mechanical ventilation. Effective in 11 cases, partial response in 8 cases, Mild effective in 3 cases. Simultaneous photodynamic therapy in 6 cases, metal stent implantation in 4 case.

Conclusions

With the proper anesthesia and respiratory support, electrocautery and APC is a safe and effective method for central airway tumor with respiratory insufficiency. It is especially helpful to relieve the symptoms of respiratory insufficiency and improve the prognosis while combining with airway stenting and / or photodynamic therapy.

id 70

19th WCBIP / WCBE World Congress
JOINT MEETING OF THE WORLD ASSOCIATION FOR BRONCHOLOGY AND INTERVENTIONAL PULMONOLOGY & THE INTERNATIONAL BRONCHOESOPHAGOLOGICAL SOCIETY
www.wcbipwcbe2016.org
Fortezza da Basso
May 8-11, 2016
Florence (Italy)

Analysis of bedside bronchoscopy washing and lavage for the treatment of 702 critical care patients

Yi-ping Zhou, Xiao-ke Chen, Li-ping Xia, Ai-fen Li, Hui Liu, Hai-qiong Yu, Nian Liu

Department of respiration, Affiliated Shenzhen Futian Hospital of Guangdong Medical College - China

Introduction

Bedside bronchoscopy plays an inportant role in the management of critical care patients, especially infectious patients.Inhalation of Antibiotist has been used for the treatment of Pseudomonas aeruginosa in bronchiectasis patients. Will ciprofloxacin be used for bronchoscopy washing and lavage in infectious patients?

Objective

To investigate the clinical efficacy of bedside bronchoscopy washing and lavage for the treatment of critical care patients.

Methods

A retrospective analysis of the treatment, prognosis and adverse reactions of 846 cases of bedside bronchoscopy washing and lavage in 702 critical care patients from January 2002 to October 2015. The lavage fluid was ciprofloxacin (0.2%) fluid or sterile saline from 60ml to 100ml.

Results

Observation objects included 85 cases of cerebral trauma in 71 patients, 196 cases of chronic respiratory failure in 172 patients, 165 cases of severe pneumonia or severe pulmonary infection in 122 patients, 228 cases of cerebral vascular disease in 204 patients, 17 cases of nerve and muscle disease in 7 patients, 62 cases of tumor in 49 patients, 12 cases of buried pressure asphyxia or poisoning in 7 patients, 50 cases of post-chest/abdomen- operation in 48 patients, 26 cases of chest trauma in 24 patients, 5 cases of massive hemoptysis in 4 patients. The significant effective rate was 56.4% (396 /702), the effective rate was 41.2% (289 /702), , and 17 cases(2.4%) were ineffective,. No patient had serious adverse reactions associated with bronchoscopy.

Conclusions

The treatment of the patients with severe acute respiratory disease with bedside bronchoscopy washing and lavage is effective, which has a unique advantage in airway management and lower respiratory tract infection. Ciprofloxacin(0.2%) was convenient and safe for lavage, with good clinical efficacy.

Table 1. **Bedside bronchoscopy washing and lavage for the treatment of 702 critical care patients**

Primary disease	patients	cases	times								effect （patient，%）		
			1	2	3	4	5	6	7	13	effective	significant effective	no effect
cerebral vascular disease	204	228	189	10	3	1	0	1	0		74	130	0
chronic respiratory failure	172	196	153	15	3	1	0	0	0		96	69	7
severe pneumonia or severe pulmonary infection	122	165	98	15	8	0	0	0	0	1	48	70	4
cerebral trauma	71	85	61	8	1	0	1	0	0		27	44	0
post-chest/abdomen-operation	42	50	34	8	0	0	0	0	0		6	36	0
tumor	49	62	39	7	3	0	0	0	0		27	16	6
chest trauma	24	26	22	2	0	0	0	0	0		5	19	0
buried pressure asphyxia or poisoning	7	12	3	3	1	0	0	0	0		0	7	0
nerve and muscle disease	7	17	3	2	1	0	0	0	1		2	5	0
massive hemoptysis	4	5	3	1	0	0	0	0	0		4	0	0
total	702	846	605	71	20	2	1	1	1	1	289,41.2	396,56.4	17,2.4

id 71

19th WCBIP / WCBE World Congress
JOINT MEETING OF THE WORLD ASSOCIATION FOR BRONCHOLOGY AND INTERVENTIONAL PULMONOLOGY & THE INTERNATIONAL BRONCHOESOPHAGOLOGICAL SOCIETY
www.wcbipwcbe2016.org
Fortezza da Basso
May 8-11, 2016
Florence (Italy)

New combinations of photodynamic therapy for lung cancer

Andrey Akopov, Anatoly Rusanov, Nikita Kazakov, Andrey Gerasin, Ivan Chistiakov, Alexey Agishev, Margarita Urtenova, Aruldas Karlson

Department of Thoracic Surgery, Pavlov State Medical University - Russia

Introduction

Bronchoscopic photodynamic therapy (PDT) is well known method to relieve the symptoms of advanced central non-small cell lung cancer (NSCLC).

Objective

We discuss possibility of new combinations of PDT as a component of multidisciplinary treatment of NSCLC.

Methods

350 patients with locally advanced and metastatic NSCLC underwent endobronchial PDT in combination with: airway stenting (PDT “through the stent", 48 patients, 14%); argon-plasma coagulation (87 patients, 25%); laser ablation in an argon atmosphere (69 patients, 20%); chemo- and targeted therapy (329 patients, 94%); surgery (55 patients, 16%). Indications for PDT were obstructing central disease as well as local recurrence after surgical treatment (29 patients, 8%). In 55 patients with stage III (16%) preoperative PDT was done to facilitate surgical resection for initially borderline or irresectable (inoperable) NSCLC. PDT involved intravenous administration of chlorine E6 (Radachlorin) in the dose of 1 mg/kg followed by irradiation with 662 nm laser light up to a total dose of 100-130 J/cm2.

Results

Endobronchial tumor was localized in the right main bronchus in 42 (12%) patients, left main bronchus - in 29 (8%), tracheal bifurcation - in 62 (18%) and trachea - in 217 (62%) patients. The average duration of PDT session was 11,5 min. All PDT combinations were good tolerated. No patients had major complications. Of the 295 patients treated without resection, 41 achieved complete response (14%), 203 - partial response (69%), 51 - no response (17%). The one year survival rate for patients with stage III was 70%, stage IV – 56%, median survival -19 months. After neoadjuvant endobronchial PDT 51 patients of 55 operated (93%) underwent complete resection, 5-year survival rate for operated patients was 61%.

Conclusions

Combinations of PDT with drug and other endobronchial therapy are safe and effective options for advanced obstructing NSCLC. Bronchoscopic neoadjuvant PDT may also be used to convert to surgery candidates in stage III central NSCLC patients.

A novel method of endobronchial photodynamic theranostics for central non-small cell lung cancer

Anatoly Rusanov, Garry Papayan, Nikita Kazakov, Andrey Gerasin, Andrey Akopov

Department of Thoracic Surgery, Pavlov State Medical University - Russia

Introduction

Modern approaches to photodynamic therapy (PDT) do not take into account the biological characteristics of the tumor.

Objective

The aim of the study was to develop a personalized approach to the endobronchial PDT, taking into account the level of photosensitizer accumulation, more precise definition of the boundaries of tumor growth and irradiation dose.

Methods

Laser irradiation of 662 nm and 600-1000 ?W was transmitted in pulse mode with a duty cycle of 0,5 via quartz fiber inserted through the biopsy channel of the bronchoscope 2 to 3 h after administration of the photosensitizer (E6-chlorine, 1 mg/kg). At the same time photodynamic diagnostic (PDD) with SAFE-3000 and a diode laser (408 nm) through the same endoscope was done to define the tumor margin based on the red fluorescence emitted by the tumor. The intensity of red fluorescence was recorded during pauses between pulses of PDT irradiation and compared with its intensity just before the PDT. With the disappearance of the red fluorescence laser irradiation wavelength of 662 nm was interrupted and resumed in the recovery of red fluorescence to the original level. Antitumor effect was evaluated during a repeat endoscopy in 3 weeks.

Results

45 patients with stage III-IV central NSCLC underwent palliative PDT and PDD for tracheal/bronchial lumen recanalization. The histologic type of all of the cancers was squamous cell carcinoma. A clear fluorescence of the tumor observed in all cases except 2 (4%). Fluorescence in unexpected places of bronchial mucosa was recorded in 4 of 45 patients (9%), the presence of tumor in these zones confirmed histologically. The mean duration of irradiation before disappearance of the red fluorescence was 195±65 seconds (from 65 to 310), the time required for the red fluorescence recovery 105±15 seconds (from 75 to 130), the duration of re- irradiation 170±65 seconds (from 50 to 280). The average dose of energy during PDT was 95±20 J/cm2 (from 60 to 130). No complications were observed. After 3 weeks endobronchial complete and partial remission achieved in 8 (18%) and 35 (78%) patients, respectively. No effect occurred in 2 (4%) patients without red fluorescence in PDD.

Conclusions

A new method of endobronchial photodynamic theranostics was designed, which allows personalizing PDT by fluorescence monitoring of the irradiated tissue. In addition, in patients with luck of fluorescence PDT do not achieve any therapeutic effect.

19th WCBIP / WCBE World Congress
JOINT MEETING OF THE WORLD ASSOCIATION FOR BRONCHOLOGY AND INTERVENTIONAL PULMONOLOGY & THE INTERNATIONAL BRONCHOESOPHAGOLOGICAL SOCIETY
www.wcbipwcbe2016.org
Fortezza da Basso
May 8-11, 2016
Florence (Italy)

A web based multicenter and prospective EBUS-TBNA registry: a european evolutive experience

Legodec Julien[1], Fournier Clément[2], Flandes Javier[3], Vergnon Jean Michel[4], Escarguel Bruno[5]

[1]Pulmonology department, Sainte Anne Military Hospital - France
[2]Clinic of respiratory diseases, Hopital Calmette - France
[3]Pneumology department, Fundacion Jimenez Diaz - Spain
[4]Pneumology department, Hopital Nord - France
[5]Pneumology department, Hopital Saint Joseph - France

Introduction

French Health Authorities have recently officially approved utility of EBUS-TBNA for diagnostic or re-diagnostic strategy in oncology.

Objective

To argue this position, we assessed the feasibility of a web based prospective multi-institutional outcomes database of EBUS-TBNA procedures to document national activity. Actually in France, there is no such prospective registry for endoscopy.

Methods

We built a web site, called EBUS-DB.com. You need a login and a password to report prospectively all of your EBUS-TBNA procedures, thanks to 3 different stages: Stage 1 : you should complete general information of your procedure (name, date of the exam, indication, type of anesthesiology, complications) and specific information of each lymph node puncture (station, size, echography and elastography description). Stage 2 : as soon as reception of cytology results, you should complete diagnostic and rentability of your procedure for staging and/or for molecular tumor profile determination. Stage 3 : you still have all the time a free access to your personal outcomes database. This web based EBUS-TBNA registry was tested in 5 institutions in France and Spain, since January the 1st in 2012.

Results

Actually, a total of 1153 procedures were reported over the 3.5-year's period. That corresponds to 2134 lymph node punctures, majority under general sedation (64% vs 36%), with 31% in the 7 station, 36% in the 4 right (R) and left (L) stations, 17.5% in the 11 (R&L) stations. EBUS-TBNA is informative in 99%, confirms diagnostic in 95% and could determinate molecular status in 90% of NSCLC diagnostic. Since January the first in 2015, we report 6,25% of EGFR mutation and 2% of ALK translocation. Failure drivers analyses in 7%, mostly due to lake of cells. We report a 9% of complication rate, mostly haemorrhagic events in 4.3%.

Conclusions

This web based prospective data analysis of EBUS-TBNA procedures is completely innovating in France and Spain, feasible and valuable. Using this site is the very close to real life. We confirm once again that EBUS-TBNA still be recommended for diagnostic oncology strategies. Gradually, we saw that our practices, technics and point of view (biomarkers, complications) are still evaluating. We believe that our multi-institutional registry will be use for database collection, bench marking and quality improvement initiatives and for training purposes in the French fellowship programs (1,2). With the support of GELF, we progress to extend this database to other French and European EBUS-TBNA centres, and extend this registry to other advanced bronchoscopic procedures.

Bibliography

1. Eapen GA and al. Chest 2013 Apr ; 143 (4) : 1044-53 2. Yarmus LB and al. Chest 2013 Apr; 143(4) :1036-43

Polidocanol in endobronchial sealing of bronchopleural fistulae a phase 2 clinical trial

Bojan Zaric[1], Goran Stojanovic[2], Evica Budisin[2], Nensi Lalic[2], Aleksandar Tepavac[2], Marijela Potic[3], Branislav Perin[2]

[1]Clinic for Thoracic Oncology, Clinical Trials Unit, Respiratory Endoscopy Unit, Institute for Pulmonary Diseases of Vojvodina, Faculty of Medicine, University of Novi Sad - Serbia
[2]Clinic for Thoracic Oncology, Respiratory Endoscopy Unit, Institute for Pulmonary Diseases of Vojvodina, Faculty of Medicine, University of Novi Sad - Serbia
[3]Clinic for Thoracic Oncology, Department for Biostatistics, Institute for Pulmonary Diseases of Vojvodina, Faculty of Medicine, University of Novi Sad - Serbia

Introduction

Broncho-pleural fistula (BPF) is in most cases rare complication following thoracic surgery procedures. Numerous endobronchial and surgical procedures are available for BPF treatment. However, there is no consensus over most appropriate bronchoscopic treatment, and majority of data originate from case studies.

Objective

Primary objective of this trial was determination of safety and feasibility of endobronchial sealing of the BPF with 2% polidocanol. Secondary objective was determination of the procedural efficacy.

Methods

This was a phase II interventional trial that recruited 15 patients with BPF from September 2012 to October 2015. Endobronchial sealing was performed by submucosal application of 1-2 mL of 2% polidocanol through TNBA needle (NA-1C-1; Olympus Co. Tokyo, Japan). Bronchoscopy was performed in general anesthesia with jet-ventilation; videobronchoscope was inserted via rigid bronchoscope. Number of punctures and number of procedures were determined on case by case basis. Age, gender, smoking status, comorbitity, major type of comorbidity, definitive diagnosis, type of tumor, type of resection, size of the fistula, duration of intervention, number of punctures, localization of fistula, number of procedures, neoadjuvant therapy, time from surgery and time to closure were evaluated for multivariate analysis regarding efficacy.

Results

Incidence of BPF in investigated study population was 1.12%. Endobronchial sealing was accomplished in 80% (12/15) patients. Mean age of the patients was 54±16 years, mean size of fistulae 7±5.5 mm, duration of intervention 20±3 minutes, number of punctures 9±6, number of interventions 1.5, time from surgery 42±34 days, time to closure 10±9 days. In majority of patients age under 50 years, male gender, non-smoking status, absence of respiratory co-morbidity and lobectomy led to bronchoscopic sealing. Neoadjuvant therapy, shorter time from surgery and positive margins led to failure of bronchoscopic sealing. Size of fistula ($p=0.018$) and time to closure ($p=0.004$) were significantly correlated to success of bronchoscopic sealing. We did not observe any procedure-related adverse effects.

Conclusions

Endobronchial sealing with 2% polidocanol is safe, feasible and possibly very efficient technique for treatment of BPF.

id 75

Antimuscarinic bronchodilator response retained following targeted lung denervation in COPD

Coenraad F Koegelenberg[1], Johan Theron[2], Dirk-jan Slebos[3], Karin Klooster[3], Martin Mayse[4], Reinoud Gosens[5]

[1]Medicine, Stellenbosch University - South Africa
[2]Private Practice, Panorama MediClinic - South Africa
[3]Pulmonary Diseases, University of Groningen - The Netherlands
[4]Founder and Chief Technical Officer, Holaira, Inc - Usa
[5]Molecular Pharmacology, University of Groningen - The Netherlands

Introduction

Acetylcholine from parasympathetic nerves remains a well-validated target to treat patients with chronic obstructive pulmonary disease (COPD).[1] Targeted lung denervation (TLD) relies on bronchoscopic ablation of parasympathetic nerves along the main bronchi and was recently described as an adjunct in the management of with COPD.[2]

Objective

We aimed to investigate whether the antimuscarinic bronchodilator response would be retained following TLD.

Methods

In the first-in-man non-randomised, prospective, sequential, two-dose study (NCT01483534), TLD was performed on 22 patients with COPD who had a >=15% increase in forced expiratory volume in 1s (FEV1) following inhalation of 80?g ipratropium at baseline.[2] We specifically assessed the peak bronchodilator response (increase in FEV1) following inhalation of 80?g ipratropium which was performed as part of the study at 90, 180 and 365 days.

Results

The clinical safety pro?les were similar between the two energy doses.[2] The bronchodilator response achieved by 80 ?g ipratropium at peak at 90, 180 and 365 days after TLD is summarised in table 1 The greatest bronchodilator response was observed in patients treated with 20W, with a mean response of 355 mL (42.8%) at one year follow up. TLD plus ipratropium at peak was significantly different from TLD alone at all timepoints ($p<0.05$), and TLD plus ipratropium at peak and ipratropium pre-TLD at peak was significantly different from baseline (pre-TLD, off bronchodilators) at all timepoints ($p<0.05$).

Conclusions

Statistically significant and clinically important additive effects were observed when an inhaled anticholinergic drug was given in combination with TLD, suggesting that the bronchodilator response achieved by inhaled ipratropium at peak was not blunted in patients who underwent TLD. The greatest bronchodilator response was observed in patients treated with 20W.

Bibliography

1. Gosens R, Zaagsma J, Meurs H, Halayko AJ. Respir Res. 2006;7:73. 2. Slebos DJ, Klooster K, Koegelenberg CF, et al. Thorax. 2015;70:411-419

Table 1: The bronchodilator response achieved by 80 µg ipratropium at peak at 90, 180 and 365 days after TLD

			Pre-TLD	90 days	180 days	365 days
20W	TLD alone (off bronchodilators)	Change (L)	---	0.085 ± 0.073	0.098 ± 0.070	0.049 ± 0.088
		Change (%)	---	12.5% ± 7.8%	13.5% ± 7.2%	11.6% ± 10.2%
	TLD plus Ipratropium at peak	Change (L)	0.265 ± 0.043	0.316 ± 0.058	0.259 ± 0.089	0.355 ± 0.074
		Change (%)	28.2% ± 2.5%	36.7% ± 4.9%	29.6% ± 7.5%	42.8% ± 6.5%
15W	TLD alone (off bronchodilators)	Change (L)	---	0.030 ± 0.039	0.079 ± 0.052	-0.001 ± 0.043
		Change (%)	---	2.9% ± 4.7%	9.6% ± 5.8%	0.0% ± 4.8%
	TLD plus Ipratropium at peak	Change (L)	0.166 ± 0.011	0.232 ± 0.042	0.210 ± 0.031	0.123 ± 0.045
		Change (%)	19.8% ± 0.6%	27.9% ± 5.8%	24.5% ± 4.0%	15.0% ± 4.8%

Data shown as average ± SEM

id 76

19th WCBIP / WCBE World Congress
JOINT MEETING OF THE WORLD ASSOCIATION FOR BRONCHOLOGY AND INTERVENTIONAL PULMONOLOGY & THE INTERNATIONAL BRONCHOESOPHAGOLOGICAL SOCIETY
www.wcbipwcbe2016.org
Fortezza da Basso
May 8-11, 2016
Florence (Italy)

A carcinoid tumor case with diffuse endobronchial and distant metastasis

Cengiz Ozdemir[1], Sinem Sokucu[1], Nihal Genis[1], Seda Tural Onur[1], Songul Buyukkale[2], Levent Karasulu[1], Levent Dalar[3]

[1]Pulmonology, Yedikule Chest Disease and Chest Surgery Training and Research Hospital - Turkey
[2]Chest Surgery, Yedikule Chest Disease and Chest Surgery Training and Research Hospital - Turkey
[3]Pulmonology, Bilim University - Turkey

Introduction

Some of the carcinoid tumors can show an agressive behaviour and close follow up is important in these tumors. Although definition of typical and atypical carcinoid tumors are different pathologically, in some tumors it is hard to make this differentiation. A carcinoid tumor case operated 5 year ago presented with diffuse endobronchial involvement and distant metastasis is presented

Methods

45 years old male patient have undergone left upper lobectomy after diagnosis of typical carcinoid tumor bronchoscopically and having no other distant metastasis 5 years ago. Pathological diagnosis of the resection material confirmed typical carcinoid tumor. In the fifth year follow up of the patient bone and liver metastasis was detected. Patient also have recently developped dispnea. Malign airway obstruction was detected radiologically and in the rigid bronchoscopy, grape like clusters of noduler infiltration starting 5 cm after the vocal cords with 3 cm in length and 80% obstructing the airway lumen was observed. The infiltration also involves right lateral wall until right main bronchus. Carina was also involved. When entered right main bronchus, airway is obstructed 70% with endobronchial iniltration. Left main bronchus is patent, upper lobe entrance ended as a squat due to operation and lower lobe entrance is 70% obstructed with endobronchial infiltration. Both lower lobe segment bronchus are open after the obstructed areas are passed with fiberoptic bronchoscopy (right figure). Lesions located at the trachea were desobstructed after coagulated by diode laser. Nearly a full patency of the airway was optained. Lesions located at the distal of the left main bronchus and at the entrance of the left lower lobe were taken out by cryoprobe after coagulated by argon plasma coagulation. Nearly a full patency was optained in the entrance of left lower lobe bronchus. Hemorragic lesion obstructing right main bronchus was coagulated by APC and then tissue residuals were taken out (left figure). In the follow up of the patient, dispne complaint was regressed. Patient is in our follow up with no active respiratory complaints.

Conclusions

Carcinoid tumors are divided into two groups as tyical and atypical. They have different malignity potential. If the mitosis number is above 20 and Ki 67 index is more then 20% then the tumor belongs to the malign group. Main treatment is surgery. Survival is significantly different in typical carcinoids compared to atypical carcinoids. We would like to present a case of carcinoid tumor with agressive behaviour and its endobronchial treatment palliatively.

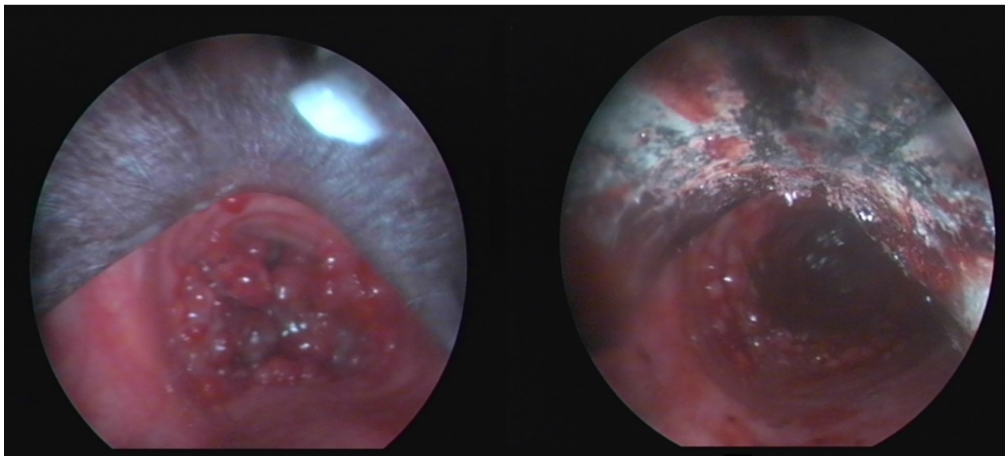

19th WCBIP / WCBE World Congress
JOINT MEETING OF THE WORLD ASSOCIATION FOR BRONCHOLOGY AND INTERVENTIONAL PULMONOLOGY & THE INTERNATIONAL BRONCHOESOPHAGOLOGICAL SOCIETY
www.wcbipwcbe2016.org
Fortezza da Basso
May 8-11, 2016
Florence (Italy)

Rigid bronchoscopy for the treatment of 2426 cases with central airway diseases

Hongwu Wang

Pulmonary Dept, Meitan General Hospital - Pr China

Introduction

Rigid bronchoscopy has been widely used in interventional bronchoscopy. The indication and contraindication have been controversed in recent years.

Objective

To explore the clinical applications of rigid bronchoscopy for the treatment of central airway diseases

Methods

We retrospectively reviewed the data that rigid bronchoscopy was performed in 1307 cases with 2426 procedures under general anaesthesia.The age was 53.2±1.7 years old.

Results

2426 rigid bronchoscopies was successfully performed in 1307 cases with central airway diseases including 1034 malignant noeplasmas with 1947 bronchoscopic procedures and 273 benign airway disorders with 479 procedures. The most common lesions were located in major airway. The complications were less common, which including incubation failures and throat edema in 8 (0.3%) patients,respectively,then laryngeal mask was exchanged.Teeth were lost in 6 (0.2%). Vocal damage and upper segment of trachea were injured in 10 (0.4%).No death occured during procedure.

Conclusions

Rigid bronchoscopy is indicated for the treatment of complex or difficult airway diseases. It is safe and rapid during procedure.

Bibliography

1.Fortin,et al. Can Respir J,2015;22(4):235-236 2.Hongwu Wang, et al. J Bronchol Intervent Pulmonol, 2010;18(1):31-37

19th WCBIP / WCBE World Congress
JOINT MEETING OF THE WORLD ASSOCIATION FOR BRONCHOLOGY AND INTERVENTIONAL PULMONOLOGY & THE INTERNATIONAL BRONCHOESOPHAGOLOGICAL SOCIETY
www.wcbipwcbe2016.org
Fortezza da Basso
May 8-11, 2016
Florence (Italy)

The results of interventional bronchoscopy in the treatment of benign and malignant central airway s

Quyet Do[1], Thang Ta Ba[2]

[1]Respiratory diseases, Vietnam military medical university - Vietnam
[2]Lung disease and tuberculosis, 103 hospital-Vietnam military medical university - Vietnam

Introduction

Interventional bronchoscopy is one of the basic and effective methods in the treatment of central airway stenosis due to benign and malignant causes.

Objective

To assess the initial results of interventional bronchoscopy in the treatment of central airway stenosis due to lung cancer and benign causes (post of endobronchial tuberculosis, endotracheal intubation and tracheostomy).

Methods

30 patients were diagnosed tracheal and bronchial stenosis due to lung cancer and the sequelaes of endobronchial tuberculosis, endotracheal intubation and tracheostomy. Patients were evaluated by multislice computed tomography scanner, virtual endobronchoscopy and flexible bronchoscopy; patients were carried out rigid bronchoscope with tracheo-bronchial dilatation, laser resection and silicone stent placement. To assess the early results of interventional bronchoscopy by the change of the clinical symptoms, chest X- ray and bronchoscopy images; FEV1, FVC, arterial blood gases and complications in the first week.

Results

There were 11 patients with tracheal stenosis, 19 patients with one side main bronchial stenosis; 10 benign cases (3/10 post endobronchial tuberculosis, 7/10 post intubation and tracheostomy) and 20 malignant cases due to lung cancer. Types of stenosis included: intraluminar tumour (66.7%), hour glass (26.6%) and web-like stenosis (6.7%). The level of stenosis: severe (53.4%), moderate (40%) and mild (6.6%). Laser therapy and dilatation were conducted in 100% of patients. Silicone stent placement was performed for 28 patients. After 1 week of intervantional endoscopy, the rate of patient out of dyspnea, blood cough and obstructive pneumonia; lung collapse on chest X-ray and local inflammatory were 73.3%, 100%, 88.8% and 90% respectively. The average value of FVC and FEV1 after the intervention increased significantly compared with before treatment (78.6 ± 9.59% vs 67.3 ± 8.63% and 72.27 ± 17.77% vs 61.18 ± 19.68% of predicted) ($p < 0.05$). The average value of PaO_2 and SaO_2 after the intervention improved significantly compared with before treatment (87.0 ± 9.55 mmHg vs 75.53 ± 11.51 mmHg and 84.0 ± 9.55 mmHg vs 75.53 ± 11,51mmHg) ($p<0.05$). The rate of early complication was 6.6%, including 1 patient with respiratory failure and 1 patient with stent migration.

Conclusions

Interventional bronchoscopy in treatment of central airway stenosis due to lung cancer and benign causes is a safe technique with initial good results.

Bibliography

1. Dutau H., Breen D.P., Endobronchial laser treatment: an essential tool in therapeutic bronchoscopy, Eur Respir Mon, 2010, 48, 1–12.

19th WCBIP / WCBE World Congress
JOINT MEETING OF THE WORLD ASSOCIATION FOR BRONCHOLOGY AND INTERVENTIONAL PULMONOLOGY & THE INTERNATIONAL BRONCHOESOPHAGOLOGICAL SOCIETY
www.wcbipwcbe2016.org
Fortezza da Basso
May 8-11, 2016
Florence (Italy)

Altered Airway Histology in Asthma Patients after Bronchial Thermoplasty

Alex Chee[1], Austin Laing[2], Alain Tremblay[1], Margaret Kelly[2], Paul Maceachern[1], Elaine Dumoulin[1], Christopher Hergott[1], Richard Leigh[1]

[1]Medicine, University of Calgary - Canada
[2]Pathology, University of Calgary - Canada

Introduction

Although bronchial thermoplasty has shown a reduction in severe exacerbation rates and improvement in quality of life in patients with moderate-severe asthma, there remain questions about the histologic process of the device.Canine models have shown that bronchial thermoplasty results in long- term abolition of airway smooth muscle and observation has been extrapolated to the human population to provide a mechanism to explain symptom improvement in patients. However there currently is limited evidence of this mechanism in humans with asthma. We hypothesize that bronchial thermoplasty results in prolonged histologic and symptom improvement in patients with moderate-severe asthma.

Objective

The aim of our study was to determine whether asthma patients had a long-term change in airway history after bronchial thermoplasty.

Methods

We performed a single center, prospective study of six patients with severe asthma who underwent bronchial thermoplasty. Our primary study outcome was the presence of deep tissue structures in biopsy samples, using both flexible forceps biopsy and flexible cryobiopsy. This was assessed by obtaining endobronchial biopsies of airways of asthmatic patients.On the first(pre-RLL bronchial thermoplasty) bronchoscopy, forceps and cryobiopsy samples were taken from the left lower lobe. Biopsy #2 was taken from the right lower lobe at bronchoscopy #3(bronchial thermoplasty bilateral upper lobes). Biopsy #3 was taken of the right lower lobe one year after initial bronchial thermoplasty. Specimens were stained to identify smooth muscle area, collagen deposition from fibrosis, and submucosal glands. Morphometric data (airway wall area, smooth muscle area [as a percent of airway wall], and submucosal gland area[percent of airway wall]) were analyzed using ImageJ™ software. Secondary outcome data included change in Asthma Quality of Life score.

Results

There was no significant difference in bleeding or other complications between cryobiopsy and forceps biopsy procedures. Although the sample size was small, there was a trend towards decreased airway smooth muscle area that persisted after one year. There was no change in submucosal gland area.

Conclusions

There is early evidence that airway smooth muscle is decreased in asthma patients after bronchial thermoplasty. Bronchoscopic cryobiopsy is also a useful tool for airway histology. Additional samples are required before larger conclusions are made.

Bibliography

Danek CJ, Lombard CM, Dungworth DL et al. J Appl Physiol. 2004;97:1946-1953. Castro M, Rubin AS, Laviolette M et al.Am J Respir Crit Care Med. 2010;181:116-124.

19th WCBIP / WCBE World Congress
JOINT MEETING OF THE WORLD ASSOCIATION FOR BRONCHOLOGY AND INTERVENTIONAL PULMONOLOGY & THE INTERNATIONAL BRONCHOESOPHAGOLOGICAL SOCIETY
www.wcbipwcbe2016.org
Fortezza da Basso
May 8-11, 2016
Florence (Italy)

New 3D «All in 1» device for fiducial tumor marking: a pilot animal study

Bruno Escarguel[1], Jean-baptiste Paoli[1], Olivier Mallet[2], Javier Flandes[3], Stephane Coulmain[4], Julien Legodec[1], Clément Fournier[5], Jean-michel Vergnon[6]

[1]Pneumology, Hopital Saint Joseph - France
[2]Radiology, Hopital Saint Joseph - France
[3]Pneumology, Fundacion Jimenez Diaz - Spain
[4]Pneumology, Hopital Sainte Musse - France
[5]Pneumology, Hopital Calmette - France
[6]Pneumology, Hopital Nord - France

Introduction

Malignant lung lesions are commonly treated with stereotactic body radiotherapy e.g. Cyberknife®. However, a common problem of existing markers is migration which requires placement of several devices (usually 3). This study presents the results of a first animal evaluation of a new device that comprises several markers in a single implant device, which can be placed in a one-step bronchoscopic procedure.

Objective

The purpose of the study was to demonstrate feasibility of a new « All in 1 » shape memory (Novatech®) Nitinol (Ni–Ti) device with Tantalum (Ta) markers, with safety and efficacy as key points, in a porcine model.

Methods

Devices: 55 devices with 3 different shapes were used to determine the best design to reduce the migration risk. Animals: 2 series with a total of 8 Piétrain pigs, 5 animals for safety and 3 animals for efficacy evaluation using flexible bronchoscopy under general anesthesia. Follow-up period: 4 weeks. Image based analysis: CT scans pre- and post-procedure, after 2 and 4 weeks. Procedure: The markers where launched in different peripheral sub-segments using a radial EBUS guide sheath (Olympus® K- 201) under fluoroscopy control. Evaluation: Procedure time, ease of placement, blinded CT scan analyses for evaluation of migration, complications and histological analysis.

Results

All 55 devices were easily inserted into the peripheral bronchi. All devices could be visualized under fluoroscopy. The average procedure time was 5 min (+/- 2,6). 5 devices per animal were inserted in the first series and 10 devices per animal in the second series. During the 4 weeks clinical follow up and CT evaluation, no immediate or late complication occurred (pneumothorax, pneumonia, severe granulations or bleedings) in the first series. One partial (<20%) pneumothorax with spontaneous remission occurred in the second series due to forceful reintubation of the pig after accidental extubation. Migration has been seen in some pigs of the first series but not in the second series. No device related complications have been noted.

Conclusions

In this pilot animal study the new « all in 1 » device for fiducial tumor marking was easy, quick and safe to use. It could be demonstrated that migration risk can be reduced with the right design.

The presenting author has the following conflicts of interest that relate to this abstract: *Educational support by Novatech Educational support by Olympus*

19th WCBIP / WCBE World Congress
JOINT MEETING OF THE WORLD ASSOCIATION FOR BRONCHOLOGY AND INTERVENTIONAL PULMONOLOGY & THE INTERNATIONAL BRONCHOESOPHAGOLOGICAL SOCIETY
www.wcbipwcbe2016.org
Fortezza da Basso
May 8-11, 2016
Florence (Italy)

Multimodal bronchoscopy diagnostics and treatment of the early central lung cancer

Viktor Sokolov[1], Dmitry Sokolov[1], Larisa Telegina[1], Raisa Yakubovskaya[2], Tatiana Karmakova[2], Nadezhda Volchenko[3], Andrey Kaprin[4]

[1]Endoscopy, P.A. Herzen Moscow Oncological Research Institute - division of National Medical Scientific Radiological Center - Russian Federation
[2]Experimental, P.A. Herzen Moscow Oncological Research Institute - division of National Medical Scientific Radiological Center - Russian Federation
[3]Pathomorphology, P.A. Herzen Moscow Oncological Research Institute - division of National Medical Scientific Radiological Center - Russian Federation
[4]General director, P.A. Herzen Moscow Oncological Research Institute - division of National Medical Scientific Radiological Center - Russian Federation

Objective

The objective of the given research is the developing and improving the bronchoscopy diagnostics and treatment techniques in case of occult early central lung cancer.

Methods

In our clinic, over the past 30 years it was examined more than 16 000 patients at high risk of lung cancer. From 1984 through 2015 176 of early central lung cancer (ECLC) was found in 128 patients. X-ray negative ECLC was in 96% of patients. It was investigated possibilities of different variants of multimodal bronchoscopy (WLI, AFI, NBI, LFS, iHb, i-scane) and in immunocytochemical (MUC 1) diagnostics of ECLC in comparison with routine examination. In July 2015, in our clinic started experimental studies use confocal laser endomicroscopy and endocytoscopy in the diagnosis ECLC. All patients with ECLC (176 tumors) had been treated with endobronchial therapies (Nd:YAG laser, electrocautery, argon-plasma coagulation and photodynamic therapy).

Results

Sensitivity and specificity using a multimodal bronchoscopy to detect occult ECLC exceeded 90%. When using endobronchial therapies for ECLC complete response was observed in 157 of the 176 early carcinomas (89%), for tumors ? 1 cm in size complete response rate was 100%.

Conclusions

Multimodal endoscopical and immunocytochemical diagnostics increases the efficiency in detecting occult ECLC, while the suggested techniques of endobronchial treatment increase the number of cured patients.

id 82

EBUS and EUS for primary and metastatic thoracic tumors

Viktor Sokolov[1], Dmitry Sokolov[1], Larisa Telegina[1], Oleg Pikin[2], Nadezhda Volchenko[3], Andrey Kaprin[4]

[1]Endoscopy, P.A. Herzen Moscow Oncological Research Institute - division of National Medical Scientific Radiological Center - Russian Federation
[2]Thoracic Surgery, P.A. Herzen Moscow Oncological Research Institute - division of National Medical Scientific Radiological Center - Russian Federation
[3]Pathomorphology, P.A. Herzen Moscow Oncological Research Institute - division of National Medical Scientific Radiological Center - Russian Federation
[4]General director, P.A. Herzen Moscow Oncological Research Institute - division of National Medical Scientific Radiological Center - Russian Federation

Objective

To analyze results of combined transbronchial and transesophageal ultrasonography (EBUS and EUS) with fine-needle aspiration (FNA) of intrathoracic lymph nodes and mediastinal tumors in advanced cancer diagnostics and staging.

Methods

Endoscopic ultrasonography of intrathoracic lesions was performed from 2007 till 2015 in 562 patients with the preliminary diagnosis as follows: peripheral (150) and central (303) lung cancer; mediastinal tumors (62); suspected metastases of non-thoracic cancers into intrathoracic lymph nodes (47). EBUS and EUS were performed without FNA in 182 patients to define tumor spreading in thoracic cavity. Tumor invasion of the trachea and bronchi (63), pulmonary artery and/or vein (32), esophagus (21), atrium (18), aorta (11) and metastases in mediastinal lymph nodes (37). In 380 patients EBUS and EUS was combined with FNA of intrathoracic lymph nodes and mediastinal tumors. Bifurcation, bronchopulmonary, paratracheal lymph nodes and mediastinal tumors were punctured in 76, 67, 46 and 38 cases respectively. FNA for two groups of lymph nodes was performed in 52, while more than two groups were punctured in 38 patients. In 63 patients (16%) the FNA was performed at EUS and EBUS procedure.

Results

Overall diagnostic efficiency of EBUS-FNA and EUS-FNA in tumor verification was 86%. Combination EBUS and EUS improves the efficiency of diagnosis in 9%. Metastatic squamous cell cancer in lymph nodes was confirmed in 104, small-celled cancer – in 63, adenocarcinoma of the lung in 105 from 318 lung cancer patients. Kidney cancer metastases (14), breast cancer metastases (14), colon cancer metastases (12), thyroid cancer metastases (12) and metastases of chondrosarcoma (2) into intrathoracic lymph nodes were confirmed. Lung cancer stage by N criteria was changed in 73 patients (N1?N2 in 52; N2?N3 in 21) after endoscopic ultrasonography. No complications were confirmed during and after these procedures.

Conclusions

EBUS-FNA and EUS-FNA is a high-precise procedure for thoracic tumors diagnostics, especially - lung cancer. EBUS-FNA increases accuracy of the lung cancer staging, particularly by N criteria. EBUS and EUS combination increases the effectiveness of diagnosis.

id 83

19th WCBIP / WCBE World Congress
JOINT MEETING OF THE WORLD ASSOCIATION FOR BRONCHOLOGY AND INTERVENTIONAL PULMONOLOGY & THE INTERNATIONAL BRONCHOESOPHAGOLOGICAL SOCIETY
www.wcbipwcbe2016.org
Fortezza da Basso
May 8-11, 2016
Florence (Italy)

Brachytherapy endobronchial in the treatment of cancer of the airway

Alberto González Estébanez, Francisco R. Villegas Fernández, Sergio Campos Téllez, María Castro Otero, Andrés Rodero Baño

Pneumology, Defense Central Hospital ¨Gómez Ulla¨. - Spain

Introduction

Brachytherapy (Bt) is a word of Greek origin (brachy: short) which refers to the small distance between the radioactive source and the tumor to irradiate. The Bt endobronchial with high dose rate (HDR) is defined, according to the International Commission of radiation units, such as the implementation of more than 20 cGy per minute (1 rad = 1 cGy). Our Hospital is a centre of reference at the national level in the application of this therapy, being at present one of the Pneumology Service of the country with more experience in such treatment.

Objective

The main objective of this study is to evaluate the efficacy and safety of the technique according to our current methodology which involves variations on the total dose administered according to specific pathology.

Methods

Retrospective and descriptive studies collected from the patients listed in the registry in the Central Defense Hospital Gómez Ulla endobronchial brachytherapy treatments between November 2013 and August 2014

Results

Dealt with a total of 11 patients, 49 session, 9 male (81.8%), with Diagnostics: Bronchogenic carcinoma (n = 8); 6 scaly 6, 1 adenocarcinoma, 1 carcinoma adenoid cystic of trachea and 1 tumor sarcomatoid and metastatic 2 (18.2%); 1 colonic adenocarcinoma and renal clear cell 1. Of treatments have had a unique mild immediate complication (bronchospasm crisis) and no late. The 11 patients are derived from other centres of the public health system.

Conclusions

This modality of treatment endobronchial brings together several very advantageous features: decreases complications by overdosing in healthy tissue by concentrating the effective radiation dose in the area of bronchial injury and reduces treatment time, making the hospital stay minimum, in regime of hospital of day, with the consequent reduction of costs. In addition, with our treatment protocol, it presents few side effects, very rarely serious. In short, this radiation mode allows to give a high dose in a very short time, making cheap, short, tolerable and safe technique.

Bibliography

1. Escobar Sacristán J. A., et al Eur Respir J 2004; 24: 348-352. 2. Dagnault A, et al Brachytherapy 9 (2010) 243-247.

19th WCBIP / WCBE World Congress
JOINT MEETING OF THE WORLD ASSOCIATION FOR BRONCHOLOGY AND INTERVENTIONAL PULMONOLOGY & THE INTERNATIONAL BRONCHOESOPHAGOLOGICAL SOCIETY
www.wcbipwcbe2016.org
Fortezza da Basso
May 8-11, 2016
Florence (Italy)

Invasive diagnosis in a series of pulmonary peripheral lesions

Giovanni Trucco, Alberto Bordo, Claudio De Michelis, Luigi Di Stefano, Patrizia Zoccali

Interventional Pneumology, Hospital - Italy

Introduction

Pulmonary diseases, both malignant and benign, can show themselves on CT scan as peripheral pulmonary lesions. Their diagnosis can be conduced using different methods.

Objective

Our goal was to value the different interventional procedures and their role in the diagnostic management of pulmonary peripheral lesions which do not involve the main or segmentary or subsegmentary bronchi and the hilar region: theorically not visible lesions with endoscopic procedures.

Methods

In the period between 2011 and 2015 we valued 159 patients who underwent invasive procedures by means of bronchoscopy or PCNA (transthoracic percutaneous needle aspiration). The radiological abnormalities found were: peripheral nodules; pulmonary masses; alveolar-interstitial opacities. A bronchoscopy with different sampling methods was performed to face lesions in contact with the bronchial tree, while peripheral lesions were studied by means of a CT-guided PCNA.

Results

The radiological abnormalities found were divided in this way: 61 peripheral nodules, 75 pulmonary masses, 23 alveolar-interstitial opacities. In 117 patients was performed a bronchoscopy (96 fluoroscopy guided, 21 with the electromagnetic navigation endobronchial system- ENB); 28 cases were faced with a CT-guided PCNA; 15 patients underwent both the endoscopic and transthoracic procedures. At the end of our diagnostic management (clinical, interventional and radiological) 127 patients received an oncological diagnosis:103 of them were studied with bronchoscopy. Bronchoscopy resulted to be a diagnostic exam in the 76% of the oncological patients. Furthermore the endoscopic inspection allowed to highlight 10 endoscopic findings which were not visible on CT scan previously. 38 patients with oncological diagnosis underwent a PCNA and this technique resulted to be diagnostic in 92% of them. In 28 of the total 159 patients studied we obtained a benign diagnosis. Bronchoscopy was diagnostic in 9 patients

Conclusions

In conclusion of our study we can assert that • Transthoracic percutaneous techniques have a real good yeld in peripheral lesions • Bronchoscopy however must be performed in every case because it has a good diagnostic yeld ant it can allow to see unexpected lesions and furthermore it is a powerful tool in mediastinal stadiation. • Electromagnetical endobronchial navigation system (ENB) did not show a satisfactory diagnostic yeld; its role should be defined with more accurate indications. • Invasive techniques showed a better diagnostic yeld in malignant diseaes than in benign ones

19th WCBIP / WCBE World Congress
JOINT MEETING OF THE WORLD ASSOCIATION FOR BRONCHOLOGY AND INTERVENTIONAL PULMONOLOGY & THE INTERNATIONAL BRONCHOESOPHAGOLOGICAL SOCIETY
www.wcbipwcbe2016.org
Fortezza da Basso
May 8-11, 2016
Florence (Italy)

Endoscopic laryngo-pharyngeal surgery for superficial hypopharyngeal carcinoma

Yosuke Nakanishi, Yoshiya Kasahara, Shigeyuki Murono, Tomokazu Yoshizaki

Otorhinolaryngology, Head and Neck Surgery, Kanazawa University - Japan

Introduction

Endoscopic laryngo pharyngeal surgery (ELPS) , which is a hybrid of head & neck surgery and gastrointestinal endoscopic treatment, for laryngo-pharyngeal cancer has been used as a novel procedure for squamous cell carcinoma of the laryngopharyngeal cancers with encouraging outcomes. We report a series of patients with hypopharyngeal carcinoma treated with primary ELPS. All ELPS resections were completed without any intraoperative complication.

Objective

In this retrospective cohort study, we evaluated the oncological and functional outcomes of ELPS.

Methods

Nine consecutive patients with T1 or T2 pharyngeal squamous cell carcinomas are included in this study from 2013 to 2015. Under general anesthesia, a specially designed curved laryngoscope was used to create a working space in the pharyngeal lumen. Gastrointestinal enoscope was inserted transorally to visualize the field by gastroenterologist, and head & neck surgeon dissected the lesion using curved forceps and high frequency electric knife. In principle, node positive patients underwent a simultaneous neck dissection.

Results

Median operation time per lesion was 108 min. The median times before patients could resume eating were 4 days. The mean length of hospitalization was 20 days. There is no local reccurence occurred.

Conclusions

ELPS is a satisfactory and minimally invasive treatment option for pharyngeal cancers.

id 86

Laryngeal preservation and function after Modified RADPLAT for advanced laryngeal carcinoma

Tomokazu Yoshizaki, Shigeyuki Murono, Yosuke Nakanishi

Otolaryngology-Head and Neck Surgery, Kanazawa University - Japan

Introduction

An intra-arterial chemoradiotherapy (RADPLAT) provides remarkable local control for head and neck cancer. However, the original RADPLAT, which infuse too much cisplatin in the larynx resulted in poor laryngeal function even it contributed to laryngeal preservation. As the tumor volume of laryngeal cancer is smaller than head and neck cancers arising from the other site of larynx, the efficacy of reduced RADPLAT protocol was studied in patients with laryngeal cancer.

Objective

As the tumor volume of laryngeal cancer is smaller than head and neck cancers arising from the other site of larynx, the efficacy of reduced RADPLAT protocol was studied in patients with laryngeal cancer.

Methods

Forty-three patients with advanced laryngeal cancer were treated with 3 course of intra-arterial cisplatin infusion (100 mg/body) and irradiation.

Results

Forty-two patients completed the protocol. At 3 years, 34 patients were alive (supraglottic 80%; glottic 87.5%). Local control was achieved in 27 patients (67.5%; glottic 11, 68.8%, supraplottic 64.0%). The glottic cohort showed better progression free survival than the supraglottic cohort (68.8% and 45.0%, respectively, P=0.019). There were 2 cases of Grade 3 neutropenia, and 3 cases of Grade 3 mucositis. No patients required tube feeding. Two patients with hemilaryngeal palsy before treatment required a tracheostomy at 3 months after the treatment. No patient without laryngeal palsy needed tracheostomy.

Conclusions

Our reduced dose RADPLAT is feasible for patients with advanced laryngeal cancer, especially glottic cancer.

id 87

19th WCBIP / WCBE World Congress
JOINT MEETING OF THE WORLD ASSOCIATION FOR BRONCHOLOGY AND INTERVENTIONAL PULMONOLOGY & THE INTERNATIONAL BRONCHOESOPHAGOLOGICAL SOCIETY
www.wcbipwcbe2016.org
Fortezza da Basso
May 8-11, 2016
Florence (Italy)

A prospective phase II study of combination with EBUS, ROSE, and VBN for diagnosis of small PPLs

Toshiya Maekura[1], Chikatoshi Sugimoto[1], Akihiro Tamiya[1], Nobuhiko Saijo[1], Yoko Naoki[1], Taro Koba[1], Yohei Kimura[1], Yoshinobu Matsuda[1], Masaki Kanazu[1], Naoko Takeuchi[1], Yumiko Sasaki[1], Yujiro Naito[1], Taisuke Tsuji[1], Reiko Sugawara[1], Takehiko Kobayashi[1], Keiko Nakao[1], Yoshihiko Taniguchi[1], Kyoichi Okishio[2], Naoki Omachi[1], Tomoaki Teramoto[3], Takahiko Kasai[3], Shinji Atagi[2]

[1]Internal Medicine, National Hospital Organization Kinki-chuo Chest Medical Center - Japan
[2]Clinical Research Center, National Hospital Organization Kinki-chuo Chest Medical Center - Japan
[3]Laboratory Medicine and Pathology, National Hospital Organization Kinki-chuo Chest Medical Center - Japan

Introduction

The diagnostic yield of peripheral pulmonary lesions (PPLs) is insufficient. Especially the diagnostic yield of lesions smaller than 20mm has been reported to be 34% in bronchoscopy?

Objective

The purpose of this study is to assess the diagnostic efficacy of combination with endobronchial ultrasonography (EBUS), rapid on-site cytologic evaluation (ROSE), and virtual bronchoscopic navigation (VBN) for small PPLs.

Methods

Patients with small PPLs (diameter?30mm) were enrolled in this prospective study. Primary endpoint is the diagnostic yield. We chose a target bronchus by using VBN (the LungPoint®) before bronchoscopy. After choosing the target lesion, we used the EBUS and ROSE during bronchoscopy. Based on the previous studies, we assumed that the diagnostic rate of 85% among eligible patients would indicate potential usefulness, whereas the diagnostic rate of 75% would indicate the lower limit of interest. The required number for a one-side ? value of 0.2 and a ? value (power) of 0.8 was estimated as 45 patients. Therefore, the target patient population was set as 50 patients.

Results

Total 50 patients were included in this study and 4 patients were excluded. 37 patients were diagnosed as lung cancer and 2 patients were diagnosed as pulmonary tuberculosis at the time of 15th November, 2015. And now, we are following up seven cases and cannot make a definite diagnosis. The diagnostic yield of 39 patients was 84.6%. Cases in which the EBUS probe was located within the lesion had a highest diagnostic yield of 92.3% compared to cases in which the probe was located adjacent to the lesion (71.4%) and outside the lesion (66.7%). Positive predictive value of ROSE was 96.7%. Cases diagnosed at the predicted target bronchus in VBN were 87.9%.

Conclusions

The combination with EBUS, ROSE, and VBN were shown to be useful for diagnosis of small PPLs.

Bibliography

Tamiya M, et al. Respirology 2013; Jul18(5):834-9 Asano F, et al. Lung Cancer 2008; 60:366-373

19th WCBIP / WCBE World Congress
JOINT MEETING OF THE WORLD ASSOCIATION FOR BRONCHOLOGY AND INTERVENTIONAL PULMONOLOGY & THE INTERNATIONAL BRONCHOESOPHAGOLOGICAL SOCIETY
www.wcbipwcbe2016.org
Fortezza da Basso
May 8-11, 2016
Florence (Italy)

Interventional bronchoscopy in the treatment of central airway stenosis in 103 hospital. Vietnam

Quyet Do[1], Thang Ta Ba[2]

[1]Respiratory diseases, Vietnam military medical university - Vietnam
[2]Lung diseases and tuberculosis, 103 hospital-Vietnam military medical university - Vietnam

Introduction

Interventional bronchoscopy is one of the basic and effective methods in the treatment of central airway stenosis due to benign and malignant causes.

Objective

To assess the initial results of interventional bronchoscopy in the treatment of central airway stenosis due to lung cancer and benign causes (post of endobronchial tuberculosis, endotracheal intubation and tracheostomy).

Methods

30 patients were diagnosed tracheal and bronchial stenosis due to lung cancer and the sequelaes of endobronchial tuberculosis, endotracheal intubation and tracheostomy. Patients were evaluated by multislice computed tomography scanner, virtual endobronchoscopy and flexible bronchoscopy; patients were carried out rigid bronchoscope with tracheo-bronchial dilatation, laser resection and silicone stent placement. To assess the early results of interventional bronchoscopy by the change of the clinical symptoms, chest X- ray and bronchoscopy images; FEV1, FVC, arterial blood gases and complications in the first week.

Results

There were 11 patients with tracheal stenosis, 19 patients with one side main bronchial stenosis; 10 benign cases (3/10 post endobronchial tuberculosis, 7/10 post intubation and tracheostomy) and 20 malignant cases due to lung cancer. Types of stenosis included: intraluminar tumour (66.7%), hour glass (26.6%) and web-like stenosis (6.7%). The level of stenosis: severe (53.4%), moderate (40%) and mild (6.6%). Laser therapy and dilatation were conducted in 100% of patients. Silicone stent placement was performed for 28 patients. After 1 week of intervantional endoscopy, the rate of patient out of dyspnea, blood cough and obstructive pneumonia; lung collapse on chest X-ray and local inflammatory were 73.3%, 100%, 88.8% and 90% respectively. The average value of FVC and FEV1 after the intervention increased significantly compared with before treatment (78.6 ± 9.59% vs 67.3 ± 8.63% and 72.27 ± 17.77% vs 61.18 ± 19.68% of predicted) ($p < 0.05$). The average value of PaO_2 and SaO_2 after the intervention improved significantly compared with before treatment (87.0 ± 9.55 mmHg vs 75.53 ± 11.51 mmHg and 84.0 ± 9.55 mmHg vs 75.53 ± 11,51mmHg) ($p<0.05$). The rate of early complication was 6.6%, including 1 patient with respiratory failure and 1 patient with stent migration.

Conclusions

Interventional bronchoscopy in treatment of central airway stenosis due to lung cancer and benign causes is a safe technique with initial good results.

Bibliography

Dutau H., Breen D.P., Endobronchial laser treatment: an essential tool in therapeutic bronchoscopy, Eur Respir Mon, 2010, 48, 1–12.

19th WCBIP / WCBE World Congress
JOINT MEETING OF THE WORLD ASSOCIATION FOR BRONCHOLOGY AND INTERVENTIONAL PULMONOLOGY & THE INTERNATIONAL BRONCHOESOPHAGOLOGICAL SOCIETY
www.wcbipwcbe2016.org
Fortezza da Basso
May 8-11, 2016
Florence (Italy)

Fogarty catheter technique for removal of endobronchial foreign body in children: case report

Yoshiya Kasahara, Yosuke Nakanishi, Naohiro Wakisaka, Tomokazu Wakisaka

Otolaryngology Head and Neck Surgery, Kanazawa University - Japan

Introduction

A foreign body in the tracheobronchial tree is often seen among children younger than 2 years. Foreign body aspiration is still considered one of the most important diagnostic and therapeutic issues for physicians. Mortality rates caused by foreign body in the airway is higher in children because of the relatively narrow airway and immature protective mechanisms. The major extraction technique for foreign bodies in children involves a rigid bronchoscope combined with forceps, but we sometimes encounter cases that are difficult to extract using conventional methods.

Methods

A 1-year,8-month-old girl aspirated a peanut. She was admitted to nearly emergency room due to a persistent cough and?vomiting following ingestion of a peanut. Two days later she referred to our hospital because she showed fever and no improvement. The foreign body was detected in the right main bronchus on a chest computed tomography scan. We tried to remove it by rigid bronchoscope combined with forceps under general anesthesia. Unfortunately it was ground to debris during extraction, part remained as foreign body in the left upper bronchus. We had terminated surgery, because of laryngeal edema. Later, we underwent surgery by using a Fogarty Catheter to remove the remaining of the left upper bronchus foreign body. Fogarty catheter was introduced through the instrument channel of a bronchoscope; it was then passed beyond the foreign body, and the balloon of the catheter tip was dilated at a distal site. The foreign body was finally extracted by pulling up the catheter.

Conclusions

The most common clinical manifestations due to foreign bodies, coughing attack and stridor, are sometimes treated as bronchial asthma or bronchitis. If we do not suspect a foreign body, it will take time to diagnosis. Organic matters like peanuts become fragile to include the moisture over time. This example demonstrates that an extraction technique that combined use of Fogaty Catheter with a bronchoscope was useful for fragile foreign bodies.

19th WCBIP / WCBE World Congress
JOINT MEETING OF THE WORLD ASSOCIATION FOR BRONCHOLOGY AND INTERVENTIONAL PULMONOLOGY & THE INTERNATIONAL BRONCHOESOPHAGOLOGICAL SOCIETY
www.wcbipwcbe2016.org
Fortezza da Basso
May 8-11, 2016
Florence (Italy)

Palliative airway stenting for symptomatic tracheobronchial strictures in cancer patients

Masahiro Endo[1], Yasuhisa Ohde[2], Tateaki Naito[3], Hirotsugu Kenmotsu[3], Akira Ono[3], Haruyasu Murakami[3], Toshiaki Takahashi[3], Kazushige Wakuda[3], Kazuhisa Nakashima[3], Shota Omori[3]

[1]Division of Diagnostic Radiology and Thoracic Oncology, Shizuoka Cancer Center - Japan
[2]Division of Thoracic Surgery, Shizuoka Cancer Center - Japan
[3]Division of Thoracic Oncology, Shizuoka Cancer Center - Japan

Introduction

Although severe obstruction of the airway due to malignant tumor may be considered as a symptom of terminal-stage disease, it may be quite extensive. Airway stenting can relieve symptoms of respiratory impairment and play an important role in palliative care.

Objective

The aim of the study was to assess the efficacy and safety of airway stenting for symptomatic tracheobronchial strictures in patients with intra- and metastatic extra-thoracic malignant tumors.

Methods

This study was approved with our institutional review board. We retrospectively reviewed medical records, 71 patients were enrolled in this study between October 2002 and October 2015. These patients were all performed palliative airway stenting for symptomatic tracheobronchial strictures under fluoroscopic guidance. The performance status (PS) of cancer patients was mainly ECOG 2 or 3. The causes of airway stricture were mainly bulky metastatic mediastinal lymph nodes and/or tracheobronchial involvement of the tumor, and the origin of malignant tumors were lung cancer in 32 patients, esophageal cancer in 18 and metastatic extrathoracic tumor in 21. Technical aspects, improvement of PS and dyspnea, complications, re-interventions and survival data were evaluated.

Results

A total of 72 airway stents (21 Gianturco-Z stents, 38 covered expandable nitinol stents and 13 Dumon silicon stents) were placed successfully in 71 patients without procedural complications. PS and dyspnea score of all patients were significantly improved after stent placement ($p<.05$). Long term complications included stent migration, tumor ingrowth and hemoptysis in one patient, respectively. Further chemotherapy or active irradiation could be performed in 22 patients with improved PS, including 10 patients with lung cancer and 12 with extra-thoracic malignancy. Total mean survival time was 160 days (range, from 6 to 1134 days), 110 in patients with lung cancer, 137 in esophageal cancer and 256 in extra-thoracic malignancy, respectively. It was significant to be effective for survival in patients with extra-thoracic malignancy ($p<.05$).

Conclusions

Airway stent placement of tracheobronchial strictures is effective and safe for palliative treatment in relapsed and/ or metastatic cancer patients. Some patients could be occasionally received further active treatment, and get long survival in extra-thoracic malignancy.

19th WCBIP / WCBE World Congress
JOINT MEETING OF THE WORLD ASSOCIATION FOR BRONCHOLOGY AND INTERVENTIONAL PULMONOLOGY & THE INTERNATIONAL BRONCHOESOPHAGOLOGICAL SOCIETY
www.wcbipwcbe2016.org
Fortezza da Basso
May 8-11, 2016
Florence (Italy)

A Case report of plastic bronchitis assessed as foreign body aspiration

Cengiz Ozdemir[1], Sinem Nedime Sokucu[1], Levent Karasulu[1], Seda Tural Onur[1], Levent Dalar[2]

[1]Chest Disease, Yedikule Chest Disease and Chest Surgery Training and Research Hospital - Turkey
[2]Department of Pulmonology, Bilim University - Turkey

Introduction

Plastic bronchitis is a disease which is characterized by bronchial lumen partially or completely obstructed by plaques or similar hard gelatinous structure. Although it often seen in childhood period, respiratory illnesses lymphatic abnormalities, congenital heart disease may also be seen after surgery. We want to present a plastic bronchitis cases considered as foreign body aspiration.

Methods

19-year-old female patient was admitted emergency room with shortness of breath, and cough. Posteroanterior chest radiograph detected left total atelectasis. In history she has complainted for cough for three weeks and during chewing a chewing gum her cough increased. The total atelectasis was considered due to possible foreign body aspiration. Flexible bronchoscopy showed that the left main bronchus distal part obstructed by dirty soft yellow foreign body. Foreign body was removed partially with flexible bronchoscopy. After then, the foreign body which obstructing the lower lobe completely removed with cryoprobe in rijid bronchoscopy session (Figure 1). Material seen to be originated from the anterobazal subsegmental of the left lower lobe segment. All tissues in the lumen were cleared by the cryoprobe and biopsy forceps and provided with the full opening of airway. From pathological assessment of amorphous material, containing elements of fibrinoid material and dense eosinophilic inflammation, fewer ulcers, inflammation of the bronchial mucosa parts were detected. 2 weeks later, the patient's complaints were increased. Bronchoscopy showed that left lower lobe anterobazal subsegments of the patient obstructed again with the same material. Intraluminal tissue was cleaned via biopsy forceps and had complete clearance of bronchial segments. Bronchodilator treatment and the acetyl cysteine were introduced to the symptomatic patient because of recurrent bronchial plugs and patient was sent to chest physiotherapy. Symptoms improved and patient is still in our follow up.

Conclusions

Foreign body aspiration suspicion have been evaluated and plastic bronchitis has been diagnosed due to pateints' results of the biopsy features and clinical presentation. In our patient, bronchial cast cleaned with cryotherapy bronchoscopically and airway lumen opening is ensured. There are no etiologic factors for patients without any specific treatment for this rare disease. Symptomatic treatment of patients who are being followed, as in our patients presenting with foreign body aspiration should be kept in mind with similar statements in the differential diagnosis of plastic bronchitis.

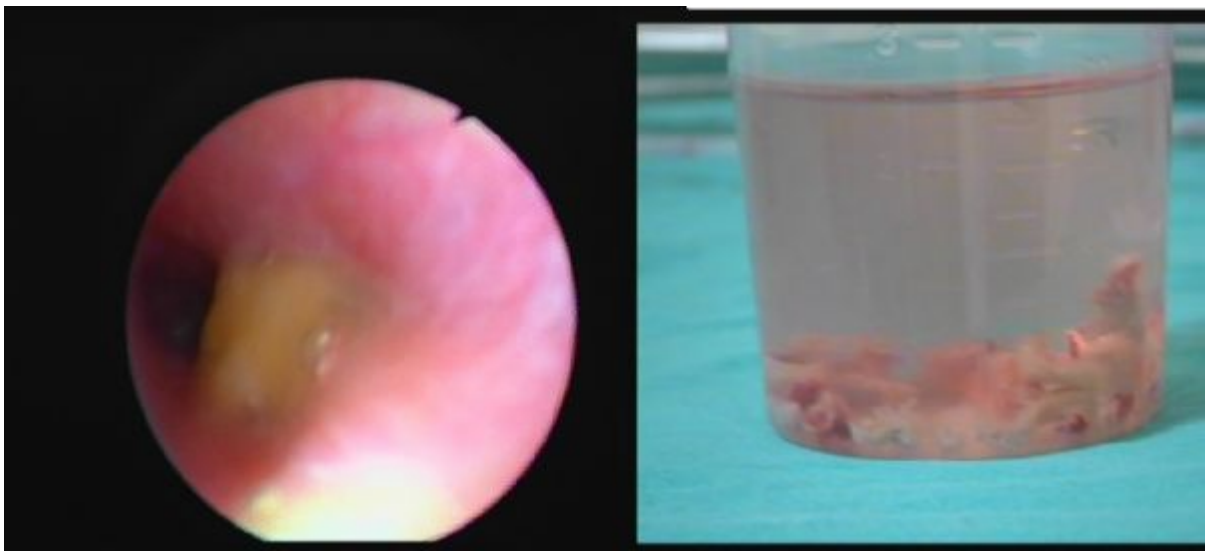

19th WCBIP / WCBE World Congress
JOINT MEETING OF THE WORLD ASSOCIATION FOR BRONCHOLOGY AND INTERVENTIONAL PULMONOLOGY & THE INTERNATIONAL BRONCHOESOPHAGOLOGICAL SOCIETY
www.wcbipwcbe2016.org
Fortezza da Basso
May 8-11, 2016
Florence (Italy)

Massive chylothorax due to extrathoracic pathology

Umang Shah[1], Nevin Kishore[1], Vivek Raj[2], Ankur Bahl[3], Vivek Saxena[4]

[1]Department of Respiratory Medicine, Max Superspeciality Hospital, Saket, New Delhi 110017 - India
[2]Department of Gastroenterology Medicine, Max Superspeciality Hospital, Saket, New Delhi 110017 - India
[3]Department of Oncology Medicine, Max Superspeciality Hospital, Saket, New Delhi 110017 - India
[4]Department of Interventional Radiology, Max Superspeciality Hospital, Saket, New Delhi 110017 - India

Introduction

Chylothorax and chylous ascites are very rare clinical entities generally caused by obstruction and disruption of the thoracic duct. Chylous ascites is accumulation of peritoneal fluid that is rich in triglycerides generally a triglyceride level more than 200 mg/dl gives rise to chylous ascites. Estimated incidence of Chyloascites causing Chylothorax in United States is approximately 1 per 20000. Most common causes for chylous ascites include trauma, malignancy and infections.

Methods

A 61 years old man presented with progressive shortness of breath since 7 days associated with diffuse pain abdomen and gradually progressive abdominal distention. Chest x ray revealed large pleural effusion on right side. USG chest was done revealing bilateral pleural effusion (R > L). USG whole abdomen was done revealing heterogeneous predominantly hypoechoic mass seen in retroperitoneum encasing the large vessels likely lymphoma and Moderate Ascites seen. On aspiration pleural and ascitic fluid were milky white in colour and had triglyceride content of 537 mg/dl and 1242 mg/dl respectively with exudative features on fluid analysis with pleural fluid was showing atypical lymphoid cells on cytology. CECT whole abdomen was done revealing large retroperitoneal mass encasing great vessels with significant compromise and compression of infra-hepatic IVC suggestive of retroperitoneal lymphoma. CT guided biopsy was done from retroperitoneum and IHC was positive for CD 23,CD 20 ,CD 10, CD3 and a diagnosis of low grade B cell non hodgkins lymphoma – non blastic possibly follicular lymphoma grade 2 was made. Medical Thoracoscopy and Talc Pleurodesis was done for right sided massive effusion and IHC staining of pleural biopsy for CD3, CD20 and Ki 67 showed presence of reactive T and B lymphoid cells. Total ICD Drain from right side pleural cavity was around 20 liters of chylous fluid over a period of 10 days. PET CT was done suggestive of FDG avid chain of conglomerate lymph nodal mass measuring 7.7 x 10.5 x 27.9 cm encasing the large vessels of abdomen and bilateral ureters resulting in bilateral hydro-ureteronephrosis. Patient was started on R Bendamustine 200 mg and 100 mg subsequently following 2 day cycle of chemotherapy along with Rituximab. Gradual resolution of tumor size, pleural drain and ascites was noted on therapy.

Conclusions

Massive chylothorax can rarely be due to Chylous ascites in which intra- abdominal malignancy and liver cirrhosis cause the majority of cases. Paracentesis and triglyceride level are the most important diagnostic factors. The outcome mostly depends on the underlying pathological condition.


ROMO-SEAL®
UNDER WATER SEAL
PLEURAL DRAINAGE SYSTEM
CAUTION
DO NOT APPLY UN-REGULATED SUCTION

id 93

19th WCBIP / WCBE World Congress
JOINT MEETING OF THE WORLD ASSOCIATION FOR BRONCHOLOGY AND INTERVENTIONAL PULMONOLOGY & THE INTERNATIONAL BRONCHOESOPHAGOLOGICAL SOCIETY
www.wcbipwcbe2016.org
Fortezza da Basso
May 8-11, 2016
Florence (Italy)

EBUS TBNA ROSE Aided Cell Block Preparation - A Putative Substitute For Conventional Biopsy

Umang Shah[1], Nevin Kishore[1], Nitin Dayal[2], Palak Brahmbhatt[1]

[1]Department of Respiratory Medicine, Max Superspeciality Hospital, Saket, New Delhi 110017 - India
[2]Department of Pathology, Max Superspeciality Hospital, Saket, New Delhi 110017 - India

Introduction

With the introduction of novel targeted therapies for Lung cancer, cytologists have had to cope with a corresponding rise in the need for accurate diagnosis and appropriate classification of subtypes. The analysis of genetic abnormalities in cancer cells, such as mutations in the epithelial grow factor receptor (EGFR) gene has become crucial for the choice of treatment. Thus, conventional cytology staining does not always provide sufficient information and additional tissue is often required. The possibility of tailored treatments for lung cancer has come at the same time as the increased availability and use of minimally invasive sampling procedures, such as endobronchial ultrasound-guided transbronchial needle aspiration (EBUS-TBNA). This technique can obtain both mediastinal and hilar cytological samples of nodes and masses that are appropriate for conventional smear and, in most cases, for immunohistochemistry.

Objective

The purpose of this study is to assess the role of ‘Rapid On Site Evaluation’ (ROSE) in the diagnosis of pulmonary/mediastinal pathologies, while performing EBUS TBNA with evaluation of cell blocks processed from EBUS TBNA samples in obtaining additional clinically relevant information such as immunohistochemistry and molecular testing.

Methods

This study is performed on twenty patients who underwent EBUS TBNA for diagnosis of hilar/mediastinal lymphadenopathy or lung mass adjacent to a central airway. The sample collected from needle aspiration was smeared and processed with rapid staining for ROSE. Based on the initial findings cell blocks were generated from the cytology needle samples, which were utilized for the morphological diagnosis. The possible uses of cell blocks for immunohistochemistry and ancillary molecular testing were also analyzed whenever needed.

Results

In our study we found adenocarcinoma (10), squamous cell carcinoma (4), lymphoma (2), non-small cell carcinoma NOS (1) and other tumors (3). Adequate cell blocks could be obtained in 70% of cases (14/20), which were used for morphological characterization and IHC studies. In 78.6% (11/14) cases, the cell block provided a subtype specific pathological diagnosis with relevant IHC. Four cases of pulmonary adenocarcinoma underwent molecular testing and showed positive EGFR/ALK mutations.

Conclusions

Performance of immediate on-site cytologic interpretation and assessment of adequacy by the cytopathologist can be time-consuming but significantly improves the diagnostic yield. ROSE during EBUS TBNA definitely lowers the need for additional bronchoscopic procedures and puncture number. It also confirms the adequacy of specimen for cell block, which can be used for immunohistochemical staining and ancillary molecular testing for better classi?cation of neoplasms and hence reduces further need of conventional biopsy procedures.

19th WCBIP / WCBE World Congress
JOINT MEETING OF THE WORLD ASSOCIATION FOR BRONCHOLOGY AND INTERVENTIONAL PULMONOLOGY & THE INTERNATIONAL BRONCHOESOPHAGOLOGICAL SOCIETY
www.wcbipwcbe2016.org
Fortezza da Basso
May 8-11, 2016
Florence (Italy)

Incidence of TB lymphadenopathy on EBUS TBNA in Renal failure v/s Non Renal failure patients

Umang Shah[1], Nevin Kishore[1], Dinesh Khullar[2], Nitin Dayal[3], Palak Brahmbhatt[1]

[1]Department of Respiratory Medicine, Max Superspeciality Hospital, Saket, New Delhi 110017 - India
[2]Department of Nephrology, Max Superspeciality Hospital, Saket, New Delhi 110017 - India
[3]Department of Pathology, Max Superspeciality Hospital, Saket, New Delhi 110017 - India

Introduction

Chronic kidney patients are prone to various infection due to their immune suppressed status. Mycobacterium tuberculosis (MTB) continues to be a major health problem worldwide, especially in developing countries. Myobacterium tuberculosis is more prevalent among immune compromised patients, such as those on dialysis treatment and recipients of organ transplants.

Objective

Newly arising enlarged or hyper metabolic mediastinal and hilar lymph nodes raise suspicion of Tuberculosis. We aimed to determine incidence of tubercular lymphadenopathy on EBUS TBNA between renal failure and non renal failure cases.

Methods

We retrospectively analyzed all proven 35 renal failure patients (18 CKD Stage V and 17 Renal transplant cases) and 35 non-renal failure patients who underwent EBUS TBNA between August 2014 and July 2015. CAT Scan Thorax was done for all these patients to assess lymph node and lung parenchyma status. In 70 patients included in this study, lung parenchyma was essential normal and only abnormality was mediastinal lymphadenopathy.

Results

All 70 patients underwent EBUS TBNA and no complications were observed. Results of EBUS TBNA in 35 renal failure cases revealed Granuloma positive in 20 cases (57.14%), Reactive lymphadenitis in 12 cases (34.28%) and Anthracosis in 3 cases (8.57%) whereas results in 35 non-renal failure cases revealed Granuloma positive in 17 cases (48.57%), Reactive lymphadenitis in 10 cases (28.57%), Anthracosis in 2 cases (5.71%), Malignancy in 4 cases (11.42%) and Inconclusive results in 2 cases (5.71%). In Renal failure cases, AFB positive in Granuloma positive revealed 13 cases (65%) and AFB negative was 7 cases (35%) whereas in non-renal failure cases, AFB positive in Granuloma positive revealed 15 cases (88.23%) and AFB negative was 2 cases (11.76%). The sensitivity, specificity, positive predictive value (PPV), negative predictive value (NPV) and diagnostic accuracy of EBUS TBNA for Granuloma positive in both renal and non-renal failure patients were 57.14%, 51.43%, 54.05%, 54.55% and 54% respectively. When both AFB positive and AFB negative cases were considered in both renal and non-renal failure patients, sensitivity, specificity, positive predictive value (PPV), negative predictive value (NPV) and diagnostic accuracy of EBUS TBNA were 37.14%, 54.29%, 44.83%, 46.34% and 45.71% respectively.

Conclusions

EBUS TBNA is safe, minimally invasive and effective method for diagnosis and assessment of Mediastinal LNs. Incidence of Tubercular lymphadenitis is high (57.14%) in CKD patients compared to (48.57%) in non CKD patients. Present study shows incidence of Tuberculosis in allograft recipient and renal failure cases is relatively high as compared to Non renal failure cases.

19th WCBIP / WCBE World Congress
JOINT MEETING OF THE WORLD ASSOCIATION FOR BRONCHOLOGY AND INTERVENTIONAL PULMONOLOGY & THE INTERNATIONAL BRONCHOESOPHAGOLOGICAL SOCIETY
www.wcbipwcbe2016.org
Fortezza da Basso
May 8-11, 2016
Florence (Italy)

Endometrial carcinoma with delayed lung metastasis diagnosed with navigational bronchoscopy

Michael Gabrilovich[1], Daniel Buxton[2], Evan Lang[3]

[1]Pulmonary and Critical Care medicine, Fort Hamilton Hospital - Usa
[2]Pathology, Fort Hamilton Hospital - Usa
[3]Oncology, Fort Hamilton Hospital - Usa

Introduction

Endometrial carcinoma is the seventh most common cancer in females. 10-15% of patients with early disease stage will have a recurrence, with the majority within the first 3 years after initial diagnosis. Isolated pulmonary metastases are rare (2.3-7%). The longest time period between initial diagnosis and isolated pulmonary metastasis described in the literature was 17 years. We present 2 cases of endometrial carcinoma metastasized to the lungs, only diagnosed with navigational bronchoscopy.

Methods

54 years old female was diagnosed with stage IIC uterine cancer in 2009. She had multiple subcentimeter pulmonary nodules. After hysterectomy and chemotherapy with carboplatine and taxol, the nodules resolved. However, a year later they reappeared. Endometrial carcinoma was seen on the transthoracic needle aspirate. She was treated with chemotherapy with resolution of the nodules. 3 years later on routine follow up CT scan, a left infrahilar mass was seen. Navigational bronchoscopy (Medtronics) with EBUS radial probe (Olympus) was performed. The mass was biopsied. There was an oozing endobronchial lesion incidentally seen in the lingula, which was biopsied and then treated with electrocautery ball tip probe (Olympus). Metastatic endometrial carcinoma was seen in both specimens. Patient was subsequently treated with chemotherapy and radiation with no active disease seen on follow up imaging. 60 years old female former smoker diagnosed with endometrial carcinoma in 2006, was treated with definitive surgery, followed by chemotherapy and radiation. Pulmonary nodules were seen in 2010, and a transthoracic biopsy reported to be benign. A CT of the chest was obtained in 2015 for nonresolving cough. Several bilateral lung masses, cavitating on the right, were seen, either new or significantly increased in size compared to 2010. Navigational bronchoscopy (Medtronics) with EBUS radial probe (Olympus) was performed, right and left upper lobe masses were biopsied and metastatic endometrial carcinoma was seen in both specimens. The patient was referred to oncology for palliative chemotherapy.

Conclusions

Endometrial carcinoma can recur long after an original diagnosis and present with metastatic disease confined to the lungs only. It can be amenable to treatment with chemotherapy and radiotherapy. Modern low invasive diagnostic modalities, such as navigational bronchoscopy and endobronchial ultrasound can be successfully utilized for quick diagnosis and direction of treatment.

Bibliography

Zaheeruddin PM et al. Metastatic endometrial carcinoma in the lung: unusual timing and site. South Afr J Gynaecol Oncol 2013;5(2):64-67.

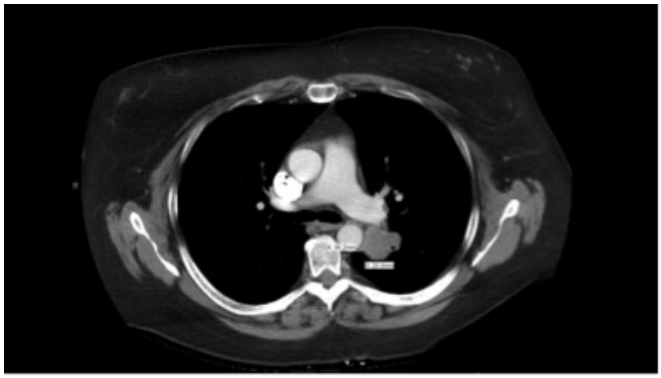

Figure 1A: Patient 1, CT scan with left infrahilar mass.

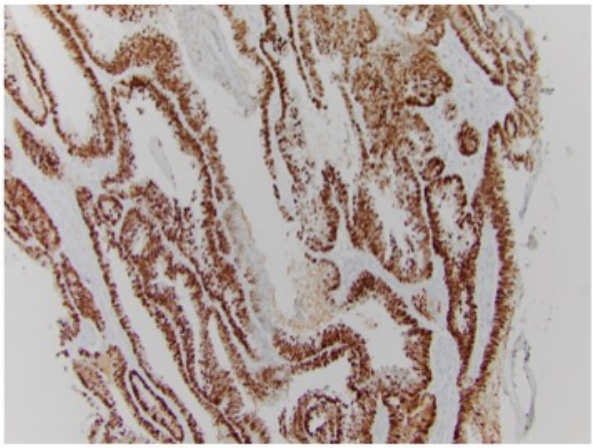

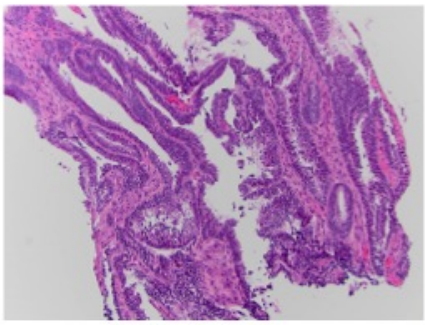

Figure 1B: patient 1, transbronchial biopsy, H&E and ER stain

id 96

19th WCBIP / WCBE World Congress
JOINT MEETING OF THE WORLD ASSOCIATION FOR BRONCHOLOGY AND INTERVENTIONAL PULMONOLOGY & THE INTERNATIONAL BRONCHOESOPHAGOLOGICAL SOCIETY
www.wcbipwcbe2016.org
Fortezza da Basso
May 8-11, 2016
Florence (Italy)

Clinical differentiation between post-Intubation and post-tracheostomy tracheal stenosis

Beomsu Shin[1], Kang Kim[1], Jung Seop Eom[2], Hye Yun Park[1], Hojoong Kim[1], Byeong-ho Jeong[1]

[1]Internal Medicine, Samsung Medical Center/Sungkyunkwan University School of Medicine - Republic Of Korea
[2]Internal Medicine, Pusan National University School of Medicine - Republic Of Korea

Introduction

Post-intubation tracheal stenosis (PITS) or post-tracheostomy tracheal stenosis (PTTS) is a serious complication in mechanically ventilated patients. Surgery is the standard treatment for these problems. But, some patients undergo interventional bronchoscopy depending on the location of stenosis and their symptoms or performance. So far, PITS and PTTS have been grouped into the same category, and little is known about their clinical impact on each other.

Objective

We investigated the clinical significance of the differentiation between PITS and PTTS in patients preferentially receiving interventional bronchoscopy.

Methods

We retrospectively conducted a chart review of 205 patients with PITS (n = 117) and PTTS (n = 88) treated at Samsung Medical Center between January 2004 and December 2013.

Results

Compared to the patients with PITS, the patients with PTTS had the following characteristics: Lower BMI (21.4kg/m2 vs. 22.4kg/m2, P = 0.037); etiology, frequent neurological disease (37.5% vs. 10.2%, P < 0.001); Stenotic lesions, frequent mid-to-lower tracheal lesion (43.2% vs. 18.8%, P < 0.001) and infrequent subglottic-to-upper tracheal lesion (56.8% vs. 81.2%, P < 0.001); Obstruction of the tracheal lumen, frequent total obstruction (75.0% vs. 23.9%, P < 0.001); frequent stenosis type, Granulation (56.8% vs. 26.5%, P < 0.001), malacia (19.3% vs. 6.8%, P = 0.009) and mixed lesion (48.9% vs. 12.0%, P < 0.001). Interventional procedure was performed about 2 times per patient. Stent insertion was performed in 87 (74.4%) patients with PITS and 63 (71.6%) patient with PTTS. Then, 77.8% of patients with PITS and 64.8% of patients with PTTS were cured and there was no case of tracheostomy, operation or death. It is important to note that the cure rate was more significantly higher for PITS than PTTS (P = 0.042). Two procedure related deaths occurred in patients with PTTS.

Conclusions

There is a significant distinction between PITS and PTTS in terms of etiology, aspect of lesions and outcome. Therefore, it is necessary to understand each feature for administering the appropriate therapy and achieving a successful outcome while avoiding the operation or death in patients with PITS and PTTS.

Clinical course of tracheoesophageal fistula after the use of Sorafenib for advanced thyroid cancer

Young Ju Jung[1], Eyun Song[2], Won Gu Kim[2], Hyeong Ryul Kim[3], Jae Cheol Lee[1], Chang-min Choi[1]

[1]Pulmonary and Critical Care Medicine, University of Ulsan College of Medicine, Asan Medical Center - South Korea
[2]Endocrinology, University of Ulsan College of Medicine, Asan Medical Center - South Korea
[3]Thoracic and Cardiovascular Surgery, University of Ulsan College of Medicine, Asan Medical Center - South Korea

Introduction

Thyroid cancer is the most common endocrine malignancy, with differentiated thyroid cancer (DTC) comprising ~ 93% of all thyroid cancers. Despite the favorable prognosis of DTC, a small percentage of patients develop metastatitic disease that is not responsive to radioactive iodine (RAI). Sorafenib, an oral tyrosine multi-kinase inhibitor, was recently approved for patients with RAI-refractory locally advanced or metastatic DTCs. Although sorafenib was initially believes to be less toxic than conventional chemotherapy, it can have rare serious and even life-threatening complication.

Objective

We report successfully treated patient who had developed tracheoesophageal fistula (TEF) associated with rapid tumor regression during sorafenib treatment for locally advanced papillary thyroid carcinoma (PTC).

Methods

A 71-year-old woman presented with a 1-week history of cough, hemoptysis, and progressive dyspnea. She had undergone thyroid surgery and RAI remnant ablation for the treatment of PTC 15 years ago. Neck CT showed a 3.6 cm-sized heterogenous enhancing mass in her right tracheoesophageal groove that invaded into the cervical esophagus and mid-trachea to cause luminal narrowing (Figure A.1). Bronchoscopic findings revealed a protruding mass at the mid-tracheal area that caused almost total obstruction of the trachea (Figure A.2). After sorafenib use for the treatment of locally advanced PTC, her symptoms dramatically improved and the tumor size decreased significantly one month later. However, she was readmitted because of recurrent aspiration at 4 months after sorafenib administration and tracheobronchial CT scan found newly developed TEF at the level of the metastatic tumor in the tracheoesophageal groove that resulted from necrosis of this lesion (Figure B.1-2). Sorafenib was discontinued and she was treated by supportive care with insertion of a feeding jejunostomy tube without oral feeding. TEF was found to be in a healing state with a decreased sized fistula opening revealed by one month follow-up bronchoscopy. Three months later, TEF had successfully healed and allowed for oral intake, so the jejunostomy was removed. There was no visible fistula track or interval change of the viable tumor in the tracheoesphageal groove during 10 months of follow-up.

Conclusions

TEF formation is a rare and deteriorating complication in patients administered sorafenib for the treatment of locally advanced RAI-refractory DTC. Patients should be aware of this side effect, and physicians should monitor patient for symptoms of TEF. TEF can be successfully treated through early detection and immediate therapeutic interventions by discontinuing sorafenib and inserting a jejunostomy tube.

Bibliography

1. Blevins DP, et al. Thyroid 2014:24:918-922. 2. Brose MS, et al. Lancet 2014: 384:319-328.

A.1

A.2

B.1

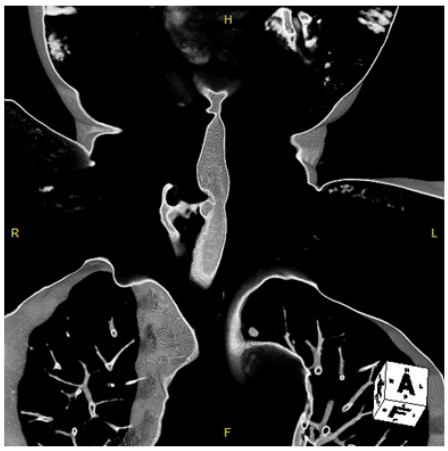

B.2

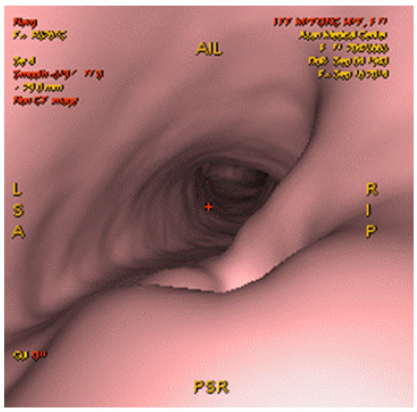

id 98

19th WCBIP / WCBE World Congress
JOINT MEETING OF THE WORLD ASSOCIATION FOR BRONCHOLOGY AND INTERVENTIONAL PULMONOLOGY & THE INTERNATIONAL BRONCHOESOPHAGOLOGICAL SOCIETY
www.wcbipwcbe2016.org
Fortezza da Basso
May 8-11, 2016
Florence (Italy)

Interventional Pulmonology: a five-year retrospective study of pleural iatrogenic injuries

Cátia Santos, Salvato Feijó, Paula Monteiro, José Rosal Gonçalves, Carla Costa, Cristina Bárbara

Interventional Pulmonology Unit, Hospital de Santa Maria - Portugal

Introduction

Iatrogeny is defined as any medical, diagnostic, therapeutic or prophylactic action that unintentionally causes symptoms that need treatment, hospital admission, increase hospital stay, cause incapacity, or lead to death. Pleural iatrogenic injuries can lead to the increase of pressure in the thoracic cavity, and secondarily to respiratory insufficiency, cardiovascular collapse or even death.

Objective

This study aims to describe and identify the frequency, type and causes of pleural iatrogenic events requiring admission to an interventional pulmonology unit from a tertiary university hospital.

Methods

We performed a retrospective and descriptive study between July 2009 and June 2014. All patients referred with pleural iatrogenic events were studied. Demographic characteristics, type of injury, etiology and treatment were reviewed.

Results

During this period, 70 patients (1.2% of all unit referrals) were diagnosed and treated. A total of 70 pleural iatrogenic events were identified. The mean age was 67 years and 38 patients (54.3%) were female. Pneumothorax was the most prevalent in 65 cases (92.9%). Hemothorax was present in 5 cases (7.1%). Major causes: placement of central venous catheter 30 (42.9%); thoracentesis 11 (15.7%); placement of pacemakers 9 (12.9%); transthoracic needle aspiration 7 (10.0%); positive pressure ventilation 5 (7.1%); surgical procedures 3 (4.2%); flexible bronchoscopy 2 (2.9%); liver biopsy 2 (2.9%) and placement of implantable cardioverter defibrillator 1 (1.4%). Treatment: 67 patients (95.7%) were submitted to chest tube pleural drainage (20 to 24CH) and in 3 patients (4.3%) was used a pleural catheter. We had no complications in 69 patients (98.6%), 1 (1.4%) required talc poudrage pleurodesis. The median drainage time was 48 hours.

Conclusions

Procedures related to pleural iatrogenic injuries had a frequency of 1.3% of all unit interventions. The most prevalent cause was iatrogenic pneumothorax secondary to the placement of central venous catheter. Given the severity of pleural iatrogenic events, a specialized and prompt patients referral is fundamental.

id 99

19th WCBIP / WCBE World Congress
JOINT MEETING OF THE WORLD ASSOCIATION FOR BRONCHOLOGY AND INTERVENTIONAL PULMONOLOGY & THE INTERNATIONAL BRONCHOESOPHAGOLOGICAL SOCIETY
www.wcbipwcbe2016.org
Fortezza da Basso
May 8-11, 2016
Florence (Italy)

Use of extended intrapleural fibrinolytic therapy in complicated pleural infections

Christopher Gilbert[1], Jason Mcclune[2], Candice Wilshire[1], Brian Louie[1], Alexander Farviar[1], Jennifer Toth[2], Matthew Taylor[3], Micheal Reed[3], Eric Vallieres[1], Ralph Aye[1], Jed Gorden[1]

[1]Division of Thoracic Surgery and Interventional Pulmonology, Swedish Cancer Institute and Medical Center - Usa
[2]Division of Pulmonary, Allergy, and Critical Care Medicine, Penn State-Milton S. Hershey Medical Center - Usa
[3]Division of Thoracic Surgery, Penn State-Milton S. Hershey Medical Center - Usa

Introduction

Complicated pleural infections (empyema and complicated parapneumonic effusions) develop in up to two-thirds of hospitalized pneumonia patients and are associated with a subsequent 10-20% mortality. Antimicrobials, pleural drainage, and surgical intervention are often advocated as standard treatments, however, the MIST II trial suggests improved outcomes utilizing intrapleural fibrinolytic therapy (IPFT). The MIST II protocol utilized six doses of IPFT over 72 hours; however, the outcomes and safety profile of extended IPFT is currently unknown.

Objective

Describe the outcomes and safety profile of extended (>6 consecutive doses) IPFT use in adult patients with complicated pleural infections.

Methods

Retrospective review of patients receiving IPFT for complicated pleural infections from January 2013 – August 2015 at two institutions was performed. All patients received concurrent tissue plasminogen activator (10mg) and DNase (5mg), with the use of additional intrapleural dosing at attending physician discretion. Inclusion criteria included: 1) empyema or complicated parapneumonic effusion undergoing tube thoracostomy drainage, 2) consecutive use of IPFT, 3) age >18 years. Exclusion criteria included previous pleural interventions for infection.

Results

We identified 173 patients receiving IPFT with 101 patients meeting inclusion criteria. The mean age was 58.9 (SD-19.3, range 20-85) years with 55% (56/101) male (Table 1). Extended IPFT was performed in 19.8% (20/101) with a mean total number of doses at 9.3 (SD-2.5, range 7-16). Outcomes including chest tube duration, hospital stay, and days to surgical referral all trended towards more days within the extended IPFT group, but none reached statistical significance. Surgical intervention occurred at similar rates (16% versus 15%). Additional chest tube placement occurred more often in the extended IPFT group (35% versus 15%) but did not reach statistical significance (p=0.08). Bleeding complications occurred in 2 patients within each group (p=0.37). The use of new or escalating narcotics occurred in the majority of patients (57% - IPFT and 80% - extended IPFT), with a non-significant trend towards the extended IPFT group.

Conclusions

The use of extended IPFT may offer alternatives to surgical intervention in complicated pleural infections. Extended IPFT may offer alternative treatment options for those unfit for surgical intervention secondary to disease severity or co-morbidities. When compared to unmatched controls undergoing IPFT, outcomes and complications were not statistically significant. While life-threatening complications and referral to surgery seem comparable, extended IPFT use appears potentially associated with prolonged hospital stay and increased narcotic usage. Further study regarding outcomes of extended IPFT therapy versus early surgical referral appears warranted.

Bibliography

1. Davies HE, et al. Thorax 2010;65 Suppl 2:ii41-53. 2. Rahman NM, et al. N Engl J Med 2011;365:518-26.

	Standard IPFT	Extended IPFT	p value
Patients (n)	81	20	
Age (years)			
Median [Interquartile Range (25-75)]	62 [44-74]	57 [49-64]	0.394
Sex (n)			0.648
Male	44	12	
Female	37	8	
Median Pleural Fluid Characteristics [Interquartile Range (25-75)]			
Lactate Dehydrogenase (units/L)	1118 [541-4117]	827 [484-6261]	0.980
Protein (g/dL)	4 [3-4]	3 [3-4]	0.561
pH	7.3 [6.8-7.5]	7.3 [7.0-7.7]	0.686
Glucose (mg/dL)	69 [25-92]	57 [32-81]	0.652
Pleural Fluid Microbiology Analysis			
Gram stain positive (n, (%))	27 (33)	8 (40)	0.575
Fluid culture positive (n (%))	29 (36)	15 (75)	0.002
Median Outcomes in Hospital Days [Interquartile Range (25-75)]			
Chest tube duration	6 [4-11]	8 [6-11]	0.200
Hospital length of stay	13 [9-19]	17 [9-25]	0.355
Admission to surgery day	6 [0-14]	7 [7-14]	0.975
Surgery Intervention (n (%))	13 (16)	3 (15)	0.821
Placement of Additional Chest Tube after IPFT Initiation (n (%))	12 (15)	7 (35)	0.080
Complications (n, (%))			
Need for outpatient pleural drainage	10 (12)	2 (10)	0.924
Bleeding requiring transfusion	2 (3)	2 (10)	0.365
New or escalating narcotic use	46 (57)	16 (80)	0.056

id 100

19th WCBIP / WCBE World Congress
JOINT MEETING OF THE WORLD ASSOCIATION FOR BRONCHOLOGY AND INTERVENTIONAL PULMONOLOGY & THE INTERNATIONAL BRONCHOESOPHAGOLOGICAL SOCIETY
www.wcbipwcbe2016.org
Fortezza da Basso
May 8-11, 2016
Florence (Italy)

Efficacy and Safety of Self-expanding Hybrid Stent for Malignant Central Airway Stenosis

Hiroshi Handa[1], Seiichi Nobuyama[2], Masamichi Mineshita[1], Teruomi Miyazawa[1]

[1]Division of Respiratory Medicine, Department of Internal Medicine, St. Marianna University School of Medicine - Japan
[2]Department of Respiratory MedicineI, nternational University of Health and Welfare Atami Hospital - Japan

Introduction

Silicone and self-expanding metal stents have been used to palliate malignant central airway obstruction. Long-term complications include granulation formation, stent fracture, chronic infection and cough. The hybrid stent was designed to reduce stent complications, e.g. no tumor in-growth and less over-growth.

Objective

The purpose of this study is to assess the efficacy and safety of hybrid stents (Aero stent?R, SHEEN MAN co., Ltd, Osaka, Japan).

Methods

This is an ongoing study for malignant central airway stenosis patients treated at our department from October 2014. The Ethics Committee of the St. Marianna University School of Medicine approved this study and written informed consent was obtained from all subjects. We have evaluated improvements in dyspnea score (MMRC), spirometry (forced expiratory flow at 1 second: FEV1, peak expiratory flow: PEF), impulse oscillometry (IOS) (respiratory resistance at 5Hz: R5, respiratory resistance at 20Hz: R20), and complications before and after stenting.

Results

Six subjects received hybrid stent placements. Five subjects showed a decrease in MMRC scores of 1 to 3 points and all subjects maintained airway patency after stenting (FEV1: 1.38±0.90L to 1.79±0.76L, PEF: 2.45±1.41 to 4.43±2.51L/s, Resistance at 5Hz (R5): 0.77±0.42 kPa/L/s to 0.57±0.14 kPa/L/s, Resistance at 20Hz (R20): 0.40±0.13 kPa/L/s to 0.37±0.08 kPa/L/s,). Four patients died due to tumor progression 35, 84, 90 and 258 days after stenting. Two subjects had complications due to granuloma formation at both ends of the hybrid stent. One patient was diagnosed as adenocarcinoma with anaplastic lymphoma kinase (ALK) fusion. Subsequently, 20 days after administration of ALK-inhibitor (alectinib?R), the right main bronchial tumor disappeared and stent removal was possible.

Conclusions

The early results of this hybrid stent study show promise in palliating patients with stenosis of the airways. When chemotherapy and/or radiation therapy has a good response to malignant tumors, hybrid stents can be removed.

Bibliography

Gildea TR. Downie G, Eapen G, et al. A Prospective Multicenter Trial of a Self-expanding Hybrid Stent in Malignant Airway Obstruction. Journal of Bronchology. 15(4):221-224, October 2008.

Bronchial Thermoplasty in 4 Patients with Severe Persistent Asthma

Rintaro Onoe, Shinya Azagami, Hiroshi Handa, Teruomi Miyazawa, Masamichi Mineshita

Division of Respiratory Medicine, Department of Internal Medicine, St. Marianna University School of Medicine - Japan

Introduction

Bronchial thermoplasty (BT) is a novel bronchoscopic therapy for patients with severe persistent asthma that is uncontrolled despite the use of high dose ICS and LABA. BT was approved in April 2015 in Japan, and we performed BT in 4 patients with severe persistent asthma as defined by Asthma Prevention and Management Guidelines, Japan Guidelines (JGL).

Objective

To evaluate the efficacy and safety of bronchial thermoplasty in 4 patients with severe asthma.

Methods

From June 2015 to present, 4 patient with severe asthma assessed by GINA were recruited. Patients were assessed by the asthma quality of life questionnaire (AQLQ) and pulmonary function tests (PFTs).BT was performed using a radiofrequency heat catheter inserted through the bronchoscope and applied to the airway wall. We report our experiences of 4 severe asthma patients treated by BT.

Results

BT procedures were successfully performed under general anesthesia. The average number of activation for the first (right lower lobe) procedure was 36.5±3.9, the second (left lower lung) was 46.3±12.9, and the third (bilateral upper lobe) was 63±10.2. The average duration of the first BT procedure was 43±13 minutes, the second was 45±8 minutes, and the third time was 44±10 minutes. All subjects presented with mild to moderate asthma exacerbations. In three subjects, ground glass opacities were seen in lobes where activation was performed. One patient developed atelectasis in each treated lobe. Although pulmonary functions of all patients worsened one day after BT, improvement in PFTs were observed within 7 days after BT. The AQLQ score showed a clinically meaningful increase before and one month after BT (4.6 to 6.3).

Conclusions

BT was a safe and feasible procedure under general anesthesia. The early results of BT show promise in Japanese patients with severe persistent asthma.

id 102

Tracheal malignancies of successfully treated with bronchoscopic cryosurgery

Yeong Hun Choe, Seung Yong Park, So Ri Kim, Seoung Ju Park, Yong Chul Lee, Heung Bum Lee

Department of Internal Medicine, Chonbuk National University Medical School - South Korea

Introduction

Malignant mass in trachea is frequently found in the forms of direct invasion or metastasis. Several palliative modality such as rigid bronchoscopic surgery or interventional bronchoscopy has been known as effective modality for relieving tracheal obstruction. However, treatment is usually palliative and it is difficult to remove completely.

Methods

In this report, we present two cases of tracheal malignancy successfully removed by cryosurgery. One was 83-year-old male patient who was diagnosed as squamous cell carcinoma located in upper trachea, and another was 76-year-old male patient with metastatic colon cancer in mid-trachea. To restore tracheal patency, we performed cryo-extraction under light sedation. Thereafter, patients was treated with cryoablation for 2 cycles. On follow-up evaluation over 6 months, tracheal malignancies was completely disappeared without any evidence of recurrence.

Conclusions

Cryosurgery with combination of cryo-extraction and cryoablation can be effective technique to treat tracheal malignancy. In selected patient, it may give an excellent outcome of rapid recanalization and complete tumor removal.

id 103

Interventional bronchoscopy as initial treatment in management of central airway obstruction

Sonja Badovinac, Mihovil Roglic, Marta Korsic, Denis Baricevic, Marko Jakopovic, Miroslav Samarzija

Department for Lung Diseases "Jordanovac", University Hospital Center Zagreb - Croatia

Introduction

Central airway obstruction is a possible life threatening condition caused by different benign or malignant diseases requiring rapid intervention. Interventional rigid bronchoscopy is used in initial management and stabilisation of a patient.

Objective

To investigate the role of interventional bronchoscopy in the initial management of central airway obstructions, to evaluate used treatment modalities, and to asses underlying conditions.

Methods

A cohort of 90 consecutive patients presenting with bronchoscopicaly confirmed large airways obstruction who underwent the interventional bronchoscopy during the period of 2 years (2013-2015) were included in the study. Etiology, bronchoscopic techniques and outcomes were analysed from the medical data.

Results

In total 133 rigid bronchoscopic procedures were performed, in 24% of patients repeated interventions were required. The median age of the patients was 59 years (range 21-90). Malignant disease was underlying cause of obstruction in 68%, and benign obstruction was present in 32% of all cases. Primary lung cancer carcinoma comprises 76% of all malignant obstruction cases, and squamous cell carcinoma was the most frequent hystologic type (51%). In the group of patients with benign underlying disease, in 45% the cause was post- intubation stenosis. In performed rigid bronchoscopic interventions following management modalities were exploited: laser-assisted resections, endobronchial electrosurgery, balloon dilatation, argon-plasma coagulation, cryo- recanalization and stent implantation. In 86% of interventions more than one management modality was used, and in 17% of all cases stent placement was required. In total, in 94% of interventions, complete or partial recanalization was achieved (76% and 18% respectively) while in 6% of cases intervention was not successful, mainly due to wide spread of the disease.

Conclusions

Rigid bronchoscopy, with various management modalities, is a useful and effective option in management of central airway obstruction providing palliative therapeutic option for patients with malignant obstruction or stabilisation of the patients requiring further surgical treatment.

id 104

A new endoscopic hand drill technique for the management of web-like tracheal stenoses

Giovanni Galluccio, Sandro Batzella, Paolo Battistoni, Raffaele Dello Iacono, Umberto Caterino, Gabriele Lucantoni

Center of Thoracic Endoscopy, San Camillo Forlanini Hospital - Italy

Introduction

Rigid Endoscopy is the treatment of choice for benign tracheal stenosis when the stenosis is newly detected and surgery is contraindicated. In the endoscopic approach, the Nd-YAG laser photodissection is largely used to make radial cuts through the entire length of stenotic scar tissue prior to mechanical dilatation to avoid tracheal lacerations. However, laser-induced thermic damage of tracheal wall microstructures might contribute to recurrence. The use of cold instrument as endoscopic rigid scissors may be a valid alternative to laser for performing radial cut of web-like stenosis.

Objective

In our paper, we experienced a complementary technique to allow a safe and functional use of forceps using a home-made hand drill to facilitate scissors' resection of web-like stenosis before mechanical dilatation and to avoid the potential thermic damage induced by laser.

Methods

This procedure was performed in 5 consecutive patients with benign web-like tracheal stenosis. Surgery was contraindicated for cerebral (n=1), pulmonary (n=3) and cardiac disease (n=1). All patients previously underwent standard laser resection and a median of 3+1 relapses occurred in median interval of months. All procedures were performed in the operating room using a Dumon rigid bronchoscope. Our tool was assembled sharpening the blunt tip of a standard endoscopic rigid cotton applicator. The tip of instrument drilled the stenotic scar, creating radial holes at 12, 3, and 9 o'clock . Then the tip of endoscopic scissors passed through the holes and cut radially the stenotic scar. Mechanical dilatation with rigid bronchoscopes of increasing diameters completed the procedure. (Figure 1)

Results

This procedure was successfully applied in 5 patients with simple benign tracheal stenosis and unfit for surgery. No intraoperative and/or postoperative complications and relapses were found. No recurrence of stenosis was detected after 2 years follow up.

Conclusions

In conclusion, our method is easy to perform, safe, and facilitates the resection of simple stenotic scar with cold instruments in order to avoid the potential risk that laser thermal damage could predispose to scar formation and relapse.

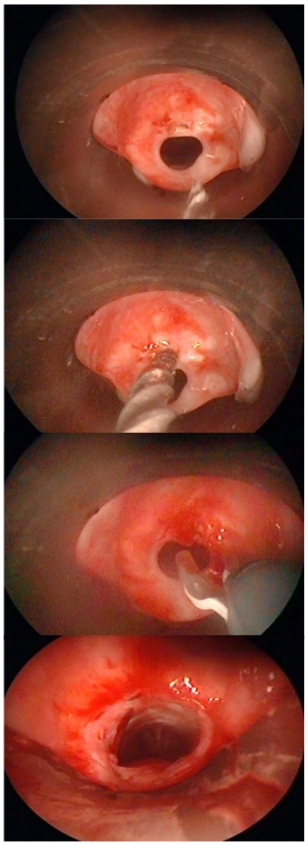

id 105

19th WCBIP / WCBE World Congress
JOINT MEETING OF THE WORLD ASSOCIATION FOR BRONCHOLOGY AND INTERVENTIONAL PULMONOLOGY & THE INTERNATIONAL BRONCHOESOPHAGOLOGICAL SOCIETY
www.wcbipwcbe2016.org
Fortezza da Basso
May 8-11, 2016
Florence (Italy)

A Prospective Randomized Trial Comparing Manual vs Wall Suction in the Performance of BAL

Luis Seijo, Maria Somiedo, Alba Naya, Iker Fernandez, Josefina Manjón, Susana Alvarez, Javier Flandes

Pulmonary Department, Fundación Jiménez Díaz University Hospital - Spain

Introduction

Bronchoalveolar lavage (BAL) may be performed using a hand held syringe or wall suction. Current clinical practice varies, and most centers perform BAL according to established local standards. We report results from a randomized trial comparing both techniques.

Objective

To compare both methods of aspiration in order to determine diagnostic yield and quantity of aspirate.

Methods

220 consecutive patients undergoing BAL at our center were included in this randomized prospective study (Ethics committee approval EO 37/2014_FJD). Manual aspiration was performed using the 50-cc syringe in 115 Group 1 patients, while wall suction applying less than 50 mmHg of negative pressure was used in 105 Group 2 patients. All bronchoscopies were performed under conscious sedation applying topical anesthesia with lidocaine. BAL was performed with 150 cc of saline in 3 aliquots of 50 cc. Microbiologic, immunologic, and cytologic studies were performed as needed.

Results

The mean total amount of fluid recovered was 67+/-20 cc in Group 1 and 55+/-22 cc in Group 2 ($p<0.001$). More patients in the manual aspiration group met ATS criteria (recovery of >30% of instilled fluid) for an optimal BAL (81% vs 59%; $p<0.001$). The quantity of recovered fluid was also related to BAL location ($p<0.001$) and radiologic findings ($p=0.002$). 48 (22%) BALs were diagnostic (23 in Group 1 and 25 in Group 2), including 37 positive bacterial cultures, 6 positive stains for Pneumocystis, and 5 cases of malignancy. No statistically significant difference in diagnostic yield was observed between the two groups. A BAL diagnosis was more likely in patients with certain radiologic ($p=0.033$) and endoscopic findings ($p=0.001$). When taking into account all bronchoscopic techniques performed during the procedure (e.g., biopsies, brushing etc.), bronchoscopy was diagnostic in 37% of patients.

Conclusions

Manual suction is superior to wall suction during BAL yielding a larger quantity of aspirate. Diagnostic yields are similar for both techniques.

id 106

19th WCBIP / WCBE World Congress
JOINT MEETING OF THE WORLD ASSOCIATION FOR BRONCHOLOGY AND INTERVENTIONAL PULMONOLOGY & THE INTERNATIONAL BRONCHOESOPHAGOLOGICAL SOCIETY
www.wcbipwcbe2016.org
Fortezza da Basso
May 8-11, 2016
Florence (Italy)

Utility of medical pleuroscopy in recurrent pleural effusion - single centre retrospective audit

Herman Lam, Matthew Peters, Tajalli Saghaie

Thoracic Medicine, Concord Hospital - Australia

Introduction

Medical pleuroscopy is often considered as a less invasive alternative to surgical thoracoscopy. One of the common indications of this procedure is patients with an exudative pleural effusion in whom analysis of the pleural aspirate has not been diagnostic. The yield in this context has been described in the literature and is comparable to surgical thoracoscopy. On the other hand, in patients with high likelihood of malignant pleural disease, or even with recurrent benign pleural effusion, medical pleuroscopy may provide options for decisive management of the effusion at the time of procedure.

Objective

To evaluate current practice and outcomes of pleuroscopy in recurrent pleural effusions.

Methods

All medical pleuroscopies performed at Concord Repatriation General Hospital in the previous 15 months were audited. As well as evaluating baseline characteristics of the patients and details of the procedure, patient notes were reviewed to confirm the accuracy of diagnosis and to assess outcomes.

Results

22 medical pleuroscopies were performed between July 2014 and October 2015 at Concord Repatriation General Hospital. Average age was 77.5 with a male predominance. Diagnosis was the main indication in 19 procedures; 17 were successful in providing a final diagnosis. 6 were malignant, and TB was found in 4 cases. In 3 patients, the main indication was decisive management of recurrent symptomatic effusion (2 benign, 1 malignant). Decisive management of pleural effusion was attempted in 10 cases. 6 of these were malignant. 7 received spray talc pleurodesis (5 malignant) and 3 received pleurx (1 malignant). Of these 8 were successful and patients did not require further procedures. Except from one in-hospital mortality, which was deemed to be unrelated to the procedure, no other adverse events were observed.

Conclusions

Medical Pleuroscopy not only provides a less invasive alternative diagnostic tool to surgical thoracoscopy, but also a variety of management options in symptomatic recurrent pleural effusions, benign or malignant.

id 107

19th WCBIP / WCBE World Congress
JOINT MEETING OF THE WORLD ASSOCIATION FOR BRONCHOLOGY AND INTERVENTIONAL PULMONOLOGY & THE INTERNATIONAL BRONCHOESOPHAGOLOGICAL SOCIETY
www.wcbipwcbe2016.org
Fortezza da Basso
May 8-11, 2016
Florence (Italy)

Primary pleural intermediate hemangioendothelioma: a case report and literature review

Yuanyuan Li, Juan Jiang

Department of Respirology & Critical care medicine of Xiangya Hospital, Central South University - China

Introduction

A 48-year-old male was diagnosed as primary pleural intermediate hemangioendothelioma in our hospital. We reviewed related literatures on clinical features, diagnostic method, treatment and prognosis of this rare tumor.

Objective

To discuss the clinical course, pathological features, diagnosis and treatment of intermediate hemangioendothelioma, particularly of those that are originated in pleura.

Methods

We conducted a search of the published English literatures since 1990 in MEDLINE and PubMed using search criteria [("primary pleural intermediate hemangioendothelioma") or ("intermediate hemangioendothelioma" and "pleural effusion")]. There is no case of primary pleural intermediate hemangioendothelioma with pleural effusion reported yet. We have also searched for recent advances in diagnosis and treatment of this disease.

Results

Primary pleural intermediate hemangioendothelioma is an extremely rare tumor. Its clinical manifestations are non-specific, and the definitive diagnosis relies on the histopathology of pleural lesions. Surgical resection is the main treatment for intermediate hemangioendothelioma. However, tendency of recurrence and metastasis sometimes exists.

Conclusions

Primary pleural intermediate hemangioendothelioma is an extremely rare tumor. Its clinical manifestations are non-specific, and the definitive diagnosis relies on the histopathology of pleural lesions. Surgical resection is the main treatment for intermediate hemangioendothelioma. However, tendency of recurrence and metastasis sometimes exists.

Bibliography

1.WHO Classification of Tumours of Soft Tissue and Bone 4th ed 2013. 2.Dasgupta R, Fishman SJ. ISSVA classification. Seminars in Pediatric Surgery. 2014; 23: 158-161.

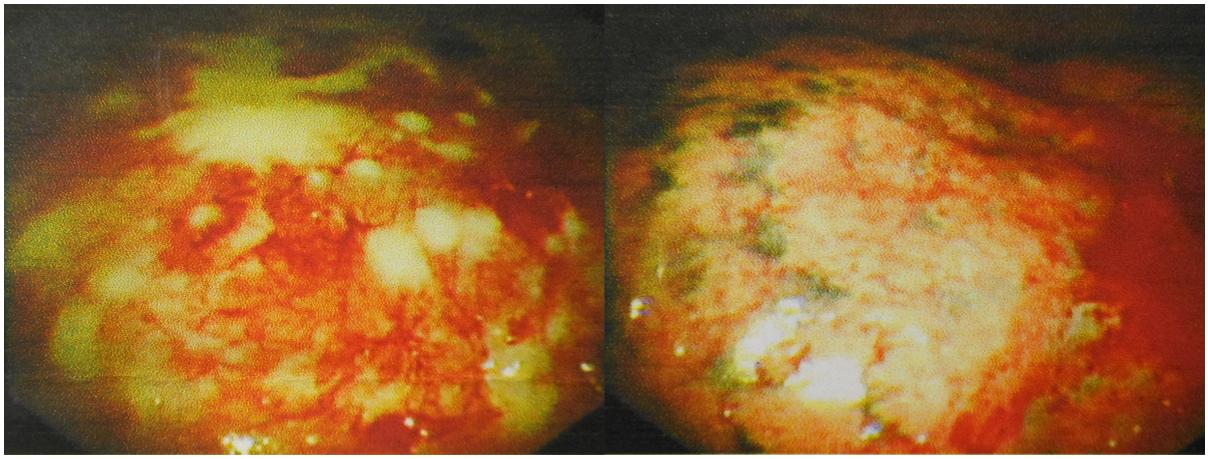

Pediatrics Foreign body aspiration: Role of Fiberoptic Bronchoscopes

Mohammad Ashkan Moslehi

Pediatrics Pulmonology,Chair of WAPID pediatrics section, Shiraz University of Medical Sciences - Iran

Introduction

Foreign body aspiration (FBA) is a worldwide health problem which often results in life threatening complications. The majority of foreign body aspirations occur in children younger than 4 years of age. Aspiration of foreign bodies results in significant morbidity and mortality in children that necessitating prompt recognition and early treatment to minimize the potentially serious and sometimes fatal consequences.

Objective

At present, foreign body removal usually relies on rigid bronchoscopic techniques.

Methods

We started to remove Foreign bodies (FBs) with only fibroptic bronchoscopes (FOB)in pediatrics age group.

Results

The results were amazing! More than One hundred FBs in any type removed by FOB without any complications during 18 months.

Conclusions

I concluded that FOB now is a safe and well tolerate methods for FBs removal in children.

id 109

Doing Bronchoscopy In Neonates: Why ,When, How

Mohammad Ashkan Moslehi

Pediatrics Pulmonology,Chair of WAPID pediatrics section, Shiraz University of Medical Sciences - Iran

Introduction

The small size of the neonates airway, differences in the anatomy of the larynx and the different pathologies according to their age group, make them quite unique and different from adult and also pediatrics too.

Objective

To evaluate the role and success rate of FOB in neonates

Methods

I done more than 150 neonatal ultrathin flexible bronchoscope in about 18 months.Here I want to discuses about Indications, methods,situations and complication possibilities.

Results

My main indications for doing bronchoscpy in neonates were: Evaluation for airways anatomy in congenital malformation Difficult intubation Evaluate the position, patency, or other changes related to Endotracheal Tubes(ETTs),Nasotracheal Tubes(NTTs) or tracheostomy Evaluate granulation formation regarding suctioning Abnormal sounds like Stridors,wheezing,snoring Persistent collapse consolidations,atelectasis Recurrent or / and persistent infiltrations Neonatal coughing Neonatal Chocking episodes Hemoptysis Removal of neonatal some foreign bodies! BAL aspiration Samples Bronchoscopic lung biopsy Remove secretions or mucus plaques Correction of webs, stenotic bronchus

Conclusions

The procedure was well tolerated and completed in less than the minutes.No permanent complication seen in our cases.

id 110

Airway stenosis in Nenonates and children: Bronchoscopy Managments

Mohammad Ashkan Moslehi

Pediatrics Pulmonology,Chair of WAPID pediatrics section, Shiraz University of Medical Sciences - Iran

Introduction

Acquired partial or complete bronchial stenosis is occurring as a common problem in neonatal periods. In infants it is associated with significant morbidity and mortality. Management options for symptomatic stenosis include serial balloon dilation, cryotherapy, laser resection, and open surgical correction.

Objective

To evaluate the role of balloon angioplasty catheters for dilating acquired symptomatic stenotic airway segments.

Methods

I will present 12 infants with acquired symptomatic airway stenosis who underwent angioplasty balloon catheter dilation by fibroptic bronchoscopy.

Results

The technique involved catheter placement under direct vision with a fiberoptic bronchoscope. Balloon expansion was controlled with a hand-held manometer. All infants demonstrated significant lumen size improvement during procedure under direct vision and marked clinical improvement postoperatively. Two infants have required one repeat dilation and have subsequently been asymptomatic after second procedure.Eight neonates tolerate extubation immediately after dilatation.All patients were followed up, and none experienced obvious discomfort.

Conclusions

Stenosis of the tracheobronchial tree can be a life-threatening problem in neonatal period. Balloon catheter dilation can be a successful technique for bronchial stenosis and should be considered prior to attempting more invasive surgical correction.

id 111

Microbial colonization associated with tracheobronchial stents

Susana Álvarez, Josefina Manjon, Iker Fernandez-navamuel, Luis Seijo, Javier Flandes

Interventional Pulmonology Service, Fundación Jiménez Díaz University Hospital - Spain

Introduction

Airway colonization by microorganisms in patients undergoing stent insertion is well known. However, few authors have studied this phenomenon and its impact on patient outcomes.

Objective

To determine the prevalence of airway colonization in patients with indwelling tracheobronchial stents and characterize the microbial flora associated with this phenomenon.

Methods

Retrospective review of all patients with indwelling tracheobronchial stents placed by the interventional pulmonology service at the Fundación Jiménez Díaz University Hospital between 2008 and 2014. A total of 145 stents were placed during the study period, including; 90 silicone stents and 55 self- expandible metallic stents. Nine patients had multiple stents placed during a single or sequential procedure. Median age was 61 years. The majority of patients were male (82; 56.5%). Stent placement was indicated for malignancy in 53.1%, post-operative complications in 8.9%, benign stenosis and malacia in 17.6%, and benign tumors in 1.3%. 18.6% of patients were previously stented and were referred to our unit for stent replacement. Cultures from bronchial aspirates are protocolized and obtained routinely at our center at the time of stent insertion. Consequently, baseline microbiologic cultures were available for review in 138 patients (94.5%). Surveillance cultures are also protocolized at our center and were available for 109 patients (76.5%) undergoing surveillance bronchoscopy. Stents were inserted in the trachea in 38%, left mainstem bronchus in 19.3%, and right mainstem bronchus in 18%. The remaining 24.7% were placed in other bronchi.

Results

Thirty-nine patients had positive cultures at the time of stent insertion (28.5%). Multiple pathogens were isolated in 6 cases. S. aureus and P. aeruginosa were the most common isolates in 22.2% and 20% of cases respectively. Fifty-four patients had positive cultures at the time of surveillance bronchoscopy (49.1%) including 4 patients with polymicrobial isolates. S. aureus and P. aeruginosa were the most common isolates in 38% and 27.6% respectively.

Conclusions

Patients undergoing airway stenting frequently have positive cultures at the time of stent insertion and airway colonization rates increase at the time of surveillance bronchoscopy. S. aureus and P. aeruginosa are the most common isolates.

id 112

Management of malignant and nonmalignant central airway obstructions (CAO) and fistulas by Y stents

Gábor Grmela, Zsolt Pápai Székely

Pulmonology, Fejér County St. George University Teaching Hospital - Hungary

Introduction

There are several malignant and nonmalignant aethiologies of CAO. No exact hungarian data is available regarding the number of cases due to scarce centers treating such conditions.Management of carinal region necessitate special tools, trained bronchologist, requiring thorough experience and multimodality approach.The topic is very important: approximately in 20-30% of lung cancer patient develop airway obstruction complicating the course of the disease (atelectasis,pneumonia, severe dyspnoe) and locoregional progression has been responsible for 40% of lung cancer death.On the other hand increasing number of patient are requiring mechanical ventillation resulting increasing number of postintubation tracheal stenosis cases despite of implementation of modern high volume low pressure endotracheal tubes.In some cases : long, complex stenosis affecting near the total trachea or involving the carina, only Y stent can be the right solution. And finally fistulas close to the carinal region,or malignant esophagotracheal fistulas requiring double stenting, or large fistulas of the trachea can be sealed securely only by Y stent. Two stent types and insertion technic have been used since 2004 in our national center.(Novatec Y stent, Dynamic Y stent, Tonn applicator system, and Freitag applicator forceps)

Objective

Single center hungarian experience on 131 patients between 2010 and 2015

Methods

retrospective analysis our patient's charts

Results

131 Y stents were deployed successfully on wide range of aethyologies

Conclusions

Y stents can be applied safely and successfully for benign and malignant airway stenosis and fistulas involving the carinal region in experienced centers

Figure 1. Underlying causes of CAO requirering Y stent insertion in 86 patients(90

(2004-2012,Szekesfehervar,Hungary)

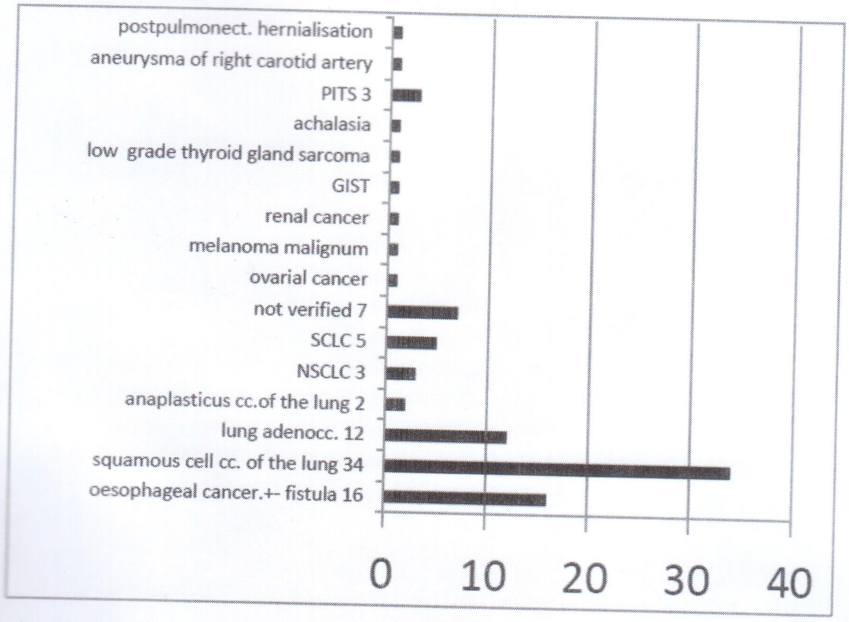

19th WCBIP / WCBE World Congress
JOINT MEETING OF THE WORLD ASSOCIATION FOR BRONCHOLOGY AND INTERVENTIONAL PULMONOLOGY & THE INTERNATIONAL BRONCHOESOPHAGOLOGICAL SOCIETY
www.wcbipwcbe2016.org
Fortezza da Basso
May 8-11, 2016
Florence (Italy)

Mitomycin C as an adjunctive treatment to the mechanical dilatation of tracheobronchial stenosis

Alberto González Estébanez, Francisco R. Villegas Fernández, Jacobo Sanchez Randulfe, Maria Castro Otero, Andrés Rodero Baño

Pneumology, Defense Central Hospital "Gómez Ulla" - Spain

Introduction

The use of Mitomycin C as an adjunctive treatment to mechanical dilation of the stricture endoscopically tracheobronchial is spreading in recent years as a preventive measure that could reduce the incidence of re-estenosis after endoscopic treatment. Our Center with extensive experience in endoscopic treatment of tracheobronchial stenosis leads using Mitomycin C from 2010 to selected cases where there is a short segment tracheal or bronchial injury in which there is no significant destruction of the underlying cartilage and in which is bet by endoscopic recanalization as sole treatment of input.

Objective

The main objective of this study is to evaluate the efficacy and safety of the technique based on our methodology.

Methods

Retrospective and descriptive studies collected from the patients listed in the register of treatments of stenosis tracheobronchial through bronchoscopy, rigid and impregnation of mucosal tissue swab of Mitomycin C in the Central defense Hospital ¨gomez Ulla¨ between May 2010 and July 2014. Results 7 patients (5 women, 2 men), treated with Dyspnea and stridor clinic by stenosis tracheobronchial benign etiology (5 idiopathic, 1 post infectious TB and 1 Post-reseccion of bronchial Hamartoma). After assessment by a multi-disciplinary Committee decided the endoscopic as first choice treatment, to be considered good candidates for the anatomic alteration that presented and severe comorbidity that is added in several cases. In all patients the same procedure took place: in the operating room, under deep sedation controlled by anesthesiologist is rigid Bronchoscopy using the following procedure: -With traqueoscopio intubation; laser therapy with Laser YAG-Nd (0, 7sg / 20-30W); mechanical resection of strictured area; Esophageal dilatation (15mm) pneumatic Balloon dilatation; photocoagulation with Argon-plasma and finally, topical impregnation of stenotic swab of Mitomycin C zone (0, 1-0, 3 mg/ml, solution) for 1 minute / 5 sessions.

Results

As results are worth mentioning: - The disappearance of the respiratory symptoms in the treated patients. - A unique complication (severe asphyxial crisis resolved by new laser therapy). - A case of Restenosis which pointed out 2 new treatments for its resolution. - No need for further surgery or prosthesis placement.

Conclusions

The topical application of Mitomycin C, under our experience, shown as an efficient and effective agent in the treatment of treated endoscopically tracheobronchial stenosis by: - Minimize surface treated. - Minimize the time of hospital stay. - Few complications. - Reduce costs for all of the foregoing.

Bibliography

1 Chen et to the; Respiration. 2013; 83 (6): 500-4. 3 Maldonado, f. et to the; Laryngoscope. 2014 Feb; 124 (2): 498-503.

Fiberoptic Bronchoscopic cryo-ablation of central bronchial lung cancer

Ahmed Shawky

Chest Department, Tanta University Hospital - Egypt

Introduction

Lung cancer is the leading cause of death from malignant disease in the world and represents > 17% of all new cases of cancer and 28% of all cancer deaths worldwide.Approximately 30% of inoperable patients with carcinoma of the lung present with obstruction of the central airway, which can cause distressing symptoms of cough, breathlessness, hemoptysis and recurrent infections.Interventional bronchoscopy, particularly therapeutic bronchoscopy, includes many diverse modalities, such as the Nd:YAG laser, electrocautery, argon plasma coagulation, photodynamic therapy, airway stenting, brachytherapy, and cryotherapy, which all have advantages and disadvantages.The advantage of endobronchial cryotherapy is that it has proven effective with minimal complications. It is also relatively easy to use and economical compared with other therapeutic modalities. Cryotherapy is safe, with no danger of bronchial wall perforation.

Objective

Current short-term follow-up study aimed to evaluate safety and clinical efficacy of flexible cryoprobe as an important option to treat the patients with inoperable obstructive central bronchial lung tumours , that may provide the potential for long-term survival (2nd part of this sudy).

Methods

In this study, a total of 38 patients with an endobronchial malignant lesion, previously determined bronchoscopically, were recruited from Chest,Oncology departments,Tanta University from June 2014, to May 2015.Inclusion criteria: Histologically proven carcinoma of the trachea and bronchi; Inoperable carcinoma based on the position of the tumor, performance status or poor respiratory function, and Predominantly, Intraluminal tumors.Exclusion criteria: Eminently respiratory distress and Uncorrectable bleeding diathesis.After obtaining informed consent, All procedures were carried out during flexible bronchoscopy with a working channel of 2.6 mm (BF-IT10; Olympus America; Melville, NY). the bronchoscopy was done in a standard fashion with topical anesthesia (5% lidocaine).A flexible cryoprobe measuring 90 cm in length and 2.4 mm in diameter was used (ERBE, Germany). The probe was cooled with co2 which allowed to decrease the temperature in the probe’s tip to –70 ° C within several seconds.

Results

There was significant symptomatic improvement after 2 and 6 weeks; Resolution of lung collapse in 60% of patients after 2 weeks, with resolution of lobe atelectasis in ~76% (n=29) of patients after 6ws.Patients (n=9) with persistent lung collapse included patients with partly and not removed tumours (n=6), with thick secretion (n=3), and with progressed extra-luminal compressive tumour (n=2).

Conclusions

In our case series, we reported the successful use with high safety profile of cryotherapy with flexible bronchoscopy to improve airway.The key efficacy outcomes are improved respiratory function and quality of life.

Bibliography

Korean J Intern Med 2011;26:132-134).

The presenting author has the following conflicts of interest that relate to this abstract: *Intervention bronchoscope, Cryotherapy.*

id 115

19th WCBIP / WCBE World Congress
JOINT MEETING OF THE WORLD ASSOCIATION FOR BRONCHOLOGY AND INTERVENTIONAL PULMONOLOGY & THE INTERNATIONAL BRONCHOESOPHAGOLOGICAL SOCIETY
www.wcbipwcbe2016.org
Fortezza da Basso
May 8-11, 2016
Florence (Italy)

Clinical Analysis of bronchial foreign body in 1030 children

Yuyan Ma, Anxia Jiao, Xiaochun Rao, Xicheng Liu

Interventional pulmonology, Beijing Children's Hospital, Capital Medical University - China

Introduction

Bronchial foreign body is a commom disease in children.It needs diagnosis and therapy as early as possible.

Objective

To analyze the characters of bronchial foreign body in children and the utilization of the electrobronchoscope in treatment of bronchial foreign body.

Methods

The study was performed in 1030 children diagnosed with bronchial foreign body during 2000.1~2015.6 in Beijing children's hospital. Under local mucosa anesthesia, electrobronchoscope(Olympas) was inserted through nasal cavity, glottis, then into bronchial. After the definition of the site of foreign body, grasping forceps was insert through bronchoscope and clear away foreign body from airway.

Results

In 1030 cases, male: female=696:334. 1~3 years old child was 953 cases. The mobility had no seasonal character, but the case number increased in 2-3months after spring festival. Hard nut was in 787cases (76.4%), skin of melon seed was in 142 cases (13.8%), metal is in 2 cases, other kinds of foreign body was in 99 cases. According to the site of foreign body , there were 318 cases in right lower lobe bronchial , 223 cases in left lower lobe, 254 cases in left or right main bronchial, 39 cases in right upper lobe, 13 cases in right middle lobe , 36 cases in left upper lobe and 27 cases in left linguist lobe. Multisite bronchial-foreign body in 120 cases.The average operation times was 1.24±0.75, one-time operation achievement ratio is 87.4%. the one-time operation achievement ratio of patients whose foreign body obstructed in main bronchial(100%) , right lower lobe(83.1%) and left lower lobe(86.5%) was higher than others. The operation times using basket grasping forceps(1.08±0.39) was lower than those using tooth types forceps(1.94±1.30),the difference was significant(P=0.000), especially to massive hard nut.

Conclusions

In conclusion, the prevalence of bronchial foreign body in boys was higher than girls. The most of cases were 1~3 years old child. The type of bronchial foreign body was a lot ,but hard nut mass and skin of melon seed was the most cases. The right and left lower lobe bronchial and main bronchial were predilection site, and were easier to be clean out by grasping forceps. To massive foreign body, basket grasping forceps was better than tooth grasping forceps.

id 116

A rare case of a giant hamartoma causing a central airway obstruction

Sadia Benzaquen[1], Michael Gabrilovich[2]

[1]Interventional Pulmonology, University of Cincinnati - Usa
[2]Pulmonology and Critical Care Medicine, Fort Hamilton Hospital - United States

Introduction

Pulmonary hamartomas are usually found in adults with a peak incidence in the sixth decade, there is a male preponderance, the male:female ratio being 2:1 to 3:1. Pulmonary hamartomas are often asymptomatic and they are typically discovered as an incidental coin lesion on a routine chest radiograph. Radiologically, hamartomas account for 7% to 14% of pulmonary coin lesions. Only 1.4% of hamartomas are located endobronchially. We present a rare case of a giant hamartoma obstructing the central airway in elderly female, successfully treated with rigid bronchoscopy and laser therapy.

Methods

81 yo female presented with severe intractable dry cough in spells associated with left sided pleuritic chest pain and progressing shortness of breath of one week duration. Prior to that she has had no respiratory symptoms or limitations. She is lifelong nonsmoker without significant occupational exposures or family history of lung diseases. Chest imaging demonstrated left upper lobe and lingular collapse with what appears to be endobronchial lesion (Figure 1A). Bronchoscopy was performed. Left upper division was completely obstructed by endobronchial round vascularized mass with smooth surface (Figure 1B). Endobronchial biopsies and transbronchial needle aspirates from the mass were obtained. This was reported to be nonspecific. Second bronchoscopy was performed with multiple needle and forceps core biopsies. Acute inflammation, fibrosis and myxoid changes were seen. Of note, tumor hasn't bled extensively with sampling. The patient underwent rigid bronchoscopy with NDYAG laser destruction with total opening of the left upper lobe and distal left mainstem bronchus. The histology reported a hamartoma that usually presents at the lung parenchyma or distal in the airways. Her symptoms have markedly improved after the procedure.

Conclusions

Hamartoma was thought to arise from embryologic residuals that were present in fetal life but generally did not become visible until adulthood. However, a cytogenetic analyses of the pulmonary hamartomas show an abnormal karyotype and reveal recombinations between chromosomal bands 6p21 and 14q24, thus supporting the opinion that a hamartoma of the lung is a true neoplasm. Pulmonary hamartoma can occur in all parts of lung, but most often, they are found in the periphery and rarely seen obstructing central airway, particularly in elderly women as described in our case. Endobronchial interventions can successfully restore airway patency.

Bibliography

Rai SP, Patil AP, Saxena P, Kaur A. Laser resection of endobronchial hamartoma via fiberoptic bronchoscopy. Lung India?: Official Organ of Indian Chest Society. 2010;27(3):170-172. doi:10.4103/0970- 2113.68329.

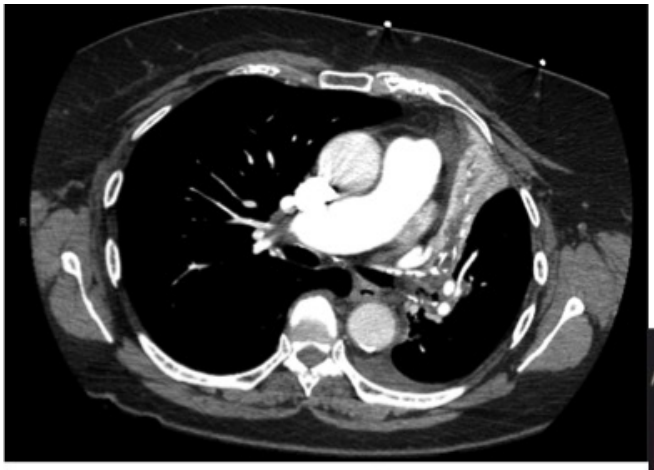

Figure 1A: CT of the chest with collapse of left upper lobe and lingula.

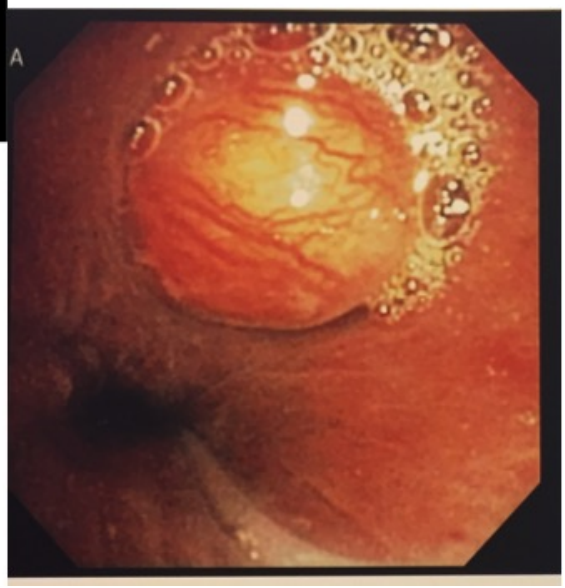

Figure 1B. Endobronchial lesion obstructing left upper division

id 117

A Michelin star chef has several knifes-Endoscopic ultrasound (EUS) performed by Pulmonologist

Pik-shan, Alice Cheung[1], Tai-chiu Wong[2], Chung-ming Chu[1], Kam-ngai Kung[2]

[1]Division of Respiratory Medicine, Department of Medicine & Geriatrics, United Christian Hospital - Hong Kong Sar
[2]Division of Gastroenterology & Hepatology, Department of Medicine & Geriatrics, United Christian Hospital - Hong Kong Sar

Introduction

Endoscopic ultrasound (EBUS) has revolutionized the diagnosis and staging for lung carcinoma. It has replaced the invasive mediastinoscopy with a comparable sensitivity and a much lower risk as well as mortality. EUS (endoscopic ultrasound) shares the similar efficacy of EBUS while it is much better tolerated especially in patients with poor lung reserve.

Objective

We reported our initial experience with EUS-FNAC (fine needle aspiration) performed by respiratory physician in a consecutive cohort of selected patients.

Methods

A two year (2013-15) retrospective cohort examining a consecutive patient series with radiological diagnosis of lung cancer underwent EUS-FNAC using the EUS scope (OLYMPUS GF TYPE UC240P-AL5).

Results

EUS was performed in 55 patients (40 male, 15 female) with majority (80%) of them were symptomatic on presentation (Respiratory 60%, constitutional 30.5%, miscellaneous 9.5%). EUS-FNAC was the first diagnostic investigation in more than half of the patients (56%), the remaining patients had undergone prior undiagnostic investigations including bronchoscopy, CT guided FNAC or EBUS. The mean volume of sedation used was 3.9±0.3mg of diazemul and 13.8±0.2mg of pethidine. Sixty-five nodes were biopsied from various sites (31 station seven, 7 station 4L, 11 matted mediastinal mass, 5 right paratracheal mass, 7 left paratracheal mass, 3 left adrenal and 1 celiac node) FNAC had revealed malignancy in 35 patients (63%) with majority were non- small cell carcinoma (n=28, 79.4%), 4 suspicious of malignancy, 1 atypical lymphoid proliferation, 4 infection (2 AFB smear positive, 1 Penicillium, 1 lung abscess) and 9 no malignant cell. EUS was aborted in 2 patients due to inaccessibility of lesion or significant bleeding tendency during the procedures. Six out of 9 patients with the EUS-FNAC showed no malignant cell had confirmed malignancy either by subsequent investigation or radiological deterioration. The diagnostic yield of EUS-FNAC in our series was 85%. For complication, 1 patient was admitted for small pneumothorax which did not require intervention.

Conclusions

In selected patients who have favorable anatomy or poor lung function, EUS- FNAC can be considered the sole mode of investigation. Our EUS series was performed by respiratory physician who is familiar of the intra-thoracic anatomy, using the EUS scope which can provide a better visualization and a lower dose of sedation. EUS is well tolerated even for patients who were precluded from endobronchial investigation due to poor lung function. Every chef has a knife; a Michelin star chef shall have more than one knife.

id 118

19th WCBIP / WCBE World Congress
JOINT MEETING OF THE WORLD ASSOCIATION FOR BRONCHOLOGY AND INTERVENTIONAL PULMONOLOGY & THE INTERNATIONAL BRONCHOESOPHAGOLOGICAL SOCIETY
www.wcbipwcbe2016.org
Fortezza da Basso
May 8-11, 2016
Florence (Italy)

A retrospective study of the peroperative complications following whole lung lavage in the treatment

Ziqing Zhou

Bronchoscopic center, Department of Respiratory Medicine, State Key Laboratory of Respiratory Disease, National Clinical Research Center for Respiratory Disease, Guangzhou Institute of Respiratory Disease, First Affiliated Hospital of Guangzhou Medical University, Guangzhou, G - China

Objective
To evaluate the safety of the precesure of whole lung lavage for pulmonary alveolar proteinosis(PAP).

Methods
In this retrospective study, we enrolled PAP patients over 5 years in our hospital. Analyze the cause of the peroperative complications.

Results
44 PAP patients were underwent 72 precesures of WLL. 19 (27.9%) of the 72 procedures developed complications. 19 compications were observed in 15 paitents, Including: pleural effusion(n=4), pneumonia(n=3), atelectasis(n=2), cardiac failure(n=2), cardiac arrhythmias(n=2), hydropneumothorax(n=2), bleeding(n=1), laryngeal edema(n=1), pleural effusion and pneumonia(n=1). All complications are mild and easy to treat. Age, DSS, PaCO2 and FEV1 were not predictor of any complications(each $p>0.05$). there was a negetive correlation between fluid recovering rate and the complications ($p<0.05$).

Conclusions
Whole lung lavage is a safe procedure in the treatment of patients suffering pulmonary alveolar proteinosis. Complications could recover after proper therapy. The peroperative complications display an inverse correlation with fluid recover rate. operation under guideline is the key to avoid complications.

id 119

19th WCBIP / WCBE World Congress
JOINT MEETING OF THE WORLD ASSOCIATION FOR BRONCHOLOGY AND INTERVENTIONAL PULMONOLOGY & THE INTERNATIONAL BRONCHOESOPHAGOLOGICAL SOCIETY
www.wcbipwcbe2016.org
Fortezza da Basso
May 8-11, 2016
Florence (Italy)

Comparison of positive lymph node on CT or PET-CT with EBUS-TBNA in pneumoconiosis patients

Chang Dong Yeo

Internal Medicine, The Catholic University of Korea - Seoul

Introduction

Pneumoconiosis patients often show false positive lymph node (LN) involvement by computed tomography (CT) or positron emission tomography (PET)-CT, which is difficult to distinguish from malignant involvement of lung cancer.

Objective

The purpose of this study was to evaluate positive mediastinal LN on CT or PET-CT by using EBUS-TBNA in pneumoconiosis patients suspicious of lung cancer.

Methods

Twenty-two pneumoconiosis patients who were suspicious of lung cancer between May 2009 and May 2013 were analyzed in the study.

Results

All patients had at least one positive mediastinal LN on CT or PET-CT. Microscopic examination by EBUS-TBNA revealed dark pigmentations of LNs from all patients. Among 22 patients, 16 (72.7%) patients were diagnosed as lung cancer. Of these, only 7 patients were confirmed as malignancy or atypical cells at least 1 lymph node by EBUS-TBNA. A total of 42 LNs were analyzed. Of these, the number of pathologic confirmation as malignant, atypical and reactive LNs were 5 (11.9%), 3 (7.1%) and 34 (81.0%), respectively. The mean value of size and SUV were not different comparing malignant and atypical LNs with reactive LNs (11.93±4.24 vs. 10.04±3.82, P=0.718; 6.67±2.99 vs. 5.15±2.21, P=0.923).

Conclusions

In patients with pneumoconiosis, mediastinal lymphadenopathy can be misdiagnosed by CT or PET-CT. The size of LNs and the SUV value in the PET-CT did not have an effect on differentiating malignant LNs from reactive LNs. Therefore, procedure like EBUS-TBNA should be considered to evaluate suspicious lymph node involvement.

id 121

Analysis of false positive lymph node on CT or PET-CT confirmed by EBUS-TBNA in lung cancer

Seung Joon Kim

Internal Medicine, The Catholic University of Korea - Korea

Introduction

Endobronchial ultrasound-guided transbronchial needle aspiration (EBUS-TBNA) is necessary to evaluate suspicious lymph node involvement of lung cancer because computed tomography (CT) or positron emission tomography (PET-CT) have limitations in its low sensitivity and specificity. There are several benign reasons that can cause false positive lymph node such as anthracofibrosis, old or active tuberculosis or other infectious conditions.

Objective

The purpose of this study was to evaluate possible causes of false positive lymph node by CT or PET-CT.

Methods

Two hundred forty-seven patients who were initially diagnosed with lung cancer between May 2009 and December 2012, and underwent EBUS-TBNA for confirmation of suspicious lymph node involvement by CT or PET-CT were analyzed in the study.

Results

Bronchial anthracofibrosis, old or active tuberculosis, infection such as pneumonia tended to be related with negative lymph node involvement by EBUS- TBNA, but statistically insignificant. However, there was positive relation to false positive lymph node involvement with increased age.

Conclusions

These findings suggest that lung cancer staging should be done more carefully when a patient has clinically benign lymph node characteristics.

id 122

19th WCBIP / WCBE World Congress
JOINT MEETING OF THE WORLD ASSOCIATION FOR BRONCHOLOGY AND INTERVENTIONAL PULMONOLOGY & THE INTERNATIONAL BRONCHOESOPHAGOLOGICAL SOCIETY
www.wcbipwcbe2016.org
Fortezza da Basso
May 8-11, 2016
Florence (Italy)

3D endobronchial ultrasound (EBUS): a human pilot study

Hanne Sorger[1], Erlend Fagertun Hofstad[2], Tore Amundsen[1], Thomas Langø[2], Håkon Olav Leira[1]

[1]Dept Thoracic Medicine, St Olavs Hospital and Dept of Circulation and Medical Imaging (ISB), Faculty of Medicine, Norwegian University of Science and Technology (NTNU) - Norway
[2]Dept Medical Technology, SINTEF Technology and Society - Norway

Introduction

Endobronchial ultrasound transbronchial needle aspiration (EBUS-TBNA) in lung cancer staging is currently shifting towards systematic mapping of mediastinal lymph nodes[1]. Endoscopy precision, speed and technique are challenged. Real-time anatomical overview is crucial for correct clinical decision-making. EBUS is not directly linked to preoperative computed tomography (CT) images, and displays one 2D ultrasound (US) image only. Multimodal image guiding systems visualize out-of-plane structures, and may therefore be of value during EBUS-TBNA. An electromagnetic (EM) navigated EBUS system was recently presented[2], allowing 3D EBUS reconstruction based on a sequence of tracked 2D EBUS images. 3D EBUS might confirm needle position, improve precision, safety and procedural documentation of EBUS-TBNA.

Objective

The main study objective was to demonstrate the clinical feasibility of intraoperative 3D EBUS in lung cancer patients, using a multimodal image guiding system.

Methods

Four consecutive, non-randomized patients referred to the thoracic department for lung cancer staging with EBUS-TBNA were enrolled in the study. Models of predefined target lymph nodes, airways and vessels were extracted from preoperative CT images. EBUS was performed according to local standards under conscious sedation, using a prototype EBUS bronchoscope with an integrated EM tracking sensor for navigated EBUS. Video-bronchoscopy and EM navigation localized the approximate target position. Exact lymph node localization, visualization and TBNA sampling were guided by EM navigated EBUS (Fig 1, top) and 3D EBUS. 2D EBUS images were used for target confirmation. 3D EBUS reconstruction (Fig 1, bottom) was performed by swiping the EBUS probe over the entire lymph node target while acquiring 100-200 2D US images in 4-8 seconds. After the procedure, the position coordinates of all targets in CT and 3D EBUS were determined, and the position deviation representing 3D EBUS accuracy was calculated. Procedural time, diagnostic yield and adverse events were recorded for all patients.

Results

3D EBUS was feasible for localization and visualization of all target lymph nodes during EM navigated EBUS-TBNA (4R node example in Fig1). The overall position accuracy (seven lymph nodes, 11 measurements) of 3D EBUS was 9.99 mm, maximum 17.59 mm, minimum 4.47 mm. Diagnostic yield was obtained in 13/16 TBNA punctures (81.3%). No additional preparations or personnel, adverse events or excess time consumption were registered.

Conclusions

Intraoperative 3D EBUS using a multimodal image guiding system was feasible, safe and easy in this human pilot study. 3D EBUS facilitated target localization, improved anatomical overview, provided procedure documentation, and might increase EBUS-TBNA precision and diagnostic yield. Extended human pilots are on-going.

Bibliography

[1] De Leyn P et al. Eur J Cardiothorac Surg 2014;45(5):787-98 [2] Sorger H et al. Eur Respir Journal Sept 2014, 44 (Suppl 58)

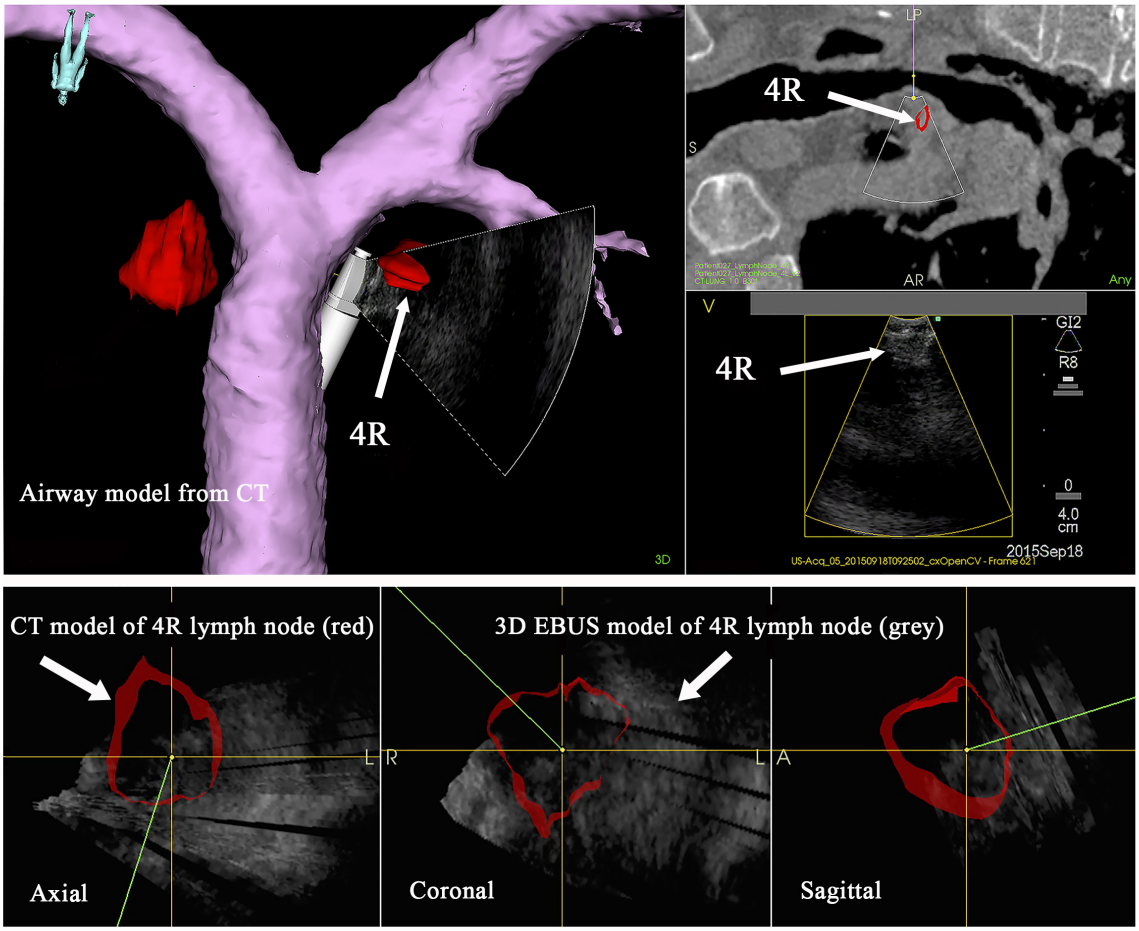
4R
Airway model from CT
3D
LP
S
AR
Any
V
GI2
R8
0
4.0
cm
2015Sep18
US-Acq_05_20150918T092502_cxOpenCV - Frame 621

CT model of 4R lymph node (red)
3D EBUS model of 4R lymph node (grey)
L R
L A
Axial
Coronal
Sagittal

id 123

B-CPAP Bronchoscopy in chronic hypoxemic patients

Carmine Guarino, Cristiano Cesaro, Giuseppe La Cerra, Luca Longobardi, Giuseppe Iepparelli, Osvaldo Della Gatta

Dipartimento di Pneumologia e Onclologia, U.O.C. di Broncologia AORN Dei Colli - Monaldi di Napoli - Italia

Introduction

Diagnostic Bronchoscopy, in chronic hypoxemic patients with normo/hypocapnia is not always feasible, although the standard oxigen delivery, for the clinical severity or comorbidity.

Objective

In this perspective study, we employed, in patients with chronic hypoxemic respiratory insufficiency,in support of spontaneous breathing, a Boussignac Continuous Positive Airway Pressure (CPAP) system (Positive End-Expiratory Pressure of 3-5 cmH2O) and a EtCo2 detection device to cope to hypoxia further induced by the same bronchoscopy, especially during the BAL and the biopsy techniques.

Methods

70 spontaneusly breathing patients in topical anesthesia (40 males 30 females median age 64,30) with PaO2/FiO2 209-249, underwent bronchoscopy with B-CPAP system facemask. Blood pressure, ECG ,oximetry, paCO2, heart and respiratory rates ,EtCO2 have been monitored. FOB' s average duration was 15,5+4,6 minutes. Exclusion criteria: method intolerance, severe arrhythmias, haemodynamic instability(systolic blood pressure < 90 mmHg), pneumothorax and pneumomediastinum. Inclusion criteria: PaO2/FiO2<250, dyspnea at rest (BORG 3- 4), respiratory rate >20 breaths/min. EGA was made before, during and after bronchoscopy.

Results

Procedures were 26 BAL, 28 TBNA, 16 Lung biopsy (BLB), , in 16 lung cancer, 9 COPD, 26 interstitial lung disease, 4 atelectasis post thoracic surgery, 4 mediastinal linphoproliferative malignancy, 4 pneumonia in cardiac transplant and 7 pneumonia in ischemic and bivalvolar heart disease. PaO2/FiO2 values increased at the end of treatment to 275,15 ± 21,70 p<0.003 and during B-CPAP to 410,71 ± 44,63 p< 0,0001. The Histogram showed heart rate, respiratory rate, SpO2 and PaCO2, in three moments of the procedure: at starting, during and at ending.

Conclusions

B-CPAP system, during bronchoscopy, has been viable alternative to the endotracheal intubation and mechanical ventilation, expecially in chronic hypoxemic COPD patient. B-CPAP system allowed the airway direct visualization and to execute BLB and TBNA for staging of lung and mediastinal cancer and also the cytological study in the interstitial pneumopathy through BAL. In all cases, treated with only topical anesthesia, the broncoscopy was completed without subsequent cardiac or respiratory complications and with a satisfactory tolerance, sending patients to the department of origin after one hour of observational time and never to intensive therapy ward.

Bibliography

1)Baumann et al. Critical Care 2011 15:R179 2)Antonelli M. Critical Care 2011 15:191 3)Esquinas A. et al. Arch. Broncopneumol. 2013;49:105-12

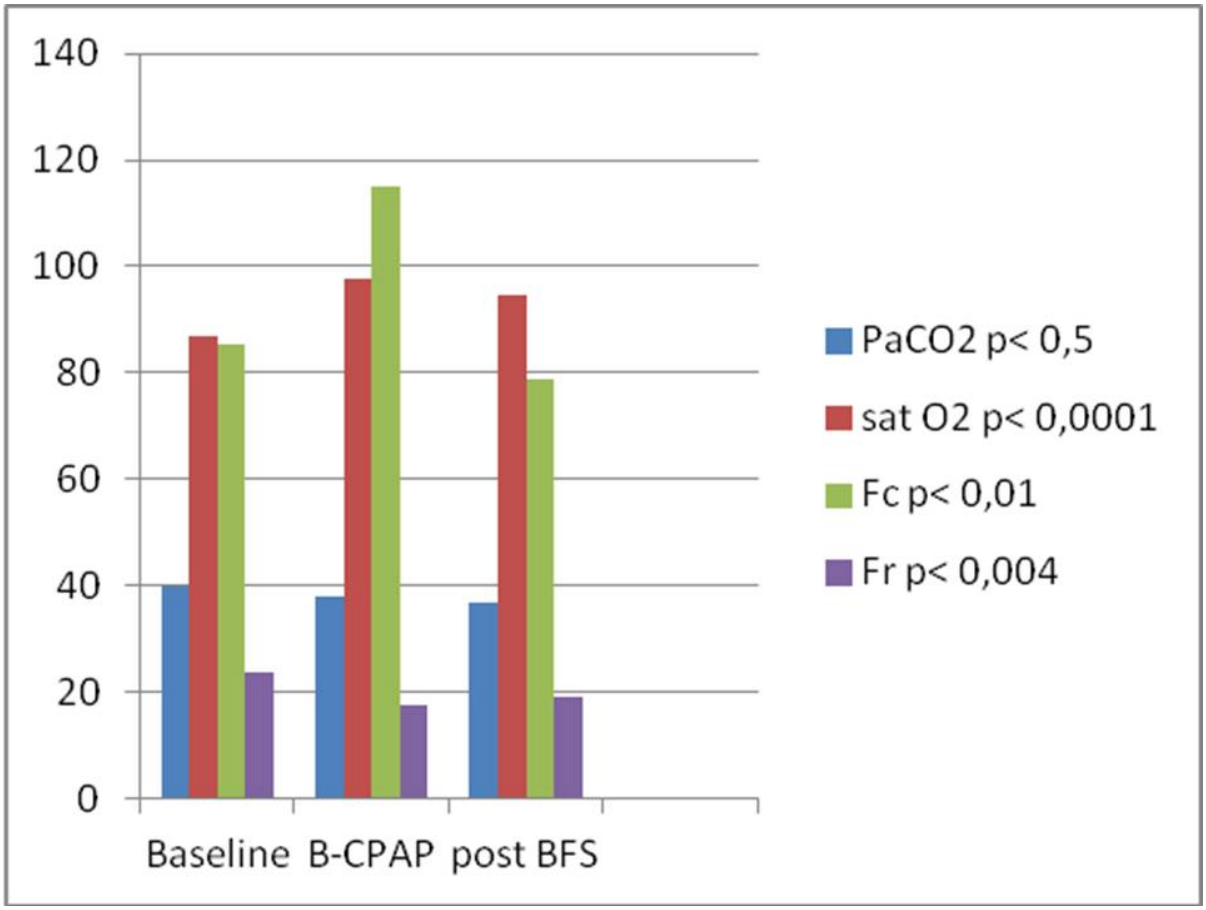
140
120
100
80
60
40
20
0
Baseline
B-CPAP
post BFS
PaCO2 p< 0,5
sat O2 p< 0,0001
Fc p< 0,01
Fr p< 0,004

id 124

VATS empyemectomy in patient with unresolved TB due to loculated pleural empyema

Falvio Montinaro[1], Kety Luzi[2], Beatrice Adriani[3], Lin I Liang[3], Donatella Aquilini[3], Francesco Falli[1], Luca Romoli[1], Tiku Zalla[1], Vito Silvestri[4], Mirko Murtigni[4], Maria Caterina Truglia[5], Giuseppe Albanese[6], Marco Scatizzi[1]

[1]General and Oncologic Surgery Unit, Santo Stefano Hospital, ASL 4 Prato - Italy
[2]Infectious Disease Unit, Santo Stefano Hospital, ASL 4Prato - Italy
[3]Infectious Disease Unit, Santo Stefano Hospital, ASL 4 Prato - Italy
[4]Intensive Care Unit, Santo Stefano Hospital, ASL 4 Prato - Italy
[5]Anatomic Pathology Unit, Santo Stefano Hospital, ASL 4 Prato - Italy
[6]Radiology Unit, Santo Stefano Hospital, ASL 4 Prato - Italy

Introduction

Pleural tuberculosis is the most common form of extrapulmonary TB and generally is present since the first diagnosis or occurs few months later due to the intrapleural rupture of a pulmonary focus or to the spillage of a tuberculous node in the pleura. Standard chemotherapy regimen heals most cases of primary pulmonary TB also with pleural involvement but rarely is necessary complementary surgical treatment to achieve recovery.

Methods

We present the case of a 37 years old man immigrant to Italy from China in 2010. He was hospitalized in January 2015 for right pneumonia and contralateral pleural effusion. We carried out empirical antibiotic therapy as a community-acquired pneumonia and drainage of pleural effusion. The exam of pleural fluid showed white blood cell 2568/microl with lymphocytes 73% and the chest computed tomography (TC) showed a nodular infiltrate in the apical- subapical-posterior areas of the upper right lobe associated with cavity formation and left pleural effusion. Given the hypothesis of tuberculosis, the patient was admitted to the Infectious Disease Unit and on 15th January started the anti-TB treatment with isoniazid (INH), pyrazinamide (PZA), ethambutol (EMB), and rifampin (RIF). HIV and HCV test was negative, previous hepatitis B. All acid-fast smear and cultures at sputum and bronchoscopy was negative. PCR for M.tuberculosis at bronchoscopy and pleural fluid culture was positive for Mycobacterium tuberculosis susceptible to all first-line anti-TB drugs. He was discharged in 19/01/2015 in good health. TB treatment was simplified after 2 months with INH and RIF. A radiologic monitoring in July showed a left posterior-basal loculated empyema. TB treatment with INH and RIF was maintained and we carried out video-assisted- thoracic surgery (VATS) empyemectomy. Acid fast stain of intraoperative pleural fluid sample was positive, mycobacterial culture was in process; no fungi or bacteria were detected at fluid culture. The patient maintain good condition after surgery, pleural drainage was removed after 7 days. We repeated acid fast stain of drainage pleural fluid after 7 days and it was negative; bacterial and fungi culture was negative again. Pleura histological examination showed necrotizing granulomatous inflammation. Patient was discharged 12 days after VATS in good condition. He continues the antimicrobial therapy with INH and RIF until the mycobacterial culture from intraoperative pleural fluid will be ready.

Conclusions

Primary TB complicated by pleural empyema sometimes requires surgical treatment to achieve healing and VATS is a good and safe tecnique as open thoracothomy, less traumatic and less painful.

Bibliography

Odell JA.Pleural tuberculosis.International Trends in General Thoracic Surgery: Surgical Management of Pleural Diseases. St.Louis,Mosby-Year Book (Vol6)1990. Migliori GB,et all.European union standards for tuberculosis care.Eur Respir J. 2012 Apr;39(4):807-19.

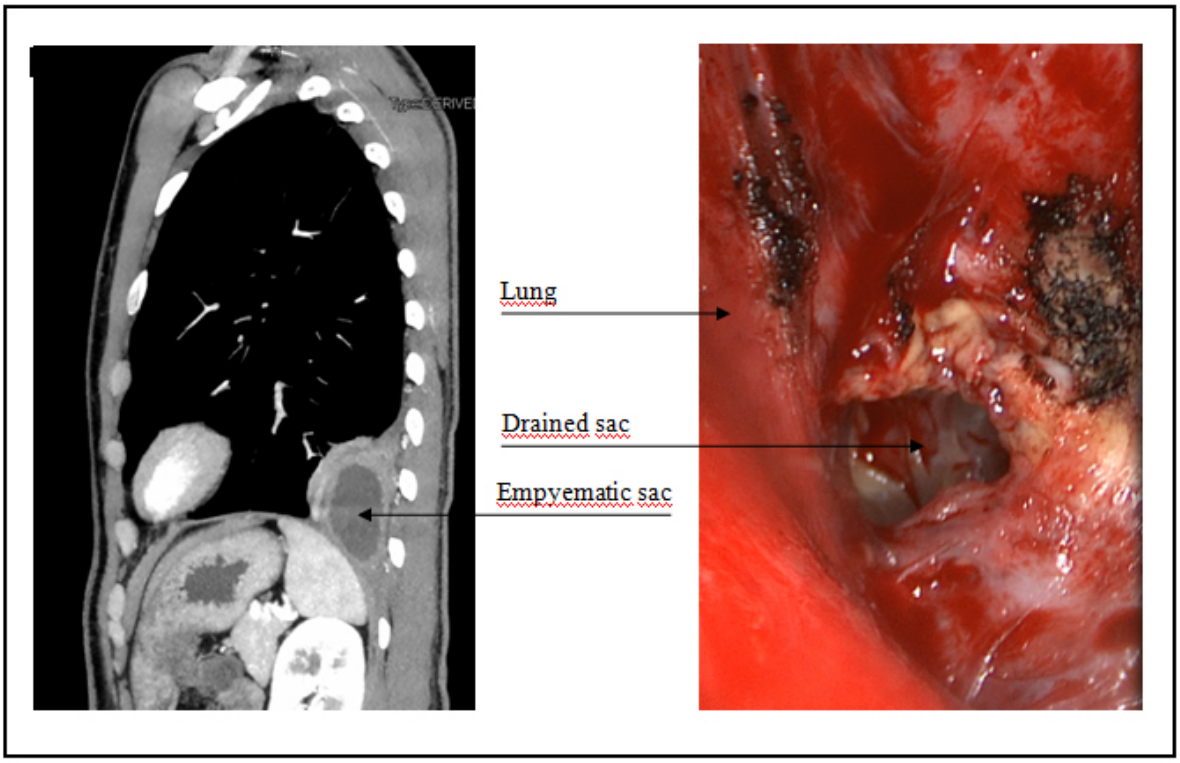

Figure 1: CT scan and videothoracoscopic view of the empyematic sac

id 125

Blind TBNA remains a viable option for diagnosis and staging of mediastinal lymphadenopathy

Scott Twaddell, David Arnold, Christopher Grainge

Department of Respiratory and Sleep Medicine, John Hunter Hospital - Australia

Introduction

Prior to the introduction of Endobronchial Ultrasound (EBUS), ‘conventional’ or blind TBNA (B-TBNA) was used to sample mediastinal and hilar lymph nodes (LNs) in diagnosis and staging. EBUS is now considered the new first line investigation for mediastinal staging in malignancy(1,2)

Objective

Periods of EBUS unavailability led the authors to consider B-TBNA as an alternative for diagnosis and staging of mediastinal lymphadenopathy. An audit of B-TBNA performance was commenced

Methods

Data was collected prospectively from January 2011 to December 2015. Yield of B-TBNA was monitored. Six needle passes were made per station using 21G or 22G TBNA needles. Rapid on-site examination (ROSE) was not available. All samples were transported in liquid based cytology medium. Samples with cancer cells, significant lymphocyte numbers or another specific diagnosis were considered positive.

Results

A total of 188 B-TBNA were performed. 170 tests returned results consistent with aspirates from lymph nodes, representing a lymph node yield of 90%. 18 specimens were reported as containing no or minimal lymphocytes and considered negative biopsies (10%). Of the samples considered negative or lymphocyte positive and cytology negative, patients were monitored for outcome over time. 3 of 18 negative LN biopsies were later found to be positive for malignancy at alternative investigation (EBUS or mediastinoscopy); 6 were considered true negative; 3 sarcoidosis and 6 inflammatory/ infective. 30 biopsies demonstrated lymphocytes but were negative on cytological examination. Of those, 2 were later found to be positive for malignancy by further investigation; the other 28 were either considered true negative nodes (18) or were diagnosed with benign conditions (sarcoidosis 5, inflammatory/ infective 5). Lymph node size correlated with successful biopsy. Median LN size for positive biopsy was 25mm. Median LN size for negative biopsy was 18mm. Of LNs over 20mm, positive rate for biopsy was 83% and percentage positive increased further as size increased, up to 98.5% when LNs were over 30mm (Figure 1).

Conclusions

B-TBNA remains a viable practical alternative to EBUS-TBNA. It is comparable in terms of positive biopsy in LNs over 20mm in size, when the pre-test probability of malignancy is high. In areas where centres providing EBUS services are significant distances apart, the procedure may save further travel and inconvenience for patients.

Bibliography

1. Vaidya PJ, et al. J Can Res Ther 2013;9:549-51 2. Navani N et al. J Thorac Oncol 2011; 6(9):1505-09

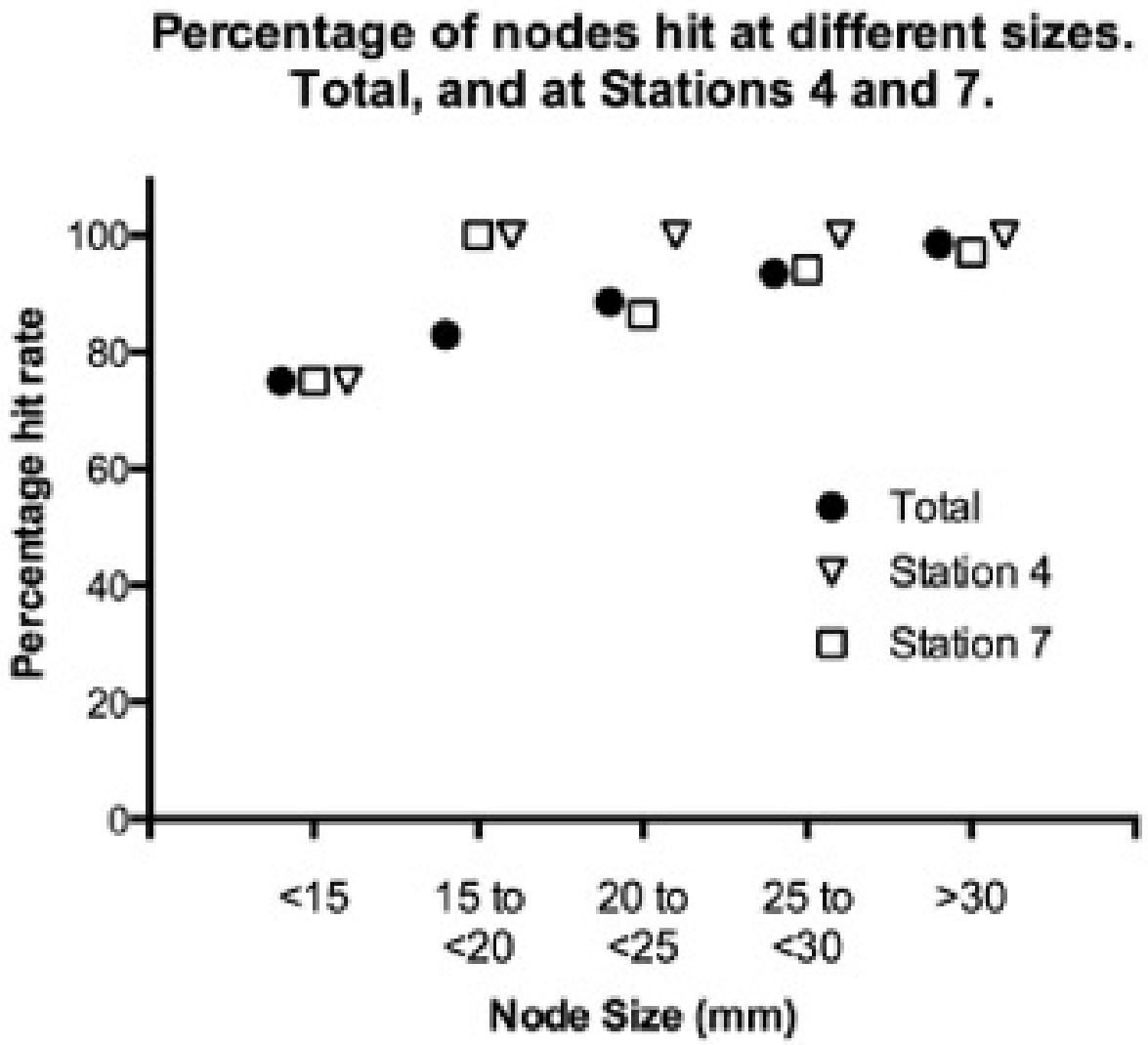
Percentage of nodes hit at different sizes.
Total, and at Stations 4 and 7.
Percentage hit rate
100
80
60
40
20
0
Total
Station 4
Station 7
<15
15 to <20
20 to <25
25 to <30
>30
Node Size (mm)

id 126

Interventional pulmonology for tracheal stenosis-where are the limits?

Simon Marioara, Vremaroiu Petrut

Bronchology, Pulmonology Clinic - Romania

Introduction

Interventional pulmonology (IP) provides comprehensive care to patients with structural airway disorders. Benign tracheal stenosis (BTS) is a potentially life-threatening condition. With the development of interventional pulmonology field in the last 20 years, definitive management of tracheal stenosis using minimally invasive endoscopic methods became a possibility

Objective

Benign airway stenoses are frequently seen by the interventional pulmonologist. Endoscopic treatment had been shown to be useful, especially in patients who are deemed high risk and too unwell for reconstructive surgery.

Methods

Many endoscopic therapeutic interventions can be offered: balloon dilatation, rigid bronchoscopy dilatation, laser or electrosurgery resection and placement of airway stents.We have retrospectively analyzed a series of 21 patients who were referred to our department between 2013-2015 for evaluation and management of symptomatic BTS.

Results

The most common condition was postintubation stenosis that develops after prolonged endotracheal intubation. Symptoms varied according to the severity of the stenosis, being the most frequent different degrees of dyspnea, cough and retained secretions. The endoscopic modalities used were: balloon and rigid bronchoscopy dilatation and radial incisions with electrosurgery knife. A stent was placed in two patients. Complications were minor and mostly included restenosis. Over a median follow-up of 36 months, the overall success rate was 85.7%, only three patients being referred to surgery.

Conclusions

Tracheobronchial stenoses can be difficult to treat, and patients benefit from a multidisciplinary approach; every case should be discussed within a team of dedicated physicians, including a pulmonary interventionist, an otorhinolaryngologist, and a surgeon, in order to offer the best available solution.

id 127

19th WCBIP / WCBE World Congress
JOINT MEETING OF THE WORLD ASSOCIATION FOR BRONCHOLOGY AND INTERVENTIONAL PULMONOLOGY & THE INTERNATIONAL BRONCHOESOPHAGOLOGICAL SOCIETY
www.wcbipwcbe2016.org
Fortezza da Basso
May 8-11, 2016
Florence (Italy)

A case report of a rare manifestation of porous diaphragm syndrome

Supparerk Disayabutr, Sivaporn Hemvimon, Jamsak Tscheikuna

Division of Respiratory Disease and Tuberculosis, Department of Medicine, Faculty of Medicine Siriraj Hospital, Mahidol University - Thailand

Introduction

Catamanial pneumothorax is one of the differential diagnosis in a reproductive age female who presented with spontaneous pneumothorax. The pathophysiologic theories of catamanial pneumothorax include a congenital diaphragmatic defect or a result of invasiveness of endometriotic tissue that entered the diaphragm due to retrograde menstruations. Porous diaphragm syndrome is a group of various conditions, e.g. catamanial pneumothorax, that cause by diaphragmatic defect. The holes in the diaphragm allow the passage of air or fluid from the abdomen into the pleural cavity. However, a large defect leading to herniation of visceral organ, such as liver or colon, into the pleural cavity is a rare manifestation. The present report describes a patient with porous diaphragm syndrome who presented with recurrent right pneumothorax with liver herniation.

Methods

A case of 45 year-old female presented with abnormal chest X-ray on her annual check-up. She had history of right spontaneous pneumothorax 2 years ago. She was treated with chest tube insertion without medical pleurodesis. She had no history of endometriosis or chest trauma. The association between the onset of pneumothorax and menstruation is unclear. Her recent chest X-ray showed right lower lung mass. Computed tomography (CT) of chest showed well-defined border, and lobulated enhancing mass at right lower lobe. Two months after performing the CT chest, she was referred to our hospital for further investigation of lung mass. She had no respiratory symptom but her chest X-ray showed right pneumothorax causing the separation of the lung from the mass, showing that the mass is extrapulmonary mass. Rigid pleuroscopy was performed under conscious sedation to explore the pleural cavity and placement of chest tube. It revealed 2 large diaphragmatic holes which their diameter were approximately 3 and 6 cm with liver protrusion through the larger defect. Furthermore, there were a few red spots at tendinous portion of the diaphragm. She underwent thoracotomy and diaphragmatic repair with pleurodesis. She had no recurrent pneumothorax during 6-month follow-up after surgery.

Conclusions

Pneumothorax is a frequent manifestation of porous diaphragm syndrome. The liver herniation is rare and mostly occurred in a large diaphragmatic defect. Surgery is the treatment of choice in this clinical situation.

id 128

Probe-based confocal laser endomicroscopy (pCLE) for early stage pulmonary alveolar proteinosis

Kazuyoshi Imaizumi, Takuya Okamura, Tomoyuki Minezawa, Sayako Morikawa, Yoshikazu Niwa, Yasuhiro Gotoh

Respiratory Medicine, Fujita Health University - Japan

Introduction

Pulmonary alveolar proteinosis (PAP) is a rare lung disease characterized by alveolar accumulation of abnormal phospholipid and protein material. In advanced case, it is easy to diagnose from characteristic findings of X-ray and bronchoalveolar lavage (BAL). In early stage of PAP, though several small patchy ground glass shadows may be seen on chest CT, it may be difficult to diagnose without pathological confirmation. Probe based confocal endomicroscopy (pCLE) is a newly developed optical probe for real time microscopic fluorescence image of distal airways. The usefulness of pCLE has been reported in lung cancer or inflammatory pulmonary diseases including advanced PAP. However, there have been few reports for pCLE in early stage PAP.

Objective

To analyze the pCLE images of early stage PAP and assess the usefulness of optical biopsy (acquisition of microscopic images by pCLE) in this disease

Methods

We performed pCLE (Cellvizio system®, Mauna Kea Technologies, Paris, France) on three consecutive patients with early stage PAP. We also performed radial endobronchial ultrasound with a guide sheath (EBUS-GS system, Olympus, Tokyo, Japan) simultaneously. After careful evaluation of thin slice chest CT images, a guide sheath was introduced to the affected segment with crazy pavement appearance. Through the guide sheath, we inserted the pCLE probe and EBUS probe followed by transbronchial biopsy (TBB).

Results

Three patients (two female and one male) were included in the study. All patients were asymptomatic and had a few small areas of ground glass opacities with crazy paving incidentally detected by chest CT. In all cases, characteristic pCLE image could be obtained. It showed some amorphous substances with macrophages with strong fluorescence (fig. 1). Comparative analyses of pCLE images with pathological findings of TBB revealed that the amorphous fluorescent substances are correspond to abnormal lipoproteinaceous materials in alveoli. Anti-GM-CSF autoantibody was detected in all cases.

Conclusions

pCLE images of PAP are characteristic and specific for the disease. Optical biopsy using pCLE could be enough for the diagnosis of early stage PAP even without TBB.



id 129

19th WCBIP / WCBE World Congress
JOINT MEETING OF THE WORLD ASSOCIATION FOR BRONCHOLOGY AND INTERVENTIONAL PULMONOLOGY & THE INTERNATIONAL BRONCHOESOPHAGOLOGICAL SOCIETY
www.wcbipwcbe2016.org
Fortezza da Basso
May 8-11, 2016
Florence (Italy)

Rapid on-site evaluation vs thoracoscopists impression of macroscopic findings during thoracoscopy

Ilias Porfyridis[1], Michalis Michael[2], Frangiskos Frangopoulos[1], Paris Vogazianos[1], Alexis Papadopoulos[1], Panayiota Kara[3], Charis Charalampous[3], Georgios Georgiadis[1], Andreas Georgiou[1]

[1]Pulmonary Department, Nicosia General Hospital - Cyprus
[2]Cytopathology Department, Nicosia General Hospital - Cyprus
[3]Histopathology Department, Nicosia General Hospital - Cyprus

Introduction

Introduction: Medical thoracoscopy(MT) is a useful method for the management of pleural disease. Certain thoracoscopic findings, such as pleural masses or nodules are suggestive of malignancy. However, many cases of severe inflammation and early-stage malignant diseases, like mesothelioma, are difficult to differentiate. Rapid on-site evaluation(ROSE) of transbronchial needle aspirates proved to be useful during bronchoscopy.

Objective

Objectives: To compare the diagnostic performance of ROSE of MT biopsy specimens and thoracoscopists impression of the macroscopic appearance for the diagnosis of malignancy.

Methods

Methods: 62 patients with exudative pleural effusions, without specific diagnosis after routine investigation, further investigated with MT, were enrolled in the study. MT was performed under local anaesthesia and conscious sedation, using the rigid pleuroscope(KARL STORZ®, Germany). ROSE with the Hemacolor rapid staining method of the biopsy specimens was performed. Thoracoscopists impression of the macroscopic appearance was recorded. The final diagnosis was established following histopathological examination.

Results

Results: Thoracoscopic pleural biopsies were diagnostic in 61 patients (98.4%). Group A (n=25) consisted of patients with malignancy and group B (n=37) with benign disorders. Area under the curve(AUC) of ROSE for the diagnosis of malignancy was 0.86 (95%CI: 0.76 – 0.96, p< 0.001). ROSE had a sensitivity of 79.17%, specificity of 94.59%, diagnostic accuracy of 88.5%, positive predictive value(PPV) of 90.5% and negative predictive value(NPV) of 87.5% for distinguishing between malignant and benign conditions. AUC of the thoracoscopists impression of macroscopic appearance was 0.72(95% CI: 0.58-0.85, p=0.001), with a sensitivity of 100%, specificity of 44.7%, PPV of 53.33% and NPV of 100%. ROSE could reduce by 69.4% the number of biopsies obtained. Intermodality agreement between ROSE and histopathology was good (? ± SE = 0.615 ± 0.084, p<0.001).

Conclusions

Conclusion: ROSE during MT was found to have high accuracy for predicting malignancy. ROSE proved to be more sensitive and accurate than thoracoscopist's impression of macroscopic appearance. Especially in patients with inconclusive macroscopic appearance, ROSE could provide an on-site preliminary diagnosis and could be beneficial.

Bibliography

1. Rodriguez-Panadero F, Janssen JP, Astoul P. Thoracoscopy: general overview and place in the diagnosis and management of pleural effusion. Eur Respir J 2006;28:409.421

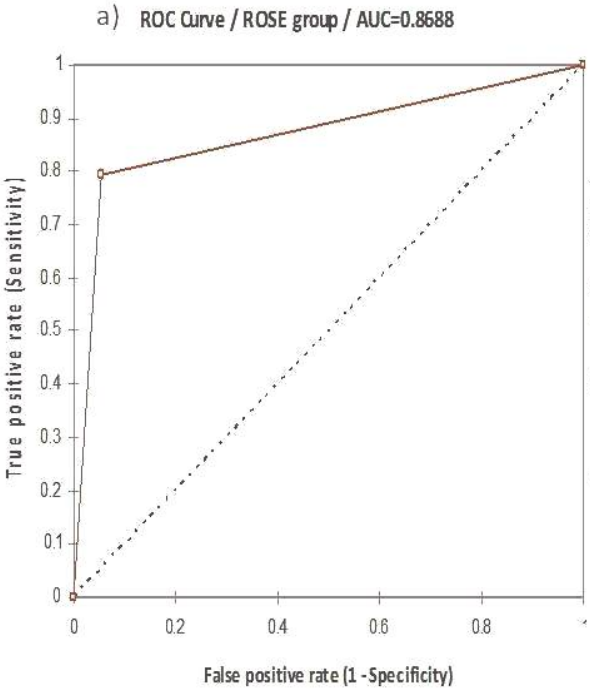
a) ROC Curve / ROSE group / AUC=0.8688
True positive rate (Sensitivity)
False positive rate (1 -Specificity)
0
0.1
0.2
0.3
0.4
0.5
0.6
0.7
0.8
0.9
1
0
0.2
0.4
0.6
0.8

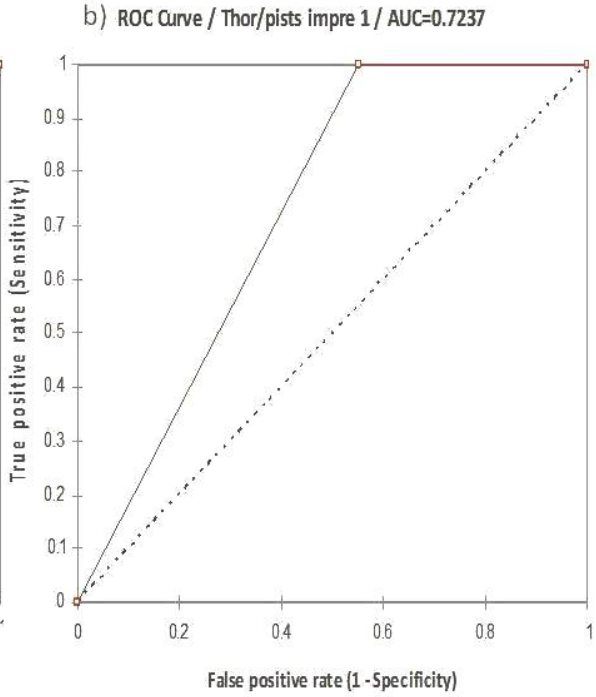
b) ROC Curve / Thor/pists impre 1 / AUC=0.7237
True positive rate (Sensitivity)
False positive rate (1 -Specificity)
0
0.1
0.2
0.3
0.4
0.5
0.6
0.7
0.8
0.9
1
0
0.2
0.4
0.6
0.8
1

id 130

19th WCBIP / WCBE World Congress
JOINT MEETING OF THE WORLD ASSOCIATION FOR BRONCHOLOGY AND INTERVENTIONAL PULMONOLOGY & THE INTERNATIONAL BRONCHOESOPHAGOLOGICAL SOCIETY
www.wcbipwcbe2016.org
Fortezza da Basso
May 8-11, 2016
Florence (Italy)

The left upper division sacrifice for tension reduce of the left main bronchoplasty

Satoshi Yamamoto, Sosei Abe, Shugo Uwatoko, Koji Mikami, Takafumi Maekawa

Department of Surgery, Fukuoka University Chikushi Hospital - Japan

Introduction

The adenoid cystic carcinoma is sometimes growth in the upper airway. Main treatment for the disease is included operative resection and radiotherapy. The operative resection often needs air way reconstruction. We performed bronchoplasty and additional left upper division lung segmentectomy for the anastomotic tension reduce for an adenoid cystic carcinoma patient of the left main bronchus.

Methods

63 year-old male with severe Diabetes mellitus (HgbA1c level=10.4) was admitted to our institute because of cough and sputum. Bronchoscopic examination showed a tumor of the left main bronchus, and pathologic examination of transbronchial biopsy revealed adenoid cystic carcinoma. We performed 6 rings of the left main bronchial cartilage resection and bronchoplasty, and additionally, the left upper division segmentectomy were performed for reduction of the bronchial anastomotic tension. The plasty site was covered with the left thymic lobe between the left main pulmonary artery. There was no severe complication after the operation. The pathological examination showed the no regional lymph node metastasis, however, the microscopic tumor positive of the both side bronchial stump. On the 48th day after the operation, he was applied of 60 Gy radioactive rays for the left main bronchus. He is well without any tumor recurrence on the 28 months after the operation,

Conclusions

We successfully performed the left main bronchoplasty for adenoid cystic carcinoma patient with severe Diabetes mellitus. The left upper division segmentectomy was useful for tension reduce of the bronchoplastic anastomosis.

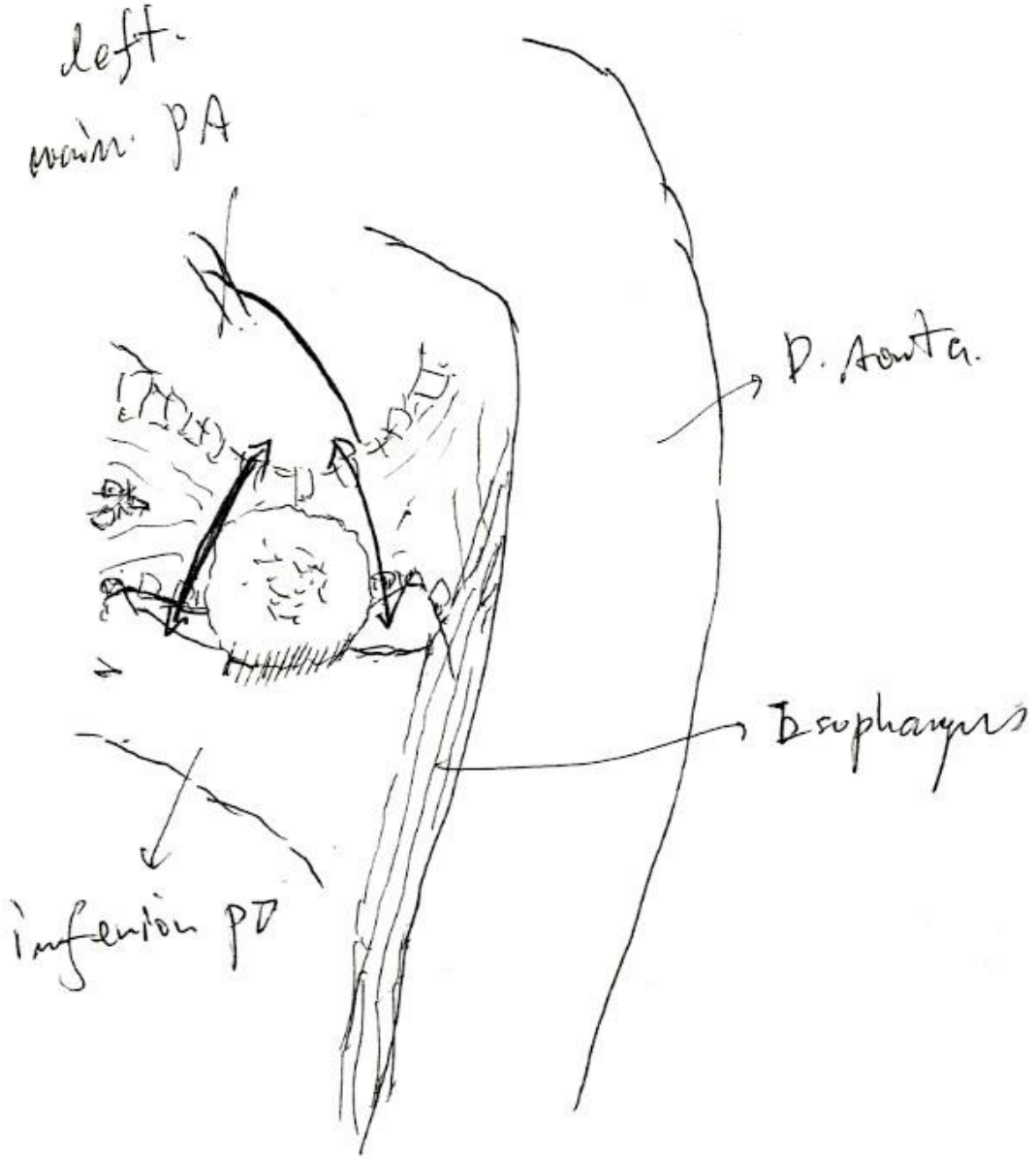
left.
main PA
D. Aorta.
Esophagus
inferior PV

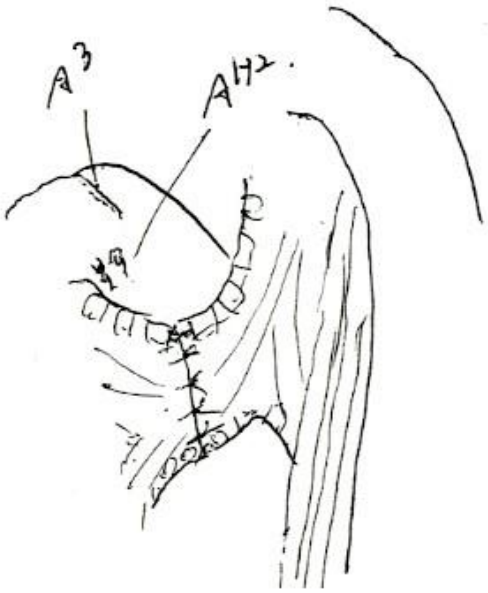
A3
A1+2.

Two cases of endobronchial papilloma successfully treated with bronchoscopic cryotherapy

Yoonki Hong[1], Jae Seung Lee[2], Jae Cheol Lee[3], Chang-min Choi[2]

[1]Internal Medicine, Kangwon National University Hospital, College of Medicine, Kangwon National University - Korea
[2]Pulmonary and Critical Care Medicine, University of Ulsan College of Medicine, Asan Medical Center - Korea
[3]Oncology, University of Ulsan College of Medicine, Asan Medical Center - Korea

Introduction

Endobronchial papilloma is a rare type of benign tracheobronchial tumors. As only small case series have been reported, it is little known about clinical presentation, morphologic features, and managements. Although surgical resection was regarded as the gold standard, other modalities of managements via endoscopy were also introduced as proper alternatives in various conditions. We present two cases of endobronchial papillomas with treated with bronchoscopic cryotherapy.

Methods

Case1. A 79-year-old woman presented with a 6-menth history of progressive dyspnea. Chest CT showed several lobulated nodular lesions in upper trachea, and follow-up bronchoscopic findings revealed two protruding masses at right and left walls of the upper-tracheal area that caused almost total obstruction of the trachea (Figure A.1). In intensive care unit, she was treated of the tracheal mass with brochoscopic cryotherapy, safely supported on venovenous extracoporeal membranous oxygenation and mechanical ventilation. There were no immediate complication of active bleeding and other bronchial injuries. The pathology showed mixed squamous cell and grandular papilloma. Post procedure follow-up bronchoscopy revealed nearly removed mass and patent central airway (Figure A.2). Case 2. A 77-year-old man presented with a 2-month history of cough, dyspnea. Chest CT and bronchoscopic fingding revealed mass totally obstructing right main bronchus (Figure B.1), and bronchoscopic biopsy revealed grandular papilloma on pathology. He was treated of the right main bronchus papilloma with two times of brochoscopic cryotherapy. There were no immediate complication of active bleeding and other bronchial injuries. After post procedure, bronchoscopy revealed nearly removed mass and patent airway of right main bronchus (Figure B.2). He was planned to receive one month follow- up bronchoscopy.

Conclusions

Although Endobronchial papilloma is rare tumor, it has various clinical presentations and its treatment may be selected according to the features of tumor or the conditions of patients. Bronchoscopic cryotherapy can be a proper modality among the treatments, and can be helped from mechanical ventilation and venovenous extracoporeal membranous oxygenation in cases of central airway obstruction.

Bibliography

1. Paganin F, et al. A solitary bronchial papilloma with unusual endoscopic presentation: case study and literature review. BMC Pulm Med. 2009 Aug 18;9:40.

A-1

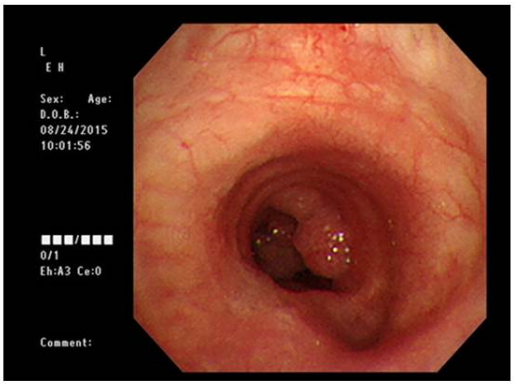

A-2

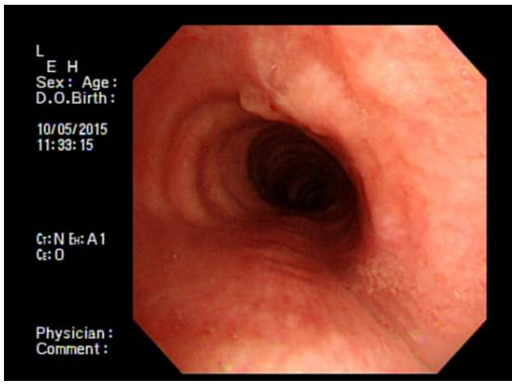

B-1

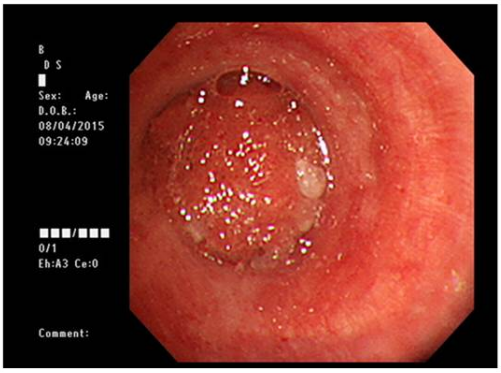

B-2

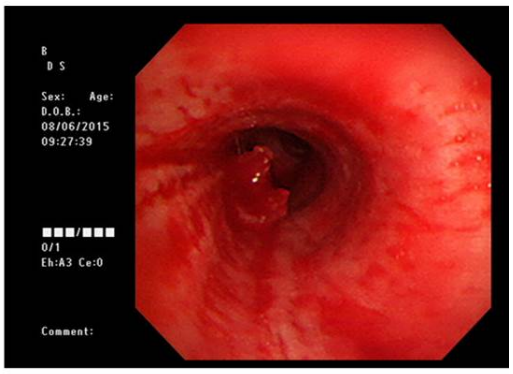

id 132

19th WCBIP / WCBE World Congress
JOINT MEETING OF THE WORLD ASSOCIATION FOR BRONCHOLOGY AND INTERVENTIONAL PULMONOLOGY & THE INTERNATIONAL BRONCHOESOPHAGOLOGICAL SOCIETY
www.wcbipwcbe2016.org
Fortezza da Basso
May 8-11, 2016
Florence (Italy)

Endobronchial ultrasound-guided fine needle aspiration: what are main difficulties for beginners?

Daniele Forcella[1], Daniela Assisi[2], Enrico Melis[1], Gabriele Alessandrini[1], Federico Pierconti[3], Francesco Facciolo[1]

[1]Surgical Oncology, Thoracic Surgery Unit, Regina Elena National Cancer Institute - Italy
[2]Gastroenterology and Digestive Endoscopy Unit, Regina Elena National Cancer Institute - Italy
[3]Anesthesiology and Intensive Care Unit, Regina Elena National Cancer Institute - Italy

Introduction

Endobronchial ultrasound-guided fine needle aspiration (EBUS-TBNA) is minimally invasive endoscopic method for diagnosis of mediastinal disease.

Objective

Aim was evaluation of diagnostic accuracy, sensitivity and negative predictive value during the learning curve of EBUS-TBNA in patients with lung cancer and/or enlarged mediastinal lymph nodes (MLN).

Methods

Twenty consecutive patients who had undergone EBUS-TBNA alone for assessment of suspected lung cancer with/without enlarged MLN or suspected lymphoma or enlarged MLN in extra-thoracic disease on the basis of abnormal CT scan and FDG PET were evaluated. Between September 2015 and October 2015 EBUS-TBNA was used as first procedure in 20 patients: in five patients directly on lung mass and in fifteen patients on hilar-mediastinal lymph nodes. Rapid on site evaluation (ROSE) was not available. Patients with non diagnostic or negative results underwent to surgical biopsy.

Results

Hilar nodes (station 10, 11) were aspirated in five patients and mediastinal nodes (station 4R, 4L, 2R, 7) in ten patients. In five patients EBUS-TBNA was performed directly on para-mediastinal lung mass. The mean number of needle passes was 3.1 (range 1-4, median 3.0). The accuracy, sensitivity and negative predictive value of EBUS-TBNA in hilar nodes was 100%, 100% and 100% respectively, in mediastinal nodes was 70%, 62.5% and 40% respectively, in lung masses was 100%, 100% (VPN not calculable) respectively. There were no complications in these procedures.

Conclusions

In this series of our first 20 EBUS-TBNA global accuracy was similar to literature's reports. Accuracy was lower only for station 4R probably due to a difficult access through tracheal wall that in two cases reduced number of needle passes. In our opinion other main difficulty for beginners to approach this procedure is acknowledgement of echographic mediastinal anatomy but this wasn't a problem for our team because an experienced echo-endoscopist works with us.

id 133

19th WCBIP / WCBE World Congress
JOINT MEETING OF THE WORLD ASSOCIATION FOR BRONCHOLOGY AND INTERVENTIONAL PULMONOLOGY & THE INTERNATIONAL BRONCHOESOPHAGOLOGICAL SOCIETY
www.wcbipwcbe2016.org
Fortezza da Basso
May 8-11, 2016
Florence (Italy)

Accessing to the aortopulmonary window lymph nodes by Endoscopic Ultrasound Fine Needle Aspiration

Daniela Assisi[1], Daniele Forcella[2], Massimo Filippetti[2], Enrico Melis[2], Federico Pierconti[3], Francesco Facciolo[2]

[1]Gastroenterology and Digestive Endoscopy Unit, Regina Elena National Cancer Institute - Italy
[2]Surgical Oncology, Thoracic Surgery Unit, Regina Elena National Cancer Institute - Italy
[3]Anesthesiology and Intensive Care Unit, Regina Elena National Cancer Institute - Italy

Introduction

Accurate lymph node staging is mandatory in case of enlarged mediastinal lymph nodes (MLN) in patients with suspected lung cancer or extra-thoracic neoplasia. Efficacy of less invasive technique for lymph node biopsies is well established. Many authors believe that surgery is the preferred approach to biopsy the station #5 lymph nodes because poor efficacy of Endoscopic Ultrasound Fine Needle Aspiration (EUS-FNA) in this mediastinal nodal station.

Objective

We evaluated accessing to the aortopulmonary window (#5 station) by transoesophageal endoscopic ultrasound (EUS) and diagnostic accuracy, sensitivity and negative predictive value of EUS-FNA in this station.

Methods

In our series of 211 EUS-FNA performed in 200 consecutive patients (127 men) with median age of 65 years from January 2011 to January 2015, we examined by EUS the lower mediastinal nodes (stations #8 and #9), the nodes of the aorto-pulmonary window (station #5), the left paratracheal nodes (stations #2L and #4L), the retrotracheal nodes (station #3P), the subcarinal nodes (station #7) and paraesophageal lung masses. In 154 of these patients (77%) we performed EUS-FNA only on enlarged MLN.

Results

EUS-FNA was performed on the following mediastinal sites according to the regional lymph-node map definitions: on station #7 in 123 cases, on station #4L in 15 cases , on station #5 in 16 cases. Complications (mediastinitis) occurred in two patients. The overall sensitivity of EUS-FNA in this series was 81.1% with a corresponding negative predictive value (NPV) of 52.1% and accuracy of 85 %. In lymph node station #7 the sensitivity of EUS-FNA to detect malignancy was 82.1%, VPN was 55% and accuracy 87.5%; in station #4L sensitivity was 70%, VPN was 57% and accuracy 78.5%; in station #5 sensitivity was 80%, VPN was 25% and accuracy 81.2%. In our series sensitivity of EUS FNA for station #5 was higher than reported in other studies.

Conclusions

These results confirm that routine use of EUS-FNA as an initial investigation after a staging CT scan or/and FDG PET-CT for enlarged MLN is a good and safe less invasive approach to mediastinal stations. Furthermore we think that also #5 station nodes must be assessed by trained operators with EUS- FNA. Low NPV in this station suggests that in case of negative or not diagnostic samples surgery (mediastinoscopy or left video-assisted thoracic surgery) is mandatory.

id 134

19th WCBIP / WCBE World Congress
JOINT MEETING OF THE WORLD ASSOCIATION FOR BRONCHOLOGY AND INTERVENTIONAL PULMONOLOGY & THE INTERNATIONAL BRONCHOESOPHAGOLOGICAL SOCIETY
www.wcbipwcbe2016.org
Fortezza da Basso
May 8-11, 2016
Florence (Italy)

Comparison of two techniques of implantation self-expanded metallic Y shape stents

Ying-hua Pei, Jie Zhang

Pulmonology, Tiantan Hospital - China

Introduction

Airway stenting results in significant palliation of symptoms, and improvement of survival for advanced thoracic cancer with central airway obstruction.Y-stent is useful in the management of malignant disease involving the main carina. As metallic Y stents can be implanted under topical anesthesia with flexible bronchoscope or under general anesthesia with rigid bronchoscope. However, there is no study to compare these two techniques to confirm which is better.

Objective

To compare two techniques of implantation self-expanded metallic Y shape airway stents(Y-SEMTs) , under topical anesthesia with flexible bronchoscope and under general anesthesia with rigid bronchoscope.

Methods

Retrospectively analyzed total 24 airway stenosis cases under Y-SEMTs treatment from 2008~2014, to compare these two techniques by time of procedure and successes rate.

Results

According to methods of anesthesia, the 24 cases were separated to group of topical anesthesia (14/24) and group of general anesthesia (10/24). The successes rate in topical group was 85.7%?12/14?vs. 100%?10/10?in general group, there was no statistical significance (P?0.05). The angle of stent, the length of trachea and bronchi segments, and the diameter of stents between two groups had no statistical significance. The time of procedure in topical group was obviously longer than general group (49.57±26.6min vs. 31.10±10.06min, P?0.05).

Conclusions

The technique of implantation self-expanded metallic Y shape stents to treat airway stenosis involving carina under general anesthesia with rigid bronchoscope is more convenient and effective than under topical anesthesia with flexible bronchoscope.

id 135

19th WCBIP / WCBE World Congress
JOINT MEETING OF THE WORLD ASSOCIATION FOR BRONCHOLOGY AND INTERVENTIONAL PULMONOLOGY & THE INTERNATIONAL BRONCHOESOPHAGOLOGICAL SOCIETY
www.wcbipwcbe2016.org
Fortezza da Basso
May 8-11, 2016
Florence (Italy)

Bronchoscopically closing a recurrent tracheoesophageal fistula with a metallic stent in a child

Man Gao[1], Lina Wang[1], Deli Li[1], Li Zhang[1], Hang Liang[1], Lijun Song[1], Xiaosong Wang[2], Mengyao Li[3], Fanzheng Meng[1]

[1]Pediatrics, The First Hospital of Jilin University - China
[2]Institute of Translational Medicine, The First Hospital of Jilin University - China
[3]Clinical Medicine, The Bethune Medical School of Jilin University - China

Introduction

Recurrent tracheoesophageal fistula (rTEF) have been reported in up to 20% of patients after surgical repair. Although considered as a gold standard, open surgical repair of rTEF is associated with significant morbidity, mortality and rates of recurrence. This has led investigators to explore less invasive techniques to repair rTEF. In children, the endoscopic attempts, as an attractive alternative, have been reported including esophageal stenting, tissue glue and clips. So far, there is no report of using a tracheal stent to close the rTEF.

Methods

In this report, we described a 29-month-old patient with congenital tracheoesophageal fistula who developed rTEF after two times attempts of open surgery repair, however, the third surgery was not available because of the bad health condition at that moment. We bronchoscopically placed a coated self-expanding metallic stent into trachea to close the fistula under the consent of the family. The stent was placed into the right bronchus and released, then pulled up slowly and carefully until just above the carina to ensure to cover the fistula completely. The stent was took out three months later and, in the end, two thirds of orifice was occluded by the granulation while the left one thirds kept open. At that time, the patient was in a good health condition and it was a good time to perform the third surgery repair.

Conclusions

This is the first report of placing a coated self-expanding metallic stent into trachea to close an intractable rTEF in a child. Bronchoscopically placing a stent into trachea could be an alternative in treating rTEF in children.

id 136

19th WCBIP / WCBE World Congress
JOINT MEETING OF THE WORLD ASSOCIATION FOR BRONCHOLOGY AND INTERVENTIONAL PULMONOLOGY & THE INTERNATIONAL BRONCHOESOPHAGOLOGICAL SOCIETY
www.wcbipwcbe2016.org
Fortezza da Basso
May 8-11, 2016
Florence (Italy)

Endobronchial tuberculosis

Elena Tudor[1], Petru Levcenco[1], Victor Cozlovschi[1], Anatolie Vornicescu[2], Iurie Simionica[1], Vadim Simionica[1]

[1]Endoscopy, Institute of Phthisiopneumology ”Chiril Draganiuc” - Republic Of Moldova
[2]Endoscopy, Dispensary of Phthisiopneumology - Republic Of Moldova

Introduction

Given the fact that bronchoscopy is not routinely performed in all patients with pulmonary tuberculosis, the real incidence of pulmonary tuberculosis cannot be assessed. Therefore, the proportion of endobronchial involvement in active pulmonary tuberculosis is variable. According to literature data, in 5.8% of cases of pulmonary tuberculosis it was also diagnosed the endobronchial tuberculosis. In another study it was reported as 10-40% (2) other studies noted by 50% (1). Endobronchial tuberculosis can mime diseases such as asthma, pneumonia and lung cancer (2).

Objective

Evaluation of the frequency of endobronchial tuberculosis in pulmonary tuberculosis and nonspecific respiratory diseases.

Methods

The material was collected in the Institute of Phthisiopneumology ”Chiril Draganiuc” from Chi?in?u and the Phthisiopneumology Dispensary from B?l?i.

Results

During 2009-2014 in the Institute of Phthisiopneumology ”Chiril Draganiuc” from Chi?in?u and the Phthisiopneumology Dispensary from B?l?i, there were performed 14531 fibrobronhoscopies of which 12602 diagnosed to 12602 patients, including 38.2% (4912) women and 61.1% (7690) men. With pulmonary tuberculosis it was in 4678 (37.2%) and 7924 (62.8%) with nonspecific diseases of the respiratory system. Endobronchial tuberculosis was diagnosed in 8.0% (375) cases among all pulmonary tuberculosis cases and 3.9% (310) cases in patients with nonspecific pathology of respiratory system. It predominated the scar form of endobronchial tuberculosis 86.2% (267) cases of nonspecific pulmonary pathology. In the infiltrative form of endobronchial tuberculosis there were determined 33.8% (127) cases in pulmonary tuberculosis.

Conclusions

1. Endobronchial tuberculosis was diagnosed in 8.0% cases in pulmonary tuberculosis and 3,9% cases in nonspecific pulmonary pathology. 2. Infiltrative form - 33.8% predominates in pulmonary tuberculosis and the scar – 86.2% in nonspecific pulmonary pathology. 3. Multidisciplinary approach to the patient, including endoscopic examination help to establish early diagnosis, timely initiation of treatment and prevention of the sequelae postuberculosis development.

Bibliography

1. Aneja A, Krishnaswamy UM, et all. Pulmonol 2014; 283972. 2. Ulmeanu R., et all. Endoscopia toracic?. Diagnostic? ?i tratament. 2009 pp. 146-156.

id 137

19th WCBIP / WCBE World Congress
JOINT MEETING OF THE WORLD ASSOCIATION FOR BRONCHOLOGY AND INTERVENTIONAL PULMONOLOGY & THE INTERNATIONAL BRONCHOESOPHAGOLOGICAL SOCIETY
www.wcbipwcbe2016.org
Fortezza da Basso
May 8-11, 2016
Florence (Italy)

Stenosis of bronchus intermedius: an unusual complication after transplantation and its treatment

Rosaria Carrinola, Lorenzo Rosso, Ilaria Righi, Paolo Mendogni, Francesco Damarco, Mario Nosotti

Department of Thoracic Surgery and Lung Transplantation, Fondazione IRCCS Cà Granda Ospedale Maggiore Policlinico - Italy

Introduction

Complications related to ischemia are the most important cause of morbidity and mortality after lung transplantation. Ischemia suffered by large bronchi during transport and transplantation of the graft is considered the possible pathogenic noxa for late stenosis as well as a possible cause of anastomotic leak or ulceration of the mucosa. It seems to emerge from the literature that the bronchus intermedius may be particularly prone to ischemia and may undergo stenosis late after transplantation.

Methods

Two patients, underwent bilateral lung transplantation for cystic fibrosis in 2014, developed in the first six months after transplantation stenosis of the bronchus intermedius. At the endoscopic and instrumental controls for follow-up there was a ischemic bronchial mucosa with stenosis of the lumen of the bronchus intermedius with normal patency of the anastomosis. One of the two patients was submitted to two sessions of pneumatic dilations with discrete outcome. At time of the next endoscopic control for transbronchial lung biopsy, following the decline in lung function, was observed a recurrence of stenosis. It was therefore decided to place a bronchial resorbable uncoated stent (ELLA-CS, Kralove, Czech R.). The other patient was treated directly with pneumatic dilatation and stent placement with the same characteristics in the same session. There was an immediate recovery of the respiratory function (increase to 20%) in both patients that was maintained at five months after placement. There was no evidence of infections or bronchial obstructions by secretions. There was no need further pneumatic dilations. Four and a half months after positioning, the stent was completely absorbed and bronchial lumen diameter preserved.

Conclusions

Stenosis of the bronchus intermedius is a late complication after transplantation that is beginning to be recognized in the literature as an autonomous entity. It 'likely that the revascularization of this long bronchial segment can be delayed or deficient in certain peculiar anatomical situations. The prompt recognition of this possible complication and its aggressive treatment can be the basis of optimal recovery of respiratory function.

id 138

Role of autofluorescence bronchoscopy in evaluation of bronchial mucosa after lung transplantation

Rosaria Carrinola, Lorenzo Rosso, Alessandro Palleschi, Davide Tosi, Matteo Montoli, Mario Nosotti

Department of Thoracic Surgery and Lung Transplantation, Fondazione IRCCS Cà Granda Ospedale Maggiore Policlinico - Italy

Introduction

Respiratory complications are a significant and persistent source of morbidity and mortality after lung transplantation; the incidence of these complications is around 15% with a mortality rate of 2- 3% correlated. Airway complications arise, typically, the first two years post-transplant, and of these almost half are identified prior to discharge; their pathogenesis, as well as to opportunistic infections, appear to be related to the difficult revascularization of the bronchi resulting in chronic ischemia

Objective

Aim of this study is to connect the degree of vascularity of the bronchial mucosa graft with the onset of complications of airway with the use of autofluorescence bronchoscopy. This method is currently used in oncology: the different blood supply of healthy mucosa from the pathological can identify precancerous lesions due to the different capacity of absorption of ultraviolet light. The increase in thickness of the mucosa precancerous, such as ischemia, prevent the absorption of frequencies of the red light by hemoglobin, and therefore the mucosa presents a bright red color as opposed to the "normal" color green

Methods

Transplant patients in the year 2014 were subjected to routine transbronchial lung biopsies: all procedures were performed with autofluorescence bronchoscopy (Olympus EVIS Lucera Spectrum AFI) and recorded on computer, weekly during the first month and next quarterly up to the first year of follow-up. The degree of fluorescence was measured using an histogram. The magenta color identifies the ischemic mucosa and the green color that normal vascularized; the results, in terms of intensity ratio (R / V ratio), obtained were correlated with ischemia time of the graft and with the onset of complications of airways

Results

We enrolled 31 patients. In the face of an appearance substantially "normal" of the mucosa in white light, in the immediate postoperative period was recorded the highest percentage of ischemic mucosa (R / V = 1.66; normal value = 0.87), with a return to normal vasculature (green) which amounted on average to 30 days post transplant. It 'was noted a relationship trend between high time of cold ischemia of the graft and high R / V. A patient at six months post transplantation still had ischemic mucosa has developed a stenosis of the bronchus intermedius, treated with resorbable endobronchial stent placement

Conclusions

Autofluorescence bronchoscopy allows to evaluate the vascularity of the bronchial mucosa graft and provides a valuable tool in the prevention and control of the onset of endobronchial complications

id 139

19th WCBIP / WCBE World Congress
JOINT MEETING OF THE WORLD ASSOCIATION FOR BRONCHOLOGY AND INTERVENTIONAL PULMONOLOGY & THE INTERNATIONAL BRONCHOESOPHAGOLOGICAL SOCIETY
www.wcbipwcbe2016.org
Fortezza da Basso
May 8-11, 2016
Florence (Italy)

Interventional Bronchoscopy In The Management Of Airway Complications After Lung Transplantation

Crutu Adrian[1], Baldeyrou Pierre[1], Le Pavec Jerome[1], Fadel Elie[2]

[1]Thoracic and Vascular Surgery, Marie Lannelongue Hospital - France
[2]Thoracic and Vascular Surgery, Marie Lannelongue Hospital/ Université Paris Sud - France

Introduction

Airway complications following lung transplantation remain a significant cause of morbidity and mortality. The management of bronchial complications may require interventional bronchoscopy.

Objective

The purpose of this study was to retrospectively analyse the use of interventional bronchoscopy for the management of airway complications following lung transplant in our hospital.

Methods

Between January 2010 and December 2014, 159 lung and heart and lung transplantations were performed at Marie Lannelongue Hospital, Le Plessis-Robinson, France. All the patients who had an interventional bronchoscopy were included in this retrospective analysis.

Results

Most of the patients had single and bilateral lung transplantation (84.27%). Out of 134 lung transplant recipients, 35 patients (26.11%) were included in this analysis (13 male and 22 female; mean age 44.62 years, range 17-63). The main indications for lung transplantation were: idiopathic pulmonary arterial hypertension (22.85%), emphysema (20%), idiopathic pulmonary fibrosis (20%) and pulmonary veno- occlusive disease (11.42%). A total of 139 procedures were performed. The mean interval between lung transplantation and interventional bronchoscopy was 71.4 days (range 8-136). 13 patients (37.14%) required 21 stents (15 silicone stents and 6 covered metal stents). The most common complications after stent placement were mucus impaction (76.19%) and migration (33.33%). Other interventional therapeutic procedures included balloon bronchoplasty and mechanical debridement with dilatation only. There were no complications in any patient during interventional bronchoscopy.

Conclusions

Airway complications after lung transplant remain a significant problem. Interventional bronchoscopy is essential in the management of airway complications in patients after lung transplantation, as the majority of patients are not suitable for repeated surgery. Stent placement can be used to manage airway stenosis after lung transplantation.

Bibliography

Colt H, et al. Chest 1992; 102:10-16 Kappor B, et al. Journal of Vascular and Interventional Radiology 2007; 18:629-632

Pleuroscopy with a semirigid thoracoscope

Julia Tarrega, Yolanda Galea, Enric Barbeta

Unitat de Pneumologia, Hospital General de Granollers Universitat Internacional de Catalunya - Spain

Introduction

Pleuroscopy, also known as medical thoracoscopy or thoracoscopy under local anaesthesia is an useful technique in the diagnosis and treatment of pleural effusions. The development of a semirigid thoracoscope, similar in design to the flexible bronchoscope, could help to implement this technique in the Departments of Pneumology and improve the performance in the diagnosis and management of pleural disease.

Objective

To describe the diagnostic yeld, complications and pleurodesis succes of 160 consecutively pleuroscopies performed with a semirigid thoracoscopy technique during a 5-years period in a 300-bed general hospital.

Methods

Pleuroscopies were performed with the OLYMPUS LTF-160 thoracoscope under local anaesthesia and conscious sedation in an endoscopy suit.

Results

During the past 5 years, 120 patients (mean age 66 years, range 21-90 years) were undergone pleuroscopy. In 77 cases initial indication was diagnostic (PD group) and in 43 therapeutic (pleurodesis) in patients with a previous diagnosis of malignancy. In the PD group, 43 patients were diagnosed of malignancy (23 carcinomatous pleurisy, 16 mesotheliomas, 2 lymphomas, 1 sarcoma and 1 melanoma), 6 of tuberculosis pleurisy and 2 empyema. In all, endoscopic examination suggested the diagnosis that was finally confirmed by biopsy obtained during the procedure. In 5 patients with malignant disease, pleural metastases were discarded. The other 21 were diagnosed of nonspecific pleuritis, 4 of them were finally diagnosed of malignancy (2 mesothelioma and 2 carcinomas). The Specificity of the macroscopic exam and biopsy taken during the procedure was 100% and sensitivity 91%. Finally a total of 74 pleurodesis with talc (Steritalc Novatech®) were performed. It was effective in 64 cases (86,5%); Median survival of the 45 deceased patients was 167 days. As complications of the technique we describe 3 subcutaneous emphysema, 2 infection stitch, 1 persistent air leak and 1 empyema

Conclusions

1 - The pleuroscopy with a semi-rigid thoracoscope is a safe, minimally invasive technique, with high performance diagnostic and therapeutic indications. 2 - The realization of this technique under local anaesthesia and conscious sedation in endoscopy rooms simplifies and improves the diagnostic process of pleural diseases. 3 - The availability of this semi-rigid thoracoscope should facilitate the implementation of this technique in the respiratory endoscopy units and increase the efficiency of pulmonologists in the management of pleural pathology.

Bibliography

m.munavvar et al. Eur Respir J, 2007;29:571-574

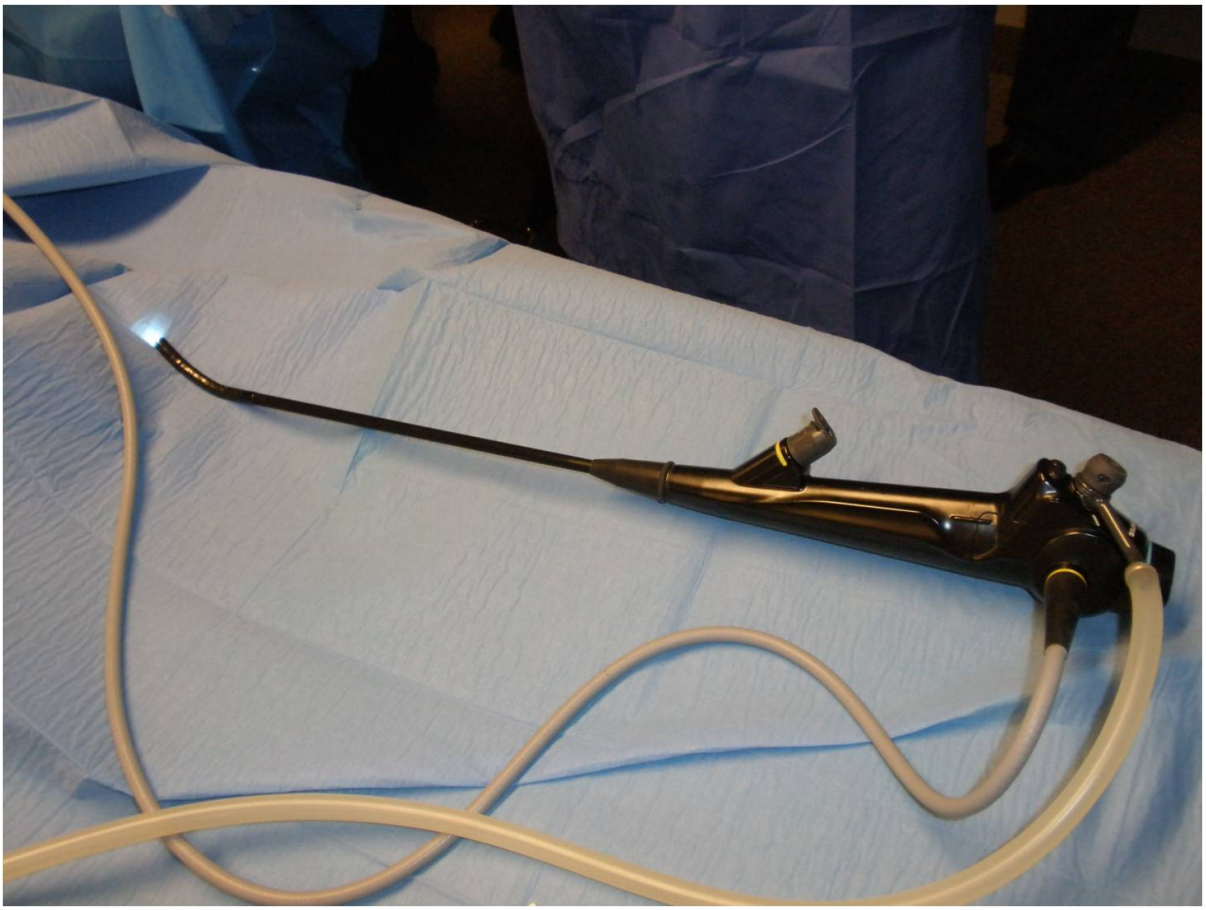

id 141

19th WCBIP / WCBE World Congress
JOINT MEETING OF THE WORLD ASSOCIATION FOR BRONCHOLOGY AND INTERVENTIONAL PULMONOLOGY & THE INTERNATIONAL BRONCHOESOPHAGOLOGICAL SOCIETY
www.wcbipwcbe2016.org
Fortezza da Basso
May 8-11, 2016
Florence (Italy)

Transoesophageal ultrasound-guided FNA of parenchymal lung lesions using an EBUS bronchoscope

Daniel Steinfort[1], Michael Farmer[2], Louis Irving[1], Barton Jennings[2]

[1]Respiratory Medicine, Royal Melbourne Hospital - Australia
[2]Respiratory Medicine, Monash Medical Centre - Australia

Introduction

Transoesophageal introduction of the endobronchial ultrasound videobronchoscope allows pulmonologists to perform endoscopic fine-needle aspiration (EUS-B-FNA) of mediastinal lesions. Diagnostic utility & feasibility in evaluation of parenchymal lesions is less well established.

Objective

To demonstrate feasibility/safety of EUS-B-FNA of parenchymal lung lesions To determine diagnostic accuracy of EUS-B-FNA of parenchymal lung lesions

Methods

All patients undergoing pulmonologist-performed EUS-B-FNA of parenchymal lung lesions at two tertiary centres in Melbourne, Australia, were included in this prospective observational cohort study.

Results

EUS-B-FNA was performed in 12 patients with parenchymal lung lesions (figure 1). No complications occurred. Two lesions were considered in accessible to any form of bronchoscopic diagnosis. Eight were positioned within the apicoposterior segment of upper lobes. EUS-B-FNA was diagnostic in 11 of 12 (92%), and sensitivity for detection of lung cancer was 100% (11 of 11).

Conclusions

Pulmonologist-performed EUS-B-FNA is safe and accurate in the evaluation of parenchymal lung lesions. It can increase the diagnostic yield of bronchoscopic investigation through diagnosis at sites not amenable to other forms of bronchosopic sampling, or in patients where anatomic position predicts a low diagnostic yield.

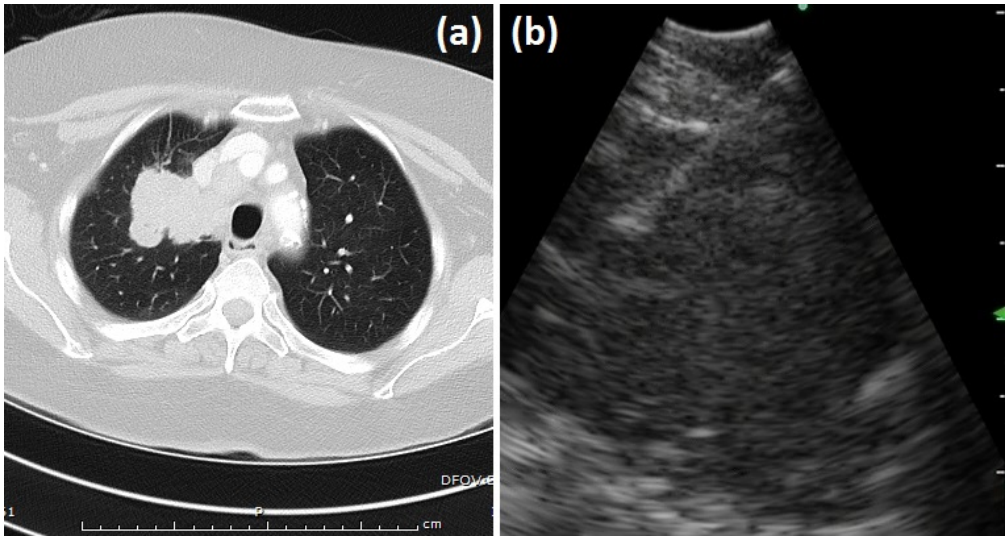

Impact of confocal endomicroscopy on the yield of transbronchial biopsies obtained via navigation

Ashley Ferraro, Adam Wellikoff, Robert Walter, Robert Holladay

Interventional Pulmonary Program, Louisiana State University Health - Shreveport - Usa

Introduction

Diagnostic bronchoscopy has advanced dramatically in recent years while more peripheral pulmonary lesions (PPL) are being found. Traditionally, transbronchial biopsies (TBBx) have been done “blind” in that the location of the probe relative to the lesion in question was unknown. Various “guiding” techniques, including electromagnetic navigational bronchoscopy (ENB) are routinely employed and have improved the diagnostic yield. The yield of traditional TBBx ranged from 14-63%, which improved to 59-88% (59% for ENB) depending on the type of guidance used.1 Other, adjunct technologies have been developed to impact the yield further. Probe-based confocal laser endomicroscopy (pCLE) is among these. The technology behind pCLE has been previously reported and recent work points to a positive correlation between pCLE images and pathology.2

Objective

The purpose of this paper is to quantify the impact pCLE has on diagnostic yield of TBBx when used with ENB.

Methods

Data from TBBx’s done to evaluate PPL’s was retrospectively analyzed over a three-year period. The groups were divided by year in order to analyze yields from ENB alone, year one of ENB+pCLE and year two to try to assess the learning curve. ENB was done using SuperDimension (Medtronic; Minnesota, USA) and pCLE with Cellvizio (Mauna Kea Technologies; Paris, France). This report represents preliminary data. Diagnostic yield was based on pathology, cytology, and culture specimens taking into consideration pre-test probabilities. If the TBBx did not make a final diagnosis, serial imaging or ancillary testing including transthoracic needle aspiration or surgical biopsy was done. If a final diagnosis was not made after further testing, the procedure was labeled as non-diagnostic and did not count towards the final yield.

Results

A diagnosis was made via TBBx in the ENB alone group in 29/56 cases (52%) whereas 50/70 cases (71%) done with ENB+pCLE had a positive TBBx with a p-value of 0.0116. An analysis of year one versus year two for the ENB+pCLE groups will be reported in the future.

Conclusions

TBBx is a common procedure today and its use is expected to grow with lung cancer screening. Guided TBBx is becoming standard of care as this provides increased yields while preserving patient safety. Adjunct technologies add to the proceduralist’s armamentarium in order to avoid invasive procedures done for benign disease. Emerging technologies must be properly vetted in order to assure these goals are met. Although further analysis is forthcoming, preliminary data suggests that ENB+pCLE has a role in this space.

Bibliography

Wang-Memoli JS, et-al. Meta-analysis of guided-bronchoscopy for the evaluation of the pulmonary nodule.Chest2012;142:385. Wellikoff AS, et-al. Comparison of in vivo probe-based-confocal-laser-endomicroscopy with histopathology in lung cancer-A move toward optical biopsy.Respirology2015;20(6):967-74.



id 143

19th WCBIP / WCBE World Congress
JOINT MEETING OF THE WORLD ASSOCIATION FOR BRONCHOLOGY AND INTERVENTIONAL PULMONOLOGY & THE INTERNATIONAL BRONCHOESOPHAGOLOGICAL SOCIETY
www.wcbipwcbe2016.org
Fortezza da Basso
May 8-11, 2016
Florence (Italy)

Optical Coherence Tomography for Staging Chronic Obstructive Pulmonary Disease

Ming Ding, Yu Chen, Chang-hao Zhong, Wei-jie Guan, Wei-zhan Luo, Shi-yue Li, Nan-shan Zhong

Interventional pulmonary department, State Key Laboratory of Respiratory Disease, National Clinical Research Center for Respiratory Disease, Guangzhou Institute of Respiratory Disease, First Affiliated Hospital of Guangzhou Medical University, Guangzhou, Guangdong, China - China

Introduction

Small airway disease might be the sole manifestation of early-stage COPD. The association between the overall well-beings and the magnitude of distal airway disorder has been difficult to establish by using conventional tools such as spirometry or radiology.

Objective

Using endobronchial optical coherence tomography(EB-OCT) to evaluate the morphological changes of those heavy smokers, and detect the association between the airway remodeling and the various COPD stages.

Methods

We recruited 149 subjects between January 2015 and October 2015, consisted of 80 COPD patients of varying stages (stage ?,n=13; stage ?, n=34; stage ?-?, n=34), 39 heavy smokers(>20 pack year), and 29 subjects without smoking history (control group). For all subjects, assessments included inquiry of smoking history, spirometry, chest CT, bronchoscopy and EB-OCT. Measure the parameters of Dmean (mean luminal diameter), Ai (inner luminal area), Aw (airway wall area) and Aw% [Aw/(Ai+Aw)×100%] from the 3rd to 9th generation bronchi by EB-OCT, and evaluate the association between the results of EB-OCT with the FEV1 and MMEF.

Results

From generation 7th to 9th , the mean diameter was larger in smokers(2.16±0.29mm) than in COPD patients in stage ?(1.75±0.28mm, P<0.001) , stage ? COPD(1.55±0.15mm, P<0.001) and stage ?-? COPD(1.35±0.15mm, P<0.001), and Aw% was significant lower in smokers(26.98±7.88%) than in stage ? COPD(39.27±12.98%, P<0.001), stage ? COPD(39.82±3.97%, P<0.001) and stage ?-? COPD(46.46±3.52%, P<0.001). While there were larger mean diameter in normal subjects than smokers (3.57±0.14mm vs. 3.33±0.2mm, P<0.001), the airway wall percentage of Smokers was greater than healthy subjects (26.98±7.88% vs. 11.56±2.63%, P<0.001). The mean diameter from gen 7th to 9th correlated significantly with FEV1% predicted in stage? and ?- ?COPD patients (r=0.48, P=0.004 and r=0.581, P<0.001 respectively). There were significant negative correlations between Aw% (gen 7th to 9th)and FEV1% predicted in stage ? and stage ?-? COPD (r=0.403, P=0.018 and r=0.744, P<0.001, respectively).

Conclusions

Heavy smokers had different morphological changes in small airways from normal subjects, and it was similar to the COPD patients but in less severity. The characteristics of airway remodeling was more obvious to the peripheral lung. It is the time to re-introduce GOLD 0 COPD stage.

Bibliography

Chen Y, Ding M, Guan WJ, et al. Validation of human small airway measurements using endobronchial optical coherence tomography. Respir Med 2015


normal subject
10
20
30
40
mm
0
mm
<< 54.0 mm, 20.0 mm/sec
smoker
10
20
30
40
mm
0
mm
<< 54.0 mm, 20.0 mm/sec
COPD patient
10
20
30
40
mm
0
mm
<< 54.0 mm, 20.0 mm/sec

id 144

19th WCBIP / WCBE World Congress
JOINT MEETING OF THE WORLD ASSOCIATION FOR BRONCHOLOGY AND INTERVENTIONAL PULMONOLOGY & THE INTERNATIONAL BRONCHOESOPHAGOLOGICAL SOCIETY
www.wcbipwcbe2016.org
Fortezza da Basso
May 8-11, 2016
Florence (Italy)

A multimodal endoscopic intervention for the treatment of laryngeal and tracheal papillomatosis

Mihir Parikh[1], Eric Seeley[1], Ganesh Krishna[2]

[1]Pulmonary, Critical Care, Allergy, and Sleep Medicine, University of California San Francisco - Usa
[2]Interventional Pulmonology, El Camino Hospital - Usa

Introduction

Squamous cell papillomas are non-invasive tumors that can be found in the larynx, trachea, and other central airways. Squamous papillomas are due to infection with human papillomaviruses (HPV). HPV subtypes 6 and 11 are most closely linked to benign tumors of the respiratory epithelium while other subtypes are associated with a higher risk for malignant transformation.1 Excision of airway papillomas is done to prevent malignant transformation and preserve airway patency. A variety of endoscopic techniques, including cryosurgery, laser vaporization, electrocautery, and forceps biopsies, have been described for the treatment of squamous papillomas.2 Here, we report the case of a 46-year-old gentleman in whom we successfully treated numerous laryngeal and tracheal papillomas with endoscopic cryosurgery, argon plasma coagulation therapy, and local injection of cidofovir.

Methods

The patient initially presented with productive cough and hoarseness. His past medical history was notable for Crohn's Disease and his medications included sulfasalazine and occasional oral prednisone. On physical examination, he appeared in good health. There were no palpable lymph nodes in his head or neck. His lung sounds were clear and there was no stridor. A CT scan of the chest performed without intravenous contrast revealed a lobulated soft tissue attenuation lesion on the posterolateral surface of the lower trachea measuring 14 x 14mm (Figure 1A). There was no hilar or mediastinal adenopathy. On endoscopic inspection of the airways, the patient had multiple verrucous lesions on the trachea and one lesion on the anterior commissure of the vocal cords. Forceps biopsies demonstrated squamous papillomatosis without stromal invasion. The lesions were positive for low risk HPV subtypes. Using rigid bronchoscopy, we extracted multiple papillomas with flexible cryoprobe using liquid nitrogen as a cryogen with a freeze-thaw cycle. More sessile papillomas were ablated using argon plasma coagulation with settings of 30 Watts, 1L flow, and 16 pulses per second. We injected the vocal cord papilloma with cidofovir (5 mg/mL) and then extracted this papilloma with flexible cryoprobe and conventional forceps. On follow-up bronchoscopy one year later, the trachea appeared normal and there was no evidence of recurrence of his papillomatosis. The vocal cords appeared normal and showed symmetric motion. His cough and hoarseness had resolved.

Conclusions

Tracheal papillomatosis is a rare, benign tumor of the respiratory epithelium. Currently, there is limited guidance on appropriate management. Here, we present the case of a 43-year-old man in whom we successfully treated laryngeal and tracheal papillomas with a multimodal endoscopic intervention.

Bibliography

1. D'Souza G, et al. NEJM. 2007. 356:1944. 2. Macchiarini P. Lancet Oncol. 2006; 7:83-91.

id 146

19th WCBIP / WCBE World Congress
JOINT MEETING OF THE WORLD ASSOCIATION FOR BRONCHOLOGY AND INTERVENTIONAL PULMONOLOGY & THE INTERNATIONAL BRONCHOESOPHAGOLOGICAL SOCIETY
www.wcbipwcbe2016.org
Fortezza da Basso
May 8-11, 2016
Florence (Italy)

Diagnostic utility of medical thoracoscopy

Rakesh K. Chawla[1], Arun Madan[2], Aditya Chawla[3]

[1]Respiratory Medicine, Critical Care & Sleep Medicine, Jaipur Golden Hospital, Rohini, - India
[2]Pulmonary Medicine & Critical Care, SMS & R, Sharda University, - India
[3]Pulmonary Medicine, Shri Ram Murti Smarak Institute of Medical Sciences, - India

Introduction

Medical thoracoscopy initially started from Sweden in early 20th century, gained popularity in 50's and 60's but declined due to effective anti- tuberculosis chemotherapy. It has again become tool of choice for undiagnosed pleural effusions.

Objective

This is a retrospective study of 349 patients who underwent Medical Thoracoscopy for undiagnosed pleural effusions.

Methods

The procedure was performed in a Bronchoscopy suite / Minor OT under conscious sedation using inj. Fortwin 30 mg and Phenargan 50 mg slow IV. All the parameters were monitored continuously including SpO2, HR, BP and ECG & patients breathed spontaneously. Patients were put in lateral decubitus position with affected side kept upwards. Local anaesthesia was injected at the site of thoracoscope insertion and a Thoracic Surgeon was always present as a stand-by colleague, ready to proceed for open thoracotomy, if required. All the pleural fluid was removed and multiple pleural biopsies taken using an electro-coagulation forceps from the parietal pleura under direct vision.

Results

Out of 349 patients with pleural effusion who were examined, pleural fluid evaluation helped in diagnosis in 198 cases (malignancy in 102 cases, TB in 66 and pyogenic empyema in 31). In 49 cases, we did closed pleural biopsy with Abram's punch, 18 came out to be malignant, 12 tubercular and rest 19 were non-specific chronic inflammation. From 2007 we are performing medical thoracoscopies. Out of 102 cases, we did talc pleurodesis in 28, malignancy was found in 48 & 19 were tubercular. In rest of 7 patients, we could not get proper free area for the thoracoscope to manoeuver, mainly because of thick pleurodesis and fear of puncturing underlying cavities. There was nil mortality related to the procedure.

Conclusions

Medical thoracoscopic biopsy is a cost effective and safe procedure, it is done under direct vision using local anaesthesia avoiding major surgical intervention, has excellent outcome in the form of diagnostic yield, is therapeutic as pleurodesis is performed under vision and nil complications. The detailed results along with original videos will be presented.

19th WCBIP / WCBE World Congress
JOINT MEETING OF THE WORLD ASSOCIATION FOR BRONCHOLOGY AND INTERVENTIONAL PULMONOLOGY & THE INTERNATIONAL BRONCHOESOPHAGOLOGICAL SOCIETY
www.wcbipwcbe2016.org
Fortezza da Basso
May 8-11, 2016
Florence (Italy)

Endobronchial ultrasound-guided transbronchial needle aspiration as a diagnostic tool of lymphoma

Sojung Park[1], Eun Kyung Bae[1], Jae Cheol Lee[2], Hyeong Ryul Kim[3], Chang-min Choi[1]

[1]Department of Pulmonary and Critical Care Medicine, University of Ulsan, College of Medicine, Asan Medical Center - South Korea
[2]Department of Oncology, University of Ulsan, College of Medicine, Asan Medical Center - South Korea
[3]Department of Thoracic and Cardiovascular Surgery, University of Ulsan, College of Medicine, Asan Medical Center - South Korea

Introduction

The value of endobronchial ultrasound-guided transbronchial needle aspiration (EBUS-TBNA) has been established for mediastinal lymph node staging of lung cancer. However, the utility of EBUS-TBNA for evaluation of lymphadenopathy suspicious for lymphoma has been controversial.

Objective

We investigated whether EBUS-TBNA could diagnose and subtype lymphoma

Methods

The medical records of patients who underwent EBUS-TBNA between July 2008 and September 2015 were retrospectively reviewed. We included the cases of patients who had undergone EBUS-TBNA for evaluation of mediastinal or hilar lymphadenopathy and were finally diagnosed with lymphoma through any diagnostic tools. The results of EBUS-TBNA were categorized as lymphoma and nondiagnostic, such as reactive or atypical lymphoid cells. Subsequently, lymphoma was subclassified into lymphoma-subtyped and lymphoma-not subtyped, by whether subtype of lymphoma could be determined by EBUS-TBNA only.

Results

A total of 297 patients with extrathoracic malignancy underwent EBUS-TBNA between July 2008 and September 2015. EBUS-TBNA was performed in 28 lymphoma patients and a total of 46 lymph nodes were achieved. The mean size of lymph node was 18.9 mm and there were no significantly specific ultrasonographic characteristics in lymphoma. Of the 28 patients, EBUS-TBNA was diagnostic in 23 patients (sensitivity 82.1%), including 15 patients (53.6%) with lymphoma- subtyped. Hodgkin lymphoma was the most common subtype (10/28, 35.7%), followed by diffuse large B cell lymphoma (DLBCL) (9/28, 32.1%). Seven patients with lymphoma-subtyped underwent further biopsy and the results of additional biopsy were consistent with those of EBUS-TBNA. Seven out of ten Hodgkin lymphoma patients showed histopathologic characteristics that suggest Hodgkin lymphoma in specimens obtained via EBUS-TBNA, although all patients underwent additional biopsy, including 1 under general anesthesia. All DLBCL patients had tissue that was compatible with lymphoma and 7 (7/9, 77.8%) could be subclassified into DLBCL by EBUS-TBNA only. The mean number of needle pass per lymph node was significantly higher in lymphoma specimens than nondiagnostic specimens (2.9 ± 0.9 versus 2.1 ± 0.6, p-value 0.022).

Conclusions

EBUS-TBNA is a minimally invasive, effective procedure that can provide diagnosis and subclassification of lymphoma. To enhance the accuracy of the diagnosis, sufficient number of needle passes to obtain sufficient sample is definitely required.

Hypoxia induced EMT and stemness properties mediated by DNA demethylation with identified NGS in lun

Chan Kwon Park[1], Su Yeon Choi[2], Nahyeon Kang[2], Young Kyoon Kim[2], Seung Joon Kim[2]

[1]Department of Internal Medicine, Youido St. Mary's Hospital, The Cancer Research Institute, College of Medicine, The Catholic University of Korea - Korea
[2]Department of Internal Medicine, Seoul St. Mary's Hospital, The Cancer Research Institute, College of Medicine, The Catholic University of Korea - Korea

Introduction

Tumors exhibiting extensive hypoxia have been shown to be more aggressive than corresponding tumors that are better oxygenized, which suggests that hypoxic condition induces stem-like properties. The purpose of the present study was to investigate whether hypoxic stress induces acquisition of stem-like properties, and which is involved with DNA demethylation in lung cancer.

Objective

To identify that hypoxia induce EMT in lung cancer and investigate whether hypoxic stress induces acquisition of stem-like properties, and which is involved with DNA demethylation in lung cancer

Methods

Normal epithelial cell line (BEAS-2B) and human lung cancer cell lines (A549, H292, H226 and H460) were incubated in either normoxic or hypoxic (below 1% O2) condition. The cell lines were treated with Western blot for E-cadherin, N-cadherin, ?-SMA, Fibronectin and Vimentin and a DNA methyltransferase inhibitor (5-azacytidine, AZA) to determine whether the expression of stem cell markers (CD44, CD133, CXCR4, ABCG2, CD117, ALDH1A1, EpCAM, CD90, Oct4, Nanog, SOX2, SSEA4 and CD166) was reactivated. Methylation-specific PCR and bisulfite sequencing were used to analyze the methylation status, and real-time RT-PCR and western blotting were performed to analyze the expression of the stem cell markers. scatter plot and volume plot of NGS sequencing were performed for confirmation of result.

Results

The EMT was identified and among the 13 stem cell markers, CXCR4, Oct4 and Nanog were increased at least one lung cancer cell line in hypoxic condition compared with in normoxic condition. These three stem cell markers were reactivated by treatment with AZA. Methylation-specific PCR showed decreased promoter methylation of these three stem cell markers in hypoxic condition compared with in normoxic condition, which was further validated by bisulfite sequencing and scatter plot and volume plot of NGS sequencing. Migration and invasion were increase in hypoxic condition compared with in normoxic condition.

Conclusions

These results suggest that under the hypoxic condition, reactivation of stem-like properties was related with promoter demethylation of stem cell markers.

id 149

19th WCBIP / WCBE World Congress
JOINT MEETING OF THE WORLD ASSOCIATION FOR BRONCHOLOGY AND INTERVENTIONAL PULMONOLOGY & THE INTERNATIONAL BRONCHOESOPHAGOLOGICAL SOCIETY
www.wcbipwcbe2016.org
Fortezza da Basso
May 8-11, 2016
Florence (Italy)

Expressions of Sarcoplasmic reticulum calcium ATPase in rat intrinsic laryngeal muscles

Hideki Bando

Department of Otolaryngology Head and Neck Surgery, Kyoto prefectural university of medicine - Japan

Introduction

The intrinsic laryngeal muscles serve a variety of vital motor functions such as phonation respiration and airway protection. The adductor muscles, thyroarytenoid muscle (TA), lateral cricoarytenoid muscle (LCA) have a higher percentage of type2 MHC and a lower percentage of type1. On the other hands, posterior cricoarytenoid muscle (PCA) and Cricothyroid muscle (CT) have a highr percentage of type? MHC compared to the adductor muscles. Sarcoplasmic reticulum Ca2+-ATPase (SERCA) transports calcium ions from the cytoplasm into the Sarcoplastic reticulum (SR) at the expense of ATP hydrolysis during muscle relaxation. Three major subtypes are known in the vertebrates, SERCA1, SERCA2 and SERCA3. They produce more than 10 isoforms through alternative splicing. In skeletal muscle, two SERCA isoforms predominate, namely SERCA1 and SERCA2a, which are differentially expressed in specific muscle fiber types. SERCA1 is expressed in type2 (fast) skeletal muscle. SERCA2 is expressed in type1 (slow) skeletal and cardiac and smooth muscle.

Objective

To investigate the functional diversity of intrinsic laryngeal muscles, we conducted immunohistochemical analysis of SERCA expressions in the rat intrinsic laryngeal muscles.

Methods

Adult male wistar-rats were fixed with 4% paraformaldehyde following cardiac perfusion under anesthesia with sodium pentobarbital. The larynx were collected and embedded with paraffin for immunohistochemistry. Primary antibody for SERCA1 and 2a were applied and visualized with fluorophore-conjugated secondary antibodies. Double immunohistochemical analysis with MHC was also performed in order to illuminate the expression corresponding to each muscle subtypes.

Results

SERCA1 was predominantly expressed in adductor muscles (TA and LCA), while less percentage (about 70%) of muscle fibers expressed SERCA1. In TA and LCA, SERCA2a expression was lower than the expressions in PCA and CT. In PCA and CT, about 30% muscle fibers expressed SERCA2a. Numbers of hybrid fiber which expressed both SERCA1 and SERCA2a were observed in PCA muscle. Double immunohistochemical stainings with MHC showed co-expression of SERCA2a and type2 MHC in PCA. On the other hand, the ratio of the hybrid fiber was lower in CT.

Conclusions

Because the SERCA plays a major role in muscle contraction and relaxation, a number of investigations have focused on understanding its role in cardiac and skeletal muscles. In our study, intrinsic laryngeal muscles showed specific expression of SERCAs. These results indicate that chracteristic SERCA expressions may serve the diversity of laryngeal motor functions.

The bronchoscopic management of subglottic stenosis with holmium laser and cryotherapy in children

Anxia Jiao, Fang Liu, Xiaochun Rao, Yuyan Ma, Chenfang Meng, Yuena Pan, Xicheng Liu

Interventional Pulmonology, Beijing Children's Hospital affiliated to Capital Medical University - China

Introduction

Subglottic stenosis is characterized with scar contracture and granulation tissue hyperplasia. It could result for wheezing, difficulty in breathing, and even life threatening. In pediatric, the most common type of subglottic stenosis, about 90%, is caused by tracheal intubation. Moreover, subglottic area is the most narrow part of the airway in children, difficulte for operation. So it is crucially important to choose a safe and effective treatment method.

Objective

Bronchoscopic interventional management has been suggested as an alternative treatment to open surgical treatment of subglottic stenosis. Through this retrospective study, we intend to explore the value and curative effect of the holmium laser and cryotherapy for post-intubation subglottic stenosis in children.

Methods

Forteen patients with post-intubation subglottic stenosis treated with holmium laser and cryotherapy by flexible bronchoscopy were included, between 2014 and 2015. It has seven males and seven females, with an age range of 2 month to 12 years. According to the Cotton-Myer, the grade of subglottic stenosis in 14 patients are classfied into grade ? in 5 patients, grade ? in 7 patients, and grade ? in 2 patients. In the course of treatment, the average number of interventional operation that patients accepted is 7.64 times, the median number is 4.5 times.

Results

All patients have initial success, including increased airway dimensions, symptom relief and no complications noted. After long-term follow-up, one patient was lost to follow-up, one patient is still in treatment. 12 patients accepted regular follow-up, and have no restenosis during 3-6 months follow- up, revealed satisfactory effect. The long-term cure rate was 100%. After this treatment, 4 cases above 3 years have finished Activity of Daily Living Scale(ADL) again, the ability of daily living can reach to the level of the same age children.

Conclusions

Holmium laser and cryotherapy by bronchoscopy is a safe and efficient method in the management of grade? to ? subglottic stenosis in children. It has offered immediate symptomatic relief and no restenosis in follow-up 3-6 months.

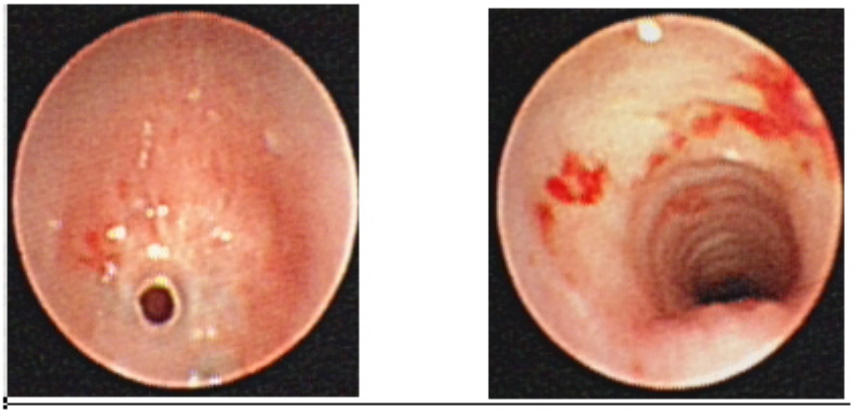

(a) (b)

Figure 1. (a) post-intubation subglottic stenosis; (b)subglottic stenosis after treatment with holmium laser and cryotherapy

id 151

19th WCBIP / WCBE World Congress
JOINT MEETING OF THE WORLD ASSOCIATION FOR BRONCHOLOGY AND INTERVENTIONAL PULMONOLOGY & THE INTERNATIONAL BRONCHOESOPHAGOLOGICAL SOCIETY
www.wcbipwcbe2016.org
Fortezza da Basso
May 8-11, 2016
Florence (Italy)

Clinical impact of rebiopsy for advanced NSCLC ~ our 14 cases experiences~

Hiroyasu Kaneda[1], Souichi Fumita[1], Kunio Okamoto[1], Ryota Shintani[2], Hirofumi Kiyokawa[2], Motokazu Kato[2]

[1]Medical Oncology, Kishiwada City Hospital - Japan
[2]Respirilogy, Kishiwada City Hospital - Japan

Introduction

Rebiopsy was performedto compare to the initial status, to detect emergence of resistancebiomarkers and to assess new biomarkers (1-2). In clinical setting, little is unknown about feasibility and utility of rebiopsy for NSCLC.

Objective

The purpose of this study was to assess the feasibility and clinical utility of rebiopsy.

Methods

We retrospectively assessed 14 lung cancer patients who had undergone rebiopsy after any chemotherapies between April 2014 and February 2015 in Kishiwadamunicipal hospital. Data were collected by a retrospective scan and a chart review for each patient.

Results

Twelve patients were male, median age was 67 years (range: 49-77), Two patients were never-smokers. All pts had ECOG PS 0/1 before rebiopsy and demonstrated adenocarcinoma histology in baseline. Regarding to mutation status by initial biopsy, six patients were detected EGFR mutation, whereas other patients could not analyze mutation status because of small sample. Seven cases (50?) were useful for guiding treatment, except for a patient with EGFR T790M mutation who diedduetocarcinomatousmeningitis. The success rate was 92.8% (13/14 cases). This result was not inferior to other reports (94%) (2). The failure case suggests that rebiopsymight be difficult if the tumor is not large and at peripheral lesion. ?In the near future, our results indicated that rebiopsycould be feasible and acceptable on clinical setting, when third generation EGFR-TKI after acquired resistance to initial EGFR-TKI would be approved.

Conclusions

Rebiopsyof lung cancer with acquired resistance is feasible and could provide sufficient material for mutation analysis in most patients. If initialbiopsyfailedtoyield a molecular profile, second biopsy should be done.

Bibliography

1)A. Hata, N. Katakami, H. Yoshioka, et. al. Rebiopsyof non-small cell lung cancer patients with acquired resistance to epidermal growth factor receptor- tyrosine kinase inhibitor. Cancer 2013 ; 119(24) : 4325-32.

A "Scout" Sample is a Weak Predictor of BAL Fluid Return: Results From a Prospective Study

María Del Valle Somiedo, Luis Seijo, Alba Naya, Iker Fernández-navamuel, Josefina Manjón, Susana Álvarez, Javier Flandes

Pulmonary Department, Fundación Jimenez Díaz University Hospital - CIBERES - Spain

Introduction

ATS guidelines suggest that an optimal BAL should recover > 30% of instilled fluid. We routinely perform a ¨scout¨ aspirate prior to BAL with 10 cc of saline in order to estimate BAL fluid recovery in the chosen bronchus. We report results from a prospective trial comparing two modalities of BAL aspiration in which a ¨scout¨ aspirate was systematically performed prior to BAL.

Objective

To evaluate the correlation between scout and BAL returns and to determine whether a ¨scout¨ aspirate performed prior to BAL predicts BAL yields.

Methods

220 consecutive patients undergoing BAL at our center were included in this randomized prospective study (Ethics committee approval EO 37/2014_FJD). A scout mini lavage with a 10 cc hand-held syringe was performed in 218 cases. BAL was performed with 150 cc of saline in 3 aliquots of 50 cc.

Results

There is a weak correlation between scout and BAL aspirates, as shown in figure 1. The scout's ability to predict optimal BAL volumes was assessed by ROC analysis: Scout aspirate volumes were weak predictors of BAL volumes meeting spanish thoracic society guidelines (Fluid recovered > 60% of instilled volume; area under the ROC curve: 0.7) and ATS guidelines (Fluid recovered > 30% of instilled volume; area under the ROC curve: 0.56). The quantity of BAL fluid recovered was also related to aspiration method ($p<0.001$), BAL location ($p<0.001$) and radiologic findings ($p=0.002$).

Conclusions

The 10 cc scout aspirate is a weak predictor of BAL fluid return in this prospective randomized study.

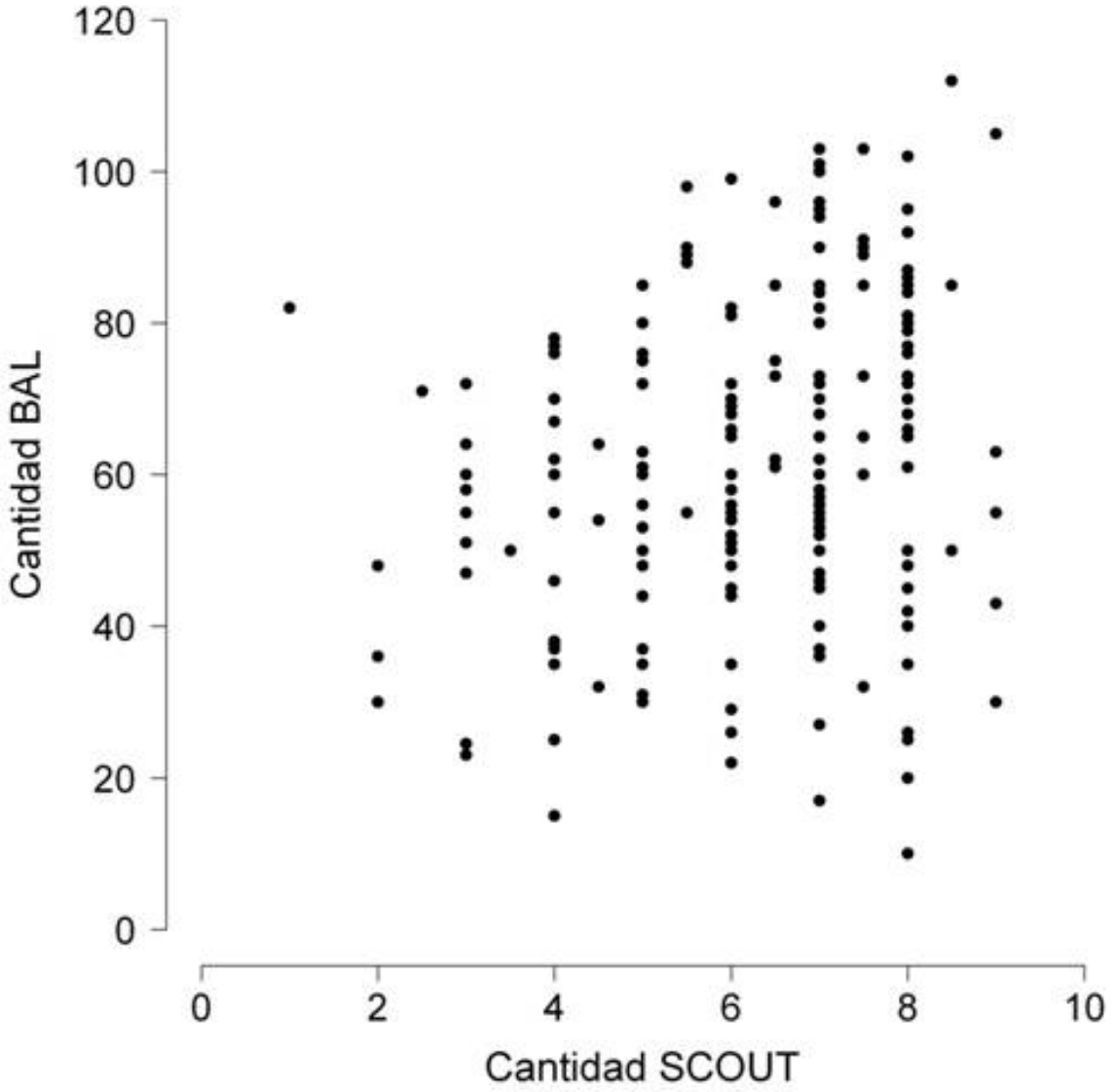

id 153

Cryorecanalization - modality for tumour debulking in management of central airway obstruction

Sonja Badovinac, Mihovil Roglic, Marta Korsic, Denis Baricevic, Marko Jakopovic, Miroslav Samarzija

Department for lung diseases "Jordanovac", University Hospital Center Zagreb - Croatia

Introduction

Malignant central airway obstruction (CAO) occurs in patients with primary or metastatic lung malignancies with significant impact on respiratory function and quality of life. In such cases, interventional bronchoscopy is used for tumor debulking and recanalization of central airways. Variety of endoscopic techniques are currently used in treatment of CAO, and usually include mechanical debulking, laser or electrocautery. Cryotechnique as a new modality for different bronchoscopic interventions such are cryotherapy or cryobiopsy emerged during the past decade. Recently, cryotechnique in interventional bronchoscopy was introduced as an option for tumor extraction as well (1).

Objective

To investigate value and possible complications of usage of cryoprobe in the tumor debulking in CAO management.

Methods

Retrospective analysis of all procedures, in which cryoprobe was used as method in interventional bronchoscopy during period of 9 months during 2015 was analyzed. Etiology of underlying malignant disease, usage of additional bronchoscopic techniques, outcomes and rate of complications were analyzed from the medical data.

Results

In total, in 23 procedures on 19 patients cryoprobe was used for recanalization. For 2 patients (11%) repeated procedures were required. Primary lung cancer comprised 74% of all malignant obstruction cases, and squamous cell lung cancer was the most frequent histological type (64%). 91% of patients had tumor in trachea or mainstem bronchus and 9% of patients had lobar or segmental obstruction. Interventions were performed trough rigid bronchoscope, endotracheal tube or flexible bronchoscope in 85%, 11% and 4% respectively. Cryoprobe was used as single recanalization modality in 27% of all procedures performed, while in 73% of interventions it was combined with other interventional modalities mostly with Nd-YAG laser or balloon dilatation. Complete recanalization was accomplished in 77% of all procedures. The most common complication of the procedure was minor bleeding that was managed by local application of cold 0.9 % NaCl solution or epinephrine solution, a single case of moderate bleeding was registered.

Conclusions

Cryorecanalization is valuable technique in interventional bronchoscopy for debulking tumor masses in central airways. It can be combined with other bronchoscopic modalities, thus offering an additional tool for optimal results in the management of malignant CAO.

Bibliography

1. Schumann C et al. J Thorac Cardiovasc Surg. 2010 Apr;139(4):997-1000.

id 154

19th WCBIP / WCBE World Congress
JOINT MEETING OF THE WORLD ASSOCIATION FOR BRONCHOLOGY AND INTERVENTIONAL PULMONOLOGY & THE INTERNATIONAL BRONCHOESOPHAGOLOGICAL SOCIETY
www.wcbipwcbe2016.org
Fortezza da Basso
May 8-11, 2016
Florence (Italy)

Medical thoracoscopy in undiagnosed exudative pleural effusion-a study from tertiary centre, India.

Mahendra Kumar Bainara, Manoj Arya, Dinesh Kumar Sharma, Hemant Kumar

Respiratory medicine and tuberculosis, RNT Medical College - India

Introduction

Medical thoracoscopy or pleuroscopy is increasingly being performed by respiratory physicians since recent past for diagnostic as well as therapeutic uses.About 25 percent pleural remain undiagnosed even after repeated thoracocentesis and blind closed pleural biopsy therefore , we planned semirigid thoracoacopy in undiagnosed exudative pleural effusion .

Objective

To find out the diagnostic yield of thoracoscopic pleural biopsy and To assess the accuracy & safety of thoracoscopy for evaluation of undiagnosed exudative pleural effusion.

Methods

Setting & Design: Institutional based prospective analysis. Material & Method: prospective analysis of data of 79 patients who underwent thoracoscopy for confirmative diagnosis of undiagnosed exudative pleural effusion “between” April 2011 to April 2015. Safety and complications of procedure were also analyzed

Results

Results: The overall diagnostic yield of thoracoscopic pleural biopsy was 81% (64/79) in patients of undiagnosed exudative pleural effusions. Pleural malignancy was diagnosed in 54.43% (43/79) of patients, Tuberculosis in 26.58% (21/79), non Specific inflammation in 18.99% (15/79). Among the pleural malignancies metastatic adenocarcinoma was found in 44.19% (19/43) patients, malignant mesothelioma in 25.58% (11/43) patients, squamous cell carcinoma in 16.28% (7/43) patients and benign mesothelioma in 11.63% (5/43) patients. There was no major complication, only four patients had minor complications (three had subcutaneous emphysema and one patient had post operative fever).

Conclusions

Semirigid Medical thoracoscopy is a semi-invasive and valuable tool in the diagnosis of undiagnosed exudative pleural effusion with minimal complication rate (5.06%). This procedure is very helpful in improving the quality of life of patients and therapeutic work can also be done with the procedure.

Initial clinical diagnosis	Yield of thoracoscopic pleural biopsy	Final diagnosis on thoracoscopic pleural biopsy
Malignant pleural effusion (N62)	51 / 62 (82.26%)	Pleural malignancy 43 (adenocarcinoma 19, squamous cell carcinoma 7, malignant mesothelioma 11, benign mesothelioma 5, solitary fibrous tumor of pleura 1) Tubercular pleuritis 8 Nonspecific inflammation 11
Tubercular pleural effusion (N=17)	13/17 (76.47%)	Tubercular pleural effusion 13 Non specific inflammation 4

Table III showed diagnostic yield of thoracoscopy according to initial diagnosis. Out of 62 patient in whom malignant pleural effusion was the initial diagnosis, 43 diagnosed as malignant pleural effusion, 8 patient diagnosed as tuberculous pleural effusion. In 11 patient no definitive diagnosis was made. Out of 17 patients in whom initial diagnosis was tuberculous pleural effusion, 13 were confirmed by thoracoscopy, in 4 patients no exact diagnosis were made.

19th WCBIP / WCBE World Congress
JOINT MEETING OF THE WORLD ASSOCIATION FOR BRONCHOLOGY AND INTERVENTIONAL PULMONOLOGY & THE INTERNATIONAL BRONCHOESOPHAGOLOGICAL SOCIETY
www.wcbipwcbe2016.org
Fortezza da Basso
May 8-11, 2016
Florence (Italy)

Multimodality bronchoscopic approach in management of stump dehiscence after surgery. A case series

Danai Khemasuwan[1], Javier Diaz-mendoza[2], Cynthia Ray[2], Michael Simoff[3]

[1]Pulmonary and Critical Care Division, Intermountain Medical Center - Usa
[2]Interventional Pulmonary Medicine, Henry Ford Hospital - Usa
[3]Interventional Pulmonary, Henry Ford Hospital - Usa

Introduction

The occurrence of stump dehiscence (SD) after surgery is associated with infection, prolonged hospital course and high mortality. The closure of SD and chest tube drainage is recommended. However, the data on bronchoscopic management of SD is limited due to rarity of the cases.

Objective

To review the technique and outcomes for multimodality bronchoscopic management of stump dehiscence.

Methods

This is a retrospective study of patients with stump dehiscence after surgery at Henry Ford Hospital from October 2003 to March 2015. These patients were treated with multimodality bronchoscopic management with Alloderm graft placement, fibrin glue installation and stent placement. Clinical characteristic, underlying lung disease and outcomes were analyzed.

Results

Nineteen patients (mean age of 59.9 years), were treated with therapeutic bronchoscopy for SD. Sixty-eight percent had malignant etiology. A median of two procedures (1 to 10) were performed in the patients in this series. Fifty-eight percent had Alloderm patch placement. Eighty-nine percent had fibrin glue instillation with a median of 4 mL of fibrin glue was instilled in each procedure. Eighty-nine percent had stent placement to cover or bypass the dehiscence site with 82% of these stents were covered Ultraflex metallic stent. Three patients underwent surgical closure. At the end of follow-up period, eighty- three percent of the patients survive in the benign group and 61.5% survive in malignant etiology. In survival group, all of the metallic stent was removed after bronchoscopic observation of healed dehiscence.

Conclusions

The use of Alloderm graft placement, fibrin sealant and covered metallic stent placement for a closure of stump dehiscence of the central airways was usually effective with multiple, repeated procedures. Surgical closure provided better survival. However, in non-surgical candidates, multimodality bronchoscopic management seems to be reasonable choice in this group of patients. In survival group, this bronchoscopic intervention provides temporarily mechanical closure and allows dehiscence stump to heal and completely close the fistula during the follow up period.

id 157

19th WCBIP / WCBE World Congress
JOINT MEETING OF THE WORLD ASSOCIATION FOR BRONCHOLOGY AND INTERVENTIONAL PULMONOLOGY & THE INTERNATIONAL BRONCHOESOPHAGOLOGICAL SOCIETY
www.wcbipwcbe2016.org
Fortezza da Basso
May 8-11, 2016
Florence (Italy)

Four consecutive elderly cases developing Takotsubo cardiomyopathy during flexible bronchoscopy

Manami Sazuka[1], Hiroshi Yamamoto[1], Chiemi Usuki[1], Hironobu Hamaya[1], Ai Kataoka[1], Yoko Hanaoka[2], Haruaki Hino[3], Hirokazu Yamada[1]

[1]Department of Respiratory Medicine, Tokyo Metropolitan Geriatric Hospital - Japan
[2]University of Tokyo Health Service Centre, University of Tokyo - Japan
[3]Department of Thoracic Surgery, Tokyo Metropolitan Geriatric Hospital - Japan

Introduction

Flexible bronchoscopy (FB) is a safe, widely applied procedure for the diagnosis of airway diseases or lung abnormalities. In case of the elderly, however, we should take account of uncommon adverse events. Takotsubo cardiomyopathy (TCM) is recognized as stress-induced cardiomyopathy, which is typically associated with transient dyskinesia or akinesia of the LV apical wall with normal or hypercontractile motion of the basal wall. FB can give elderly patients so much stress that it is apprehensive about developing TCM.

Methods

Here we report a series of cases diagnosed as TCM during or after FB as follows. Case 1: A woman aged 85 developed TCM one day after FB. Case 2: A woman aged 85 developed TCM 6 days after FB. Case 3: A man aged 85 developed TCM 5 days after FB. Case 4: A man aged 78 developed TCM during FB. Two of four cases (Case 3, 4) recovered from TCM by watch and wait without additional severe events. However, Case 1, 2 were followed by heart failure, thromboembolism, or arrhythmia and ended in death.

Conclusions

TCM is an uncommon, but an important adverse event of FB on the elderly, because it can lead to severe events such as pump failure, arrhythmia, or thromboembolism. British Thoracic Society states in its guideline that routine electrocardiogram (ECG) monitoring during bronchoscopy is not required but should be considered in those patients with a history of severe cardiac disease and those who have hypoxia despite oxygen supplementation. However, TCM can be developed without any cardiac disease, and therefore should be mentioned in the safety guidelines of FB on the elderly with referring to routine monitoring of ECG.

Bibliography

British Thoracic Society Bronchoscopy Guidelines Committee, a Subcommittee of the Standards of Care Committee of the British Thoracic Society. Thorax 2001; 56(Suppl 1): i1–i21.

19th WCBIP / WCBE World Congress
JOINT MEETING OF THE WORLD ASSOCIATION FOR BRONCHOLOGY AND INTERVENTIONAL PULMONOLOGY & THE INTERNATIONAL BRONCHOESOPHAGOLOGICAL SOCIETY
www.wcbipwcbe2016.org
Fortezza da Basso
May 8-11, 2016
Florence (Italy)

An simple method for placement of nickel titanium Y type stent

Chang-hao Zhong, Yu Chen, Xiao-bo Chen, Chun-li Tang, Shi-yue Li

Interventional pulmonary department, State Key Laboratory of Respiratory Disease, National Clinical Research Center for Respiratory Disease, Guangzhou Institute of Respiratory Disease, First Affiliated Hospital of Guangzhou Medical University, Guangzhou, Guangdong, China - China

Introduction

Y-stent is frequently used in clinical practice, it is commonly inserted by double guide-wire in general anesthesia through rigid bronchoscope and/or with X- ray guided.

Objective

To assess the efficacy and feasibility of a simple way to insert the Nickel titanium Y type stent, by using high-frequency jet ventilation, intravenous anesthesia, and single guide-wire through flexible bronchoscope.

Methods

This was a retrospective study, reviewed 15 patients underwent nickel titanium Y type stent inserted from Oct. 2013 to Nov. 2015 in First Affiliated Hospital of Guangzhou Medical University. Including 9 males and 6 females, aged from 42 to 81 years old(median 62y), 8 patients were mediastinal tumor invasion of the trachea and left and right main bronchus, 6 were tracheoesophageal fistulas secondary to carcinoma of esophagus after radiotherapy, 1 was severe airway stenosis caused by severe airway burn. After a routine intravenous anesthetic induction, pushing the guide wire to middle and lower section of trachea, then inserted a 2.66mm (8F) ventilation duct with the end at up and middle section of trachea, and connected to the jet ventilation(mode: frequency 80~100/min, pressure 0.12?0.16MPa), and a single guide wire was placed on the right / left lower lobe via nasal bronchoscope(diameter 4mm or 2.8mm), Y type stent were inserted to the lower trachea or above carina under direct vision, released the stent slowly, and adjusted the direction to the corresponding bronchial by bronchoscopy, when the stent closed to the intermediate junction of carina, released left and a right support bracket, after that released the proximal part of the stent completely.

Results

15 patients were successfully completed the stent placement, with good location and satisfactory outcome. There were no obvious changes in parameters including: blood pressure, oxygen saturation(SaO2), or heart rate(HR), and no major complications such as bleeding and pneumothorax.

Conclusions

Under the high frequency jet ventilation, the new method of single wire to insert the nickel titanium Y type stent through flexible bronchocopy was simple, safe and had a high success rate.

19th WCBIP / WCBE World Congress
JOINT MEETING OF THE WORLD ASSOCIATION FOR BRONCHOLOGY AND INTERVENTIONAL PULMONOLOGY & THE INTERNATIONAL BRONCHOESOPHAGOLOGICAL SOCIETY
www.wcbipwcbe2016.org
Fortezza da Basso
May 8-11, 2016
Florence (Italy)

The study on the effects of HIF-1? on the ragulation of fibroblasts in hypoxia in vitro

Jing Liu[1], Xiaodan Liu[1], Zhigang Cai[1], Huiran Zhang[2], Rongqin Li[2]

[1]Respiratory medicine, The Second hopsptial of Hebei Medical University - China
[2]Academic medical centers, Respiratory medicine - Shijiazhuang

Introduction

With the development of technology of emergency in the intensive care unit and the population of lung transplantation and airway operation, the morbidity rate of airway stenosis gradually increased. Studies of animal experiments and clinical cell culture in vitro showed that hypoxia was an important factor leading to the scar formation, fibrosis and inflammation. Our study further verified the the role of HIF-l? in fibroblast activation and its downstream signaling molecules involved in the scar formation through the identification and cultivation of fibroblasts in vitro hypoxia mode.

Objective

We aim to investigate the regulation of HIF-1? on fibroblast and activation and apoptosis and the mechanism under hypoxia.

Methods

1 We isolated and cultured fibroblasts from local tracheal stenosis in vitro and conducted the hypoxia-fibroblasts model with three-gas cultural system. The 3th or 4th generation fibroblasts from airway granulation tissue was selected, randomly divided into four groups and cultured for 12 h, 24 h, 48 h and 72 h in the incubator with 4% oxygen concentration. The expression of mRNA and protein of HIF-1?, ?-SMA, bFGF, VEGF and TGF- ?1 were detected by Real-time PCR and Western blot. 2 The 3th or 4th generation fibroblasts from airway granulation tissue was selected, randomly divided into four groups and cultured in the incubator with 4%?8%?16% and normal oxygen concentration for 12 h. The expression of mRNA and protein of HIF-1?, ?-SMA, bFGF, VEGF and TGF- ? were detected by Real-time PCR and Western blot.

Results

1 mRNA and protein expression level of HIF-1? gradually increased with the time extension under 4% oxygen concentration ($p<0.05$). The expression of mRNA and protein of the target genes including ? -SMA, VEGF, bFGF and TGF- ?1 increased in varying degrees under 4% oxygen concentration for different time?compared with the control group ($p<0.05$). 2 HIF-1? mRNA and protein expression gradually increased with the decrease of oxygen concentration that was 16%, 8% and 4%. Each was cultivated for 12h ($p<0.05$). The expression of mRNA and protein of the target genes including? -SMA, VEGF, bFGF and TGF- ?1 werecraised to different level under different hypoxia concentration compares with the normal group.

Conclusions

Fibroblasts under hypoxia for different time or under reduced oxygen concentration for the same time can promote mRNA and protein expression of HIF-1? and its target genes including ?-SMA, bFGF, VEGF, and TGF-?1. Our study shows that HIF-1? can promote the expression of genes associated with fibroblast proliferation by activation of fibroblast.

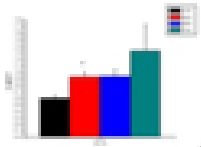

Fig.1 Expression of HIF-1α mRNA in different groups(n=3)

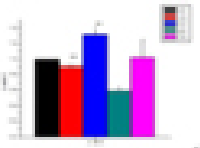

Fig.2 Expression of α-SMA mRNA in different groups(n=3)



Fig.3 Expression of VEGF mRNA in different groups(n=3)



Fig.4 Expression of bFGF mRNA i

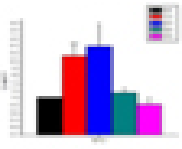

Fig.5 Expression of TGF-β1 mRNA



Fig.6 Expression of HIF-1α in different groups(n=3)



Fig.8 Expression of VEGF in different groups(n=3)



Fig.10 Expression of TGF-β1 in different groups(n=3)

Fig.7 Expression of α-SMA in three groups(n=3)



Fig.9 Expression of bFGF in different groups(n=3)



Fig.11 Expression of HIF-1α mRNA in different groups(n=3)



Fig.12 Expression of α-SMA mRNA in different groups(n=3)

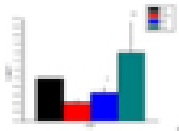

Fig.13 Expression of VEGF mRNA in different groups(n=3)

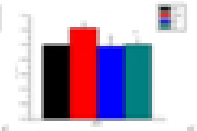

Fig.14 Expression of bFGF mRNA in different groups(n=3)

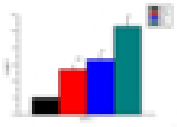

Fig.15 Expression of TGF-β1 mRNA in different groups(n=3)

Fig.16 Expression of HIF-1α in different groups(n=3)

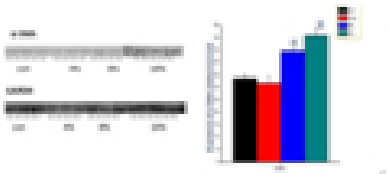

Fig.17 Expression of α-SMA in different groups(n=3)



Fig.18 Expression of VEGF in different groups(n=3)



Fig.19 Expression of bFGF in different groups(n=3)



Fig.20 Expression of TGF-β1 in different groups(n=3)

id 160

19th WCBIP / WCBE World Congress
JOINT MEETING OF THE WORLD ASSOCIATION FOR BRONCHOLOGY AND INTERVENTIONAL PULMONOLOGY & THE INTERNATIONAL BRONCHOESOPHAGOLOGICAL SOCIETY
www.wcbipwcbe2016.org
Fortezza da Basso
May 8-11, 2016
Florence (Italy)

Isolation and identification of fibroblasts from the patients with benign tracheal stenosis

Jing Liu, Xiaodan Liu, Zhigang Cai, Huiran Zhang

Respiratory medicine, the second hospital of hebei medical university - China

Introduction

With the development of technology of emergency in the intensive care unit and the population of lung transplantation and airway operation, the morbidity rate of airway stenosis gradually increased. The common causes of scar stenosis of airway is trauma. So the tracheal stenosis has become a kind of common disease of respiratory system and benign airway tracheal stenosis has become a common disease in respiratory intervention area. In recent years, keloid hypoxic environment and the role of HIF-1? in scar formation and contraction process have received more and more attention. Tracheal stenosis scar is essentially a fibrous proliferative disease, which is characterized by over expression of collagen based extracellular matrix and its composition changes.However, whether HIF-l? is involved in the benign tracheal stenosis scar tissue formation and its related signal transduction pathway has not been reported.

Objective

We aim to investigate the isolation and identification of fibroblasts of granulation tissue in the patients with benign tracheal stenosis, and this will provide a foundation for the research of the formational mechanism of benign airway stenosis in vitro.

Methods

This study was designed to culture the fibroblasts in vitro through the cultivation of tissue, purify the fibroblasts by difference adherence, then digest and subculture with 0.05% Trypsin-EDTA, then identify by morphological observation, HE staining and immunocytochemical identification method.

Results

1 The adherent cells were typically fusiform with larger cell body, clear boundaries, strong three-dimension and high refraction under the inverted microscope. 2 Immunohistochemistry results showed that vimentin staining was positive and a lot of brown yellow granules in the cytoplasm. 3 HE staining showed that the cells were long spindle shape with clear contour and big nucleolus.

Conclusions

The cultured cells identified by morphology, HE staining and immunohistochemistry with vimentin showed the characteristic of fibroblasts.



Fig.1 Morphology characteristics of fibroblast derived from airway granulation of patients with benign tracheal stenosis. A and B:There are fibroblasts creeped from granulation tissue at 9 days (×200); C and D: Serial subcultivation fibroblasts confluenced at 7 days (×400).

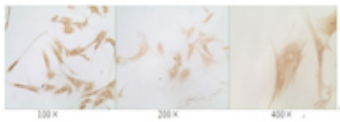

Fig.2 Immunocytochemical staining. Vimentin staining was positive. There were brown deposits kytoplasm in fibroblasts (×100, ×200, ×400).

Fig.3 HE staining of fibroblasts (×100, ×200, ×400).

Custom complex human airway stenting using 3D printing technology

Thomas Gildea, Michael Machuzak

Pulmonary, Allergy and Critical Care Medicine & Transplant Center,, Respiratory Institute, Cleveland Clinic - Usa

Introduction

Complex airway geometry is a challenge in many patients leading to innumerable procedures to manage stent related complications of infection and granulation tissue. Although self-expanding metallic stents (SEMS) have been a major improvement for some of these issues the risk of long term complications related to stent incorporation into the airway wall or metal fatigue/failure continue to be major limitations with non-malignant conditions. As we have been forced to use silicone (Dumon type) stents and perform fairly complex modifications to increase stent life we sought to make patient-specific stents based on the CT scan.

Objective

The process presented uses a standard CT to generate a 3D prescription in a proprietary software package then use a 3D printer to make a final product made of medical grade silicone.

Methods

We present 4 cases of how the technique addresses complex disease states. The technique is currently under FDA review pending clinical trials and/or compassionate use implantation prior to approval. Case 1. Patient with sarcoidosis and traction bronchiectasis has tracheobronchomegally but severe malacia at the carina to RMB with multiple recurrent infections and respiratory failure. He is currently managed with an 18mm silicone stent in the RMB but proximal malacia in the trachea is limiting improvement- no stent large enough to treat trachea. Proposed Y- stent but will expect problems loading and deploying stent but now has tracheostomy that may help. Case 2. Patient had a right auto-pneumonectomy following XRT from adenocystic tracheal cancer 10 years ago. The right lung was lost and there is residual scar at the carina into the LMB causing severe symptoms. Prior stents caused severe granulation from poor fitting cut, Y-stent related to abnormal anatomy. Case 3. Patient has an airway fire as a child during treatment of respiratory papllioma. Had open reconstruction and rib graft but later in life developed complex symptomatic airway stenosis. Case was published in past to try to manage one portion of airway (1). Despite Complex Y-stent modifications still has recurrent staph infection and severe rapid accumulation of secretions and halitosis and proximal granulation Case 4. Patient has multiple complex airway strictures and malacia from airway complications of GPA-Wegener's with recurrent pneumonias and respiratory failure prior to stenting. Prior left main stent stent eroded into the inferior medial wall with excessive granulation at secondary carina and proximal malacia with a much wider distal airway from the erosion.

Conclusions

Custom complex airway stenting may solve significant patient/stent problems.

Bibliography

Alraiyes AH, Machuzak MS, Gildea TR. Intussusception technique of intrabronchial silicone stents: description of technique and a case report. J Bronchology Interv Pulmonol 2013;20:342-344.

Case	Clinical/Stent Problems	Solution	Diameter range	Custom Stent
1	1) Tracheomegally 2) Carina malacia 3) different airway sizes between RMB/LMB and Trachea	Y-stent with variable sizes and each main stem custom	Trachea- 21mm RMB- 15.7mm LMB- 12.6mm	
2	1) Right auto-pneumonectomy 2) Scar at carina 3) Taper from trachea through distal LMB	Isolated trachea to LMB stent	Proximal Trachea-18.2 Proximal LMB-14.1 Distal LMB-11.9	
3	1) Long complex tracheal stenosis despite reconstruction and rib graft with non-linear trachea 2) Carina stenosis with Bilateral Main stem stenosis 3) RMB stenosis that narrows the take off the RUL	Multidimensional Y-stent with tracheal curving, curved LMB, RMB to RBI stent with hole for the RUL	Trachea variable- 13-14mm LMB- 10mm curved RMB 10mm curved but 7.5mm hole at orifice to RUL	
4	1) LMB long, curved, malacia and stenosis in different areas 2) Inverted cone-shaped airway distorted from prior stent 3) Distal left secondary carina disease from prior stent	Curved, conical stent with distal flange to be modified prior to implant. Variable wall thickness	Proximal LMB-12mm Distal LMB 15mm with flange. Distal LMB wall thickness is 1.0mm to be more soft compared to proximal airway at 1.5mm	

id 162

19th WCBIP / WCBE World Congress
JOINT MEETING OF THE WORLD ASSOCIATION FOR BRONCHOLOGY AND INTERVENTIONAL PULMONOLOGY & THE INTERNATIONAL BRONCHOESOPHAGOLOGICAL SOCIETY
www.wcbipwcbe2016.org
Fortezza da Basso
May 8-11, 2016
Florence (Italy)

Preliminary Clinical Evaluation of Montgomery T-tube on the treatment for subglottic stenosis after intubation/tracheotomy

Weizhan Luo[1], Changhao Zhong[1], Xiaobo Chen[1], Chunli Tang[1], Yu Chen[2]

[1]Respiratory Medicine, The First Affiliated Hospital of Guangzhou Medical University - China
[2]Guangzhou, The First Affiliated Hospital of Guangzhou Medical University - China

Introduction

Surgery remains the gold standard for the treatment of subglottic stenosis, however?airway stenting may be a choice for subglottic stenosis. And the Montgomery T-tube may play a role in alternative or complementary treatment for subglottic stenosis after intubation/tracheotomy.

Objective

To discuss our experience with the management of Montgomery T-tube on the treatment for subglottic stenosis after intubation/tracheotomy.

Methods

This was a respective investigated Montgomery T-tube for subglottic stenosis conducted between April 2014 and November 2015 at a tertiary care research institute in China. The primary outcome was treatment effect. The secondary end points were complications.

Results

13 Montgomery T-tube procedures were performed in 12 patients subglottic stenosis?9 after tracheotomy and 3 after intubation? enrolled this study. Before having T-tube, 72 bronchoscopy treatments were performed in 3 subglottic stenosis which was postintubation with a mean of 24 procedures per patient. After all the patients were placed, they swallow and ventilate well. The distance between T-tube and vocal folds was 12.3mm(5~25mm). 9 patients had complications after T-tube placement were observed in 9 out of 12 patients, 2 of them requiring treatment. Complications. And the complications were: granulomas in 4(30.8%),subglottic edema in 4 (30.8%), and sputum retention in 7 (53.8%)?and subcutaneous emphysema in 2?15.4%?. Cryotherapy and inject drugs treat the complications. However, one patient who had lots of granulomas replaced other type of Montgomery T-tube.

Conclusions

Montgomery T-tube on the treatment for subglottic stenosis is safe and effective. However, we should pay attention to the complications.

id 163

A 25-year follow-up of 2 airways stents (Gianturco Z-stents) placed during childhood

Lise Lucker, Paola Soccal, Frédéric Lador, Jérôme Plojoux

Division of Pulmonary Medicine, Geneva University Hospital - Switzerland

Introduction

Transposition of great vessels in infants is treated by a switch operation, which may be complicated by life-treathening vascular-driven tracheobronchial compression requiring surgery. The use of non-absorbable stents for benign airways compression in children is not the optimal treatment but can be an alternative in case of surgical failure.

Methods

A 25-year old man was referred to our Pulmonary Medicine outward because of a 6 weeks productive cough, which eventually improved after a 10-days antibiotic course. He didn't complain of dyspnoea. Clinical examination was unremarkable. He was born with a d-transposition of great vessels, operated at 6 days of life. Three months later, he presented with a stridor complicated by a respiratory arrest. Bronchoscopy showed a 70% narrowing of the trachea and a subtotal obstruction of the left main bronchus. Computed tomography-scan revealed a tracheal compression by the ascending aorta and a left main bronchus compression by the innominate artery. Because failure of 2 surgical innominate artery's suspensions, 2 Gianturco metallic Z stents were inserted in the trachea and the main left bronchus with a good initial result. During following years, physicians observed several strut's rupture of the tracheal stent, and barb's fragmentations, followed by a rupture of the left main bronchus stent, without migration. These stents ruptures were found incidentally on planned follow up in a symptom-free patient . For the management of the recent cough, work-up included pulmonary function tests, revealing a restrictive pattern and a flattening of the inspiratory curve, and a chest computed tomography scan, showing a posterior rupture of tracheal stent with fragments. One fragment had migrated through the posterior tracheal wall and reached the anterior part of a vertebral body, next to the oesophagus (Figure). The left main bronchus stent seemed broken at its distal inferior part but did not migrate outside the bronchus. The patient underwent a bronchoscopy, which confirmed the posterior rupture of the tracheal stent. Stitches of the stent could not be visualized in the posterior wall of the trachea. There was a protrusion of the distal anterior part of the tracheal stent in the lumen, which diameter remained above 50%. The left bronchus stent was completely covered by the bronchial mucosa.

Conclusions

This case shows a 25-years follow-up of a patient with 2 stents placed in his airways as an infant. Despite several fractures of the stents, the patient remained pauci-symptomatic and did not suffer of severe complication so far.

Bibliography

Bugmann P, et al. Chest 1994;106(5):1580–2.

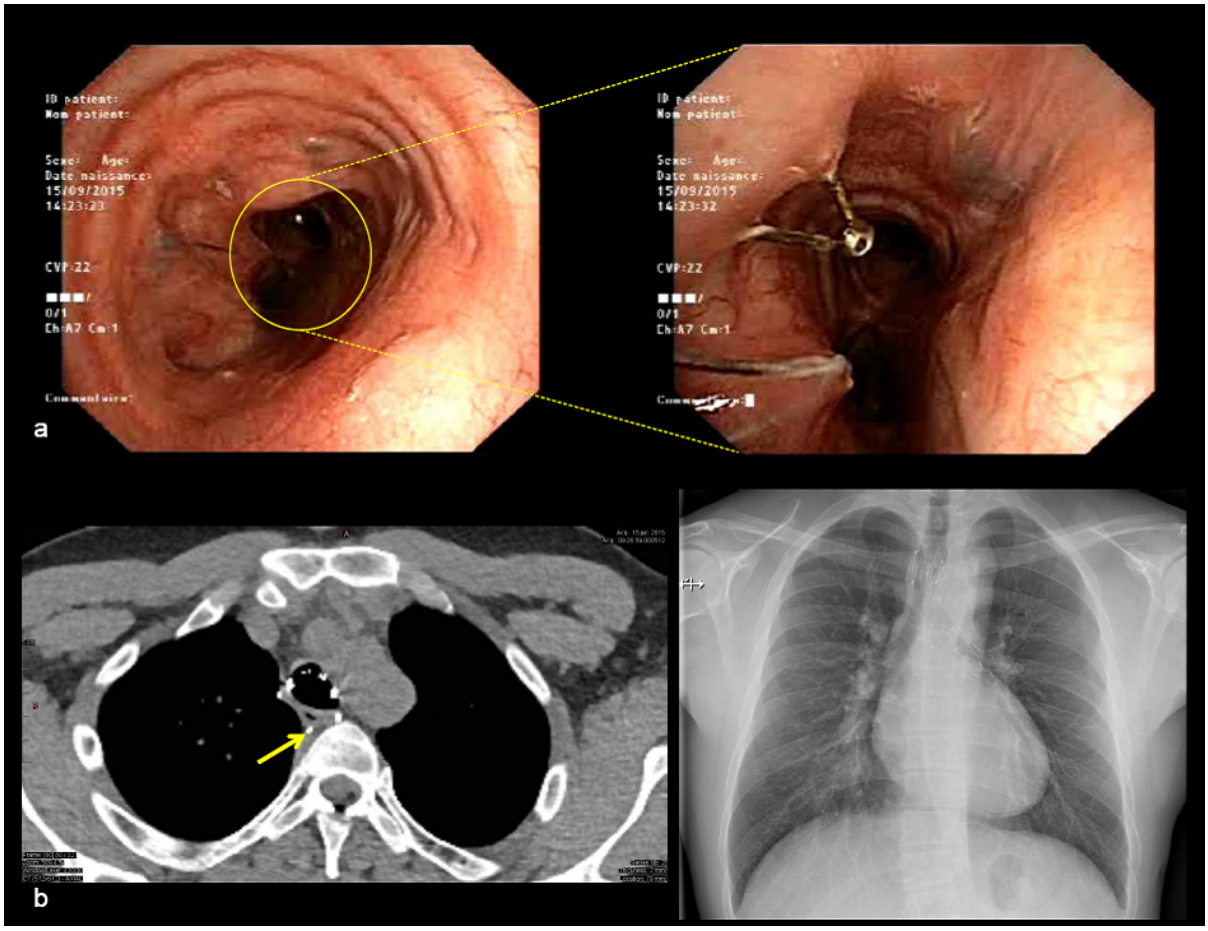
ID patient:
Nom patient:
Sexe: Age:
Date naissance:
15/09/2015
14:23:23
CVP:22
0/1
Ch:A7 Cm:1
Commentaire:
a
ID patient:
Nom patient:
Sexe: Age:
Date naissance:
15/09/2015
14:23:32
CVP:22
0/1
Ch:A7 Cm:1
b

id 164

Diagnosis of a cardiac lymphoma by endobronchial ultrasound-guided transbronchial needle aspiration

Beatrice Duxbury[1], Jean-claude Pache[2], Jacques Dumais[2], Paola Soccal[3], Jerome Plojoux[3]

[1]Division of Pulmonary Medicine, Geneva University Hospital - Switzerland
[2]Department of Clinical Pathology, Geneva University Hospital - Switzerland
[3]Department of Pulmonary Medicine, Geneva University Hospital - Switzerland

Introduction

EBUS-TBNA is well recognised for staging mediastinal lymphnodes in non small cell carcinomas. Recent reported sensitivity values for mediastinal lymphoma range from 76 to 91%. Yet, BTS guidelines do not recommend EBUS TBNA for this diagnosis. Primary cardiac lymphoma (PCL) is a rare entity, accounting for only 1.3% of cardiac tumors and 0.5% of extranodal lymphomas. The most frequent subtype of PCL is large B-cell non-Hodgkin lymphoma, and can arise from the epicardium or the myocardium, more frequently in the right cardiac chambers. The diagnosis is most often obtained by endomyocardial biopsy, with known associated risks. The following case report demonstrates that a posterior epicardial mass could be safely reached by EBUS.

Methods

A 75-years-old woman with moderate COPD was admitted for a 6 weeks history of dyspnea, weight loss and night sudations. The initial status revealed mild hypotension (91/67mmHg), tachycardia (147/min) and hypoxemia (SpO295% under O2 2L/min), the rest of the status was normal. An urgent CT scan showed a segmental pulmonary embolism as well as tissular intra-pericardial lesions, confirmed by an echocardiography and a cardiac MRI. This latter exam described 3 epicardial masses, in the posterior and superior pericardial recesses and in the left and right coronary sulcus, with right and left atrial as well as possible left and right ventricular wall infiltration. The cardiac function was preserved and the coronary arteries were intact according to the angiography. The 3 lesions were hypermetabolic on the FDG-PET-CT with a maximum SUV of 31. Cytology samples of the posterior epicardial mass were obtained by EBUS-TBNA from the left main bronchus, allowing a rapid diagnosis of cardiac diffuse large B-cell lymphoma after immunocytochemistry. No complication occurred post-procedure.

Conclusions

This case report illustrates that cytology specimens of a pericardial mass can accurately be obtained by EBUS-TBNA without any complication. Furthermore, it suggests that EBUS-TBNA can be used for diagnosis of mediastinal lymphoma and underlines its utility in such pathologies, as recently described by others. Figure Axial images of enhanced computed tomography showing left posterior (A-B) and right anterior (C) epicardial masses (asterisks). A: access to the mass by EBUS-TBNA (arrow). C: right coronary artery (arrow)

Bibliography

1. Kennedy MP, et al. Thorax 2008;63(4):360–5. 2. Jeudy J, et al. Radiogr Rev Publ Radiol Soc N Am Inc 2012;32(5):1369–80.

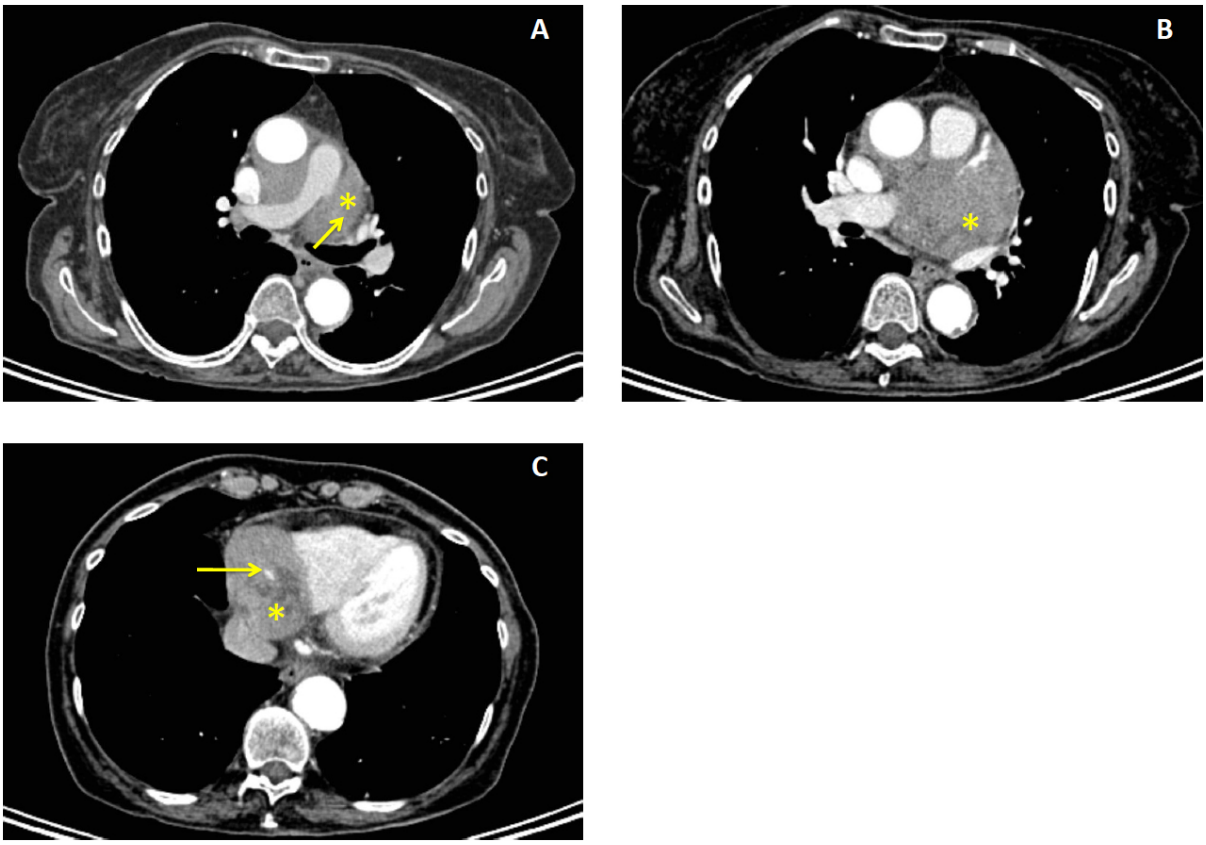

id 165

The aerstentR TBJ, a usefull treatment for right-sided post pneumonectomy broncho-pleural fistula

Dubrez Jean[1], Clerc Frederic[1], Lahon Benoît[1], Valentin Marylaure[2], Wittig Alexandre[2]

[1]Thoracic and Cardiovascular Surgery, Capio Clinique Belharra - France
[2]Department of anesthesiology, Capio Clinique Belharra - France

Introduction

Despite technical and medical improvements, fistula remains a life threatening complication after pneumonectomy. At the time of diagnosis, the patients often present with a poor clinical condition worsened by the abnormal ventilation of the remaining lung and the associated infection. Among the less invasive therapeutic options, the use of tracheo-bronchial stents was considered of benefit. The custom made TracheobronxaneTM DumonR stents (Novatech Marseille France) raised the problem of a bad adherence with the airways' mucosa. This was solved by the use of a covered self- expandable metallic stent after appropriate measures (SilmetR CO Novatech Marseille France). The second problem concerning the migration of the stent led to adopt an anchoring technic (Andreetti Cl). The present case reports the use of a L shape metallic covered stent. As it solve the two previous problems of the tracheo-bronchial stents, it allowed the complete occlusion of the fistula.

Methods

A fifty six years old male patient with a squamous cell lung carcinoma which preoperative status was cT2N0M0. A bilobar lower lung resection was performed complicated by broncho pleural fistula on the 10th post operative day. Four consecutive procedures consisting of thoracoscopic pleural cleaning, thoracostomy with myoplasty, right pneumonectomy and six ribs thoracoplasty were proposed, due to recurrence of the fistula. During that period never the left lung was infected nor the patient needed to be ventilated. Because the patient was young and the histopathology pT2N0M0, an ultimate procedure was considered. Implantation of a tracheo-bronchial self expandable covered stent (aerstentR TBJ Leufen Medical Berlin Germany) was decided. Firstly, computerized tomodensitometry allows the appropriate size of the stent to be chosen. Secondly, under general anesthesia, the stent was placed then gastrostomy and tracheostomy tubes were inserted. Immediately after air leak in the chest tube disappeared, even though the patient was ventilated and admitted in an intensive care unit. Afterwards the chest tube was pull out and the patient began to breathe spontaneously. Then the patient was discharged. The stent was extracted three months later.

Conclusions

As various sizes in diameter and length are proposed, the aerstentR TBJ should be considered for minimally invasive treatment in case of right-sided post pneumonectomy tracheo-bronchial fistula.

Bibliography

Andreetti Cl et al. Interact Cardiovasc Thorac Surg. 2012 Apr;14(4):420-3. doi: 10.1093/icvts/ivr077. Epub 2012 Jan 19.

id 166

Wrong way: a five-year retrospective study

Cátia Santos[1], Ana Bandeirinha[1], Salvato Feijó[1], Paula Monteiro[1], José Rosal Gonçalves[1], Carla Costa[2], Cristina Bárbara[1]

[1]Interventional Pulmonology Unit, Hospital de Santa Maria - Portugal
[2]International Pulmonology Unit, Hospital de Santa Maria - Portugal

Introduction

Aspiration to the airways can be a respiratory emergency resulting in serious pulmonary injury or even death. It occurs at all ages and a small proportion of cases are iatrogenic. The main treatment remains flexible and/or rigid bronchoscopy.

Objective

This study aims to characterize the frequency, type and cause of iatrogenic aspiration in hospital admitted patients. All cases required admission to an interventional pulmonology unit in a tertiary center.

Methods

We performed a retrospective and descriptive study between July 2009 and June 2014. This study includes all patients referred to our interventional pulmonology unit with iatrogenic aspiration events. Demographic data, type of injury, etiology and treatment were reviewed.

Results

During this period, 43 patients (0.8% of total patients) were diagnosed and tr treated. A total of 44 iatrogenic aspiration were identified. The mean age wa was 64 years and 24 patients (55.8%) were male. Etiologic distribution: aspiration of blood in 9 (20.4%); enteral nutrition i in 5 (11.4%); activated charcoal in 4 (9.1%); vomit in 3 (6.8%), barium c contrast in 3 (6.8%) and also foreign body aspiration like teeth in 5 ((11.4%); pills in 4 (9.1%); nasogastric tube in 2 (4.6%); and other in 9 ((20.4%). The main causes were surgical and anesthetic procedures in 20 (46.5%), therapeutic procedures in 14 (32.6%) and diagnostic procedures in 9 (20.9%). Concerning treatment 53 procedures were required: 39 (73.6%) flexible b bronchoscopies and 14 (26.4%) rigid bronchoscopies. 39 patients (73.6%) r required endobronchial “toilette” and 14 patients (26.4%) foreign body r removal. We had no complications. Two patients (4.7%) required a new endobronchial “toilette”.

Conclusions

Inward patients or patients submitted to diagnostic or therapeutic procedures under general anesthesia are at risk of aspiration events. Flexible bronchoscopy is the gold standard procedure to diagnose and treat these complications. Recognizing the severity of these events, despite his low incidence, implies a sp specialized and prompt referral to an interventional pulmonology unit.

id 167

19th WCBIP / WCBE World Congress
JOINT MEETING OF THE WORLD ASSOCIATION FOR BRONCHOLOGY AND INTERVENTIONAL PULMONOLOGY & THE INTERNATIONAL BRONCHOESOPHAGOLOGICAL SOCIETY
www.wcbipwcbe2016.org
Fortezza da Basso
May 8-11, 2016
Florence (Italy)

Management of anxiety in patients undergoing Endobronchial ultrasound (EBUS-TBNA)

Rebecca Trenear[1], Leon Gerard D'cruz[2], Syed Arshad Husain[2]

[1]Medical School, King's College London - Uk
[2]Respiratory Department, Maidstone and Tunbridge Wells NHS Trust - Uk

Introduction

As we perform endobronchial ultrasound transbronchial needle-aspiration (EBUS- TBNA) under “conscious-sedation”, a systematic study of anxiety levels modulated by sedation was warranted to formulate future optimal-sedation- protocols. We conducted a prospective observational study on a cohort of patients referred for EBUS-TBNA.

Objective

To determine the subjective levels of anxiety pre and post-procedure and to correlate these with the level of sedation used during procedure Aim: 1. Determining pre-procedure anxiety/discomfort levels and if they influenced patients’ willingness for a repeat-procedure if necessary. 2. Determining pre-procedure anxiety levels and if they decreased on titration of sedation.

Methods

Self-completing-questionnaires were distributed to patients (n=42, Female:Male ratio 5:9) post-EBUS procedure. The questionnaire featured 16 questions ranging from satisfaction, anxiety levels before, during and after EBUS. The Fentanyl and Midazolam doses administered were analysed and paired with the subsequent analyses.

Results

We observed anxiety levels pre-procedure positively correlated with discomfort-levels during the procedure (Pearson coefficient r=0.1276). Pre- procedure anxiety levels increased while post-procedure levels decreased over time, reflected in negative correlation-factor (Pearson coefficient r=- 0.1332). A positive correlation was recorded between the dose of Midazolam administered and anxiety levels pre, during and post-procedure (Pearson coefficient r=0.2569, r=0.0563, r=0.0825). Anxiety levels also correlated positively to Fentanyl doses before and during the procedure (Pearson coefficient r=0.1721, r=0.0571). Higher Fentanyl doses correlated with less anxiety as reflected by the weak negative correlation (Pearson coefficient r=- 0.1444).

Conclusions

Pre-procedure anxiety levels correlated with the degree of discomfort during the procedure, hence, patients with significant anxiety pre-procedure were likely to be more anxious during the procedure. Anxiety levels were lower at the start of the procedure (post-bolus-Midazolam), rising gradually during the procedure reflecting gradual weakening of sedation as Midazolam is metabolised with time.

Intrapleural fibrinolytic therapy using urokinase in empyema and parapneumonic effusions

Masamichi Mineshita, Atsuko Ishida, Rintaro Onoue, Shinya Azagami, Kazutaka Kakinuma, Hiromi Muraoka, Kei Morikawa, Mariko Okamoto, Ayano Usuba, Masao Takemura, Teppei Inoue, Naoki Furuya, Hirotaka Kida, Hiroshi Handa, Hiroki Nishine, Takeo Inoue, Teruomi Miyazawa

Division of Respiratory Medicine, Internal Medicine, St. Marianna University School of Medicine - Japan

Introduction

Intrapleural fibrinolytic agents are used in the drainage of pleural effusions. Intraleural urokinase has been reported to be effective in empyema and parapneumonic effusions, although a small risk of pleural bleeding were observed (1-2).

Objective

We reviewed our experiences of intrapleural urokinase for empyema and parapneumonic effusion and evaluated the safety and the efficacy of this treatment.

Methods

All patients with empyema and parapneumonic effusions who were treated with intrapleural urokinase between September 2008 and September 2015 were evaluated retrospectively.

Results

Twenty patients (mean age 69 years; 30% women) were included. Pleural effusions from 13 cases were culture positive. Of the 20 patients, 120,000 units of urokinase was injected once a day through the chest tube. The average dose of urokinase was 318,000 units (range 120,000 - 720,000 units). Nineteen patients experienced clinical and radiological improvement after intrapleural urokinase and were discharged. The average duration from admission to discharge was 19.2 days (range 10 - 35 days), and the average duration from the first instillation of urokinase to discharge was 10.7 days (range 4 - 31 days). One patient underwent operation 6 days after intrapleural urokinase and discharged 12 days after operation. Although 2 patients felt severe chest pain after instillation of urokinase, their symptoms improved with standard medication. There were no cases of pleural bleeding that required blood transfusion.

Conclusions

Although our study was not a randomized controlled study, intrapleural fibrinolytic therapy using urokinase seemed to be effective in patients with empyema and parapneumonic effusions and only acceptable adverse events were observed. Further studies are needed to determine patient selection criteria and the optimal dosing regimen.

Bibliography

1. Aleman C, et al. Lung 2015; 193: 993-1000. 2. Thomas R, et al. Chest 2015; 148: 746-751.

id 169

19th WCBIP / WCBE World Congress
JOINT MEETING OF THE WORLD ASSOCIATION FOR BRONCHOLOGY AND INTERVENTIONAL PULMONOLOGY & THE INTERNATIONAL BRONCHOESOPHAGOLOGICAL SOCIETY
www.wcbipwcbe2016.org
Fortezza da Basso
May 8-11, 2016
Florence (Italy)

Tunneled pleural catheters are safe in the setting of chemotherapy and immunosuppression

Candice L. Wilshire[1], Christopher R. Gilbert[2], Brian E. Louie[3], Ralph W. Aye[3], Alexander S. Farivar[3], Eric Vallieres[3], Jed A. Gorden[2]

[1]Interventional Pulmonology and Thoracic Surgery, Swedish Medical Center and Cancer Institute - Usa
[2]Interventional Pulmonology, Swedish Medical Center and Cancer Institute - Usa
[3]Thoracic Surgery, Swedish Medical Center and Cancer Institute - Usa

Introduction

The concern for infections related to immunosuppression during chemotherapy is often cited as a contraindication to tunneled pleural catheter (TPC) placement in patients with malignant/para-malignant pleural effusions (MPE/PMPE). Delays in definitive pleural palliation can result in progressive symptoms and decreased independence. The rate of TPC-related infections in patients receiving chemotherapy ranges from 4-20%; however, current data does not directly correlate the immune status of patients on chemotherapy at the time of infections.1,2

Objective

We aimed to correlate TPC-related infections in patients undergoing active chemotherapy to immune system competency and compare this to TPC-related infections in patients not receiving chemotherapy.

Methods

We reviewed patients with MPE/PMPEs from 2008-2015 and identified management with 278 TPCs, which were divided into two groups: 1) 196 TPCs of which insertion and/or drainage coincided with patients undergoing chemotherapy, and 2) 82 TPCs of which insertion and drainage did not coincide with patients undergoing chemotherapy. The TPC-related infections in group 1 were subdivided: associated with an immunocompromised versus immunocompetent state within 10 days of infection. An immunocompromised state was defined as leukopenia, lymphopenia, and/or neutropenia. A TPC-related infection was defined as either a deep pleural infection (purulent and/or a positive fluid gram stain/culture) or a superficial infection (catheter site cellulitis) requiring systemic antibiotics. A delay in chemotherapy was defined as an interruption in delivery of active chemotherapy for seven or more days.

Results

Of the 196 TPCs in patients undergoing chemotherapy (group 1), 15 (8%) were associated with an infection. Ten (5%) TPC-related infections occurred in an immunocompromised state, while 5 (3%) in an immunocompetent state. The median time to infection from TPC insertion was 2 months (interquartile range: 1-4). The presence of infection delayed chemotherapy in 40% (4/10) and 40% (2/5), respectively; p=0.576. Of the 82 TPCs in patients not undergoing chemotherapy (group 2), 10 (12%) were associated with an infection. The median time to infection from TPC insertion was 1 month (interquartile range: 1-2). There was no difference in infection rates between the two groups: 8% versus 12%, p=0.227. All infections were successfully treated with antibiotics (Figure). There were no infection-related mortalities in either group.

Conclusions

These results suggest that active chemotherapy and immunosuppression may not increase the risk of TPC-related infections as the rate remains low and comparable to immunocompetent patients. The continued use or need to initiate chemotherapy should not delay definitive pleural palliation with TPCs in patients with MPE/PMPEs.

Bibliography

1. Morel A, et al. Thorax 2011; 66:448-449. 2. Fysh ETH, et al. Chest 2013; 144:1597-1602.

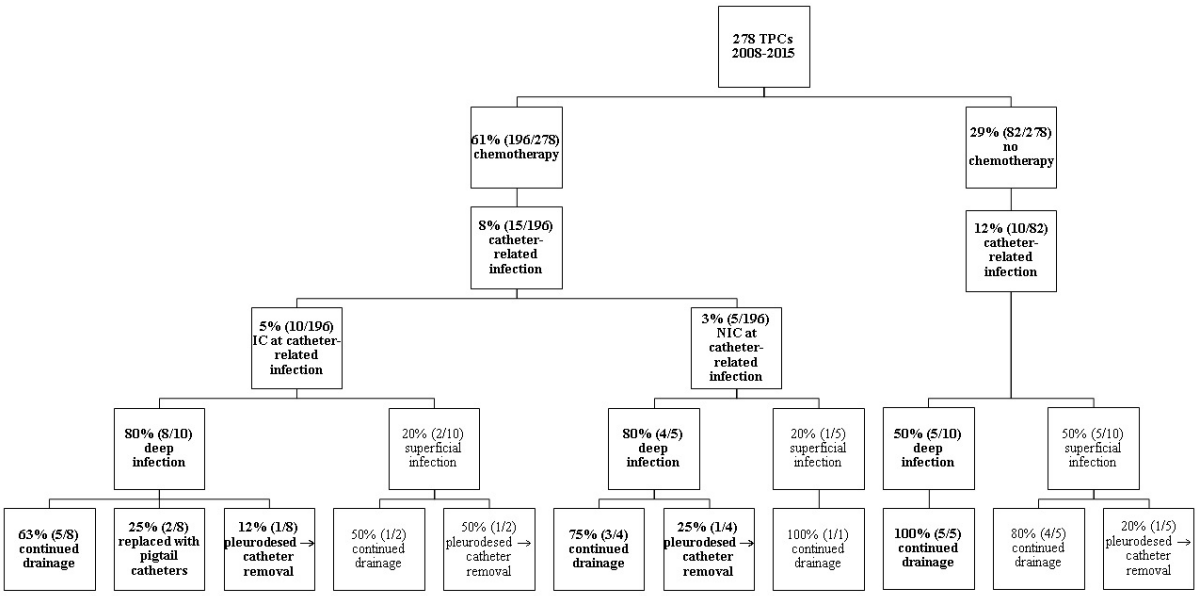

IC = immunocompromised; NIC = not immunocompromised

id 170

19th WCBIP / WCBE World Congress
JOINT MEETING OF THE WORLD ASSOCIATION FOR BRONCHOLOGY AND INTERVENTIONAL PULMONOLOGY & THE INTERNATIONAL BRONCHOESOPHAGOLOGICAL SOCIETY
www.wcbipwcbe2016.org
Fortezza da Basso
May 8-11, 2016
Florence (Italy)

Effects of Lung Transplantation on Excessive Dynamic Collapse

Carli J. Lehr, Atul C. Mehta

Department of Pulmonary Medicine, The Cleveland Clinic Foundation - Usa

Introduction

Excessive dynamic airway collapse (EDC) is defined by airway narrowing of greater than 50% and pathologic collapse due to laxity of the posterior membrane of the central airways. EDC can be seen in patients with chronic obstructive pulmonary disease (COPD) due to increased peripheral airway resistance, air-trapping, and the use of high dose inhaled corticosteroids and beta-agonists (1). Lung transplantation is seldom performed for EDC in COPD although we will present two cases of patients with EDC who experienced symptomatic improvement and flow-volume loop normalization following lung transplantation.

Methods

A 60 year old female with Gold stage IV COPD (FEV1 17%), a 15 year history of tobacco use, hypothyroidism, and diabetes mellitus underwent sequential bilateral lung transplantation. Prior to transplantation, she was treated with prednisone 10 mg, fluticasone 220 mcg, tiotropium 18 mcg, and inhaled beta-agonists. The pre-transplant flow volume loop demonstrated very severe air flow obstruction with hyperinflation and expiratory Computed tomography (CT) scan of the chest revealed near complete tracheal occlusion with bowing of the posterior membrane. A 57 year old female with Gold stage IV COPD (FEV1 14%), a 30 year history of tobacco use, hypertension, GERD, on continuous positive airway pressure underwent sequential bilateral lung transplantation. She was maintained on prednisone tapers twice a year, fluticasone 50 mcg, tiotropium 18 mcg, inhaled beta-agonists, and azithromycin 250 mg prior to transplantation. Pre- transplant spirometry revealed very severe obstruction with concomitant hyperinflation and CT scan obtained during expiration revealed EDC. Both patients underwent bronchoscopy following transplant demonstrating continued EDC of the central airways. Additionally, both patients experienced complete resolution of obstruction on spirometry with normalization of the flow-volume loop. Measurement of subjective dyspnea and functional limitation was greatly improved.

Conclusions

In our experience, the presence of EDC in COPD patients should not preclude patients from consideration for lung transplantation and may be considered a therapeutic option for patients who have failed conventional treatment. The peripheral airways are the site of increased lung resistance and a key contributor to increased intra-thoracic pressure in COPD which leads to the presence of EDC with further insult due to the frequent steroid and beta- agonist use in this population (2). The implantation of a healthy lung allograft replaces the malfunctioning peripheral airways in COPD and provides patients with a mechanism to overcome the severe central airway obstruction associated with EDC.

Bibliography

Mehta A et al. "Tracheobronchial smooth muscle atrophy and separation." Respiration 90.3 (2015): 256-262. Yanai M et al. "Site of airway obstruction in pulmonary disease." JnlofAppPhys 72.3 (1992): 1016-1023.

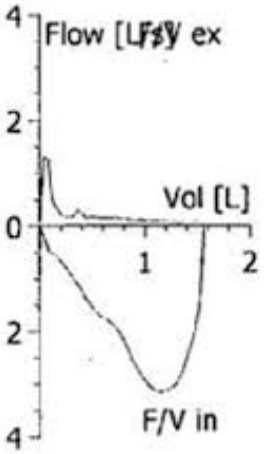

A.

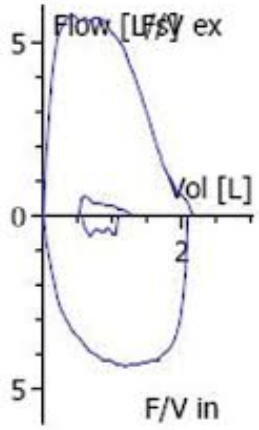

B.

C.

D.

id 171

19th WCBIP / WCBE World Congress
JOINT MEETING OF THE WORLD ASSOCIATION FOR BRONCHOLOGY AND INTERVENTIONAL PULMONOLOGY & THE INTERNATIONAL BRONCHOESOPHAGOLOGICAL SOCIETY
www.wcbipwcbe2016.org
Fortezza da Basso
May 8-11, 2016
Florence (Italy)

Respiratory papillomatosis: intralesional cidofovir after laser assisted mechanical resection

Emanuela Barisione[1], Roberto Carbone[2], Roberto D'agostino[3], Lauro Mazzarello[4], Elena Cappellaro[5], Carlo Genova[6], Mario Salio[1]

[1]UO Pneumologia, IRCCS AOU San Martino IST - Italy
[2]UO Malattie Infettive, AO SS Antonio e Biagio e C. Arrigo - Italy
[3]UO Otorinolaringoiatria, Istituto Giannina Gaslini - Italy
[4]UO Anestesia e Rianimazione Pediatrica, AO SS Antonio e Biagio e C. Arrigo - Italy
[5]UO Otorinolaringoiatria, AO SS Antonio e Biagio e C. Arrigo - Italy
[6]UOS Tumori Polmonari, IRCCS AOU San Martino IST - Italy

Introduction

The tracheal papillomatosis of the child is a rare disease with incidence ranging from 0.17 to 0.43 / 100,000 inhabitants. Most cases involve children born from young first-time mothers suffering from genital warts. Here we present the case of a young patient receiving treatment for recurrent papillomatosis.

Methods

A 3-years old child from Benin came in Italy after receiving endoscopic treatment for numerous papillomas in the larynx in his home country, which resulted in severe scarring. When the patient came to our attention, we performed a laryngoscopy and a bronchoscopy; the former showed emergence of new papillomas in the larynx, while the latter revealed a single papilloma in the carina. The biopsy revealed human papilloma virus infection. The patient underwent three CO2 laser procedures in the larynx and one neodymium-doped yttrium aluminum garnet (Nd-YAG) laser procedure in the carina; unfortunately, due to the preexisting scars, a tracheostomy was deemed necessary. Afterwards, the patients had returned to Benin, eventually contracting malaria, until he came back to our operative unit at the age of seven; this time, the patient was suffering from respiratory failure and tirage. Endoscopic procedures did not reveal recurrent laryngeal papillomas, while papillomas in the trachea were numerically increased to the point that they were occupying almost the whole surface of the trachea itself, the carina and the entrance of the main bronchi. We associated systemic therapy (interferon and ribavirin) with laser-assisted mechanical resection and infiltrations of cidofovir in the basis of the papillomas using a trans-bronchial needle aspiration (TBNA) needle connected to a three-way valve. Currently, the patient's conditions are improving and treated papillomas did not recur, although new papillomas kept developing in other areas of the respiratory tract.

Conclusions

The laser assisted endoscopic treatment is the gold standard for recurrent respiratory papillomatosis. In children who underwent 4 or more endoscopic treatments, or who present papillomas distally to the larynx, adjuvant therapy should be considered. Currently, no adjuvant therapy is considered curative. Local cidofovir , among others, is the most promising, although further studies are still needed to determine doses and dosing intervals. Unfortunately, cidofovir is no longer available in Italy. The special feature of this case is linked to the fact that cidofovir is used in combination with interferon and ribavirin therapy associated with bronchoscopic laser-assisted mechanical resection in a serious case of relapsing papillomatosis of the child.

Bibliography

Tjon Pian Gi REA, et al. Eur Arch Othorinolaryngol 2013; 270:1679-1687 Derek CS, et al. The Laringoscope 2008;118:1236-1247

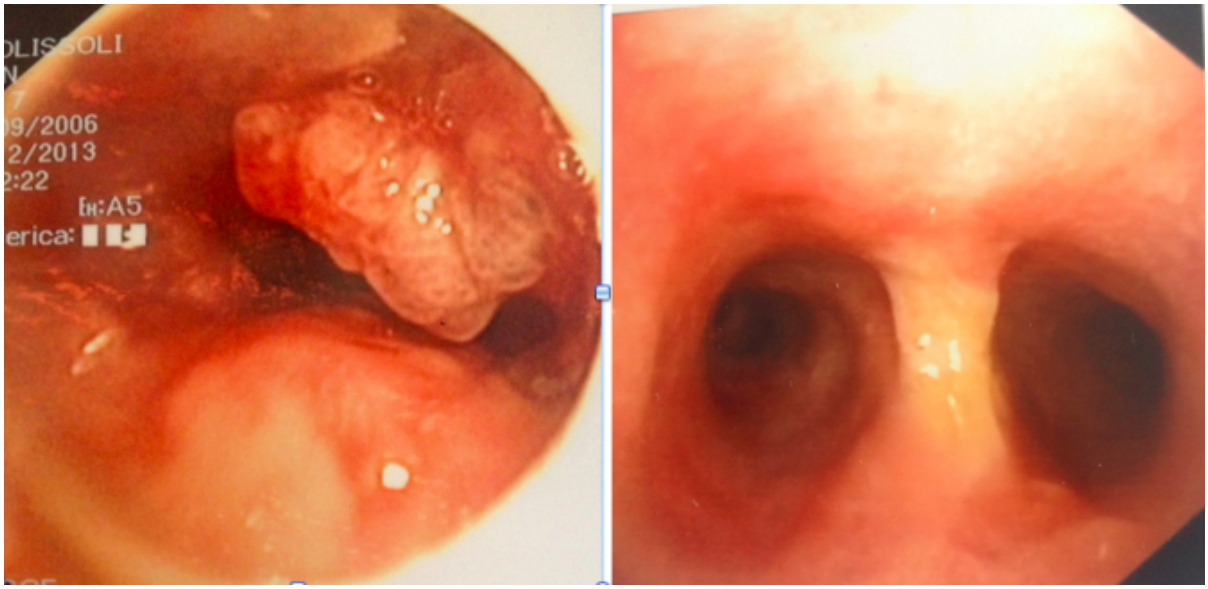

id 172

19th WCBIP / WCBE World Congress
JOINT MEETING OF THE WORLD ASSOCIATION FOR BRONCHOLOGY AND INTERVENTIONAL PULMONOLOGY & THE INTERNATIONAL BRONCHOESOPHAGOLOGICAL SOCIETY
www.wcbipwcbe2016.org
Fortezza da Basso
May 8-11, 2016
Florence (Italy)

Comparative study of Conventional chest tube drainage v/s Indigenous technique of Pleuroscopy

Deepali Bhandari, Hanmant Ganpat Varudkar, Arti Julka, Anukool Chandra Jain

Pulmonary Medicine, R.D. Gardi Medical College - India

Introduction

Bye and large, pleural diseases are managed only with intercostal drainage tubes(ICD) in our country. However there are limitations in diagnosis and some therapeutics with this procedure. We are working on especially designed, developed and used a new set of stainless steel (no. 316L) conduits (patents application no.) for pleuroscopy with Fiber Optic Bronchoscope (FOB).

Objective

The aim was to assess the impact of this technique on various pleural diseases.

Methods

A prospective, open, controlled trial was undertaken in patients with moderate to massive pleural effusions, hemothorax or pneumothorax, pyothorax without specified co-morbidities were randomly allotted to either study or control group. Both the groups were subjected to drainage of pleural contents with stoma under local anesthesia. In the latter group ICD was inserted. Former group underwent pleuroscopy as follows; simple curve conduit was passed through the stoma and FOB was negotiated through the it to visualize pleura. In the next step, this was replaced with parietal pleuroscopy conduit to inspect whole of the parietal pleura systematically. Similarly, the last one was replaced with visceral conduit to inspect the visceral part of pleura. Further, in appropriate cases adhesiolysis, opening of loculi were done, and ICD was inserted. Post-operative care of both the groups was done in our ward until chest drains were removed after full lung expansion.

Results

35 patients (Male-30, Female-8) of study group and 31(Male-22 Female-9) of control group with complete protocol were included in final analysis. Both the groups had comparable sex ratio, contents of pleural cavities, and associated parenchymal lesions. Even patterns of fluid distributions in pleural cavities were not different. All the patients of study group needed midazolam and more painkillers during the procedures. However, Duration of post-operative stay and drug requirement of study group was highly significantly less than control group (P = 0.001). There were no complications related to instrumentation.

Conclusions

Our technique of pleuroscopy helps early lung expansion with less medications for pleural diseases. This is also a safe procedure.

id 173

19th WCBIP / WCBE World Congress
JOINT MEETING OF THE WORLD ASSOCIATION FOR BRONCHOLOGY AND INTERVENTIONAL PULMONOLOGY & THE INTERNATIONAL BRONCHOESOPHAGOLOGICAL SOCIETY
www.wcbipwcbe2016.org
Fortezza da Basso
May 8-11, 2016
Florence (Italy)

Bronchoscopic Lung Volume Reduction by Histoacryl

Hatem M Shehata[1], Ayman A H Farghaly[1], Mona M Ahmed[2], Khaled M. Wageh[2]

[1]Pulmonary, Military Respiratory Center - Egypt
[2]Pulmonary, Ain Shams Univ. - Egypt

Introduction

The development of less invasive and less morbid approaches to lung volume reduction would represent a substantial advance in the treatment of emphysema. Several bronchoscopic procedures designed to reduce lung volume in patients with emphysema are under development. These include one-way valves, or bronchial occlusive devices to collapse emphysematous regions of lung and bronchial fenestration with bypass stents to improve expiratory flow . The advantage of Sealant adhesive lung volume reduction have been the reduced cost and the less recurrence due to collateral ventilation .

Objective

To report the first multicenter experience on the treatment of emphysema using histoacryl blue glue .

Methods

Fourty patients with diagnosed emphysema were bronchoscoped with instillation of Histoacryl in both upper lobes on two separate sessions separated by two weeks intervals . Spirometry, , ABG , exercise tolerance testing and 20 only with plethysmography were performed before and 90 days after the procedure.

Results

RV decreased by 15.30 % (p 0.567), FEV1 increased by 11.43 % (p 0.088), FVC increased by 22.92 % (p 0.007), and 6-min walk distance increased by70.39% (p 0.021). Patie. Five patients (12.5%) had complications in the form of chest pain in the first 7 days, only one death (2.5 %).

Conclusions

This study analysis confirms that improvement in pulmonary function and exercise tolerance that can be achieved in emphysematous patients using BLVR by Histoacryl. Future efforts should be directed to determining how to select those patients who would benefit most from this procedure and the best endobronchial treatment strategy.

Bibliography

Mineshita M, Slebos DJ., Respirology , Nov;19(8):1126-37,2014. Pizarro C,et al , Eur Respir J,Oct 30 2014.

id 174

19th WCBIP / WCBE World Congress
JOINT MEETING OF THE WORLD ASSOCIATION FOR BRONCHOLOGY AND INTERVENTIONAL PULMONOLOGY & THE INTERNATIONAL BRONCHOESOPHAGOLOGICAL SOCIETY
www.wcbipwcbe2016.org
Fortezza da Basso
May 8-11, 2016
Florence (Italy)

Cigarette smoking and smoking cessation restores laryngeal secretory homeostasis in rats

Rumi Ueha[1], Satoshi Ueha[2], Takaharu Nito[1], Kenji Kondo[1], Yoko Fujimaki[1], Hironobu Nishijima[1], Koichi Tsunoda[3], Francis Shand[2], Kouji Matsushima[2], Tatsuya Yamasoba[1]

[1]Department of Otolaryngology, The University of Tokyo - Japan
[2]Department of Molecular Preventive Medicine, The University of Tokyo - Japan
[3]Department of Artificial Organs and Otolaryngology, National Institute of Sensory Organs - Japan

Introduction

Cigarette smoke is a major source of exposure to toxic chemicals. In the respiratory organs, a long history of cigarette smoking (CS) significantly increases the risk of various mucus hypersecretion diseases such as chronic laryngitis and chronic obstructive pulmonary disease. Mucus accumulates in the respiratory tract and irritates the sensitive tissues therein, causing coughing. Coughing after smoking cessation (SC) is also common, possibly due to changes in the amount of mucus secretion from airways. The mechanisms that underlie the effects of CS and SC on respiratory secretion remain elusive, especially in the case of laryngeal mucus secretion.

Objective

We hypothesized that CS and SC cause laryngeal hypersecretion due to an increase in pro-inflammatory mediators such as IL-1?, IL-6, and TNF-?. In this study, to test this hypothesis, we established smoking models in eight- week-old male Sprague Dawley rats that involved administration of a cigarette smoke solution (CSS).

Methods

Firstly, we explored the effects of CS, short-term SC (four weeks), and long- term SC (three months) on laryngeal secretion and pro-inflammatory responses using histological analyses and quantitative real-time PCR (qPCR) analyses. Secondly, we investigated the effects of triamcinolone acetonide (TA) administration, which is one of glucocorticoids and have a long-lasting effect, on laryngeal secretion and inflammatory responses.

Results

We found that both CS and short-term SC increased laryngeal secretion. This change coincided with an increase in the expression of mRNA for the inflammatory cytokines TNF-?, and IL-6. Concurrent upregulation of MUC5AC mRNA, which is involved in mucin production was also observed. Interestingly, the extent of mucus secretion in the short-term SC model was higher than in the CS model. However, inflammatory responses and laryngeal secretion were lower in the long-term SC model than in the short-term model. TA administration suppressed CSS-induced laryngeal mucus hypersecretion and pro-inflammatory cytokine production.

Conclusions

These results indicate that CSS induces laryngeal hypersecretion, while short- term SC causes further hypersecretion and upregulation of pro-inflammatory cytokines and MUC5AC mRNA. The inflammatory responses and hypersecretion that occur during CS exposure and after SC represent promising targets for the treatment of cigarette smoke-associated prolonged cough and hypersecretion. TA may reduce expression of pro-inflammatory cytokines in the larynx and thus be useful for the treatment of CS-induced hypersecretion.

Successful use of EBV and medical thoracoscopy in intractable bronchopleural fistula

Xiaodan Liu, Jing Liu, Zhigang Cai

Respiration Medicine, The Second Hospital of Hebei Medical Universiry - P . R China

Introduction

Bronchopleural fistula is a fistula formed between alveoliã€•all levels of bronchial and pleural cavity. It can be caused by a variety of reasons, of many therapies, the medical interventional treatment and the surgical management and laser coagulation are used widely. Conservative medical therapy is including biological therapyã€•plugging into EBV flapperã€•using Nd: YAG laser and using the bentonite type bronchial stents, but the effect is actually modest.

Objective

To evaluate a new method of the occlusion of intractable bronchopleural fistula.

Methods

Mr. Zhang, a 65 years old male, was definitely diagnosed as bronchopleural fistula after radiofrequency ablation. The operations were all successfully accomplished, later then, chest tightness and shortness of breath appeared. CT examination showed bronchopleural fistula. And then, local hospital operated thoracic cavity closed drainage for him. They also injected high-glucose to make the pleura conglutinationed. However, the effect is not satisfying. After treatment in our hospital, we tried to use EBV ,medical thoracoscopy and argon plasma coagulation to block the fistula.

Results

The new way successfully cured the intractable bronchopleural fistula.

Conclusions

EBV, medical thoracoscopy and argon plasma coagulation can be used as a new way to the intractable bronchopleural fistula.

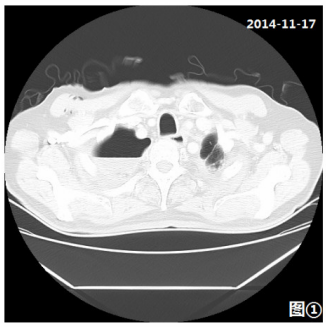

图①：入院时CT，可见右侧胸腔前部液气胸改变

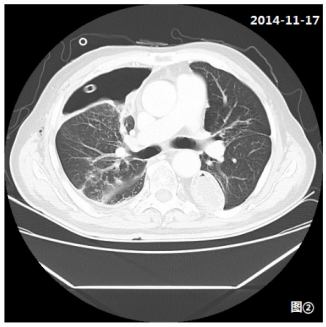

图②：入院时CT，可见右侧胸腔前部液气胸，内可见引流管

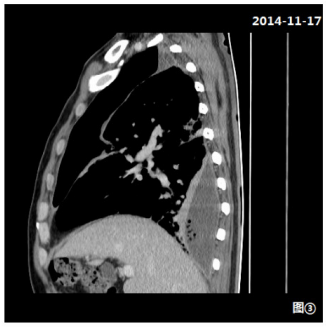

图③：入院时CT重建，可明显看见支气管胸膜瘘口

图④：第一次行支气管镜检查，第一次检查，可见右主支气管、右上叶及右中叶支气管开口均可见黄白色脓性分泌物，以右上叶为著。

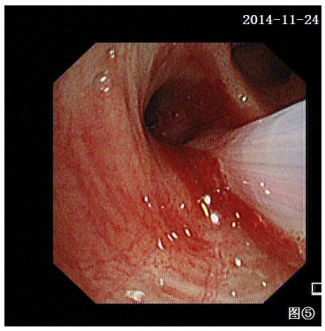

图⑤：支气管镜下行自体血及凝血酶注入封堵瘘口。

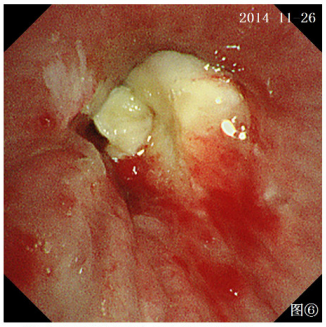

图⑥：全麻下行硬质支气管镜检查，于右上叶前段行硅胶海绵置入。

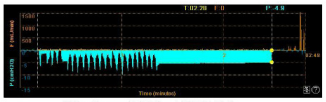

图⑦：行CRATIS球囊探测，未发现漏气迹象

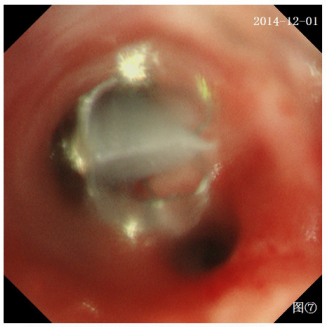

图⑦：经气管镜于右肺上叶尖段a支支气管置入EBA-TS-5.5单向活瓣

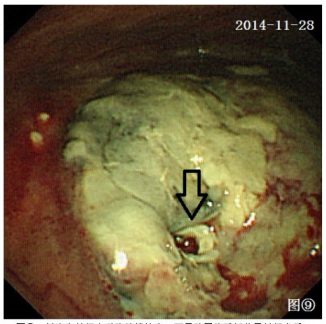

图⑨：首次为其行内科胸腔镜检查，可见脏层胸膜部分呈射频术后改变，局部可见瘘口并有气泡冒出。

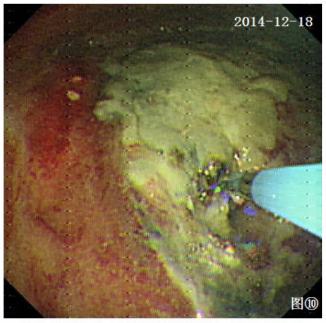

图⑩：发现瘘口后，予以氩等离子体凝固封堵瘘口并局部予以50%高糖保留，局部未见明显瘘口。

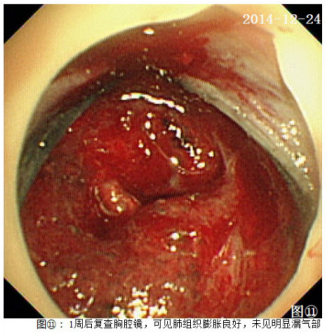

图⑪：1周后复查胸腔镜，可见肺组织膨胀良好，未见明显漏气部位，胸腔镜不可继续进入胸膜腔。

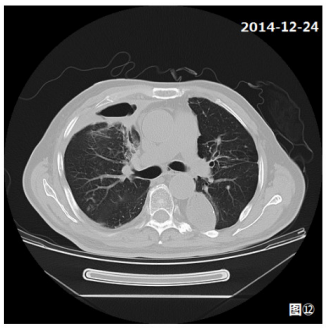

图⑫：复查胸部CT，前胸部气漏明显减少，治疗有效。

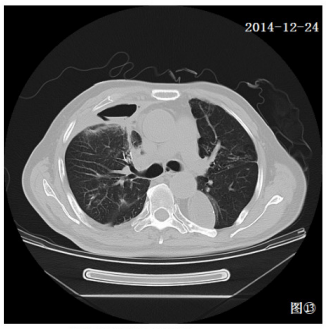

图⑬：复查胸部CT，可见活瓣

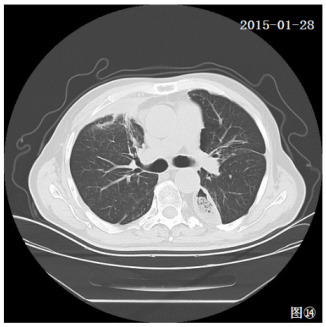

图⑭：3月后复查CT，未见明显液气胸，肺组织膨涨良好。

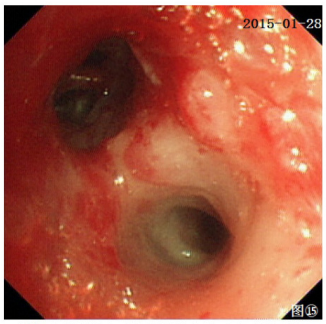

图⑮：行支气管镜检查，未见明显脓性物质，给予患者取出单向活瓣。

The European practice of airway stenting in the adult population: a survey of the EABIP

Dutau Hervé

Thoracic Oncology, Pleural Diseases and Interventiona Pulmonology Department, North University Hospital - France

Introduction

The commercially era of airway stenting (AS) started in Europe in 1987. Consequently, several companies started to develop other airway stents with silicone or metal over the last two decades. The EABIP was founded in 2002 with, among its objectives, the exchange of knowledge and experience within Europe, by launching joint international multicentre research projects.

Objective

International European survey focusing on AS practice among 26 European countries, represented by their EABIP national delegates.

Methods

A questionnaire was created and was sent to all EABIP board national delegates representing 26 European countries, in order to be fulfilled. Each national delegate was responsible in obtaining the most precise and objective data regarding AS practice in his/her country.

Results

AS (Figure 1) is performed in more than 30 centres in 3 countries, between 21 to 30 centres in 2, between 11 to 20 centres in 2, between 6 to 10 centres in 4, between 2 to 5 centres in 11 and 1 one centre in 2. AS is not performed in one country. AS is exclusively performed by pulmonologists in 5 countries and mainly by pulmonologists in 12. AS is mainly performed by thoracic surgeons in 3 countries. AS is equally performed by pulmonologists and thoracic surgeons in 3 countries, and equally performed by thoracic surgeons and ENT surgeons in one country. In all the countries, AS is mainly performed in public hospitals. In 10 countries, AS can be performed in private hospitals. AS under general anaesthesia (GA) is almost the rule for all the countries. In 16 countries, GA is exclusive. Stents can be place under LA in 9 countries. Rigid bronchoscopy is the main technique in 20 countries. Among these 20 countries, RB is exclusive in 5. RB and FB are equally performed in 2 countries. FB is favoured in 2 countries. Dumon straight and Y -shaped, Polyflex, T-Tube, Ultraflex, Dynamic and Silmet stents are the most spread. Eight countries have more than 10 commercially available brands while, 2 countries have less than 5 commercially available stents. Among the commercially available stents, the Dumon and the Ultraflex stents are far ahead the most placed. Eleven countries declare that AS is an economically worth activity while 10 countries claim that it is not.

Conclusions

This EABIP survey demonstrates an important heterogeneity in AS practice in Europe. Therapeutic bronchoscopy training and economic issues are probably the main reasons explaining these findings.

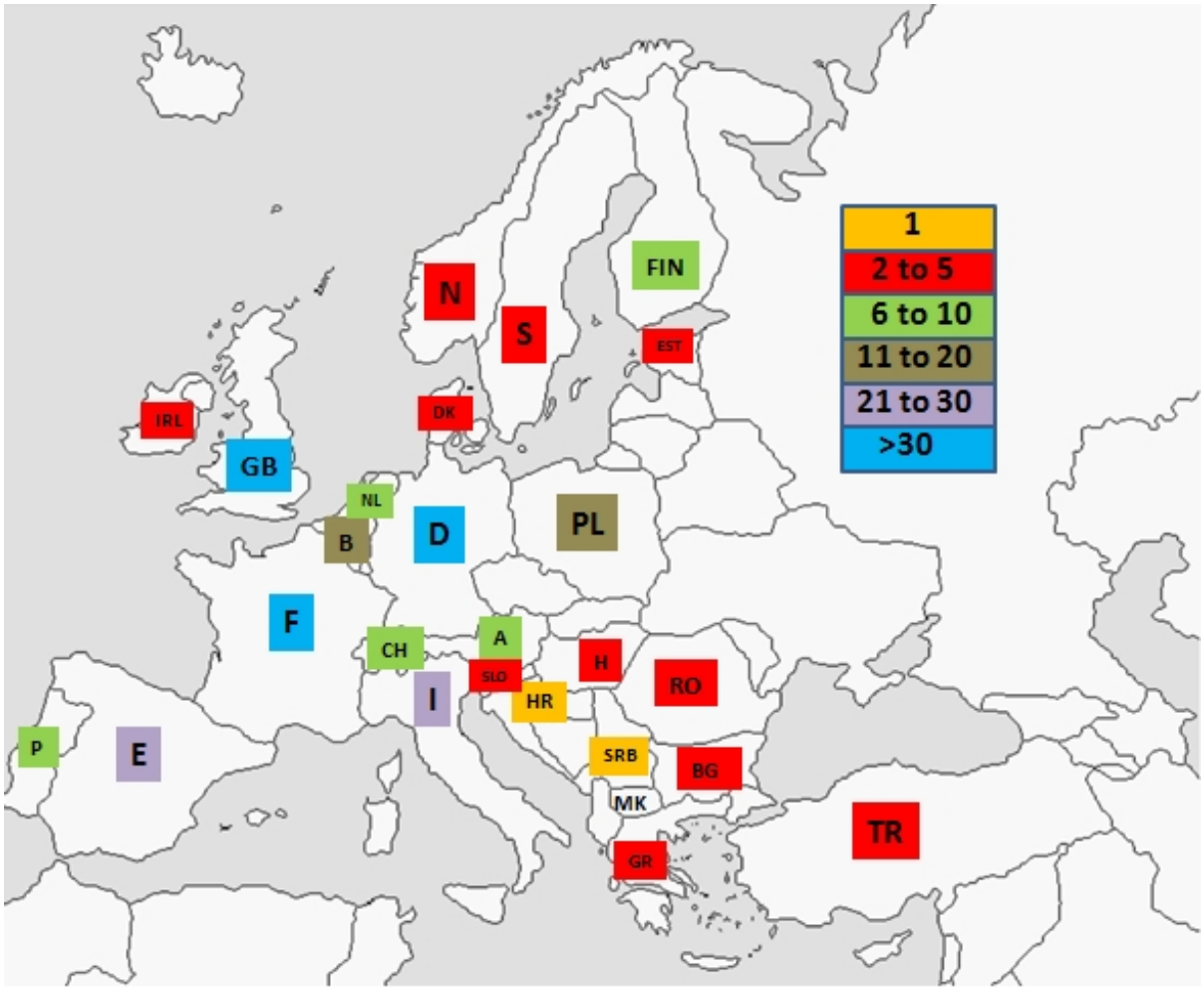

The presenting author has the following conflicts of interest that relate to this abstract: *I am consultant for Novatech SA*

id 177

19th WCBIP / WCBE World Congress
JOINT MEETING OF THE WORLD ASSOCIATION FOR BRONCHOLOGY AND INTERVENTIONAL PULMONOLOGY & THE INTERNATIONAL BRONCHOESOPHAGOLOGICAL SOCIETY
www.wcbipwcbe2016.org
Fortezza da Basso
May 8-11, 2016
Florence (Italy)

Feasibility of VATS lobectomy in small children

Yong Soo Choi, Seok Kim, Hong Kyu Lee, Jong Ho Cho

Thoracic Surgery, Sungkyunkwan University School of Medicine, Samsung Medical Center - South Korea

Introduction

There have been only small numbers of reports for VATS lobectomy in the pediatric population.

Objective

We reviewed our surgical experience and problems encountered during VATS lobectomy focusing on children less than 10 years old.

Methods

We tried VATS lobectomy in small children since July 2010. Between July 2010 and June 2015, 11 patients less than 10 years old underwent lobectomy by thoracotomy or VATS for lung disease, whose mean age was 40 months(0-10 years), mean body weight 14.83kg(1.55-34 kg) and mean height 95.21cm (48.5-142.2 cm). Diagnosis was congenital cystic adenomatoid malformation (n=6), congenital lobar emphysema(n=2), pulmonary aspergilloma(n=1), and malignancy(n=2).

Results

Of the 11 children, 5 children underwent thoracotomy and 6 children, VATS. Thoracotomy was required in case of infant, larger mass and history of previous thoracotomy. In VATS lobectomy group, resected lobe was RLL in 3, RML, LUL and LLL in 1 patient, respectively. VATS approach was done by three port VATS in 3, single port VATS in 2 patients. In single port VATS, we made a 3cm skin incision in the mid-axillary line of 6th intercostal space. The me median age, body weight and height at the time of operation were all si significantly different between VATS and thoracotomy group; 62 months vs. 19 days(p=0.04), 23kg vs. 5kg (p=0.02), and 117cm vs. 62cm(p=0.03), respectively. In VATS group, single-lumen endotracheal tube was used in 5 patients and double lumen endotracheal tube was used in 5 patients and double-lumen endotracheal tube in 1 patient. Mean operation time was 204 minutes and postoperative hospital days was 6.3 days in VATS group. There was one case of in-hospital mortality in thoracotomy group, emergency operation for congenital cystic adenomatoid malformation in a neonate with arrest, and the patient died on the day of operation. The other patients were discharged without any complication.

Conclusions

We tried VATS lobectomy in some small children less than 10 years old, and found the VATS lobectomy to be technically feasible and safe in selected group of them.

id 178

The application of stents in pediatric airway reconstruction

Jing Ma

Center for Respiratory Intervention, Qilu Children's Hospital of Shandong University - China

Introduction

The technique to treat disease using of airway remodeling with airway stents implantation and pediatric airway stents used is still at exploration stage at home and abroad.

Objective

To explore the interventional treatment effect on serious tracheal and bronchial stenosis, chondromalacia and external pressure lift-threatening disease.

Methods

1. Metallic stent group: (1) twenty children were implanted with thirty-seven cardiovascular stents, of which seventeen stents were implanted into the trachea and twenty into the bronchia. (2) One boy was implanted with the covered metallic stents, inhaled button type battery, caused serious tracheoesophageal fistula, the surgical repair was failure. 2. Silicone stent group?(1) Seven children were implanted with nine silicone stents, of which three stents were implanted into the trachea and six stents into the bronchia. (2) Two T-type silicone stent were implanted in the trachea of two children in the neck surgery under the supervision with the endoscope. Diseases were trachea stenosis and closure after endotracheal intubation. b. Implantation methods: (1) the cardiovascular balloon dilated metallic stent was placed at the pathologic position through the working channel of the soft lens. (2) Under the parallel direct viewing with the soft lens, the covered metal stents and the silicone stents were placed. (3) Silicone stents were placed with the rigid endoscope. (4) Surgery neck T type silicone stent was induced through the soft endoscope trachea.

Results

1. Twenty-one cases were successful in implantation metallic stents (including covered metallic stents), of which the stents were taken out in 7 cases, and 6 cases were dead – one case of pulmonary vascular malformation serious haemoptysis, one case of measles, one case of severe pneumonia, one case of liver failure and one case was gave up by the parents. 2. Nine cases were successful in implantation silicone stents, of which the stents were taken out in 7 cases. Two cases were not taken out, as one was dead and another self coughed. The granulation tissue was formation after the stents implantation in six cases, which was improved after refrigeration and stents arrangement.

Conclusions

The ages of the children are different and the causes are various, the selection and implantation method of the stents should be engineering designed, and the individual accurate treatment should be needed.

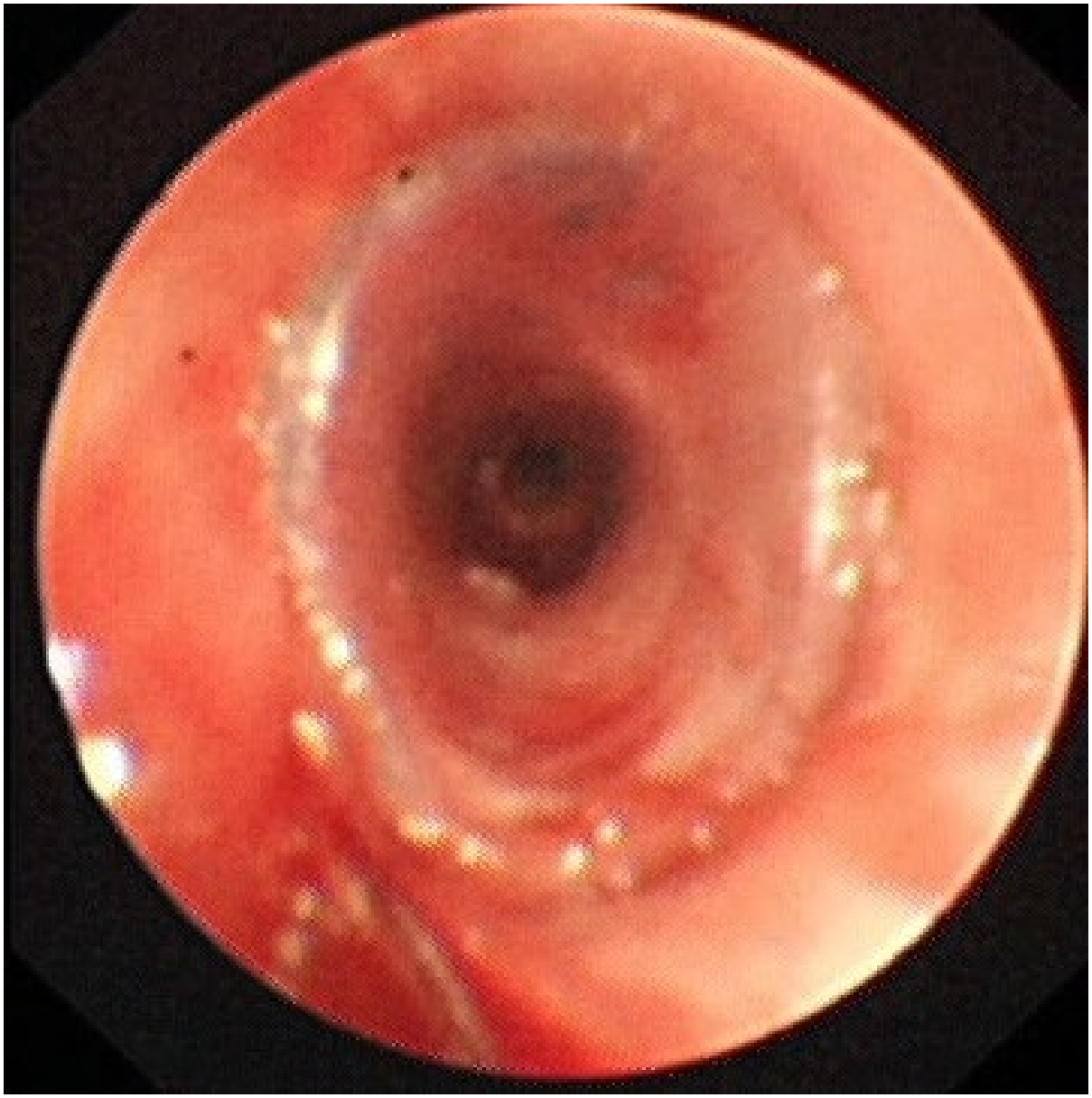

id 180

19th WCBIP / WCBE World Congress
JOINT MEETING OF THE WORLD ASSOCIATION FOR BRONCHOLOGY AND INTERVENTIONAL PULMONOLOGY & THE INTERNATIONAL BRONCHOESOPHAGOLOGICAL SOCIETY
www.wcbipwcbe2016.org
Fortezza da Basso
May 8-11, 2016
Florence (Italy)

Extremely rare case, differential diagnostic problem, solved by EBUS

Judit Varga, Gábor Grmela, Zsolt Pápai-székely

Department of Pulmonology, St. George University Teaching Hospital of Fejér County - Hungary

Introduction

The diagnostic method of endobronchial ultrasound (EBUS) is more and more widely used, in onco-pulmonology for cytological sampling and as an important oncological staging technique. Even though, sometimes this method yields surprising results.

Methods

The 60 year old female patient was admitted to our hospital with nausea, emesis, left upper quadrant abdominal pain and intensifying cough in lying position. According to her case history she had been hospitalized because of pancreatitis, 1,5 year earlier, and had regularly been followed-up for reason of remnant pancreas pseudocysts. Since than, multiple CT-examinations have shown a decrease in the numbers and extensions of the pseudocysts. At the time of admission, increased inflammatory values, moderate increase of amylase and lipase, as well as left shift of the complete blood count were verified by blood tests. Neither free abdominal air, nor abdominal fluid levels were seen on the native abdominal X-ray. Subcapsular splenic fluid was detected by abdominal ultrasound. The chest X-ray showed a right-sided widening of the upper mediastinum suggestive of malignant growth. The abdominal and chest CT-scan - ordered by our department - raised the possibility of extensive, lien and pancreas related pancreatic pseudocyst, which was spreading through the diaphragm to the upper mediastinum. During bronchoscopy, along the entire length of the trachea a prominent impression was detected from the pars membranacea region, that caused a moderate stenosis. In the paraoesophaegeal, paratracheal sac by EBUS examination moderate dense substance was detected with the echogenicity characteristic of fluid. By the puncture of the laesion quite viscous, coffee ground-like substance was aspired, with significantly increased amylase and lipase levels. Meanwhile we also performed the ultrasound guided, transdermal puncture of the paralienal, subcapsular fluid, which yielded a similar content to the EBUS sample. According to the outcomes, the diagnosis of pancreas pseudocyst was established. Further on the patient's surgical care, abdominal and transjugular mediastinal drainage was implemented.

Conclusions

Because of the rapid development of science and technique and specialization to even more and more particular areas, interdisciplinary cooperation and comprehensive way of thinking is especially important.

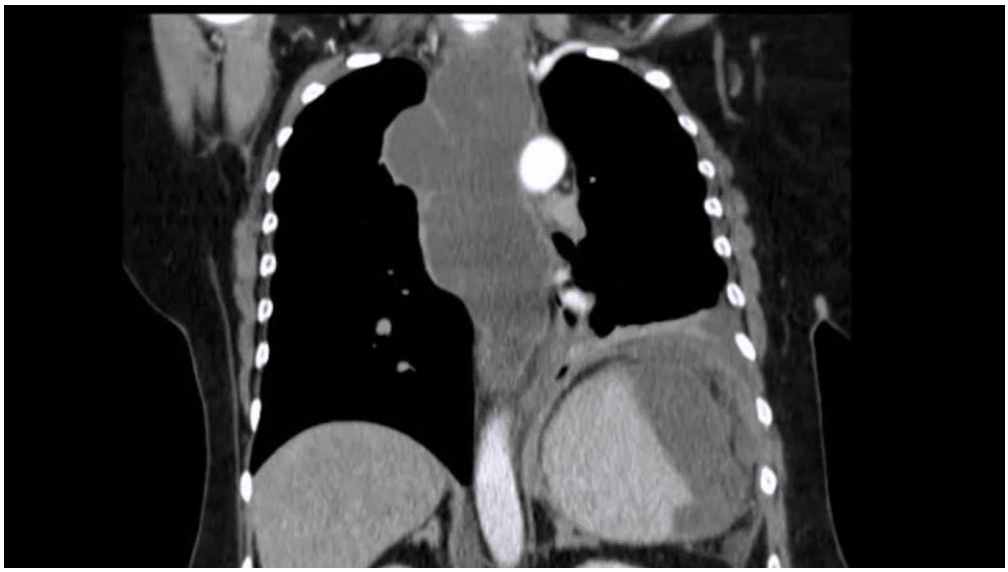

The "nonconformings"• in the quality system monitoring in a Respiratory Endoscopy Service

Cristina Erminia Legorini, Gianfranco Milani

UOC Pneumologia, Azienda ULSS 18 - Italy

Introduction

The Respiratory Endoscopy Service quality system is process-oriented and the implementation includes: identifying the process, understanding the interactions between these processes, documenting the processes in order to assure their effective efficiency and control.

Objective

The quality system defines the modality of measurement, analysis and improvement processes. After the identification of all the processes, we determined how to measure and monitor the applied procedures and how to control nonconformings (NCs) found for each procedure.

Methods

In 2001 we recorded a total of 160 NCs, which 130 (77%) regarding the Access Procedure (incomplete personal data, incomplete form for bronchoscopy request, lacking patient information, incomplete preoperative testing, lack of fasting, lack of cardiovascular therapy administration, lack of prophylactic antibiotics administration whereas it is indicated, lack of anticoagulant therapy control, contraindications). The corrective actions we adopted in 2002 include forms and brochures for physicians and information for patients. NC data and detailed information – corrective actions – were communicated to pneumology director. In 2002 we recorded a total of 121 NCs, which 106 (87%) regarding the Access Procedure; in 2003 a total of 125 NCs, which 107 (85.6 %) regarding the same procedure. In the 2014-october 2015 we recorded 150 NCs, which 78% regarding Access Procedure.

Results

The results revealed the no effectiveness of this corrective actions. According to Raison's theory, we implemented a check-list of systematic direct controls for all the patients done by physicians and nurses of the Respiratory Endoscopy Service. This check-list includes all the possible NCs of the Access Procedure.

Conclusions

The NC registration of 2014- October 2015- regarding Access Procedure – confirms that the application of this check-list is the only efficient strategy in order to provide for risk management in this procedure

Bibliography

Reason J. Managing the Risks of Organizational Accidents. Aldershot, UK: Ashgate; 1997.

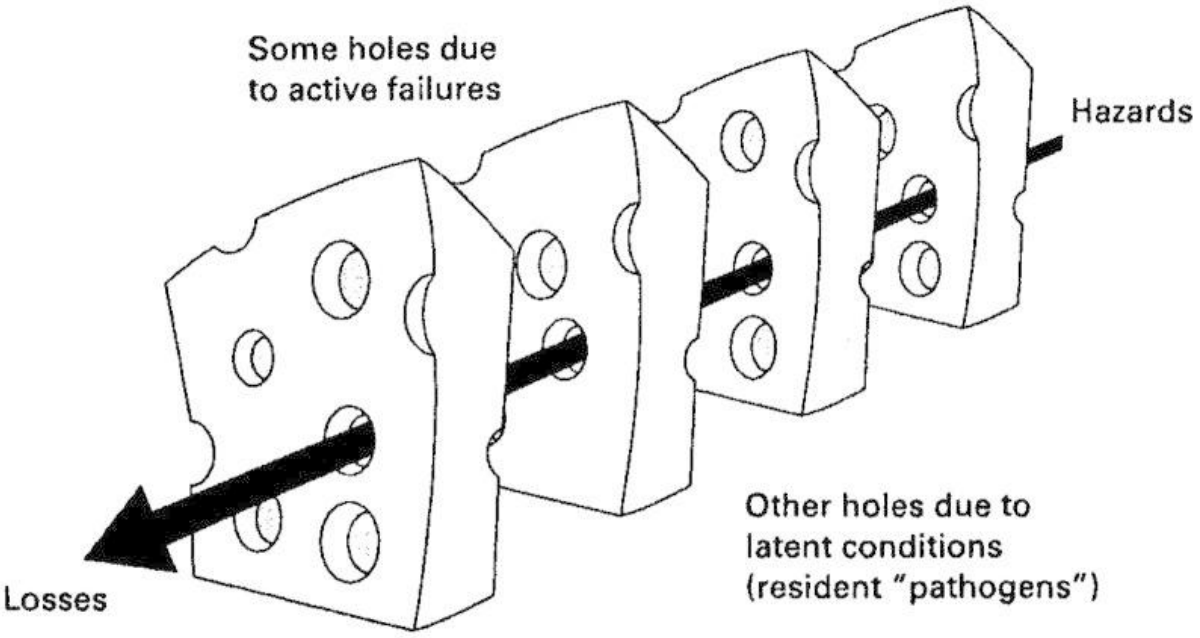

Successive layers of defences, barriers and safeguards

id 182

An Uncommon Recurrent Pleural Effusion: Case report and review of the literature

J. Francis Turner, Jr., Michael Mccormack, Anil Singh, Victor Gordon

Department of Medicine, Division of Pulmonary & Critical Care Medicine, University of Tennessee Graduate School of Medicine - Usa

Introduction

Recurrent exudative pleural effusions in association with an abdominal etiology may be associated with a ruptured viscus, abdominal abscess, or rarely with pancreatitis. We report the case of a 62-year-old woman with a pancreatic pseudocyst and recurrent pleural effusions owing to a pancreaticopleural fistula with subsequent review of the literature.

Methods

A 62-year-old female was admitted to the hospital medicine service complaining of worsening epigastric abdominal pain over the past several months. She had a known history of chronic pancreatitis associate with ethanol use, but recently noted increased epigastric pain and associated shortness of breath. Imaging was performed demonstrating a large pancreatic pseudocyst and changes consistent with acute on chronic pancreatitis with an associated pleural effusion. Due to her dyspnea, the pulmonary service was consulted and a right pigtail catheter was inserted with drainage of an exudate that also was notable for an amylase level of 11,525 units/L. Chest tube drainage was continued for 11 days and then removed owing to minimal drainage. Unfortunately there was recurrence over the following week with subsequent drainage demonstrating an amylase of 10,880 u/L. MRCP was performed showing findings consistent with a pancreaticopleural fistula (Fig. 1).

Conclusions

Pleural effusions associated with pancreatic disease are uncommon. The reported incidence with pancreatitis is 0.4% most often owing to alcoholic pancreatitis (1). Elevated amylase in pleural effusions is most often seen with malignancy, infection, esophageal rupture, and pancreatitis. Review of the literature reveals this is associated with disruption of the pancreatic duct and leakage of pancreatic fluid into the pleural space. Treatment is often complicated by the debility of the patient population and is initially conservatively managed with drainage and TPN. Recurrence may necessitate surgery with resection of the diseased or cystic pancreas and closure of the fistulous tract. Recurrent pleural effusions associated with pancreaticopleural fistulas are notable for markedly elevated pleural amylase levels and require a high index of suspicion in patients with chronic pancreatitis. Subsequent treatment is impaired by the overall debility of the patients and may include medical, endoscopic, and surgical therapy.

Bibliography

1. Francisco E, et al. Pancreaticopleural fistula: an unusual complication of pancreatitis. BMJ Case Rep 2015;doi:10.1136/bcr-2014-208814. 2. Ali T, et al. Pancreaticopleural fistula. Pancreas 2009; 38(1):e26-31.

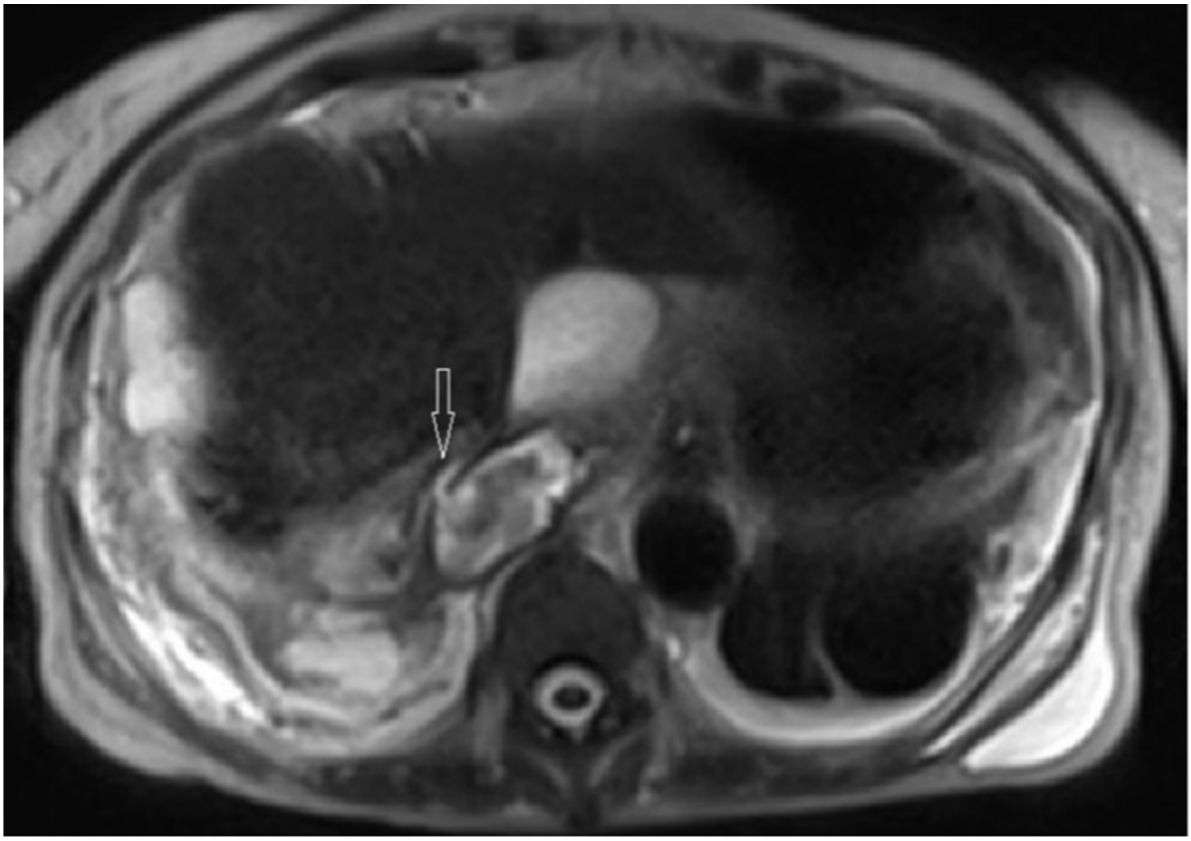

Figure 1. MRCP demonstrating pancreaticopleural fistula. *Open arrow shows communication between pseudocyst and pleural space.*

id 183

The Feasibility of Distal Bronchial Stenting for Lobar Salvage

Sonali Sethi, Michael Machuzak, Francisco Almeida, Joseph Cicenia, Thomas Gildea

Interventional Pulmonary - Respiratory Institute, Cleveland Clinic - Usa

Introduction

Airway stents are traditionally used in central airway obstructions to maintain airway patency. Historically, distal bronchial stenting within lobar and segmental bronchi has not been amenable to stenting. This is secondary to a multitude of factors including inability to find the appropriate stent size to fit within small airways. Additionally, there are questionable benefits to stenting small airways.

Objective

The Atrium iCast is a polytetrafluoroethylene covered stainless steel balloon deployed stent which is commonly used in the vascular arena. Its size ranges from 5-10x16-59mm. This stent can easily be deployed through a flexible bronchoscope under direct visualization. Our objective was to assess the feasibility, complications, and long-term impact of using this stent in patients with distal bronchial stenosis(DBS) either secondary to malignancy or benign etiologies.

Methods

All records of patients who had the placement of an iCast stent were reviewed over 3.5 years. For each patient the age, gender, location and histology, stent size, duration of stent placement, radiographic improvement, and complications were collected.

Results

A total of 122 iCast stents were deployed in 38 patients with DBS. The average age was 58 years with 50% male. The etiology of DBS included 45% malignant and 55% due to benign conditions. This was further categorized into 26% patients having DBS secondary to malignant disease following XRT, 18.5% patients with external compression secondary to malignancy, 37% lung transplant patients, and 18.5% patients with benign etiologies including rheumatologic or infectious diseases. The majority of stents were placed in the RML(37%), followed by the LLL(20%), RLL(15%), LUL(14%), and RUL(14%). 18.5% patients had stents placed in more than one segment. The most common stent size deployed was 7x16mm(48%), followed by 7x22mm(32%), 6x16mm(14%), 6x22mm(3%), 5x16mm(2%), and 8x38mm(1%). There was an average of 4 procedures per patient with a mean time to stent revision or removal of 85d. Common complications included migration(10%), granulation tissue formation(5%), deployment malfunction(2%), stent dislodgement immediately after deployment(2%), mucous plugging(1%), and tumor occlusion(1%). Eight patients had their stents removed with 5 patients achieving permanent airway patency. Remaining 3 patients had bronchial re-stenosis which could not be recaptured. One patient was lost to follow-up. Sixteen patients died. All patients had symptomatic or radiographic improvement.

Conclusions

Airway stents are commonly only deployed in CAO to reestablish patency. However, stenting small airways with lobar salvage is feasible and improves outcomes and quality of life. Small stents should be a part of every thoracic surgeon or interventional pulmonologists armamentarium for DBS.


LUL bronchial stenosis secondary to XRT

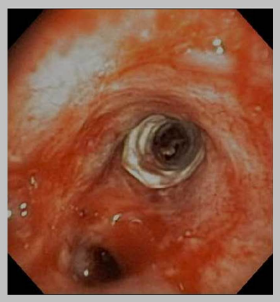


s/p Balloon dilation and iCast stent placement

id 184

19th WCBIP / WCBE World Congress
JOINT MEETING OF THE WORLD ASSOCIATION FOR BRONCHOLOGY AND INTERVENTIONAL PULMONOLOGY & THE INTERNATIONAL BRONCHOESOPHAGOLOGICAL SOCIETY
www.wcbipwcbe2016.org
Fortezza da Basso
May 8-11, 2016
Florence (Italy)

Bronchoscopic Cryoextraction and APC in Central Airway Obstruction by Blood Clot in Airway Bleeding

Eric Daniel Tenda[1], Abraham Yakub[2], Ceva Wicaksono Pitoyo[2]

[1]Division of Respirology and Critical Care, Department of Internal Medicine, c - Indonesia
[2]Division of Respirology and Critical Care, Department of Internal Medicine, Dr. Cipto Mangunkusumo National General Hospital/ Faculty of Medicine Universitas Indonesia - Indonesia

Introduction

Life threatening event due to central airway obstruction caused by very large blood clot formation with profuse on going bleeding its very challenging to manage. Interventional pulmonologist must aware about this situation which can lead to respiratory failure. There are several choices to treat this unlikely situation, in example flexible bronchoscopy with forceps, basket, snares and also rigid bronchoscopy. Cryoextraction is an approach that is indicated for central airway obstruction due to blood clots while argon plasma coagulation (APC) might stop hemorrhagic process immediately

Objective

We present a case with post-surgical tracheostomy bleeding which caused a giant blood clot formation in a disseminated intravascular coagulation due to severe sepsis in end stage renal disease patient, successfully managed with cryoextraction and argon plasma coagulation (APC).

Methods

In this case, attempt to evacuate blood clot in distal trachea with biopsy forceps was failed hence cryoextraction was performed. Presences of bleeding in former sites of blood clots were controlled by using APC.

Results

Cryoextraction was successful in extracting a 4 cm length and 1.5 cm thick size blood clot from distal trachea while APC successfully controlled hemorrhage sites immediately. Two days follow up bronchoscopy revealed no new blood clots and hemorrhagic process

Conclusions

This is a very rare case report using two endobronchial approaches which can give a quick, safe and cost effective lifesaving treatment

id 185

Does a learning effect influence the diagnostic yield of EBUS-TBNA?

Leonello Fuso[1], Francesco Varone[1], Daniele Magnini[2], Antonietta Pecoriello[2], Giuliano Montemurro[2], Giulia Angeletti[2]

[1]Bronchoscopy Unit, Catholic University - Italia
[2]Pneumology Unit, Catholic University - Italia

Introduction

It is known that the diagnostic yield of conventional transbronchial needle aspiration (TBNA) is characterized by a learning effect, so a training program is essential to improve the performance of this technique.

Objective

The aim of this study was to verify whether a learning curve similarly affected the yield of endobronchial ultrasound-guided (EBUS) TBNA in sampling of mediastinal lymph nodes. To this end, we evaluated sensitivity and diagnostic accuracy of EBUS-TBNA during the first three-year since the introduction of this technique in our Unit in October 2012.

Methods

EBUS-TBNA was performed using an ultrasonic endoscope (Olympus BF-UC180F) and 21- or 22-gauge needles. Cytological samples were obtained from mediastinal lymph nodes enlarged at chest CT-scan and/or with increased FDG uptake at PET-scan in patients with suspected lung cancer. The cytological diagnosis of EBUS- TBNA samples has been compared with the final diagnosis obtained from further invasive procedures, resection surgery or clinical-radiological follow-up.

Results

From October 2012 to October 2015 we collected 416 EBUS-TBNA cytological nodal samples: 240 were diagnostic for metastatic involvement and 176 resulted non- metastatic. The latter included 134 true negatives, 24 false negatives and 18 samples without a definitive diagnosis and considered as lost in follow-up (LFU). The definitive diagnosis was 264 metastatic and 134 non-metastatic lymph nodes (Table). The overall sensitivity was 85% (240 positive nodal samples out of 264 cases with a definitive diagnosis of cancer plus 18 LFU). Sensitivity per year was: first year 82% in 87 samples, second year 87% in 152 samples and third year 85% in 177 samples. The overall diagnostic accuracy of EBUS-TBNA, including also true negatives, was 90% (240 samples positive for metastatic involvement plus 134 true negatives out of total 416 samples). The diagnostic accuracy per year was: first year 85%, second year 91% and third year 91%. The most frequently sampled nodal stations were 7 (167 samples), 4R (118 samples), 10R (45 samples) and their diagnostic accuracy per year was respectively: station 7: first year 82%, second year 92% and third year 87%; station 4R: first year 93%, second year 89% and third year 95%; station 10R: first year 87%, second year 100% and third year 100%.

Conclusions

Our data show that the diagnostic yield obtained in the first year was lower than that achieved in the two following years. Thus, similarly to conventional TBNA, a learning effect could be recognized also for the EBUS-TBNA.

		FINAL DIAGNOSIS		
		Metastatic lymph node	Non-metastatic lymph node	**Total**
EBUS-	Positive for metastatic involvment	240	0	**240**
TBNA	Negative for metastatic involvment	42 (24 false negatives and 18 LFU)	134	**176**
	Total	**282 (264 cancer and 18 LFU)**	**134**	**416**

id 186

Does autoflorescence bronchoscopy still have a role in the early diagnosis of lung cancer?

Duilio Divisi, Gabriella Di Leonardo, Roberto Crisci

Thoracic Surgery, University of L'Aquila, "G. Mazzini" Hospital - Italy

Introduction

The early histological detection of bronchogenic carcinoma is characterized by the reduction of morbidity and improvement of overall survival after surgical resection. The endobronchial ultrasound and electromagnetic navigation seem to have supplanted the use of autofluorescence bronchoscopy (AFB).

Objective

The purpose of this retrospective study was to analyze the AFB in the diagnosis of precancerous and malignant lesions.

Methods

Two thousand five hundred twenty-six patients, with a parenchymal mass of 5 ± 2 cm in diameter to thin-section computed tomography, underwent AFB between January 2010 and January 2015. Only 852 patients (34%) with a visual score 2 or 3 of mucosa alterations were included in the study. Four bronchial biopsies were performed in each patient: 2 in “Twin Mode” and 2 in “Multiple Image Xposition” (MIX) technique.

Results

Histological evaluation of biopsies revealed 360 precancerous (42%) and 446 malignant (52%) lesions. Six hundred forty-four patients (75.6%) with lung cancer, carcinoma in situ and severe dysplasia still evident in a further AFB control after 2 months underwent lobectomy. Twenty-nine patients (18%) who experienced worsening dysplasia (moderate to severe) to endoscopic check at the third month received lobar resection. The sensitivity and specificity of “Twin” versus (vs) “MIX” technologies were 93% vs 95% ($p < 0.001$) and 52% vs 52%, with the diagnostic accuracy of 91% vs 93% ($p < 0.002$) respectively.

Conclusions

The autofluorescence bronchoscopy, based on the complementarity of the two modalities of investigation, allows the early detection of premalignant and malignant lesions. It is a safe, easy and fast procedure that provides a valid alternative to more invasive diagnostic methods.

Bibliography

Divisi D, et al. Interact CardioVasc Thorac Surg 2010;11:740-744 Sharma D, et al. Arch Med Sci 2015;11:1033-1043

A case of endobronchial lesion due to Mycobacterium avium in immunocompromised host

Lucia H Sales[1], Adriana Barreto[2], Ana C Braga[2], Maria Luiza Lopes[3], Karla V De Lima[3]

[1]Institute of Health Sciences, Federal University of Pará - Brazil
[2]University Hospital João de Barros Barreto, Federal University of Pará - Brazil
[3]Bacteriology and Mycology Section, Evandro Chagas Institute - Brazil

Introduction

Although pulmonary parenchymal disease due to Nontuberculous Mycobacteria (NTM) is well-recognized, endobronchial lesions as a result of NTM are rare in either an immunocompetent or immunocompromised host (1).

Methods

A 41-year-old man was diagnosed with acquired immunodeficiency syndrome (AIDS) in 2013 with multiple abandonments of treatment and 2 hospitalizations, the last in September 2015. The fisrt CD4 count was 26 cells/mm3 (oct, 2013); this year, 27, 403, 37 and 66 cells/mm3 in january, may, august and october respectively. CT scan of april, 2015 showed linear opacities and nodular opacities also with the tree-in-bud aspect in the apic posterior segment of the left superior lobe. Bronchoscopic of examination of june, 2015 revealed elevated sessile lesion in the right secondary carina (ulcerated), segmental anterior bronchus of the right upper lobe and middle lobe bronchus (Fig.). Bronchoscopic biopsy of the endobronchial lesion showed mucosa with intense inflammatory process. The Acid-fast bacilli staining (AFB) demonstrated limited suspicious structures for AFB. Acid-fast bacilli (AFB) staining was positive in bronchial washing fluid. Culture for AFB in the bronchial lavage was positive for nontuberculous mycobacteria after twenty one days, and M. avium was identified. Althoug being asked for, the patient took too long to return for medical consultation. Due to the very committed general state, he was hospitalized and antimycobacterial therapy started with 1.000 mg of clarithromycin, 600 mg of rifampicin, and 1.200 mg of ethambutol with the antiretroviral therapy beeing restarted.

Conclusions

We reported a case of an endobronchial M. avium infection in an immunossupressed patient. Few reported cases with and without AIDS. When presence of endobronchial lesions, except for one case of M. Kansassi (2), M avium was found. Patients with pulmonary disease due to M. avium diagnosed by sputum examination should undergo bronchoscopy? If presence of endobronchial lesions, must be accompanied by the ability to evolve for airway stenosis? If so, how should be the follow up?

Bibliography

1. S Kang, et al. Infect Chemother 2013; 45(1): 99-104 2. E D Manali, et al. Respiration 2005; 72: 305–308

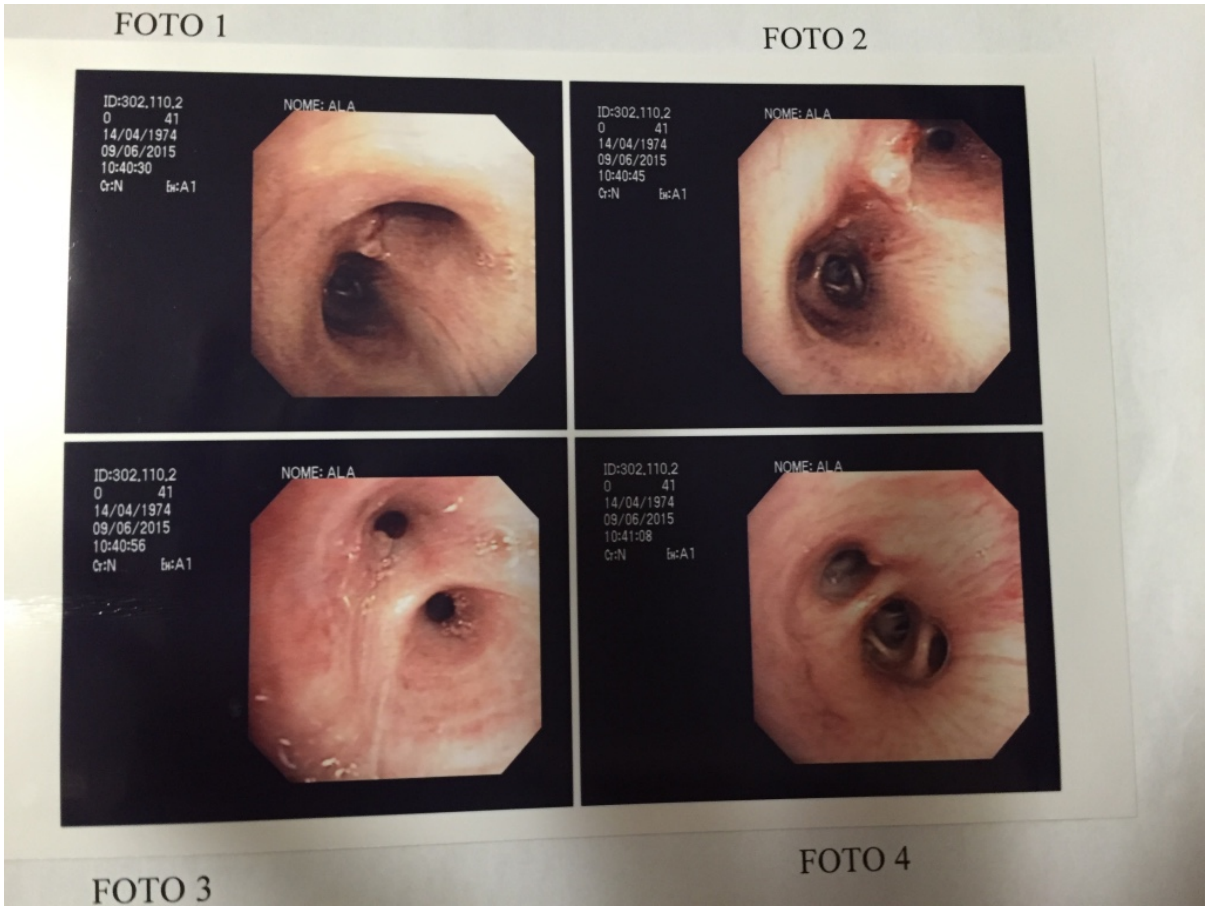
FOTO 1
ID:302.110.2
0 41
14/04/1974
09/06/2015
10:40:30
Cr:N Бк:A1
NOME: ALA
FOTO 2
ID:302.110.2
0 41
14/04/1974
09/06/2015
10:40:45
Cr:N Бк:A1
NOME: ALA
ID:302.110.2
0 41
14/04/1974
09/06/2015
10:40:56
Cr:N Бк:A1
NOME: ALA
ID:302.110.2
0 41
14/04/1974
09/06/2015
10:41:08
Cr:N Бк:A1
NOME: ALA
FOTO 3
FOTO 4

id 188

19th WCBIP / WCBE World Congress
JOINT MEETING OF THE WORLD ASSOCIATION FOR BRONCHOLOGY AND INTERVENTIONAL PULMONOLOGY & THE INTERNATIONAL BRONCHOESOPHAGOLOGICAL SOCIETY
www.wcbipwcbe2016.org
Fortezza da Basso
May 8-11, 2016
Florence (Italy)

TB-PCR using EBUS-TBNA samples in patients with intrathoracic granulomatous lymphadenopathy

Kyu Min Lee, Jung Seop Eom, Jeong Ha Mok, Ki Uk Kim, Mi-hyun Kim, Min Ki Lee, Kwangha Lee

Department of Internal Medicine, Pusan National University School of Medicine - South Korea

Introduction

Although endobronchial ultrasound-guided transbronchial needle aspiration (EBUS-TBNA) has been widely used to perform mediastinal lymph node sampling, little information is available on polymerase chain reaction for Mycobacterium tuberculosis (TB-PCR) using EBUS-TBNA samples in patients with intrathoracic granulomatous lymphadenopathies (IGLs).

Objective

We evaluate the efficacy of TB-PCR using EBUS-TBNA samples in patients with intrathoracic granulomatous lymphadenopathy.

Methods

A retrospective study with a prospectively collected database was performed to evaluate the efficacy of TB-PCR test using EBUS-TBNA samples in patients with IGL. Histological specimens were classified into five grades as follows: I) granulomatous inflammation with caseation, II) granulomatous inflammation without caseation, III) necrosis, IV) nonspecific, and V) inadequate sample

Results

Forty-six patients with IGLs (16 tuberculous lymphadenitis and 30 sarcoidosis) were included. The sensitivity, specificity, positive predictive value, and negative predictive value of TB-PCR for tuberculous lymphadenitis were 56%, 100%, 100%, and 81%, respectively. The overall diagnostic accuracy of TB-PCR for tuberculous lymphadenitis was 85%. In addition, 7 (17%) patients had grade IV and V disease, regarded as nondiagnostic, and all had nondiagnostic microbiological results of acid-fast bacilli smear and culture. Four (57%) of seven patients with grade IV to V disease had positive TB-PCR results, and anti-tuberculosis treatment led to clinical and radiological improvement in all patients.

Conclusions

TB-PCR using EBUS-TBNA samples is a useful laboratory test for diagnosing IGL. Moreover, it can prevent further invasive evaluation in patients whose histological and microbiological tests are nondiagnostic.

id 190

Diagnosis and bronchoscopic removal of airway foreign bodies in adults

Pee Hwee Pang, Wee See Yap, Alan, Wei Keong Ng

Respiratory and Critical Care Medicine, Tan Tock Seng Hospital - Singapore

Introduction

Foreign body (FB) aspiration is uncommon in adults. This study reports our experience with diagnosis and bronchoscopic removal of airway FBs in adults.

Methods

We retrospectively reviewed adult patients with airway FBs that required bronchoscopic removal over a 10 year period (2006 – 2015) in Tan Tock Seng Hospital, a tertiary teaching hospital in Singapore. Clinical records, radiographic investigations and endoscopy reports were reviewed.

Results

Between February 2006 and October 2015, a total of 13 patients were admitted to our institution for FB aspiration. The patients' ages ranged from 34 to 89 years, with a median age of 61 years. There were 8 male and 5 female patients. Only 2 patients (15.3%) provided a history suggestive of FB aspiration. Another 2 patients had pre-existing dysphagia. The common presenting symptoms were cough (69.2%), breathlessness (38.4%) and fever (38.4%). 2 patients (15.3%) were asymptomatic. Chest radiographs were non-diagnostic in 7 patients (53.8%). Computed tomography (CT) of thorax revealed FBs in 11 patients (84.6%), and was non-diagnostic in 1. 2 were diagnosed with FB aspiration only after bronchoscopy. The locations of the FBs were the left main bronchus (5), left lower lobe (3) right main bronchus (2), right middle lobe (2), right lower lobe (2) and right bronchus intermedius (1). 11 patients underwent flexible bronchoscopy. 2 had rigid bronchoscopy because of potential difficulty in removing the FBs. 1 patient required 2 flexible bronchoscopic procedures (15 months apart) as the first procedure was unsuccessful. The rest were successful (92.8%). The FBs were teeth (whole or fragments, 4), coins (2), bones (1 fish bone, 1 chicken bone fragment), nut, tablet, cigarette filter, plastic spoon fragment and screw. Various devices were used for bronchoscopic removal of the FBs. They were toothed forceps (8), biopsy forceps (2), Roth net (3), optical forceps (1), basket and snare (1). There were no procedural complications. 2 patients died of pneumonia as a result of FB aspiration. A total of 7 had pneumonia. 2 had exacerbations of underlying obstructive airway diseases.

Conclusions

A history of FB aspiration is usually not obvious. Chest radiographs are also not helpful. A high index of suspicion, together with the use of CT thorax and bronchoscopy will aid in prompt diagnosis. Bronchoscopic removal of FBs has a high success rate. As the complications of FB aspiration are significant, prompt diagnosis and removal of FBs by bronchoscopy are recommended.

Bibliography

Dong YC, et al. Removal of tracheobronchial foreign bodies in adults using a flexible bronchoscope: experience with 200 cases in China. Intern Med. 2012;51(18):2515-9.

No.	Sex/Age	Symptoms	Pre-existing Dysphagia	Imaging	Foreign body	Site	Bronchoscopy	Tools	Successful removal
1	M/60	Nil	nil	CXR, CT thorax	Coin	Left main bronchus	Rigid	Optical forceps	yes
2	M/61	Cough, dyspnea, sore throat	nil	CT thorax	Cigarette filter	Left main bronchus	Rigid	Rat tooth forceps	yes
3	M/77	Cough, dyspnea, fever	present	CT thorax	Tooth	Right bronchus intermedius	Flexible	Tooth forceps and Roth net	yes
4	M/51	Cough, fever, chest pain	nil	CT thorax	Broken off sharp pointed end of plastic spoon	Left main bronchus	Flexible	Biopsy forceps	yes
5	F/80	Cough, chest tightness	nil	CT thorax	Chicken bone fragment	Right main bronchus	Flexible	Rat tooth forceps	yes
6	M/70	Cough, dyspnea	nil	Bronchoscopy	Nut	Right lower lobe	Flexible	Biopsy forceps and Roth net	yes
7	M/49	Nil	nil	CXR	Tooth	Left lower lobe	Flexible	unknown	yes
8	F/43	Cough, fever	nil	CXR, CT thorax	Screw	Right middle lobe	Flexible	Rat tooth forceps	yes
9	M/71	Cough, dyspnea, chest pain	nil	CT thorax	Fish bone	Left main bronchus	Flexible	Rat tooth forceps	yes
10	F/72	Fever	nil	CXR, CT thorax	Tooth	Left lower lobe	Flexible	Snare, basket, balloon and different forceps	no
		Fever	nil	CXR	Tooth	Right middle lobe	Flexible	Snare, basket, tripods, balloon, different forceps and Roth net	yes
11	M/53	Cough, dyspnea	nil	CXR, CT thorax	Coin	Right main bronchus	Flexible	Rat tooth forceps	yes
12	M/34	Assault	nil	CXR	Tooth fragments	Right lower lobe and left lower lobe	Flexible	Rat tooth forceps	yes
13	F /89	Cough, fever, chest pain	present	Bronchoscopy	Tablet	Left main bronchus	Flexible	unknown	yes

19th WCBIP / WCBE World Congress
JOINT MEETING OF THE WORLD ASSOCIATION FOR BRONCHOLOGY AND INTERVENTIONAL PULMONOLOGY & THE INTERNATIONAL BRONCHOESOPHAGOLOGICAL SOCIETY
www.wcbipwcbe2016.org
Fortezza da Basso
May 8-11, 2016
Florence (Italy)

Missed diagnostic opportunities? A retrospective evaluation for evidence of excessive central airway

William Richter[1], Ismael Matus[2]

[1]Medicine, Georgetown University Hospital - Usa
[2]Interventional Pulmonology, Georgetown University Hospital - Usa

Introduction

Excessive central airway collapse (ECAC) refers to pathological narrowing of the central airways during expiration. ECAC consists of both tracheobronchomalacia (TBM) and excessive dynamic airway collapse (EDAC) which have differing underlying pathophysiology but have similar symptomatology. Symptoms frequently mimic or contribute to the manifestations of other pulmonary disorders which may in part explain why it is under recognized. It is therefore typically only discovered after a focused evaluation with dynamic inspiratory-expiratory CT or dynamic bronchoscopy. Combined inspiratory/end-expiratory CTs are often done to evaluate for air trapping in patients diagnosed with obstructive pulmonary disease, however, these CTs also have the capability for identifying ECAC. Prior studies have shown that combined inspiratory/end-expiratory CT's with >50% narrowing of the central airway on expiration, are remarkably specific for pathologic airway collapse, with one study noting a 94% specificity.

Objective

We reviewed combined inspiratory-end expiratory chest CT scans at our institution to evaluate for incidental findings of ECAC and the under- reporting of these findings.

Methods

We reviewed 372 inspiratory/end-expiratory CTs from 2008-2015 performed at Georgetown University Hospital, with the goal of evaluating the incidence of ECAC and how often it was reported by radiologists. ECAC was defined as a greater than a 50% loss of airway diameter in the trachea or main stem bronchi, based on airway collapse on expiratory images in comparison with inspiratory airway diameters.

Results

ECAC was present in 27 (7%) of these studies. Of these 27 abnormal scans, only 4 (15%) were formally reported as ECAC, airway collapse or malacia. Known diagnoses in these patients with radiographic evidence of ECAC included connective tissue disorders, ILD, COPD, and Obesity. Table 1 highlights the extent of narrowing, underlying diagnosis and recognition by radiologist for each combined inspiratory/end expiratory CT displaying evidence of ECAC.

Conclusions

We conclude that findings of ECAC can be a significant incidental finding that is heavily under reported at our institution and potentially at many others. Clinicians are therefore missing opportunities to further evaluate for a diagnosis of and potentially treat ECAC. While radiographic evidence of ECAC does not always represent the presence of clinical disease, in those patients with unexplained dyspnea, cough, or recurrent infections, a CT finding suggestive of ECAC warrants prompt diagnostic evaluation.

Bibliography

1) O'Donnell, C.R. et al. ....expiratory tracheal collapse in COPD. Clinical Radiology. 2014;69:357-362. 2) Baroni et al. Comparison between ...expiratory CT for Evaluation of Central Airway Collapse. Radiology. 2005;235:635-641.

Underlying Condition	Area of Narrowing	Severity of Narrowing	Mentioned in Report
Rheumatoid Arthritis	Trachea	68%	N
Pulmonary Fibrosis	Trachea	64%	N
ILD, OSA	Trachea	68%	N
ILD	Trachea	72%	N
ILD	Trachea	70%	Y
COPD, Pulmonary Fibrosis	Trachea	79%	N
ILD, COPD	Trachea	51%	N
Tracheal Compression	Tracheal Compression	58%	Y
Scleroderma	Trachea	65%	N
COPD, Cirrhosis	Trachea	57%	N
Wegner's	Trachea	68%	N
Asthma, Bronchiectasis	Trachea	84%	Y
Lung Nodule, Asthma	R Main Stem Bronchus	51%	N
Lung Nodules, Obesity	Trachea	55%	N
ABPA, Asthma	R Main Stem Bronchus	54%	N
Tracheal Stenosis	Trachea	56%	Y
Bronchiectasis	Trachea	62%	N
Pulmonary Alveolar Proteinosis	Trachea	92%	N
NSCLC, OSA	Trachea	70%	N
Rheumatoid Arthritis	Trachea	64%	N
Obesity	Trachea	52%	N
Pulmonary Alveolar Proteinosis	Trachea	95%	N
Pulmonary NTM, Bronchiectasis	Trachea	68%	N
Rheumatoid Arthritis	Trachea	62%	N
Sarcoidosis	Trachea	52%	N
Scleroderma, Pulmonary Fibrosis	Trachea	59%	N
Hepatitis C Cirrhosis	Trachea	50%	N

id 192

19th WCBIP / WCBE World Congress
JOINT MEETING OF THE WORLD ASSOCIATION FOR BRONCHOLOGY AND INTERVENTIONAL PULMONOLOGY & THE INTERNATIONAL BRONCHOESOPHAGOLOGICAL SOCIETY
www.wcbipwcbe2016.org
Fortezza da Basso
May 8-11, 2016
Florence (Italy)

Tracheal stent, an attractive choice in treating intractable children tracheoesophageal fistula

Lina Wang, Man Gao, Li Zhang, Deli Li, Fanzheng Meng

Department of pediatric respiratory, The Bethune First Hospital ,Jilin University - China

Introduction

Tracheoesophageal fistula (TEF) including congenital fistula and acquired fistula in children patients are relatively not rare. Although considered as a gold standard, open surgical repair is not a practical (or available) choice in some intractable cases, such as recurrent tracheoesophageal fistula (rTEF) and acquired tracheoesophageal fistula caused by corrosive substance. It is this kind of intractable condition that led the investigator and clinical practitioners to attempt to explore new alternatives for decades. In children, the endoscopic attempts, as an attractive alternative, have been reported including esophageal stenting, tissue glue and clips. So far, there is no report of using a tracheal stent to treat the rTEF.

Methods

Three boys ages are 3months,20months,29months respectively.They were treated for recurrent and acquired tracheoesophageal fistula. Two children were recurrent tracheoesophageal fistula and one child was acquired tracheoesophageal fistula. Two children were treated with the covered retrievable metal biliary stent and one child was treated with silicone stent. Three months later?all the three stents were taken out and, in the end, we found the one caused by button battery was occluded completely and 2 thirds of another metallic stent case was occluded while the silicone stent treating case was not occluded at all.But this treatment can win the time for open surgery.

Conclusions

In view of the treatment status of children tracheoesophageal fistula, we applied this treatment for the thorny problem at first time. We found the covered retrievable metal biliary stent is better than the silicone stent in treating the tracheoesophageal fistula,because the silicone stent had a poor ability to attach the trache.We can conclude that endotracheal stent closure is a new treatment method for recurrent and acquired tracheoesophageal fistula which are not suitable for the recent surgery treatment.

Bibliography

1. Koivusalo AI, et al. J Pediatr Surg.2015 Feb;50(2):250-4. 2. Piastra M, et al. Eur J Pediatr Surg. 2013,23 (2) 153–156.

The visual diagnosis of tuberculous pleurisy under medical thoracoscopy

Pier Aldo Canessa, Vanna Balestracci, Valentina Pinelli, Massimiliano Sivori

SC Pneumologia, ASL 5 La Spezia - Italy

Introduction

Tuberculous (TB) pleural effusion occurs in approximately 5% of patients with Mycobacterium tuberculosis infection. Thoracoscopy is the most accurate tool for establishing the diagnosis of TB pleurisy with a diagnostic accuracy of 100% on histology and 76% positivity on culture (1).

Objective

To investigate the feature of visual diagnosis in TB pleurisy via medical thoracoscopy, we performed a retrospective review of visual pattern of medical thoracoscopy in TB pleurisy.

Methods

A retrospective review was done of 765 patients (pts) who had medical thoracoscopy for pleural effusion from January 1, 2002 to November 30, 2015. We had 15 pts (8 M, 11 Italians, 45 mean age, range 16-77) with a TB Pleurisy diagnosis by histologic examination of tissue from the pleural biopsy (granulomatous inflammation and necrosis) with PCR biopsy positivity (2).

Results

The visual pleural findings were: A) 8 pts had diffuse white-pink miliary nodules, on hyperemic and soft thickened pleura (Fig 1); B) 5 pts had single or multiple pleural white - red nodules on hyperemic and soft thickened pleura; C) 2 pts had hyperemic, edematous and thickened pleura without nodules. Pleural adhesions or fibrotic septa and loculated effusion were present in 13/15.

Conclusions

We confirm TB Pleurisy presents a pauci-variety of scopic phenotypes under medical thoracoscopy. The experienced pulmonologist could visually be able to suspect TB pleurisy efficiently and directly via medical thoracoscopy.

Bibliography

1. Diacon AH et al. Eur Respir J 2003;22:589 2. Hasaneen NA et al. Chest 2003;124:2105–2111.

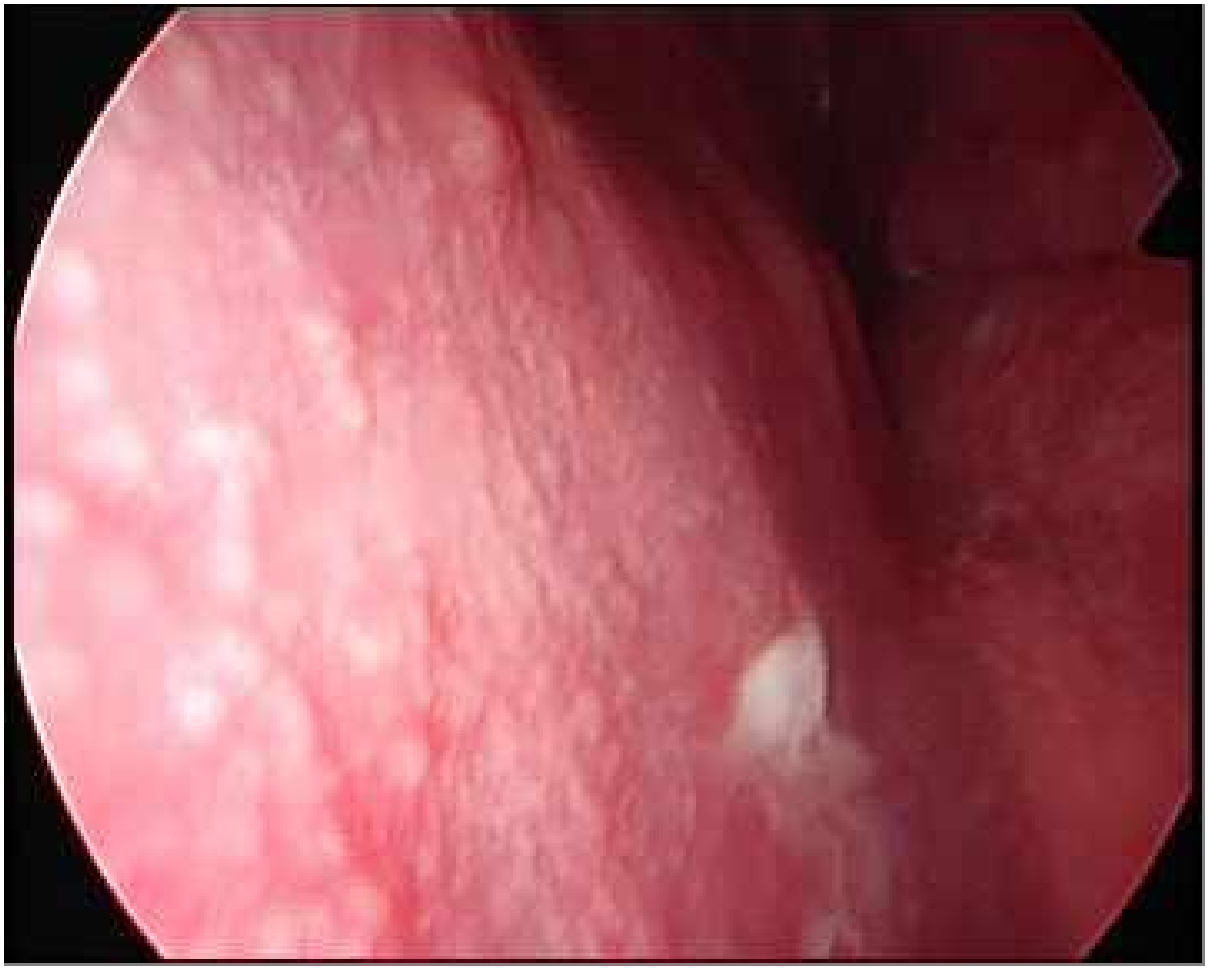

id 194

19th WCBIP / WCBE World Congress
JOINT MEETING OF THE WORLD ASSOCIATION FOR BRONCHOLOGY AND INTERVENTIONAL PULMONOLOGY & THE INTERNATIONAL BRONCHOESOPHAGOLOGICAL SOCIETY
www.wcbipwcbe2016.org
Fortezza da Basso
May 8-11, 2016
Florence (Italy)

Successful use of flexible bronchoscopic lung insufflation for pulmonary left lower lobe atelectasis

Carlo Luigi Cardini Md,phd[1], Sandro Casadei Md[1], Stefano Santoprete Md,phd[1], Moira Urbani Md,phd[1], Jacopo Vannucci Md[2], Mark Ragusa Md, Phd, Fccp[1]

[1]Thoracic Surgery Unit, Università degli Studi di Perugia - Azienda Ospedaliera S. Maria - Italy
[2]Thoracic Surgery Unit, Università degli Studi di Perugia - Italy

Introduction

Fiberoptic bronchoscopy is a commonplace procedure in thoracic surgery, pulmonology and intensive care units. Even though bronchial cleaning of retained secretions represents the most common daily indication, the procedure could be useful in clinical situations of persistent or recurrent lung atelectasis. This article presents a case of successful bronchoscopic insufflation resolving a persistent left lower lobe atelectasis in a road accident victim.

Methods

The patient was a 57-year-old smoker woman with no significant medical history who was referred to our Unit with a 2-week history of left lower lobe atelectasis following blunt chest trauma with multiple rib fractures, left pneumothorax and an uncomplicated fourth lumbar vertebral body fracture, suffered in car accident. Admitted to our department, a pleural tube was inserted. A Chest X-Ray performed after the procedure showed good expansion of the upper lobe with residual lower lobe atelectasis. Fiberoptic bronchoscopy revealed massive mucus obstruction of the trachea and main stem bronchi. The day after bronchial cleaning, a chest X-ray, showed persistent left lower lobe atelectasis and a second endoscopy revealed normal endoluminal findings. CPAP via mask therapy administered for half hour every 4 hours for 2 days was ineffective. For this reason, the patient underwent bronchoscopic lung insufflation. The treatment consisted in insufflation of pure oxygen at the dose of 4L/min, given through the operative channel of the instrument wedged into the left lower bronchus, in three cycles lasting for 2 minutes each. The procedure was repeated for three times, every other day, without complications resulting in the complete radiological re-expansion of the entire lobe. The patient was discharged six days later in good general conditions and free of respiratory symptoms. A thorax CT scan performed one month later showed no relapse of the condition with full left lower lobe recovery.

Conclusions

This case suggests that bronchoscopic lung insufflation in the adult can be a safe and effective procedure for treatment of persistent lobe atelectasis refractory to conventional endoscopic bronchial cleaning associated with CPAP therapy.

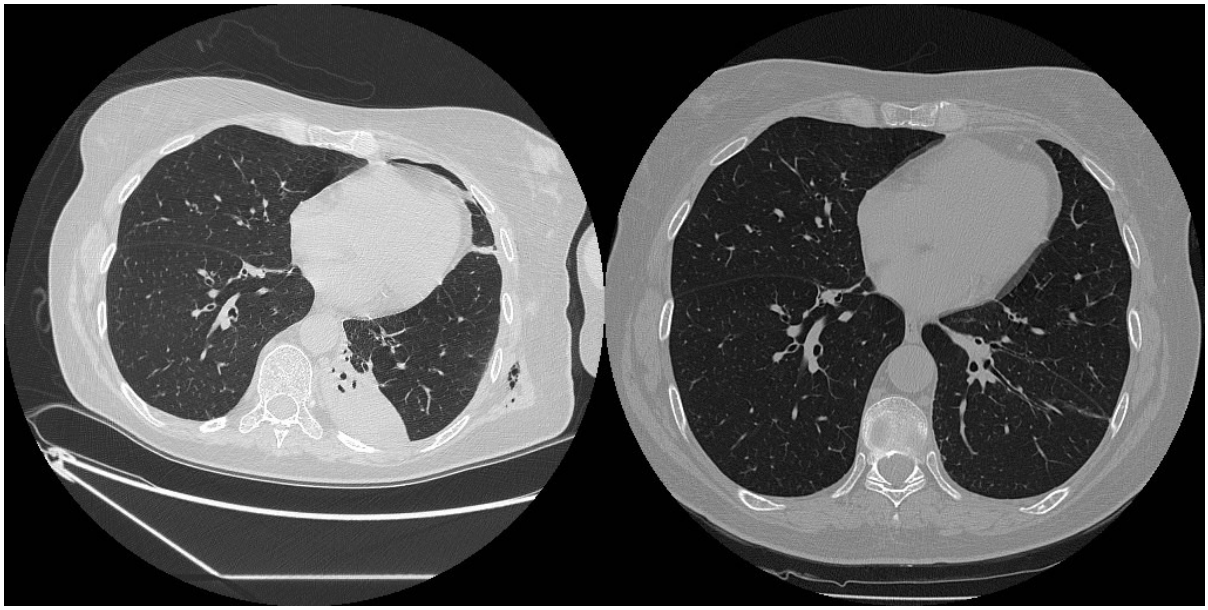

Combination of elastography with EBUS-TBNA in the diagnostic of intrathoracic lymphadenopathy

Potjanee Korrungruang[1], Viboon Boonsarngsuk[2]

[1]Medicine, Rajavithi Hospital, Rungsit University - Thailand
[2]Department of Medicine, Ramathibodi Hospital, Mahidol University - Thailand

Introduction
Novel technique of elastography ultrasound demonstrated tissue stiffness representing benign or malignant in nature.

Objective
To assess the accuracy of elastography ultrasound combined with endobronchial ultrasound- guided transbronchial needle aspiration (EBUS-TBNA) in the diagnosis of intrathoracic lymphadenopathy.

Methods
Multicenter, cross sectional study was conducted in the patients who were sent for evaluation of intrathoracic lymphadenopathy (LN). EBUS elastography classified lymph nodes in 3 types according to the overall color: type 1, predominantly non blue (yellow and green); type 2, part blue- part non blue; and type 3, predominantly blue. The elastographic findings were compared with etiologies of LN.

Results
There were 53 lymph nodes from 36 patients who underwent EBUS-TBNA. The size of lymph node was 16.6 ± 6.7 mm. The final diagnosis included 35 malignant lymph nodes (66%) and 18 benign lymph nodes (34%). The diagnostic yield of EBUS-TBNA was 77.4%. All of 12 type 1 LNs were proved to be benign diseases, while 33 of 37 type 3 LNs (89.2%) were finally diagnosed as malignancy. 4 LNs classified as type 2 were proved to be 2 benigns and 2 malignancies.

Conclusions
EBUS elastography is useful technique in real-time predicting benign or malignant in nature of the lymph nodes.

id 196

19th WCBIP / WCBE World Congress
JOINT MEETING OF THE WORLD ASSOCIATION FOR BRONCHOLOGY AND INTERVENTIONAL PULMONOLOGY & THE INTERNATIONAL BRONCHOESOPHAGOLOGICAL SOCIETY
www.wcbipwcbe2016.org
Fortezza da Basso
May 8-11, 2016
Florence (Italy)

Flexible laryngoscopy in exercise induced upper airway dysfunction

Jonas Yserbyt, Christophe Dooms, Lieven Dupont

Pulmonology, University Hospital Leuven - Belgium

Introduction

Exercise-induced vocal cord dysfunction is a paradoxical closure of the vocal cords during inspiration. Supraglottic and subglottic abnormalities may also occur during exercise. These events are probably underdiagnosed in athletes and often misdiagnosed as exercise-induced asthma. Upper airway abnormalities have a typical abrupt onset at peak exercise and resolve quickly with reduction of exercise intensity. Diagnosis is often clinically suspected but difficult to confirm.

Objective

To assess feasibility of flexible laryngoscopy during ergometry in elite athletes.

Methods

We performed flexible laryngoscopy during bicycle exercise using a 3.8mm flexible bronchoscope, taped to the nose to achieve image stability. Local anesthesia of the nasal cavity was applied (lidocain 1% solution & xylocaine 2% gel), without local anesthesia of the pharynx or vocal cords. For physical exercise, a cyclo-ergometer with a maximal resistance of 300 W was used. The incremental exercise test started at a resistance of 50 W with an increase of 50 W every 2 min at a cadence of 60 rpm and was performed under continuous heart rate and SpO2 monitoring.. A sprint (90-100 rpm) was performed at 300W if the maximum heart rate was not achieved after 12 minutes. The test was terminated after a cool down of 5 minutes.

Results

Four professional athletes and one Olympic athlete were subjected to flexible laryngoscopy during cyclo-ergometry. All subjects had unexplained symptoms of dyspnea at peak exercise. In three cases, dyspnea was accompanied by the production of an abnormal sound during respiration and in two cases soreness of the throat was reported. In all subjects FEV1 at rest was normal (range 96- 121% predicted). Two subjects were diagnosed with asthma and treated with inhaled steroids, in three subjects histamine provocation testing and exercise provocation was normal. In three subjects laryngoscopy showed abnormal findings at peak exercise, accompanied by abnormal sound at inspiration : 1 subject presented with paradoxical adduction of the vocal cords, 1 subject showed flapping of the arytenoids and aryepiglottic folds and in 1 subject supra-glottic collapse of the arytenoids towards the glottis was noticed. All three subjects reported reproduction of their symptoms at peak exercise.

Conclusions

Flexible laryngoscopy during ergometry enables the diagnosis of upper airway abnormalities during peak performance in highly trained athletes. Since competitive circumstances are difficult to reproduce in a hospital setting and because peak performance is highly dependent of the particular discipline, a negative test doesn’t preclude exercise-induced upper airway dysfunction.

id 197

19th WCBIP / WCBE World Congress
JOINT MEETING OF THE WORLD ASSOCIATION FOR BRONCHOLOGY AND INTERVENTIONAL PULMONOLOGY & THE INTERNATIONAL BRONCHOESOPHAGOLOGICAL SOCIETY
www.wcbipwcbe2016.org
Fortezza da Basso
May 8-11, 2016
Florence (Italy)

Preoperative photodynamic therapy and chemoradiotherapy for non-small-cell lung cancer

Fumi Suzuki[1], Masafumi Misawa[1], Hiroaki Nomori[2], Ryuta Tsuzuki[1], Satoshi Yamawaki[1], Ayumu Otsuki[1], Junko Watanabe[1], Masahiro Katsurada[1], Kei Nakashhima[1], Satoshi Noma[1], Hiroshi Sugimura[2], Masahiro Aoshima[1]

[1]Pulmonary Medicine, Kameda Medical Center - Japan
[2]Thoracic Surgery, Kameda Medical Center - Japan

Introduction

There has been no established strategy for non-small-cell lung cancer (NSCLC) with the endobronchial wall spread. Since photodynamic therapy (PDT) has been shown to be effective as neoadjuvant therapy which could lead to be less extended resection in some studies, we evaluated the efficacy of a combination of preoperative PDT and induction chemo-radiotherapy (ICRT) for NSCLC with endobronchial wall spread.

Methods

?Case 1?77 year old male. Squamous cell carcinoma of the left S3, cT1bN0M0 stage IA. Because of broad extension to the left upper lobe bronchus confirmed by auto fluorescence imaging (AFI) and cytological diagnosis, we performed the combined strategy. He was concurrently administered carboplatin + paclitaxel and thoracic radiotherapy (TRT) (40Gy). We irradiated PD-laser to the spur between left B3 and B4, and to the ventral region of the left upper lobe bronchus. PDT procedure was done using second-generation photosensitizer agent NPe-6 during ICRT. We used video-bronchoscope EB-530T and visualized PD-laser light clearly by adjusting FICE?Flexible Spectral Imaging Color Enhancement?mode. We irradiated 664 nm laser light at each dose of 100J/cm2 for 11 minutes and 6 seconds. 98 days after PDT, we operated the left upper sleeve lobectomy. There were no malignant cells in the surgical specimen (Ef.3) and fibrosis was only seen in the PDT irradiation part. His postoperative status was favorable without any surgical complication.?Case 2?80 year old male. Adenocarcinoma of the right S6, cT2aN1M0 stage IIA. Because of the extension to the membranous portion of the trunchus intermedius recognized by AFI, we also performed the combined strategy. He was administered carboplatin + paclitaxel and TRT (40Gy) concurrently. We circumferentially irradiated PD-laser to the right B6 lumen by an all-direction irradiation probe, and to the membranous portion of the trunchus intermedius by a direct irradiation probe. 64 days after PDT, we operated the right lower sleeve lobectomy. While ICRT had no effect on the primary tumor (Ef.0), PDT irradiation part was free from malignancy. Although he got radiation pneumonitis, he completely recovered following steroid administration.

Conclusions

It is possible to safely perform the neoadjuvant PDT and ICRT followed by surgery. PDT could prevent NSCLC spread to endobronchial wall and be effective for less extended resection. This is the first report of preoperative combined strategy of neoadjuvant PDT using NPe-6 and ICRT for NSCLC.

Bibliography

Ross P Jr, et al. Lasers in Surgery and Medicine 2006; 38(10):881-89 Akopov A, et al. Photodiagnosis Photodynamic Therapy 2014; 11(3):259-64

19th WCBIP / WCBE World Congress
JOINT MEETING OF THE WORLD ASSOCIATION FOR BRONCHOLOGY AND INTERVENTIONAL PULMONOLOGY & THE INTERNATIONAL BRONCHOESOPHAGOLOGICAL SOCIETY
www.wcbipwcbe2016.org
Fortezza da Basso
May 8-11, 2016
Florence (Italy)

One Airway Clinic: Why and How?

Katherine Conroy[1], Nirmal Kumar[2], Vikas Malik[1], Jennifer Gilchrist[2]

[1]Ear, Nose and Throat, Blackpool Teaching Hospitals NHS Foundation Trust - Uk
[2]Ear, Nose and Throat, Wigan, Wrightington and Leigh NHS Foundation Trust - Uk

Introduction

The Allergic Rhinitis and Impact on Asthma (ARIA) report in 2010 highlighted the similarities between nasal and bronchial inflammation in the context of "One Airway". Upper aero-digestive tract disorders (such as asthma, rhinitis, laryngopharyngeal reflux and unexplained cough) can have complex relationships and causes which are difficult to address in a single-specialty clinic. We believe a multidisciplinary approach can optimise disease management, improve patient experience and is economically viable. However, setting up a multidisciplinary 'One Airway Clinic' is logistically challenging.

Objective

We examine the numerous benefits of running a multidisciplinary 'One Airway Clinic' and discuss how potential obstacles can be overcome, using our experience in the North West of England.

Methods

. A literature search using terms [one airway] and [unified airway] - we noted that there were no descriptions of unified airway clinics in the literature . A survey of Otorhinolaryngology consultants in North West England assessing aspects of introducing One Airway clinics . An analysis of patient outcomes and satisfaction scores from an established 'One Airway Clinic'

Results

The links between different aerodigestive tract conditions and symptoms are well documented in the literature, making a strong case for multidisciplinary management of certain patients. All 12 teaching centres in the North West of England responded to our survey, with 100% of respondees feeling that introducing one airway clinics would benefit patients; 75% were considering or initiating this process. However, several barriers were identified including cost (67%) and finding an agreeable time slot (75%). In 2009 a One Airway clinic with an Otorhinolaryngologist, Respiratory physician, Specialist nurse, Speech and Language Therapist and one-stop allergy testing, flexible nasendoscopy and spirometry was established in Wigan to manage patients with: . Unexplained cough . Asthma . Rhinitis . Laryngopharyngeal Reflux The clinic was initially run as a pilot to demonstrate economic viability and improved outcomes, and to develop a referral protocol, before being expanded. Patient satisfaction scores were high, with 89% of patients stating they were "satisfied" or "highly satisfied" with their experience. In addition, the clinic proved to be an excellent platform for the use of novel treatments and research trials.

Conclusions

A One Airway clinic is difficult to set up, however despite the barriers we have identified there are many benefits in terms of patient outcomes and cost-effectiveness - demonstrated by the success of the clinic in Wigan. We hope to use this model to roll out further clinics in the North West of England.

19th WCBIP / WCBE World Congress
JOINT MEETING OF THE WORLD ASSOCIATION FOR BRONCHOLOGY AND INTERVENTIONAL PULMONOLOGY & THE INTERNATIONAL BRONCHOESOPHAGOLOGICAL SOCIETY
www.wcbipwcbe2016.org
Fortezza da Basso
May 8-11, 2016
Florence (Italy)

Usefulness of virtual bronchoscopic navigation for diagnosing ground glass opacity lesions

Shoji Tetsuaki Dr.[1], Naofumi Shinagawa Dr.[1], Yuta Takashima Dr.[1], Megumi Morimoto Dr.[1], Hajime Kikuchi Dr.[1], Yasuyuki Ikezawa Dr.[1], Taichi Takashina Dr.[1], Hidenori Mizugaki Dr.[1], Eiki Kikuchi Dr.[1], Junko Kikuchi Dr.[1], Jun Sakakibara-konishi Dr.[1], Satoshi Oizumi Dr.[1], Kosuke Nakano Dr.[2], Noriaki Sukoh Dr.[2], Masaharu Nisimura Dr.[1]

[1]First Department of Medicine, Hokkaido University School of Medicine - Japan
[2]Respiratory Department, National Hospital Organization Hokkaido Cancer Center - Japan

Introduction

?Background and Purpose?We and others have reported that transbronchial biopsy, using radial endobronchial ultrasonography (EBUS), under virtual bronchoscopic navigation (VBN) is an effective way for diagnosing small peripheral pulmonary lesions. Among them, ground glass opacity (GGO) lesions are often difficult to diagnosis because of invisibility under X-ray fluoroscopy. In this study, we focused only on such GGO predominant type lesions, and retrospectively analyzed the diagnostic yield for those lesions when using VBN, and finally compared the data with our historical data when we had not used VBN.

Methods

?Patients and Methods?Between May 2004 and September 2015 in Hokkaido University Hospital and Hokkaido Cancer Center, we performed transbronchial biopsy, using radial EBUS and VBN under X-ray fluoroscopic guidance, for a total of 169 GGO predominant type lesions. As navigation system, we used either Bf-NAVI® or DirectPath®.

Results

?Results?EBUS images could be obtained in 156 (92%) of 169 GGO predominant type lesions, among which 31 were pure GGO and 138 mixed GGO consisting of GGO components more than 50%. A total of 116 lesions (114 adenocarcinoma, 2 inflammation) could be diagnosed by biopsied specimen. The average size of lesions measured on computed tomography (CT) was significantly larger when diagnosis could be obtained compared with when it could not (22.0mm vs. 18.0mm; P<0.01). For the lesions where any bronchus is identified to get into the center of the lesions on CT, the diagnostic yield was significantly higher than those without such CT findings. (79% vs. 54%; P < 0.01) When we compared the data from our earlier study where we had used the same diagnostic procedure but without VBN, the EBUS probe reached to the target lesions far more frequently in this study (156/169 (92%) vs. 50/67 (75%); p<0.01), and the diagnostic yield was significantly highrt (116/169 (69%) vs. 38/67 (57%); p=0.041).

Conclusions

?Conclusion?The addition of VBN to radial EBUS could be a useful modality in clinical practice for diagnosing GGO predominant type lesions located at the peripheral lung.

id 200

An interesting foreign body removed via FOB: part of wood spoon in an epileptic patient

Mukremin Er[1], H.canan Hasanoglu[2], Aysegul Senturk[1]

[1]Pulmonary Diseases, Ataturk Training and Research Hospital - Turkey
[2]Pulmonary Diseases, Yildirim Beyazit University, School of Medicine - Turkey

Introduction

Tracheobronchial foreign body aspiration in adults is a rare situation. Foreign bodies usually remove via rigid bronchoscopy. We were presented a case unusual foreign body removed using with fiberoptic bronchoscopy (FOB).

Methods

A 38-years-old man admitted to pulmonary outpatient clinic with cough which sustained for 3 months. Although he was gone to several hospitals during 3 months for cough complaint, gave to him to cough reliever over and over antibiotics and anti-flu drugs. We removed a part of wood spoon from right main bronchus via FOB successfully. We were seen a granulation tissue on the place of removed foreign body. We learned from his medical history that he was an epilepsy patient and he get over seizure 3 months ago. His family have been put a wood spoon to sustain opened his mouth during epileptic seizure.

Conclusions

High clinical suspicion and inquiry is necessary for individuals who have chronic cough complaint. Family and friends of epilepsy patients must be warn for carefully choosing a device which put his mouth to sustain open during epileptic seizure. The removal of foreign bodies do not need rigid bronchoscopy unconditionally, also can be removed with fiberoptic bronchoscopy which more reliably and comfortably.

Bibliography

1-Sehgal IS, at al. Respir Care. 2015; 60(10):1438-48 2-Kam JC, et al. Case Reports in Medicine 2013; 2013:317104

id 201

Concordance between rapid on site evaluation and final diagnosis of EBUS samples

Rosa Cordovilla[1], Pablo Alvarez[2], Marco López Zubizarreta[2], Miguel Iglesias[2], Jorge Feito[3], Marta Rodríguez[3], Idania De Los Santos[2]

[1]Pulmonolgy, Salamanca University Hospital - Sapin
[2]Pulmonology, Salamanca University Hospital - Spain
[3]Pathology, Salamanca University Hospital - Spain

Introduction

The presence of a pathologist in the bronchoscopy suite (ROSE) for EBUS-TBNA has several advantages in EBUS procedures. Nevertheless, ROSE is time- consuming and is not available in every institution (1). However, the concordance with the final diagnosis is up to 89% (2) but the published series included benign and malignant diagnoses. In order to improve the cost- effectiveness of ROSE is important to better select the patients that truly need ROSE.

Objective

To analyze the concordance between ROSE and the final diagnosis in the samples obtained by EBUS for the diagnosis of hilar and mediastinal lymph nodes and for lung cancer staging.

Methods

We reviewed the cythopathologic reports of all EBUS performed from November 2012 to November 2015 in which ROSE was implemented. The Diff-Quick technique was used for ROSE, and it was classified as positive (malignant or benign pathology), negative (lymphocytes) or non-valid sample (lack of pathology or lymphocytes). The gold standard (GS) was mediastinoscopy or surgery. A descriptive analysis was performed: anatomic pathology of ROSE, EBUS and GS. Concordance was measured with Cohen's kappa coefficient (1960). The statistical package SPSS 20.0 was used for calculations.

Results

We included 192 patients: 84% men and 16% women. The final diagnosis after EBUS was: 72 cancer (37.5%), 96 reactive lymph nodes (50%), 12 granulomatosis (6.3%), 5 lymphomas (2.6%) and 2 tuberculosis (1%). ROSE detected 60 cases of cancer (83.3%), 4 granulomatosis (30.8%) and 89 reactive lymph nodes (92.7%). The overall concordance rate (CR) observed between ROSE and final EBUS results was 83.4%. Regarding different diagnoses, the CR for cancer was 85%, for sarcoidosis 25%, for lymphoma 60% and reactive lymph nodes 91.1%. There was no concordance in 21 patients in which ROSE demonstrated reactive lymph nodes while they were ultimately positive, and 2 patients who were classified as pathological by ROSE and who in fact had reactive lymph nodes. (Table 1) The Kappa index between ROSE and EBUS in all patients was 0.694 (p=0.000), for lung cancer 0.560 and for reactive lymph nodes 0.306. In all cases the index was significant. Kappa index was not significant for sarcoidosis, lymphoma and tuberculosis due to the low number of patients.

Conclusions

The concordance between ROSE and the final diagnosis in the samples obtained by EBUS is high, which proves the importance of ROSE during EBUS. This may not be the case for sarcoidosis, which shows lower concordance, which means that its presence is probably not indispensable in this disorder.

Bibliography

1. Van der Heijden E, Casal R, Trisolini R et al. Respiration 2014; 88: 88:500-17. 2. Trisolini R, Cancellieri A, Tinelli C et al. Chest 2001;139:395-401

Classification of patients according to ROSE and EBUS					
All patients		ROSE			Total
EBUS		Pathological	Inflammatory	Non valid	
	Pathological	66	21	4	91
	Inflammatory	2	89	5	96
	Non valid	0	0	5	5
Total		68	110	14	192

id 202

Endobronchial ultrasound-guided TBNA (EBUS-TBNA) with a 19 gauge needle - institutional experiences

Felix Jf Herth

Pneumology, Thoraxklinik - Germany

Introduction

A tissue diagnosis of mediastinal nodes is frequently needed for most mediastinal diseases. EBUS-TBNA allows real-time controlled tissue sampling of paratracheal, subcarinal and hilar lymph nodes. Until now, the needle size has been limited to 21 gauge.

Objective

We are reporting on the use of a 19g EBUS-TBNA needle

Methods

The Flex 19g EBUS-TBNA needle (Olympus Respiratory America, Redmond, USA) is compatible with Olympus EBUS scopes with a 2.2mm working channel. Patients with enlarged mediastinal and/or hilar nodes underwent an EBUS-TBNA. The 19 g needle was used as through the EBUS TBNA scope. The yield and the safety were analysed.

Results

20 patients (7f, 13m, mean age 57.6 y.) were examined. A total of 72 lesions were sampled. No complications occurred. The diagnostic yield was 90% (8x Adenocarccinoma, 2x SCLC, 2 squamous cell, 2 Lymphoma, 4 sarcoidosis). The mean procedure time was 7.4 minutes.

Conclusions

EBUS-TBNA with a Flex 19 g needle is feasible and safe. The diagnostic yield is high and may provide more material for the pathologist.

id 203

Validation of computed tomography post processing of thoracic imaging

Anastasios Palamidas[1], Mali Shen[2], Samuel Kemp[1], William Mcnulty[1], Guang -zhong Yang[2], Pallav Shah[1]

[1]The National Institute for Health Research Unit,, Royal Brompton & Harefield NHS Foundation Trust, and Imperial College, - Uk
[2]The Hamlyn Centre for Robotic Surgery, Imperial College - Uk

Introduction

New bronchoscopic interventions are evolving with an acceptable safety profile and improvement in quality of life indexes and pulmonary function for patients with advanced severe emphysema. These therapeutic approaches like lung volume reduction coils and valves are targeted at specific lobes. We have developed CT post processing software to determine densitometry and volumetry.

Objective

Our objective was to evaluate lobar and lung volumes after a semi automated interlobar fissure assessment and the emphysema destruction scores using automated densitometry Our aim was to validate this system to current industry standards.

Methods

We analysed 15 randomly selected patients HRCTs with advance COPD at full inspiration. Emphysema destruction scores for each lobe and the whole lung with density below -950 HU were computed automatically. Lobar and lung volumes after fissure marking were also measured semi automatically after splicing off the airways and the vessels. Mean values were obtained for all variables. Students t-test and Mann - Whitney rank sum test when needed applied for displaying the differences between the two post processing systems. Furthermore, we performed repeated meas-urements with individual scans to assess reproducibility of results.

Results

Both softwares analysed all patients HRCTs successfully. There were no significant differences in the lobar volumes or the whole lung volume measurements between the two softwares Table 1. There were no statistical significant differences in the emphysema destruction scores in every lobe or each lung separately between the softwares Table 1. The only limitation of the study was that the fissure analysis measuring the lobar volumes for every software has been performed by different operators. Repeated measurement on the same CT SCANS with our software provided consistent results.

Conclusions

Post processing with the software we have developed produces consistent and reliable measures of lobar lung volumes and emphysema severity.

Table 1. Measurements of lobar and lung volumes and emphysema destruction scores in 15 patients with advanced COPD.

N=15	VIDA SOFTWARE	OUR SOFTWARE	Δ	T test (P)
VOLUME LUL, ml	1968.0±554.5	2093±694.2	125.1±261.9	0,534
VOLUME LLL, ml	1520.0±731.9	1487.3±567.4	32.8±279.5	0,967
VOLUME RUL, ml	1847.6±598.8	1984.8±672.0	137.2±247.5	0,590
VOLUME RML, ml	484.9±366.5	516.9±346.9	31.9±86.1	0,772
VOLUME RLL, ml	1445.8±365.5	1537.8±427.3	91.9±191.9	0,531
EMPHYSEMA LUL, HU	49.0±7.6	51.1±7.5	2.1±0.9	0,448
EMPHYSEMA LLL, HU	35.1±12.9	36.6±12.2	1.5±3.1	0,507
EMPHYSEMA RUL, HU	48.3±5.3	50.1±5.2	1.8±1.4	0,362
EMPHYSEMA RML, HU	38.1±14.0	39.9±13.4	1.9±3.6	0,590
EMPHYSEMA RLL, HU	36.6±14.2	38.5±14.3	1.9±1.7	0,711

Values are mean ± SD unless otherwise specified. LUL: left upper lobe; LLL: left lower lobe; RUL: right upper lobe; RML: right middle lobe; RLL: right lower lobe; R: right; L: left; Emphysema: Emphysema destruction score; HU: Hounsfield Units; ml: millilitres; Δ: mean value of the measured differences.

19th WCBIP / WCBE World Congress
JOINT MEETING OF THE WORLD ASSOCIATION FOR BRONCHOLOGY AND INTERVENTIONAL PULMONOLOGY & THE INTERNATIONAL BRONCHOESOPHAGOLOGICAL SOCIETY
www.wcbipwcbe2016.org
Fortezza da Basso
May 8-11, 2016
Florence (Italy)

Improvement of hyperinflation and airway tethering after endobronchial coil treatment

Anastasios Palamidas[1], Mali Shen[2], Samuel Kemp[1], William Mcnulty[1], Zaid Zoumot[3], Guang -zhong Yang[2], Pallav Shah[1]

[1]The National Institute for Health Research Unit, Royal Brompton & Harefield NHS Foundation Trust, and Imperial College - Uk
[2]The Hamlyn Centre for Robotic Surgery, Imperial College - Uk
[3]Respiratory and Critical Care Institute, Cleveland Clinic Abu Dhabi - United Arab Emirates.

Introduction

Lung volume reduction coils is an emerging technique exhibiting a feasible safety profile with improvements in quality of life indexes, exercise capacity and pulmonary function. The basic principles responsible for that improvement remain unknown.

Objective

This is the first randomised study set to investigate putative mechanisms of action of endobronchial coils. To achieve that we tried to correlate lung function data with HRCT regional volumetric and densitometric studies.

Methods

We studied 36 patients with end stage emphysema (homogenous and heterogenous). The were randomised to bilateral coil placement (treatment, n=18) group and best medical care (control, n=18) group. Both groups underwent detailed lung function testing including body plethysmogra- phy and HRCT scanning at baseline and 3 months after the bilateral coil procedure. For the imaging studies we used a customised scientific software able to compute lobar volumes and emphysema destruction scores in a semi automated manner after lobar fissure marking and splicing off airways and vessels.

Results

The major findings of the study were that in the target lobes there were significant reductions in lobar volume and the emphysema destruction scores (p:0.05 and p<0.001respectively). The only predictor for these two changes was the FRC improvement after the coil intervention (p:0.003, p:0.0019 respectively). There were improvements in FEV1 and all the potential hyperinflation in- dexes, RV, RV/TLC, IC/TLC (p:0.05, p:0.001, p:0.04 respectively) Finally airway tethering im- proved as inspiratory conductance and expiratory resistance exhibited significant increase (p:0.022) and decrease (p:0.003) after the coil implantation.

Conclusions

Our findings suggest that endobronchial coils mediate a reduction in the volume and an improvement in the emphysema percentage of the targeted lobes by enhancing elastic recoil and airway tethering and thus counteracting hyperinflation and dynamic airway collapse.

id 205

EBUS-TBNA mediastinal lymph node staging in malignant pleural mesothelioma

Katarzyna Czarnecka-kujawa[1], Kazuhiro Yasufuku[2], Marc De Perrot[2]

[1]Thoracic Surgery, Respirology, University of Toronto - Canada
[2]Thoracic Surgery, University of Toronto - Canada

Introduction

Given poor survival of patients with malignant pleural mesothelioma (MPM) and extrapleural nodal metastasis, mediastinal lymph node (LN) staging with cervical mediastinoscopy (CM) has been advocated. Previous investigations suggest that Endobronchial Ultrasound-guided Transbronchial Needle Aspiration (EBUS-TBNA) may perform better than CM in detection of mediastinal metastasis in MPM (1).

Objective

To assess the performance of EBUS-TBNA for mediastinal LN staging in MPM.

Methods

Retrospective chart review of patients with confirmed diagnosis of MPM referred to the mesothelioma program at a tertiary Canadian cancer center between January 1, 2012 and December 31, 2014 who received mediastinal LN staging with EBUS-TBNA.

Results

48 patients were eligible for analysis. 81.3% of patients were male (39/48). Average age was 66.9y (range 48-84). Mesothelioma subtypes were as follows: epithelioid (70.8%), sarcomatoid (8.3%), biphasic (14.6%) and other (6.3%). Stage distribution (clinical in non-surgical and pathological in surgical patients) was as follows: I 18.8%, II 10.4%, III 47.9%, and IV 22.9%. On average 3.4 LNs were sampled per patient (range1-5).The mean short axis of biopsied LN was 6.8±3.8mm. The mean number of passes per LN was 2.6±1.1 (range: 1-9). Rapid On Site Evaluation was available in 75% (36/48) of the assessments. Prevalence of N2/N3 disease was 35.4% (17/48). Prevalence of N2 disease in LNs not accessible to EBUS-TBNA was 6.3% (3/48) (internal mammary and station 8 LNs). Including only the surgical patients, EBUS-TBNA sensitivity, specificity, positive predictive value (PPV), negative predictive value (NPV) and diagnostic accuracy for detection of metastatic LN disease were as follows: 14%, 100%, 100%, 62.5%, and 64.7%, respectively. EBUS-TBNA mediastinal LN staging prevented unnecessary hemithoracic radiation and EPP in 18.8% (9/48 patients) by discovery of N2/N3 disease (8 patients) and metastatic secondary malignancy (1 patient). There were no EBUS-TBNA related complications. PET-CT was performed in 72.9% of patients (35/48), 88.2% (15/17) of patients treated with EPP and 61.1% (11/18) patients with metastatic nodal disease. The sensitivity, specificity, PPV, NPV and diagnostic accuracy of PET-CT in detection of metastatic disease in MPM was 20%, 100%, 100%, 60% and 50%, respectively. Lymphadenopathy was present in 57.7% of the metastatic LNs.

Conclusions

EBUS-TBNA mediastinal LN staging has a potential to significantly impact management of patients with MPM by detecting mediastinal metastatic disease, therefore preventing morbidity and mortality associated with unnecessary surgical management in patients with non-surgical disease. It offers better diagnostic accuracy than PET-CT and it should be considered in pre-operative assessment of patients with MPM.

Bibliography

Rice DC, Steliga MA, Stewart J et al. Endoscopic Ultrasound-Guided Fine Needle Aspiration for Staging of Malignant Pleural Mesothelioma. Ann Thorac Surg 2009; 88:862-9.

19th WCBIP / WCBE World Congress
JOINT MEETING OF THE WORLD ASSOCIATION FOR BRONCHOLOGY AND INTERVENTIONAL PULMONOLOGY & THE INTERNATIONAL BRONCHOESOPHAGOLOGICAL SOCIETY
www.wcbipwcbe2016.org
Fortezza da Basso
May 8-11, 2016
Florence (Italy)

Palliative cryo surgery and argon plasma coagulation in central airway obstruction caused by cancer

Achmad Mulawarman Jayusman Md (pulmonologist), Eddy Soeratman Md (pulmonologist), Arif Riswahyudi Hanafi Md (pulmonologist), Muhamad Alfin Hanif Md (pulmonologist)

Pulmonology, National Cancer Center "Dharmais" Indonesia - Indonesia

Introduction

Central airway obstruction caused by lung cancer or metastatic lesion in the lung led to high morbidity and mortality in cancer patients. This obstruction must be removed to extend survival. Many methods used to remove this obstruction eg by cryo surgery, laser, argon plasma coagulation (APC) and others.

Objective

This study tried to get a patient's survival in patients who have done the cryo surgery in combination with APC in Indonesia.

Methods

We done cryo surgery and APC on cancer patients with central airway obstruction using fiberoptic bronchoscopy. Then we followed up patients until died.

Results

We have doing cryosurgery and APC in 35 patients from 2012 until 2015. Most of them were male (83%). The underlying disease that cause central airway obstruction were lung cancer (42.9%), laryngeal cancer (28.6%), thyroid cancer (14.3%), colon cancer (5.7%), tracheal cancer (2.8%), testicular cancer (2.8%), and vocal cord cancer (2.8%). Survival rate was 6 month, the longest survival was 12 month and the shortest survival was 2 days (caused of death was arrhythmia). There was no serious complication caused by the procedure except arrhythmia (2.8%).

Conclusions

Cryo surgery and Argon Plasma Coagulation (APC) is safe and can prolong survival at least for 6 months.

id 207

Analysis of new virtual bronchoscopic navigation system for diagnosing peripheral pulmonary lesions

Taichi Takashina Dr., Naofumi Shinagawa Dr, Yasuyuki Ikezawa Dr, Tetsuaki Shoji Dr, Yuta Takashima Dr, Megumi Morimoto Dr, Hajime Kikuchi Dr, Hidenori Mizugaki Dr, Eiki Kikuchi Dr, Junko Kikuchi Dr, Jun Sakakibara-konishi Dr, Satoshi Oizumi Dr, Masaharu Nishimura Dr

First Department of Medicine, Hokkaido University School of Medicine - Japan

Introduction

Several studies previously reported the usefulness of Virtual bronchoscopic navigation (VBN) for diagnosing peripheral pulmonary lesions (PPLs). Recently, DirectPath® (Cabernet System Inc., Tokyo, Japan), which is a new system exclusive to VBN and has some new functions, have been sold in Japan. DirectPath® can show the virtual X-ray fluoroscopic image, which is linked with changes in the direction of the bronchial tree. Therefore, it is expected to guide the bronchoscopy to the invisible lesion on X-ray more accurately.

Objective

In this study, we retrospectively evaluated the diagnostic yield of PPLs by endobronchial ultrasonography with a guide sheath (EBUS-GS) with DirectPath® and analyzed factors which might influence the diagnostic yield.

Methods

Between January 2014 and December 2014, we performed transbronchial biopsy (TBB) using DirectPath with EBUS-GS under X-ray fluoroscopic guidance for a total of 118 PPLs in Hokkaido University Hospital.

Results

118 PPLs were consist of 99 solid lesions and 19 ground glass nodule lesions. The median size of lesions was 24mm (range: 9-71mm). DirectPath® could automatically construct VB images up to the median 5th-generation bronchus (range; 3rd-8th). To increase the navigation accuracy, the median first-generation bronchus (range; zero- third) was additionally extracted manually. In 109 (92%) of 118 PPLs, EBUS images (within or adjacent) could be obtained. 76 (64%) PPLs were diagnosed by TBB using EBUS-GS with DirectPath® (65 primary lung cancers, 3 metastatic cancers, 4 nontuberculous mycobacterium infections, 2 aspergillosis, and 2 organized pneumonias). 68 (65%) PPLs of 105 PPLs suspected for malignancy and 8 (57%) PPLs of 14 PPLs suspected for benign before TBB could be diagnosed.

Conclusions

The new navigations system can guide a bronchoscope accurately to PPLs. DirectPath® is a promising tool for diagnosing PPLs.

id 208

Bronchial thermoplasty: a real life experience on twenty severe asthma patients

Nicola Cosimo Facciolongo[1], Sofia Taddei[1], Carla Galeone[1], Maria Teresa Bonini[1], Francesco Menzella[1], Roberto Piro[1], Luigi Zucchi[1], Mirco Lusuardi[2]

[1]Department of Cardiology, Thoracic and Vascular Surgery and Critical Care Medicine, Azienda Ospedaliera ASMN, Istituto di Ricovero e Cura a Carattere Scientifico - Italy
[2]Respiratory Rehabilitation, AUSL Reggio Emilia, S. Sebastiano Hospital - Italy

Introduction
Bronchial thermoplasty (BT) is a new non pharmacological treatment for severe asthma resulting in a reduction in airway smooth muscle mass. BT could be a further strategy to control asthma symptoms in selected patients.

Objective
The main objective was to evaluate quality of life in subjects undergoing BT, secondary objective was BT efficacy measured as reduction in rate of exacerbations, number of hospitalizations, and oral corticosteroid (OCS) therapy.

Methods
We enrolled 20 patients with severe asthma (defined according to GINA guidelines) who underwent BT performed as per standard procedure. Data were collected about Asthma Quality of Life Questionnaire (AQLQ) score and Asthma Control Questionnaire (ACQ) score with questionnaires administered at baseline (T0, data of the 12 months prior to BT) and at 3 (T3), 6 (T6) and 12 (T12) months after BT. Secondary outcomes, i.e. rate of asthma exacerbations, number of hospitalizations and changes in OCS dose were also evaluated during T0 to T12 follow up visits.

Results
Thirteen patients completed the follow up at T12, 4 patients at T6, 1 at T3 while 2 patients are still on follow up. Data showed a statistically significant improvement of AQLQ and ACT scores at 3 months ($p<0.05$) persisting after 6 and 12 months as compared to baseline. In particular, baseline AQLQ mean score was 2.69±0,92, while at T12 AQLQ was 5.71±0.74. ACT mean score was 23.36±1.06 at baseline, 6.55±1.24 at T12. A significant reduction in the rate of exacerbations ($p<0.05$) was observed since T3 to T12. In detail, the rate of exacerbations was 5.54±2.67 at baseline, declining to 1.00±1.29 at T12. Despite a low number of patients reporting hospitalizations at baseline, we found a statistically significant decrease in the number of hospital admissions ($p=0.047$). Only 2 patients needed hospitalization during the follow up period. Eleven among 13 patients used OCS at baseline, 4 of them stopped OCS after BT, 4 continued with half dose, and 3 did not modify therapy. The mean dose of OCS (prednisone or equivalent) was reduced from 23.6±11.5 mg at baseline to 11.5±14.6 at T12.

Conclusions
Our study shows that bronchial thermoplasty can improve quality of life in selected patients with severe asthma and reduce exacerbation rate, hospitalizations and regular use of oral corticosteroid.

		baseline		T-12		
		No. 20	100,0%	No. 13	65,0%	P value
Sex	Male	11	55,0	5	45,5%	
	Female	9	45,0	8	88,9%	
Age (years);	means ± SD	53,65±10,04		56 ± 10		
AQLQ*	score means ± SD	2,69±0,92		5,71±0,74		
ACT*	score means ± SD	23,36±1,06		6,55±1,24		
exacerbations	means ± SD	5,54±2,67		1,00±1,29		p<0,05 [1]
hospitalizations**	means ± SD	1,20±1,77 (0-6)		0,21±0,58 (0-2)		p=0,047 [1]
OCS dose (prednisone	means ± SD	23,56±11,46		11,54±14,62		p<0,05 [1]

* 11 patients completed T-12 F.U; ** low value at baseline;

[1] Student's t-test

id 209

Flexible bronchoscopy-induced massive bleeding: a 12-year multicentre retrospective cohort study

Qiang Li

Department of Respiratory Medicine, Changhai Hospital, Second Military Medical University - China

Introduction

Although massive bleeding is the most life-threatening complication caused by flexible bronchoscopy, data on flexible bronchoscopy-induced massive bleeding are scarce, and the associated clinical characteristics and prognostic factors are unknown.

Objective

To explore the incidence, mortality, and treatment of, as well as prognostic factors for flexible bronchoscopy-induced massive bleeding.

Methods

This was a multicentre, retrospective cohort study of all patients who underwent flexible bronchoscopy in thirty-three tertiary hospitals from January 2001 to June 2013. The clinical characteristics and outcomes were collected and analysed.

Results

A total of 194 patients with massive bleeding were identified among 520,343 patients who underwent flexible bronchoscopy. The average blood loss reached up to 378 ml. The overall incidence and mortality were 0.037% and 0.004%, respectively, and the overall fatality was 10.8%. The risk of massive bleeding induced by therapeutic bronchoscopies was significantly higher than that induced by diagnostic bronchoscopies (incidence: 0.059% vs. 0.031%, P<0.001; mortality: 0.012% vs. 0.003%, P<0.001; fatality: 20% vs. 8.4%, P=0.068). Multivariate analysis showed that age>=65 years, tracheal bleeding, blood loss>=500 ml, and occurrence of shock were independent factors predicting poor outcome, while emergency surgery was an independent protective factor. Re- bleeding occurred in six patients, resulting in three deaths within a month.

Conclusions

Flexible bronchoscopy-induced massive bleeding is rare but life-threatening. Age, bleeding location, bleeding volume, circulation condition, and emergency surgery were independent prognostic factors.

id 210

19th WCBIP / WCBE World Congress
JOINT MEETING OF THE WORLD ASSOCIATION FOR BRONCHOLOGY AND INTERVENTIONAL PULMONOLOGY & THE INTERNATIONAL BRONCHOESOPHAGOLOGICAL SOCIETY
www.wcbipwcbe2016.org
Fortezza da Basso
May 8-11, 2016
Florence (Italy)

The major complications of rigid bronchoscopy

Hong Zhang, Guangfa Wang, Wei Zhang, Nan Li, Yuhong Gong

Department of Respiratory and Critical Care Medicine, Peking University First Hospital - China

Introduction

Rigid bronchoscopy is a useful instrument for therapeutic purpose. It is unfamiliar to physicians and its application is impeded by the concern of safety.

Methods

We retrospectively reviewed all rigid bronchoscopy procedures accomplished in Peking university first hospital through Dec 2008 to Dec 2015. All procedures were carried out under general anesthesia. Manual jet ventilation was used to control patient's breath during the operation. Therapeutic procedures such as laser, cryotherapy, balloon dilation and stent implantation/removing were done under rigid bronchoscope. Laryngeal mask was intubated after removing rigid bronchoscope when the patient did not fully recover after the procedure.

Results

328 rigid bronchoscopy were accomplished in 211 patients, aged 9~85 (median 59), 64% were male. 131 patients had malignant diseases: 92 patients with lung cancer and 39 patients with other malignant diseases. 80 patients had benign disease, including tracheal stenosis after intubation/tracheotomy, anastomotic stenosis, sequelae of bronchial tuberculosis and miscellaneous. 54 procedures experienced complications. The complication rate was 16.5%. There was no procedure-related death. Hypoxemia is one of the major complications. 63 cases had respiratory failure, while 9 patients was intubated before rigid bronchoscopy. All patients on mechanical ventilation exchanged ETT to rigid bronchoscope smoothly without sustained hypoxemia. Difficult intubation was related to history of neck surgery/radiotherapy and laryngeal anatomical structure and led to severe hypoxemia. Despite of the severity of underlying disease, hypoxemia during the procedure did not significant or sustained. 22 patients experienced hypoxemia following the operation due to laryngeal edema, uncompleted recovery from general anesthesia and poorly underlying lung function. 20 cases occurred in operating room and 2 cases occurred back to the ward. 18 patients were re- intubated. More than 50ml bleeding was noted in 17 cases. Only one patient with broncholithiasis halted the procedure. Pneumothorax/subcutaneous emphysema developed in 5 patients. 2 of them needed drainage. 11% complications developed before the procedure, 48% occurred during and 41% happened after the procedure. All major complications were listed in Table and arranged from common to rear.

Conclusions

Rigid bronchoscopy had higher incidence of complication than diagnostic flexible bronchoscopy (0.08%-1.08%), since it was used in high-risk patients and dealt with difficult airway. Operators have to pay extra attention to patients waking from the general anesthesia or removing the bronchoscope/laryngeal mask.

Complication	case	%
Hypoxemia	**28**	**8.5**
Hypoxemia following procedure	19	5.8
Hypoxemia during procedure	5	1.5
Bleeding (>50ml)	**17**	**5.2**
Pneumothorax/Subcutaneous emphysema	**5**	**1.5**
Difficult intubation	**4**	**1.2**
Cardiovascular events	**3**	**0.9**
Loose teeth	**2**	**0.6**

Temporarily placement of metallic stent could lead to long-term benefits for benign tracheobronchial

Qiang Li

Department of Respiratory Medicine, Changhai Hospital, Second Military Medical University. - P.r.china

Introduction

The permanent placement of metallic stent for benign tracheobronchial stenosis (BTS) was controversial.

Objective

This study was conducted to evaluate the long-term outcomes of temporary placement of metallic stent for BTS.

Methods

The BTS patients who received temporary placement of retrievable self-expanded metallic stents were included between 2008 and 2011. Pre-stenting and follow-up respiratory status was analyzed. And symptom recurrence-free survival (SRFS) was assessed.

Results

A total of 49 stents were successfully temporarily placed in 40 consecutive BTS patients whose etiologies included endobronchial tuberculosis (EBTB) (n=22), post-tracheostomy stenosis (n=10), post-intubation stenosis (n=6) and post radiotherapy stricture (n=2). All stents were removed integrally after a median 18 days' stenting period, without major complications. During the median 27 months follow-up period after stent removal, a total of 22 patients were free of recurrence. And the overall 3-year SRFS rate was 52.0%. According to the etiology, the 3-year SRFS rates were 59.1% and 42.9% in the patients with EBTB and non-EBTB, respectively. Compared with pre-stenting, the follow- up internal diameter of stricture, Hugh-Jones scale, 6MWT and FEV1% were significantly improved. Multivariate analysis suggested that granulation tissue growth and tracheobronchial malacia might be independent factors of poor prognosis.

Conclusions

Temporary placement of retrievable metallic stent may be an alternative treatment for BTS patients.

id 211

Detection of Lung Cancer Specific Volatile Organic Compounds during Bronchoscopy

Mariko Okamoto[1], Carolin Drees[2], Ayano Usuba[1], Masao Takemura[1], Hiroshi Handa[1], Takeo Inoue[1], Teruomi Miyazawa[1], Masamichi Mineshita[1]

[1]Division of Respiratory Medicine, Department of Internal Medicine, St. Marianna University School of Medicine - Japan
[2]Biomedical Sciences, Reutlingen University - Germany

Introduction

Currently, there are no established guidelines for lung cancer screening; therefore, lung cancer is usually diagnosed at a later stage which renders successful therapy more difficult. There is evidence that lung cancer cells present a different metabolism in comparison with healthy lung cells, and this might produce unique types of volatile organic compounds (VOCs). Therefore, current research approaches have focused on analyses of VOCs from exhaled breath to find potential biomarkers for the early diagnosis of lung cancer.

Objective

The aim of this study is to confirm the carcinogenic origin of specific VOCs in the exhaled breath of lung cancer patients as a potential biomarker.

Methods

To measure VOCs, an Ion Mobility Spectrometry coupled to a multi capillary column (MCC/IMS) was used. The MCC/IMS is a rapid analytical method which provides real-time analysis for VOCs, e.g. in exhaled breath. For this study, breath samples through a PTFE tube directly above the cancer tissue in lung cancer patients were collected during bronchoscopy. To detect the correlation of potential lung cancer VOCs, the obtained measurements from bronchoscopy were compared with the exhaled breath measurements previously collected from each patient.

Results

Thirteen lung cancer patients (7 adenosquamous carcinoma, 1 small-cell carcinoma, 3 squamous cell carcinoma, 2 unknown carcinoma), were included in this study. For collected bronchoscopy air 51 VOC peaks were found and analyzed. After excluding potential contaminations such as, ambient air and medications, we detected 7 promising peaks. These peaks presented a significantly higher intensity for the bronchoscopic air samples with a confidence level of 95% after Bonferroni correction, than in ambient air. Furthermore, several of these 7 peaks were detected in exhaled breath with lower intensity. Consequently, these peaks could be associated with the metabolic origin of the surrounding tissue. One of the 7 peaks was identified as 2,2,4,6,6-Pentamethylheptane. Especially 2,2,4,6,6- Pentamethylheptane is auspicious because it was found in previous lung cancer studies as a cancer-specific VOC.

Conclusions

At present, this is an ongoing study and the next steps will be to compare these result with a healthy control group to confirm the carcinogenic origin of the detected VOCs, and the identification of the remaining 6 peaks. Currently 2,2,4,6,6-Pentamethyheptane is a highly promising intermediate result.

id 212

The importance of bronchoscopy in the rational management of the endobronchial lung cancer in 512 cases

Antonino Scaramozzino, Giuseppe Barracato, Valeria Micalizi, Marco Umberto Scaramozzino

U.O. Pneumologia, Policlinico Reggio Calabria - Italia

Introduction

Due the growing diffusion of risk factors over the last century, prevalence, incidence and mortality of lung tumors have globally increased. Approximately one third of lung cancer cases is complicated by endoluminal growth, resulting in poor prognosis and hugely impaired quality of life. Moreover, endobronchial lesions might be expression of metastatic involvement from distant sites.

Objective

We aimed to assess the role of bronchoscopy for management of endobronchial tumors, in terms of diagnosis, extent evaluation, and local treatments.

Methods

We retrospectively reviewed patients admitted to our pulmonary division who underwent complete diagnostic work-up for endobronchial cancer assessment, including clinical, serological, radiological tests and bronchoscopy.

Results

Overall, 512 patients, aged between 46 and 80 years, were included in the present study. Histological diagnoses were squamous (209), adenocarcinoma (105), spinocell (81), small cell (42), large cell (29), metastases (27), mixed adeno-squamous (13), benign tumors (4), teratoma (2).

Conclusions

Our results confirmed the relevant role of bronchoscopy in the management of endobronchial tumors, as it led to a proper diagnosis and staging, essential to assess the best therapeutic strategy.

id 214

Difficult Tracheal Intubation: A retrospective analysis

João Carvalho[1], Bruno Von Amann[1], Paula Monteiro[1], José Gonçalves[1], Cristina Bárbara[2]

[1]Unit of Pulmonary Intervention, Hospital Santa Maria, Centro Hospitalar Lisboa Norte - Portugal
[2]Director of Pneumology Department, Hospital Santa Maria, Centro Hospitalar Lisboa Norte - Portugal

Introduction

According to the American Society of Anesthesiologist, difficult airway is the clinical situation in which a conventionally trained anesthesiologist experiences difficulty with facemask ventilation of the upper airway, difficulty with tracheal intubation, or both. In agreement with the same society, difficult endotracheal intubation occurs when proper insertion of the tracheal tube with conventional laryngoscopy requires more than three attempts or more than 10 minutes.

Objective

Description of tracheal intubations that required support of the bronchofiberscope (BF).

Methods

Restrospective analysis (2011-2014) of a group of patients intubated with the support of the BF, due to difficult airway. Interventions were only performed by trained professionals from Unit of Pulmonary Intervention of Hospital Santa Maria.

Results

Our professionals were called to perform BF intubation in 314 patients, which 66.6% were males and 33.4% were females. The mean age 47.3 (min 7 months and max 89 years). The Units which requested support more often were the General Surgery (16.2%), Emergency room (15.9%), Orthopedy (15.3%), Plastic Surgery (11.1%), Cardio-thoracic Surgery (8.3%) and Othorhinolaryngology (8.3%). The main associated pathologies were cervical spine pathology (24.5%), oropharyngeal dismorphy (10.1%) and goiter (4.5%). Verification of double lumen orotraqueal placement was performed in 8.6%. However, in 36.6% of the situations, the main pathology remains unknown. The most used technique was oral intubation (80.2%), whereas nasal intubation was performed in 16.4%. However, the BF intubation was not necessary in 13.4% of patients and intubation was not possible in three patients due to complications.

Conclusions

BF facilitated intubation is one of the most commonly described alternative techniques employed in difficult tracheal intubation. In clinical situations of difficult airway, BF intubation is a valid and secure technique, usually with no complications. Observational studies report successful BF intubation in 87-100% of difficult airway patients.

Bibliography

Practice Guidelines for Management of the Difficult Airway An Updated Report by the American Society of Anesthesiologists Task Force on Management of the Difficult Airway

id 215

One year follow-up after EBV treatment in patients with emphysema without collateral ventilation

Karin Klooster, Jorine E. Hartman, Nick H.T. ten Hacken, Dirk-Jan Slebos

Department of Pulmonary Diseases, University of Groningen, University Medical Center Groningen - The Netherlands

Introduction

The recently published study ‘Endobronchial valves for emphysema without interlobar collateral ventilation’ (STELVIO trial)(1)showed that the endobronchial valve treatment is clinically effective at 6 months after treatment. However, the benefits of this specific treatment approach in the long term are not known.

Objective

The aim of this study is to investigate the safety and effectiveness at one year follow-up.

Methods

Patients with severe emphysema and a confirmed absence of interlobar collateral ventilation measured with the Chartis system who were previously treated with one-way endobronchial valves (PulmonX, USA) in the ‘Stelvio trial’ (1) were invited for a voluntary visit one year after treatment. Efficacy was evaluated by pulmonary function testing, 6-minutes walking distance (6MWD) test and the St. George's Respiratory Questionnaire(SGRQ).

Results

Sixty-four patients received the endobronchial valve treatment. The endobronchial valves were retained in 50 patients (78%) throughout the 1 year study period. At 1 year, 40 patients (26 female), mean age 59±8 years, FEV1 0.86±0.29L, residual volume (RV) 4.56±1.00L, 6MWD 367±78m and SGRQ score 56±13 points, visited the hospital. Significant improvements (all P<0.001) in the outcome measures from baseline to 1 year follow-up were found for FEV1 +17% (95% CI, 11 to 24), RV -687 ml (95% CI, -918 to -456), 6MWD +61 m (95% CI, 42 to 80), and the SGRQ score -11 points (95% CI,?17 to ?6), see figure for minimal clinically important differences and responder rates. Of all treated patients (N=64) at 1 year 2 (3%) deaths were observed. Causes of death were respiratory failure (58 days post treatment), and myocardial infarction (313 days post treatment). Nine COPD exacerbations and 5 pneumonia’s which required hospitalization were reported. Serious treatment related adverse events included pneumothorax (in 22% of all treated patients; all before 6 month FU)(1) and events requiring valve replacement (in 23% of all treated patients) or permanent valve removal (in 17% of all treated patients).

Conclusions

At 1 year after endobronchial valve treatment, the pulmonary function, exercise capacity and quality of life were still significantly improved in patients with severe emphysema characterized by the absence of interlobar collateral ventilation. The changes from baseline measures exceeded the established minimal clinically important difference and with a good responder rate. No late pneumothoraces occurred. Repeat bronchoscopy can be needed to replace or temporarily or permanently remove endobronchial valves.

Bibliography

(1)1. Klooster K et al. Endobronchial Valves for Emphysema without Interlobar Collateral Ventilation. N Engl J Med 2015;373:2325-35.

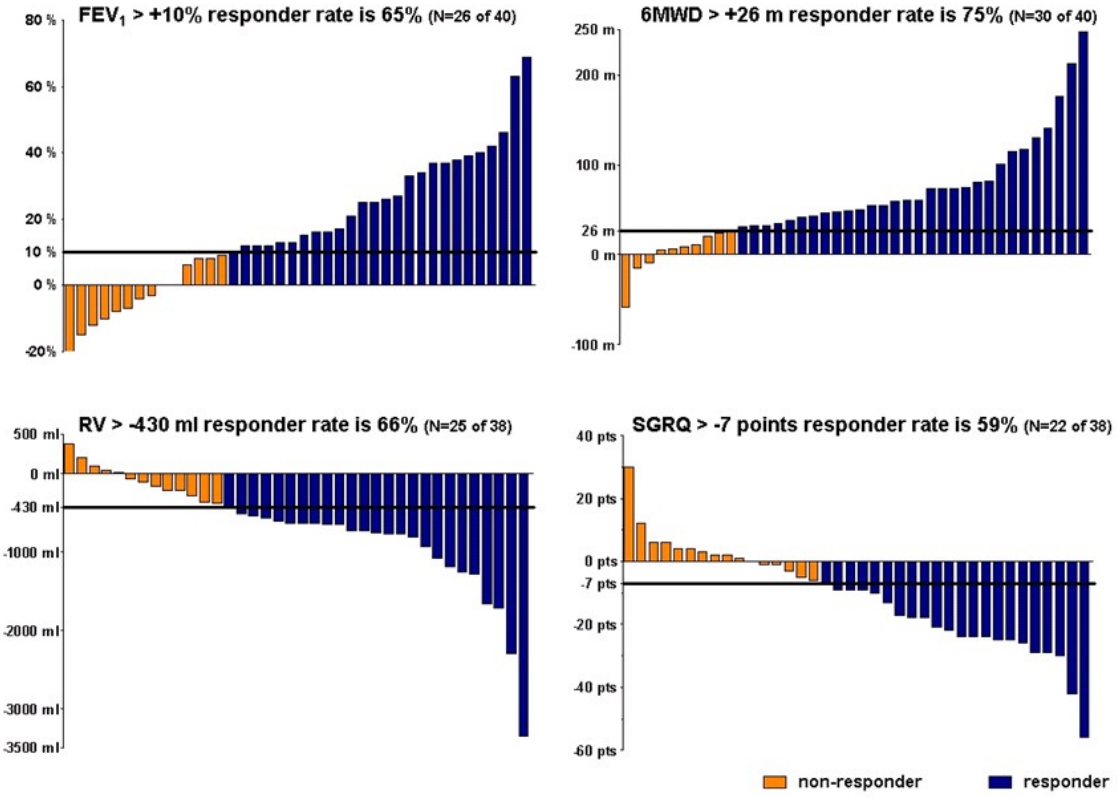

Legend to figure

One bar represents one patient. Orange colored bars represents the patients who did not reach the minimal clinically important difference. Blue colored bars represents the patients who did reach the minimal clinically important difference. FEV_1: forced expiratory flow in 1-second; 6MWD: 6 minute walk test distance; SGRQ: St. George's Respiratory Questionnaire.

The presenting author has the following conflicts of interest that relate to this abstract: *Karin Klooster reports receiving lecture fees from Pulmonx and devices for treatments, travel support, and grant support from PneumRx/BTG and Pulmonx.*

id 216

19th WCBIP / WCBE World Congress
JOINT MEETING OF THE WORLD ASSOCIATION FOR BRONCHOLOGY AND INTERVENTIONAL PULMONOLOGY & THE INTERNATIONAL BRONCHOESOPHAGOLOGICAL SOCIETY
www.wcbipwcbe2016.org
Fortezza da Basso
May 8-11, 2016
Florence (Italy)

Mediastinal Cyst Presenting with Sub-acute Respiratory Failure due to Central Airway Obstruction

Wissam Jaber[1], David Lafon[2], Douglas Minnich[3]

[1]Interventional Pulmonary Medicine, Cancer Treatment Centers of America - Usa
[2]Pulmonary and Critical Care Medicine, University of Alabama at Birmingham - Usa
[3]Thoracic Surgery, University of Alabama at Birmingham - Usa

Introduction

The primordial lung bud arises from the ventral surface of the foregut at 3 to 4 weeks of gestation. The division into a ventral trachea and a posterior esophagus happens over the next 2 weeks. A variety of anatomic malformations of the bronchopulmonary tree can develop in the event of a ventral foregut budding abnormality. Bronchogenic cysts are among the most common malformations. Common intrathoracic locations include paratracheal, subcarinal, hilar and para-esophageal areas. The clinical presentation is variable from respiratory distress at birth to late appearance of symptoms or incidental finding. In adults, bronchogenic cysts are often asymptomatic at presentation.

Methods

A 43 year old female never smoker with DM, ESRD, and history of ‘asthma’ presents to ED with increasing dyspnea, wheezing, “chest congestion” and clear sputum production of 6 months duration that was gradually worsening. She had more than 10 hospital admissions this year with minimal improvement with nebs, steroids for presumed asthma exacerbations. In 2009, she was diagnosed with mediastinal mass. ROS positive for dysphagia for solids. CT scan of chest revealed a 9 cm mediastinal mass with compression of the body of the trachea. After discussion with ENT and thoracic surgery teams, we proceeded with EBUS bronchoscopy. Airway exam revealed mid tracheal narrowing of 50-75%. The distal trachea was significantly narrowed to 90%. The carina was compressed with a significant obstruction of the orifices and take off of the right and the left main stems. EBUS was used to define the mass that looked like a complex cyst. A 22 g needle was used to stick and suction. There was no fluid return. Rapid onsite evaluation by cytopathology team showed acellular debris and macrophages. No malignant cells were noted. A white gelatinous fluid started gushing from the needle stick site. The fluid was suctioned over 20 minutes. A repeat airway exam showed a significant relief in tracheal compression all over. Patient was next taken to OR for VATS excision of the cyst . She returned to MICU, extubated 2 days later, and continued to improve. Cultures from cyst contents grew Candida albicans. She was treated with fluconazole and did well. Discharged POD #12. Surgical pathology report showed Soft tissue, mediastinal cyst, excision:- Bronchogenic cyst with squamous metaplasia.

Conclusions

EBUS bronchoscopy is a useful diagnostic modality for evaluation of cystic mediastinal masses, and can be helpful in relieving central airway obstruction due to extrinsic compression in specific cases.

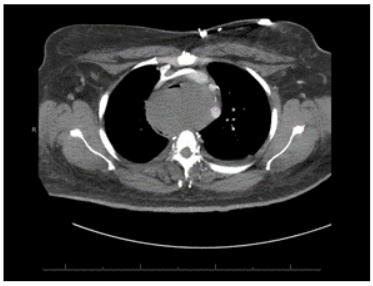

Mediastinal cyst

Proximal trachea

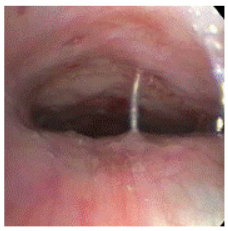

Mid-distal trachea

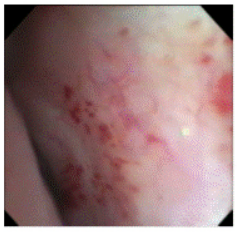

Carina

EBUS TBNA of cyst

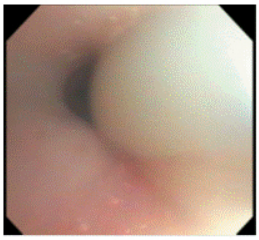

Milky fluid from cyst

Tracheal decompression

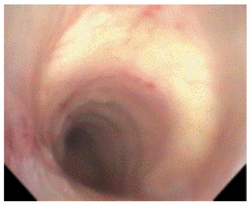

90% of normal lumen

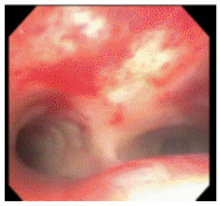

Carina post drainage

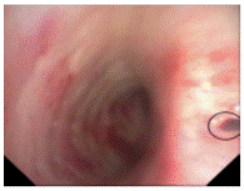

Needle tack

id 217

19th WCBIP / WCBE World Congress
JOINT MEETING OF THE WORLD ASSOCIATION FOR BRONCHOLOGY AND INTERVENTIONAL PULMONOLOGY & THE INTERNATIONAL BRONCHOESOPHAGOLOGICAL SOCIETY
www.wcbipwcbe2016.org
Fortezza da Basso
May 8-11, 2016
Florence (Italy)

Hand-sewn anastomosis of cervical esophagus and gastric tube under 2.5 times magnifier glass

Satoshi Yamamoto, Takahiro Sawada, Kenji Maki, Koji Mikami, Takahumi Maekawa

Department of Surgery, Fukuoka University Chikushi Hospital - Japan

Introduction

<Background> Anastomosis of cervical esophagus and gastric tube is the most careful method of subtotal esophagectomy for esophageal cancer. Recently, due to the technically development of the stapler, there are some good results of the stapled anastomosis. However, we consider hand-sewn anastomosis is still important skill and useful technique of esophagectomy for the esophageal cancer.

Methods

<Patients and Methods> Consecutive thirty esophageal cancer patients were performed subtotal esophagectomy with gastric tube reconstruction in 2013 to 2015. They are 26 male and four female, average age of all patients is 66±8 (51to84 year-old). The induction chemotherapy was performed for eight patients before operation. The method of subtotal esophagectomy in our institute is the following. Thoracic esophageal mobilization was performed in the thoracoscopically in the left lateral decubitus position. After that, the gastric tube was made under open laparotomy, and pull-through via posterior mediastinal route. After cervical lymph node dissection, cervical esophagus and gastric tube end to end anastomosis was performed by layer to layer with 4-0 absorbable monofilament suture under 2.5 times magnifier glass.

Results

<Results> The average of operating time was 449±83 minutes, and the average of blood loss was 369±575ml. There was no anastomotic leakage and stricture. There were pneumoniae in two patients, and chylothorax in one patient.

Conclusions

<Conclusions> We successfully performed the cervical esophagus and gastric tube anastomosis with hand-sewn under 2.5 times magnifier glass. Hand-sewn anastomosis is still important and basic technique.

id 218

19th WCBIP / WCBE World Congress
JOINT MEETING OF THE WORLD ASSOCIATION FOR BRONCHOLOGY AND INTERVENTIONAL PULMONOLOGY & THE INTERNATIONAL BRONCHOESOPHAGOLOGICAL SOCIETY
www.wcbipwcbe2016.org
Fortezza da Basso
May 8-11, 2016
Florence (Italy)

How safe and justified is invasive diagnostic of lung tumours in elderly patients?

Mateja Marc Malovrh, Katja Adamic, Maja Ferjan, Ales Rozman

Pulmology, University Clinic for respiratory and Allergic diseases Golnik - Slovenia

Introduction

With prolonged life expectancy increasingly more patients with the lung cancer are found in the age group of over 80 years old. These patients are more fragile because of co-morbidities and carry higher risk for invasive diagnostic procedures.

Objective

The main objective was to determine the safety of invasive diagnostic procedures for lung cancer in the octogenarians. The secondary objective was to determine whether these patients receive specific oncologic treatment after the diagnosis and whether they have benefit from it.

Methods

This retrospective study was done in the tertiary pulmonary centre in patients over 80 years old with diagnosis of lung cancer. Medical records and survival records were analysed and data extracted for the group of patients, diagnosed between January 2009 and December 2010.

Results

100 patients with age 80 years or more with lung cancer were included, which represented 7% of all patients with lung cancer in that time period. 74 patients had bronchoscopy, 12 CT guided transthoracic needle aspiration (CT- TTNA) and 14 other methods (thoracocenthesis, peripheral lymph node or metastasis fine needle aspiration). Complications after bronchoscopy were: moderate, prolonged bleeding after biopsy (n=1), pneumonia (n=1), cerebrovascular bleeding (n=1). Complications after CT-TTNA were: pneumothorax (n=1), pneumonia (n=1). Among 41 patients who were in stage I-III at the time of diagnosis 19 were treated with curative intent (3 surgery, 15 high dose radiotherapy, 1 radiofrequency ablation). Their median survival was significantly better (median 15, range 3-74 months) than survival in 22 non-radically treated patients from this group (median 5.5, range 0-84 months). 53 patients had stage IV disease at the time of diagnosis. 13 were treated with tyrosine kinase inhibitor (median survival 16, range 1-66 months), 8 with chemotherapy (median survival 6, range 0-16 months) and 32 received symptomatic treatment (median survival 3, range 0-30 months). A group of patients treated with TKI had statistically significant longer survival ($p<0.05$). In 6 patients the stage was not determined because of their low health status (WHO 4). Low PS, co-morbidities and decreased lung function mainly contributed to the decision for symptomatic treatment in 54% of the patients from the study.

Conclusions

Invasive diagnostic procedures are safe in octogenarians with lung cancer and have low complication rate. Patients can benefit from these procedures. However, invasive diagnostic procedures must be carried with all due precaution in these patients which are more fragile due to high rate of co- morbidities.

id 219

19th WCBIP / WCBE World Congress
JOINT MEETING OF THE WORLD ASSOCIATION FOR BRONCHOLOGY AND INTERVENTIONAL PULMONOLOGY & THE INTERNATIONAL BRONCHOESOPHAGOLOGICAL SOCIETY
www.wcbipwcbe2016.org
Fortezza da Basso
May 8-11, 2016
Florence (Italy)

EUS-B and the left adreal gland

Franz Stanzel, Ulrich Klein, Uta Wuelfing, Joern Brune

Interventional Pneumology, Lung Clinic Hemer - Germany

Introduction

In metastatic lung cancer, the left adrenal gland (LAG) plays a role as a predilection site for distant metastases. Esophageal endoscopic ultrasound (EUS) is one of the methods to obtain tissue from the LAG. Complete mediastinal nodal staging can be achieved by the combination of EBUS and EUS using a single EBUS scope by introducing it into the esophagus (EUS-B) following the endobronchial procedure. There is a debate, if the LAG can also be assessed with the EUS-B procedure, and if there can be taken biopsies.

Objective

The aim was to investigate the feasibility to detect the LAG with an EBUS scope and to get samples of the left adrenal gland by using the EBUS cytology needle.

Methods

We retrospectively analysed the reports of patients suspiciuos for non small cell or small cell lung cancer and LAG metastasis based on imaging (CT, PET-CT or MRT), who underwent EBUS and EUS-B using the EBUS scope for mediastinal staging and LAG assessment from 11/2014 to 12/2015. Additionally we analysed the pathology reports regarding the results of rapid on site evaluation (ROSE), the definitive cytology and histology of the samples taken.

Results

80 patients were included in the study. All underwent EBUS and EUS-B under general anesthesia. The EBUS scope was introduced in the airways through the rigid scope, and in the esophagus in supine position. In all patients the EBUS could be introduced into the esophagus. In 70 from 80 patients (87,5%), the LAG could be clearly visualised. In 10 patients, the LAG was not found because of poor contact between the tip of the scope and stomach wall or the fact, that the EUS-B was too short. In 20 from 70 patients the LAG appeared to be normal, in the others it was thicker or knotty. In 65 out of 70 patients sufficient material could be found in the samples. ROSE was suspicious for malignancy in 49 out of 70, definitively malignant by histology in 47 or cytology only in 3 patients (71,4%). A clear benign histologic finding could be achieved in 15 patients (21,4%). No complications occurred.

Conclusions

The EBUS scope in the EUS-B mode allows the visualisation of the LAG in the majority of patients. Also samples can be taken without complications through the gastric wall. There is a high success rate, even histologic sampling is possible without complications. This procedure should be included in the repertoire of every bronchoscopist carrying out EBUS.

id 220

19th WCBIP / WCBE World Congress
JOINT MEETING OF THE WORLD ASSOCIATION FOR BRONCHOLOGY AND INTERVENTIONAL PULMONOLOGY & THE INTERNATIONAL BRONCHOESOPHAGOLOGICAL SOCIETY
www.wcbipwcbe2016.org
Fortezza da Basso
May 8-11, 2016
Florence (Italy)

Radial endobronchial ultrasound with a guide sheath for peripheral cavitary lung lesions

Manabu Hayama, Norio Okamoto, Motohiro Tamiya, Takayuki Shiroyama, Hidekazu Suzuki, Ayako Tanaka, Takuji Nishida, Takashi Nishihara, Naoko Morishita, Tomonori Hirashima

Department of Thoracic Malignancy, Osaka Prefectural Medical Center for Respiratory and Allergic Diseases - Japan

Introduction

Endobronchial ultrasound with a guide sheath (EBUS-GS) has improved the diagnostic outcomes for peripheral pulmonary lesions; however, to our knowledge, reports on the use of EBUS-GS for cavitary lesions are unavailable.

Objective

This study aimed to assess the effectiveness and safety of EBUS-GS for the diagnosis of peripheral cavitary lung lesions.

Methods

This study was a single-institutional retrospective review of cases of peripheral cavitary lung lesions examined using EBUS-GS between July 2013 and October 2015. The diagnostic results of different EBUS-GS samples, including cytological, histopathological, and microbiological samples, were analysed separately.

Results

Of the 696 radial EBUS procedures performed during the study period, 50 EBUS-GS procedures were performed for the examination of peripheral cavitary lung lesions. The overall diagnostic yield of EBUS-GS was 78% (39/50). Regarding 27 malignant lesions, the diagnostic yields for cytological and histopathological samples were 63.0% (17/27) and 74.1% (20/27), respectively. Regarding 22 benign lesions, the diagnostic yields of histopathological and microbiological samples were 68.2% (15/22) and 50% (11/22), respectively. Univariate and multivariate analyses showed that the EBUS probe within was the only factor signi?cantly associated with increased diagnostic yield (odds ratio: 8.83, P = 0.013). Although pulmonary infection occurred after the procedure in the case of 1 patient (2.0%), no other complication, including pneumothorax and significant haemorrhage, was noted.

Conclusions

EBUS-GS was found to be effective and safe for the diagnosis of peripheral cavitary lung lesions.

id 221

19th WCBIP / WCBE World Congress
JOINT MEETING OF THE WORLD ASSOCIATION FOR BRONCHOLOGY AND INTERVENTIONAL PULMONOLOGY & THE INTERNATIONAL BRONCHOESOPHAGOLOGICAL SOCIETY
www.wcbipwcbe2016.org
Fortezza da Basso
May 8-11, 2016
Florence (Italy)

Bronchoscopic removal of a fractured metallic tracheostomy tube: a case report

Apichart So-ngern, Viboon Boonsarngsuk

Division of Pulmonary and Critical Care Medicine, Department of Medicine, Division of Pulmonary and Critical Care Medicine - Thailand

Introduction

Although tracheostomy is a well-accepted procedure for life support, some early and late complications may occur. Tracheostomy care and scheduled replacement are essential in order to reduce complications. Herein we report a rare occurrence of fractured metallic tracheostomy tube migrating into the tracheobronchial tree in an elderly patient.

Methods

A 65-year-old Thai man who had been bed-bound from hemorrhagic stroke for 18 months and required tracheostomy tube placement for managing secretions presented with fever and cough with purulent sputum for 4 days. His relatives also noted some difficulty in suction. A chest X-ray disclosed a metallic density of the fractured tracheostomy tube in his left main bronchus (Fig 1A). Rigid bronchoscopy was performed through the tracheostomy stoma under general anesthesia. The fractured tube was pull up by a balloon catheter and then removed through the stoma with the aid of an arterial clamp (Fig 1B).

Conclusions

We report a rare complication of metallic tracheostomy tube. Bronchoscopic removal of the fractured tube with a balloon catheter is feasible and less injured to the airway wall.

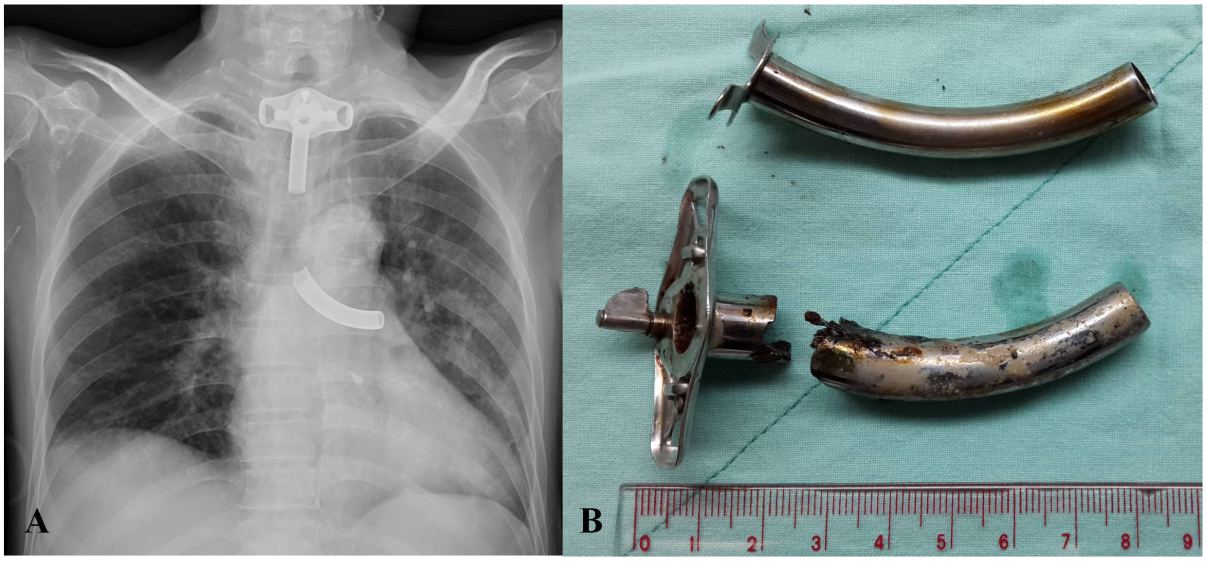

19th WCBIP / WCBE World Congress
JOINT MEETING OF THE WORLD ASSOCIATION FOR BRONCHOLOGY AND INTERVENTIONAL PULMONOLOGY & THE INTERNATIONAL BRONCHOESOPHAGOLOGICAL SOCIETY
www.wcbipwcbe2016.org
Fortezza da Basso
May 8-11, 2016
Florence (Italy)

Successful Electromagnetic Navigational Bronchoscopy Using Veran Thoracic Navigational System

Mohamed Faisal Abdul Hamid Faisal Abdul Hamid[1], Aziz Marwan Aziz[2], Andrea Ban Yu-lin Andrea[1], Tidi Maharani Hassan Tidi[1]

[1]Respiratory, Universiti Kebangsaan Malaysia Medical Centre - Malaysia
[2]Respiratory, Universiti Sains Islam Malaysia - Malaysia

Introduction

Bronchoscopy was first performed in 1897 and there have been many advances since. Electromagnetic navigational bronchoscopy (ENB) is among the latest technology in bronchoscopy allowing tissue sampling at the lung peripheries. With this technology, we have access to small, peripheral lung lesions which were previously accessible for biopsy only by computed tomography (CT) guidance or video assisted thoracoscopic surgery (VATS).

Methods

We report a 53-year-old man, a chronic smoker who presented with cough, dyspnea and loss of weight and appetite for one month. Chest radiograph revealed interstitial opacities in the right lower zone. On CT thorax, there were multiple peripheral lung nodules, the largest in the anterior segment of left lower lobe (LLL) measuring 3.2 x 2.2 cm and the right middle lobe measuring 1.8 x 1.9 cm. Flexible bronchoscopy showed no endobronchial lesions. We performed a transbronchial biopsy of these peripheral lesions with the help of the electromagnetic navigational bronchscopy system. The biopsy revealed small cell carcinoma of the lung.

Conclusions

This is one of the first few successful application of Veran medical thoracic navigational technology in Asia. ENB is safe, accurate and it can prevent unnecessary referral for VATS.

id 224

19th WCBIP / WCBE World Congress
JOINT MEETING OF THE WORLD ASSOCIATION FOR BRONCHOLOGY AND INTERVENTIONAL PULMONOLOGY & THE INTERNATIONAL BRONCHOESOPHAGOLOGICAL SOCIETY
www.wcbipwcbe2016.org
Fortezza da Basso
May 8-11, 2016
Florence (Italy)

Bronchoscopic Findings of Endobronchial Tuberculosis: 1,221 Cases Analysis

Yuanyuan Li, Yu Peng, Chengping Hu

Department of Respirology & Critical care medicine of Xiangya Hospital, Central South University - China

Introduction

The clinical manifestations and radiological fingdings of endobronchial tuberculosis are multifarious non-specific. In recent years, with the increasing amont of multi-drug resistant tuberculosis and abuse of hormones and antibiotics, there come to more non-spefic tuberculosis. It has been often misdiagnosed as lung cancer ,invasive pulmonary aspergillosis or viral pneumonia., hence preoperative diagnose is usually inaccurate. Diagnostic bronchoscopy can often achieve the diagnosis of endobronchial tuberculosis preoperatively and quickly.

Objective

To analyze the clinic characteristics and the flexible bronchoscopic findings of 1 221 cases of endobronchial tuberculosis, and try to find out some useful clues for the diagnosis of endobronchial tuberculosis.

Methods

The clinic characteristics and the bronchoscopic findings of 1 221 cases of endobronchial tuberculosis were summarized and analyzed.

Results

n the 1,221 cases of bronchial tuberculosis, there were 491 males and 730 females with mean age of 45. 5 ±16. 8 years(ranged between 6 and 84 years) . The peak incidence of endobronchial tuberculosis in females was between 20 and 50 years old, and in males was between 45 and 70 years old. The lesions were more common in the right lung (757 cases, 62. 00%) . The most susceptible segment involved was the right upper lobe(316 cases, 25. 88%) .The cases of left main bronchus tuberculosis (270 cases, 22. 11%) were more than right main bronchus tuberculosis (247 cases, 20. 23%) . The most common bronchoscopic appearances were oedematoushyperaemic and necrosis. The typical changes include caseous necrosis(117 cases, 14. 50%) , fibrostenotic (130 cases, 10. 65%) , and granuloma(92 cases, 7. 53%) , which often occurred in the left main bronchus. The most common endoscopic classification of endobronchial tuberculosis was type ?(531 cases, 43. 49%)and type ? (505 cases, 41. 36%) .

Conclusions

Bronchial tuberculosis occures in females more of ten than males. Female patients were mainly under the age of 50 years, while male patients was mainly above the age of 45 years. The most susceptible segments are the right upper lobe and the left main bronchus. The most common endoscopic classification is necrotizing ulcerative and granulation proliferative.

Bibliography

1. Xue Q, Wang N,Wang J. Eur J Clin Microbiol Infect Dis, 2011, 30 : 1039 -1044 2.Chung HS, Lee JH. Chest, 2000, 117 : 385-392.

19th WCBIP / WCBE World Congress
JOINT MEETING OF THE WORLD ASSOCIATION FOR BRONCHOLOGY AND INTERVENTIONAL PULMONOLOGY & THE INTERNATIONAL BRONCHOESOPHAGOLOGICAL SOCIETY
www.wcbipwcbe2016.org
Fortezza da Basso
May 8-11, 2016
Florence (Italy)

Bronchoscopic Evidence of Endobronchial Hairs in Endobronchial Teratoma

Pengbo Deng, Bingrong Zhao, Yuanyuan Li

Department of Respirology & Critical care medicine of Xiangya Hospital, Central South University - China

Introduction

A 39-year-old male was diagnosed as endobronchial teratoma in our hospital. We reviewed related literatures on clinical features, diagnostic method, treatment and prognosis of this rare tumor.

Objective

To discuss the clinical course, pathological features, diagnosis and treatment of endobronchial teratoma,.

Methods

We conducted a search of the published English/Chinese literatures since 2000 in MEDLINE /PubMed and WANFANG DATA using search criteria [(“endobronchial teratoma”) or (“teratoma” and “bronchia” and “bronchoscopy”)]. There is 8 case of endobronchial teratoma. We have also searched for recent advances in diagnosis and treatment of this disease.

Results

The clinical manifestations of endobronchial teratoma are non-specific, so it has been often misdiagnosed as turberculosis, invasive pulmonary aspergillosis or lung cancer. The definitive diagnosis relies on the histopathology of bronchial neoplasm. Moreover, The special bronchoscopic findings can be a distinguishing feature of endobronchial teratoma. Surgical resection is the main treatment. However, tendency of recurrence and metastasis sometimes exists.

Conclusions

Endobronchial teratoma is an extremely rare tumor., hence preoperative diagnose is usually inaccurate. Diagnostic bronchoscopy can often achieve the diagnosis of endobronchial teratoma preoperatively. As a result ,the importance of bronchoscopy in the diagnosis should be stressed.

id 226

A completely asymptomatic 68-Year-Old Woman with an extensive endobronchial lesion

Annalisa Brianti, Maria Grazia Covesnon, Francesca Scordamaglia, Lorenzo Stellino, Claudio Francesco Simonassi

UO Pneumologia, ASL3 Genovese - Italy

Introduction

Tracheobronchial tumors are rare, accounting for only about 0.4% of all body tumors. In adults, only 10% of the tracheobronchial tumors are benign. Pulmonary hamartomas are the most common benign lung tumors, with an incidence between 0.025% and 0.32%. Most of the pulmonary hamartomas are diagnosed during adulthood, with a peak incidence in the sixth to seventh decade and a male predominance by a ratio of 2:1 to 3:1. Endobronchial hamartomas (EHs) represent only 1.4% of pulmonary hamartomas, although some studies have reported a higher incidence between 10% and 20%. EHs can have variable presentations depending on the site and size of the tumor. The patient can be asymptomatic, especially in early stages, but later the patient can develop symptoms of airway irritation or obstruction. Our patient was completely asymptomatic despite the severe lung consolidation and the extension of the endobronchial lesion suggesting a slow growth of the lesion.

Methods

The patient was a 68-year-old woman with a previous extensive smoking history and alcoholism. She was completely asymptomatic with stable vital signs. The patient presented to our emergency room after a syncope with following facial trauma. The chest radiograph showed a complete opacification of the right lung. The CT scan of the chest confirmed the consolidation of the right parenchyma lung with excavated opacities coherent with cystic bronchiectasis and a solid low-density endobronchial lesion in the right main bronchus (Fig 1). Bronchoscopic examination showed a whitish,high-consistence,polypoid lesion with a narrow stalk causing near complete obstruction of the right main bronchus and intermediate bronchus. The patient underwent endoscopic removal with Nd:YAG laser via rigid bronchoschopy and subsequent recanalization. There were no complications. Pathologic examination reveals clefts of respiratory-type epithelium extended between lobules of mature cartilage and other bland mesenchymal elements such as fat and smooth muscle. These findings were consistent with the diagnosis of chondroid hamartoma. After 1 month, the patient repeated the chest CT scan with no recurrence of the endobronchial lesion but persistence of the complete consolidation of the lung

Conclusions

EH is a rare tumor of the tracheobronchial tree that can have variable presentation. Endoscopic intervention is the first line of treatment of uncomplicated EHs. Endoscopic removal of benign airway tumors including EHs is preferred, as it is less invasive and provides satisfactory results.

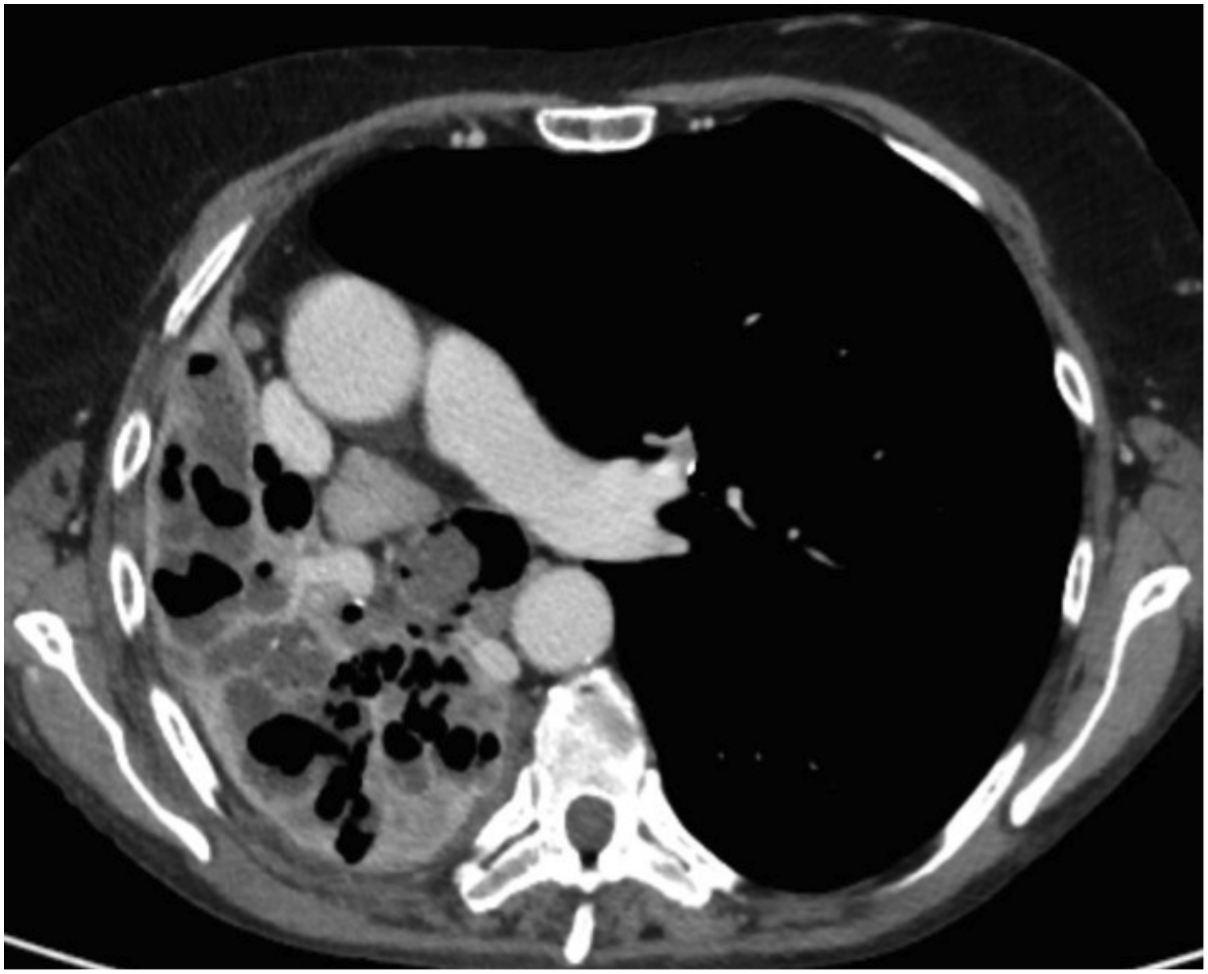

id 227

Efficacy of total lung lavage in pulmonary alveolar proteionosis: a multicenter international study

Gay Pierre

Pneumology and thoracic oncology, CHU - France

Introduction

Total Lung Lavage (TLL) is consider as standard of care in Pulmonary Alveolar Proteinosis (PAP). Yet, new therapies have emerged in the traitement of PAP and therefore there is a real need to evaluate the efficacy of TTL in this rare disease.

Objective

The aim of this study was to assess the efficacy of TTL in patients with PAP.

Methods

We have included 25 patients who underwent TTL from 10 centers, members of the French-Speaking Endoscopy Group (GELF) for analysis. Data collection concerned patient's and disease characteristics, pulmonary function tests (PFTs) before and after the procedure, and technical informations on the procedure.

Results

Median age of the patients is 43.5 years (13 to 77) with a male predominance (18-72%). Patients with respiratory insufficiancy at presentation were 14 (56%). All patients underwent lung lavage by general anesthesia and selective lung ventilation, but one who underwent awake flexible bronchoscopy lavage. We noted differences in the technique as 12 (48%) patients had percussion during the procedure and only 7(28%) underwent two-lungs lavage during one anesthesia. A median of 11.5 L were used to performed TLL (1.0L to 33L). Complications occured in 8 (32%) patients and 14(56%) of them relapsed in a median period of 19.6 months . No significant changes were found in all PFTs parameters studied, in exception to PaO2 which was after the procedure higher of 8.667 mmHg (p=0.0242 ; [95%CI : 1.309-16.024]) in comparison to before.

Conclusions

Although the technique of TLL has a variability in its application, due probably to patient's condition, it improves significantly patients' short-term respiratory condition, by improving PaO2. However, long-term effect needs to be confirmed, as many of our patients relapsed.

id 228

Management of bronchial stenosis due to Right-sided Aortic Arch using bronchial Oki stents

Ekrem Cengiz Seyhan

Cchest, Medipol University, Medical Faculty, Chest Diseases, Istanbul, - Türkiye

Introduction
Right aortic arch (RAA), a congenital malformation of the great vessels of the thorax, is a rare disease in adulthood, and can cause symptoms from the compression of the trachea, bronchi or esophagus.

Objective
In this report we presenting a case with RAA caused bronchial stenosis treated implantation of bronchial Y stent.

Methods
Thorax computed tomography showed RAA with an aberran left subclavian artery and bronchiectasis of right lower lobe. Intermediate bronchus was seen narrowed like fish eye, and could not been passed distal of the intermediate bronchus, during fiberoptic bronchoscopy.

Results
Narrow bronchus was opened. After one year, bronchoscopy showed the bronchus is fully open.

Conclusions
Interventional bronchoscopy offers immediate palliation of respiratory symptoms in cases with tracheobronchial stenosis due to RAA.

Bibliography
1- Cina CS, Arena GO, Bruin G, Clase CM. Kommerell's diverticulum and aneurysmal right-sided aortic arch: acase report and reviev of the literature. J Vasc Surg 2004; 39(6): 1360-1361

Cutoff value of thyroglobulin in fine needle aspirates to detect neck metastasis from thyroid cancer

Koji Sakamoto[1], Yorihisa Imanishi[2], Hiroyuki Ozawa[3], Toru Ishikawa[1], Hiroko Fujita[1], Masafumi Ueno[1], Seiichi Shinden[1], Kaoru Ogawa[3]

[1]Otorhinolaryngology, Saiseikai Utsunomiya Hospital - Japan
[2]Otorhinolaryngology, Machida Municipal Hospital - Japan
[3]Otorhinolaryngology, Keio University - Japan

Introduction

Fine needle aspiration cytology (FNAC) is one of the useful tools to diagnose lymph node metastasis from thyroid carcinoma. However sometimes it reveals a false negative in hypocellular lesions like cystic metastases. Thyroglobulin measurement in fine needle aspirates (FNA-Tg) is an accurate method to detect the specific protein secreted by thyroid follicular cells and high FNA-Tg levels in an extra-thyroidal lesion means that the lesion comprises thyroid- originated tissue, most of which suggests the metastasis from thyroid carcinoma. Cutoff value of FNA-Tg is reported by several studies but these studies did not include the lesions other than lymph nodes. Clinically, congenital neck cysts, neurogenic tumor, and salivary gland tumors are sometimes difficult to distinguish form lymph node metastases from occult primary thyroid carcinoma even by imaging study and FNAC. This study was aimed to determine cutoff value of FNA-Tg including lymph nodes and other neck lesions.

Objective

To evaluate cutoff value of FNA-Tg which may specifically differentiate thyroidal lesions from non-thyroidal lesions including the lesions other than lymph nodes.

Methods

We retrospectively reviewed 125patients who had extra-thyroidal lesions (137 lesions) which were measured FNA-Tg with FNAC and undergone pathological examinations. We compared FNA-Tg value of pathologically proven lesions including lymph nodes and other lesions which needed to be differentiated from lymph node metastasis from thyroid carcinoma. We calculated cutoff value of FNA-Tg at the point whose specificity was 100% by ROC curve.

Results

Among 137 lesions, 67 lesions were thyroid origin (64 metastases of papillary carcinoma, one follicular carcinoma, one poorly differentiated carcinoma, and one ectopic thyroid tissue) and 70 lesions were not thyroid origin (47 lymph nodes and 23 other neck lesions). High FNA-Tg value was observed in thyroid- originated lesions and the cutoff value at the point of 100% specificity was 62.8 ng/ml. The sensitivity of this cutoff offers 80.6%. Among thyroid carcinoma, Sensitivity of FNAC and FNA-Tg were 60.4% and 80.3%, respectively and combining FNAC and FNA-Tg resulted in 95.5% of sensitivity.

Conclusions

Our result suggest that 62.8ng/ml of FNA-Tg is recommended as a cutoff value to differentiate thyroid-originated lesion from other neck masses. FNAC and FNA-Tg are considered to be complementary to each other for preoperative diagnosis of lymph node metastasis of thyroid carcinoma. FNA-Tg was validated to improve the preoperative diagnostic sensitivity especially when combined with FNAC.

First Danish Experience of Cryobiopsies for the Diagnosis of Interstitial Lung Diseases

Birgitte Folkersen[1], Torben Riis Rasmussen[1], Line Bille Madsen[2], Finn Rasmussen[3], Venerino Poletti[1], Elisabeth Bendstrup[1]

[1]Department of Respiratory Diseases and Allergy, Aarhus University Hospital - Denmark
[2]Department of Pathology, Aarhus University Hospital - Denmark
[3]Department of Radiology, Aarhus University Hospital - Denmark

Introduction

The diagnosis of interstitial lung diseases (ILD) is challenging. A confident diagnosis depends on a multidisciplinary team effort based on the combination of a clinical history, radiology and pathology. Many patients remain unclassified due to the lack of a surgical lung biopsy, often deemed too risky either due to age, frailty and comorbidity or due to mild, limited disease. Transbronchial cryobiopsies (TBCB) have emerged as a new method of obtaining histopathological specimens for the diagnosis of ILD.

Objective

To report on the first Danish experiences with cryobiopsies in ILD diagnosis.

Methods

The use of TBCB for the diagnosis of ILD was begun in 2015 and was performed by two experienced interventional pulmonologists in patients with suspected ILD. Data on demographics, high-resolution computed tomography (HRCT), size and number of biopsies, histology patterns and its contribution to a confident diagnosis of an ILD and complications have been retrieved from patient files.

Results

Eleven patients (6M/5F) with a mean age of 65.2 ± 9 years had TBCB taken between November and December 2015. Mean forced vital capacity was 96 ± 20 % predicted, mean diffusion capacity 66 ± 10 % predicted. HRCT showed possible UIP in 6 patients;no patient had a definite UIP pattern. The mean number of biopsies was 4 and the mean diameter of each biopsy was 6.32 ± 2.9 mm. 6 patients had complications (5 pneumothorax, 1 hemoptysis after discharge). 4 patients needed drainage of their pneumothorax. There were no deaths. In 7 patients the biopsy contributed to a confident diagnosis thus preventing the patient from having other invasive investigations.

Conclusions

The first Danish experiences with TBCB have been successful and show that cryobiopsies are easy and feasible to apply. Complications are acceptable and results important in achieving a confident diagnosis in ILD.

id 231

Pleural adhesions assessment as a predictor for pneumothorax after endobronchial valve treatment

Wouter H. Van Geffen, Karin Klooster, Jorine Hartman, Nick Ten Hacken, Huib Kerstjens, Rienhart Wolf, Dirk-jan Slebos

Department of Pulmonary Diseases, University Medical Center Groningen - Netherlands

Introduction

Pneumothorax after endobronchial valve (EBV) treatment in patients with advanced emphysema is a common adverse event, occurring in about 20% of the patients. It is not well known which factors can predict the development of a pneumothorax. A possible explanation is that these pneumothorax are caused by adhesions between the treated lung and parietal pleura. They might work against the large volume shifts after successful EBV treatment.

Objective

To assess the occurrence of pleural adhesions on high resolution computer tomography (HRCT) in patients who undergo EBV treatment in relation to the likelihood of developing a pneumothorax.

Methods

Post hoc analysis were performed on the pre-treatment HRCT of patients who received EBV treatment in the Stelvio trial (1). Two readers measured the longest axis of pleural adhesions in the treated lung following a cumulative “Pleural Adhesions Score (PAScore)”; 1 point for a small pleural lesion (<1mm), 5 points for a medium lesion (1-5mm) and 10 points for a bigger lesion (>5mm). For each patient a mean score of both assessors was calculated. Incidence of pneumothorax was registered until 6 months after treatment.

Results

Forty-one HRCTs were assessed (N=14 developed a pneumothorax after endobronchial valve treatment and we were able to assess N=27 without pneumothorax). Pleural Adhesions Score [mean ±SD] in the group without pneumothorax was 9.2 ± 7.4 and in the group with a pneumothorax was 20.4 ± 11.4 (P<0.01)(see figure). A threshold Pleural Adhesions Score of >=20 resulted in our analysis in a higher risk for pneumothorax (Odds ratio: 8.00 (95%CI: 1.63-39.35)). A score smaller than 20 does not rule out the risk for pneumothorax.

Conclusions

Pleural adhesions in the treated lung were associated with a higher occurrence of pneumothorax after EBV treatment. This assessment can be used to identify patients at risk, and inform individual patients about their potential pneumothorax risk.

Bibliography

(1) Klooster K, ten Hacken NHT, Hartman JE, Kerstjens HAM, van Rikxoort EM, Slebos D. Endobronchial Valves for Emphysema without Interlobar Collateral Ventilation. N Engl J Med 2015;373(24):2325-2335.

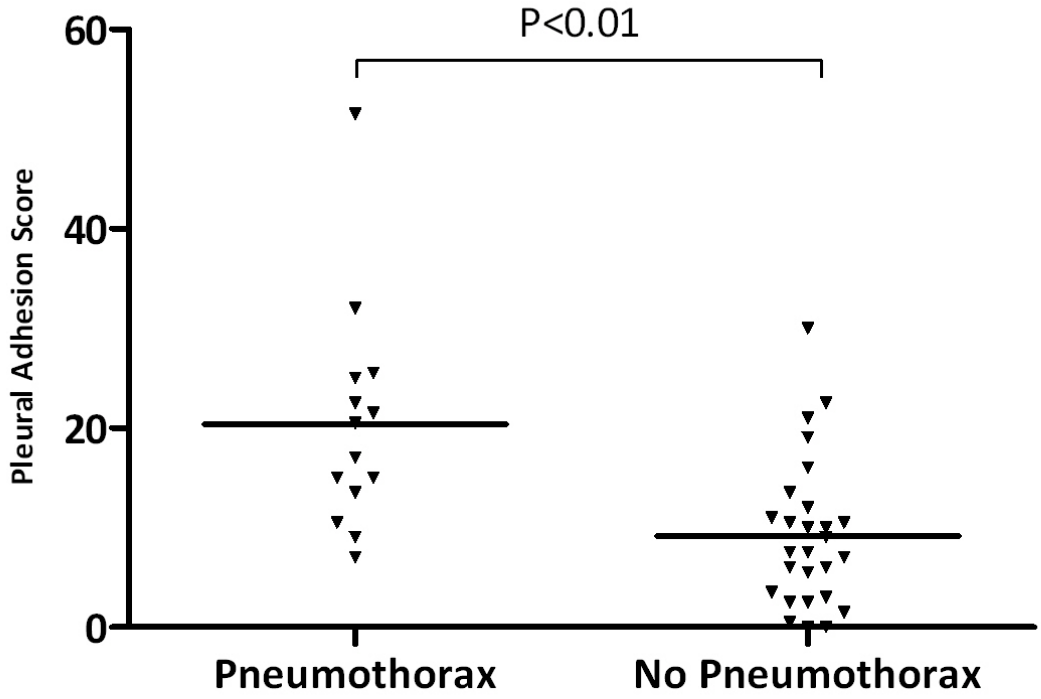

Pleural Adhesion Score by group categorization based on the latter occurrence of pneumothorax after EBV treatment. Each dot represents the mean of the Pleural Adhesion Score of two assessors. An unpaired t-test was used to asses the difference between the groups. The horizontal line represent the mean PAScore.

id 232

A new visualization method for navigated bronchoscopy

Páll Jens Reynisson[1], Erlend Fagertun Hofstad[2], Håkon Olav Leira[3], Christian Askeland[2], Thomas Langø[2], Hanne Sorger[3], Frank Lindseth[4], Tore Amundsen[3], Toril Anita Nagelhus Hernes[1]

[1]Dept. Circulation and medical imaging, Norwegian University of Science and Technology NTNU - Norway
[2]Dept. Medical Technology, Stiftelsen for industriell og teknisk forskning SINTEF - Norway
[3]Dept. Circulation and medical imaging & Dept. Thoracic Medicine, Norwegian University of Science and Technology NTNU & St. Olavs Hospital - Norway
[4]Dept. Medical Technology & Dept. Computer and Information Science, Stiftelsen for industriell og teknisk forskning SINTEF & Norwegian University of Science and Technology NTNU - Norway

Introduction

Literature shows accuracy improvement after the introduction of navigation systems for bronchoscopy success rates enhancing up to 60-80%, for all types of lesions.1 For the last 20 years there has been numerous publications on navigated bronchoscopy on registration with electromagnetic tool tracking, centerline extraction and virtual bronchoscopy (VB). VB is the visualization part of the navigated bronchoscopy that pulmonologists see on the monitor screen, consisting of a segmented airway from patient data displayed additionally with the traditional two-dimensional (2D) computed tomography (CT) orthogonal views. The drawback with current VB visualization is the lack of associating the surrounding environment within the lung in three- dimensional (3D) such as detailed anatomical features such as neighboring area to lesions and straight path to target. We have therefore implemented a new method that combines the traditional 2D orthogonal CT, 3D models, path to target and VB into one display so called Anchored to Centerline Curved Surface (ACCuSurf) a 3D CT structure for diagnostic navigated bronchoscopy.

Objective

Improvement in diagnostic success rate is vital by refinement of visualization methods in navigational bronchoscopy. The ideal interface would include simultaneous overview of the position of the target(s), the surrounding anatomy (e.g. larger vessels), the ideal pathway to the target and detailed real-time information of the exact position of the bronchoscope. The main aim is to increase the usefulness of 3D visualization in the region of interest, simplify the detection of the target, the sampling procedure and avoid vulnerable anatomical structures in order to ultimately improve diagnostic precision and reduce adverse events.

Methods

To generate the ACCuSurf visualization we used the shortest path from the top of the trachea to the target along the airway centerline. Another path was selected in the other lung compartment leading to the airway closest to the thoracic wall and caudally. Then we extracted perpendicular voxel segments from the CT data beginning in the selected paths on each side of the lung and ending in the thoracic walls. The extracted voxel segments were smoothed with Bezier curvature.

Results

The following figure demonstrates the new 3D CT ACCuSurf structure with a lung window as threshold displaying anatomical features in the lungs and the surrounding anatomy see figure.

Conclusions

The proposed technique can simplify navigated bronchoscopy, detection and sampling of lung lesions by compensating for the orientation confusion and potentially improve the diagnostic precision, reduce adverse events and become indispensable guiding tool for lung diagnostics.

Bibliography

1. Reynisson, P. J. et al. Journal of Bronchology and Interventional Pulmonology 2014; 21:1-23

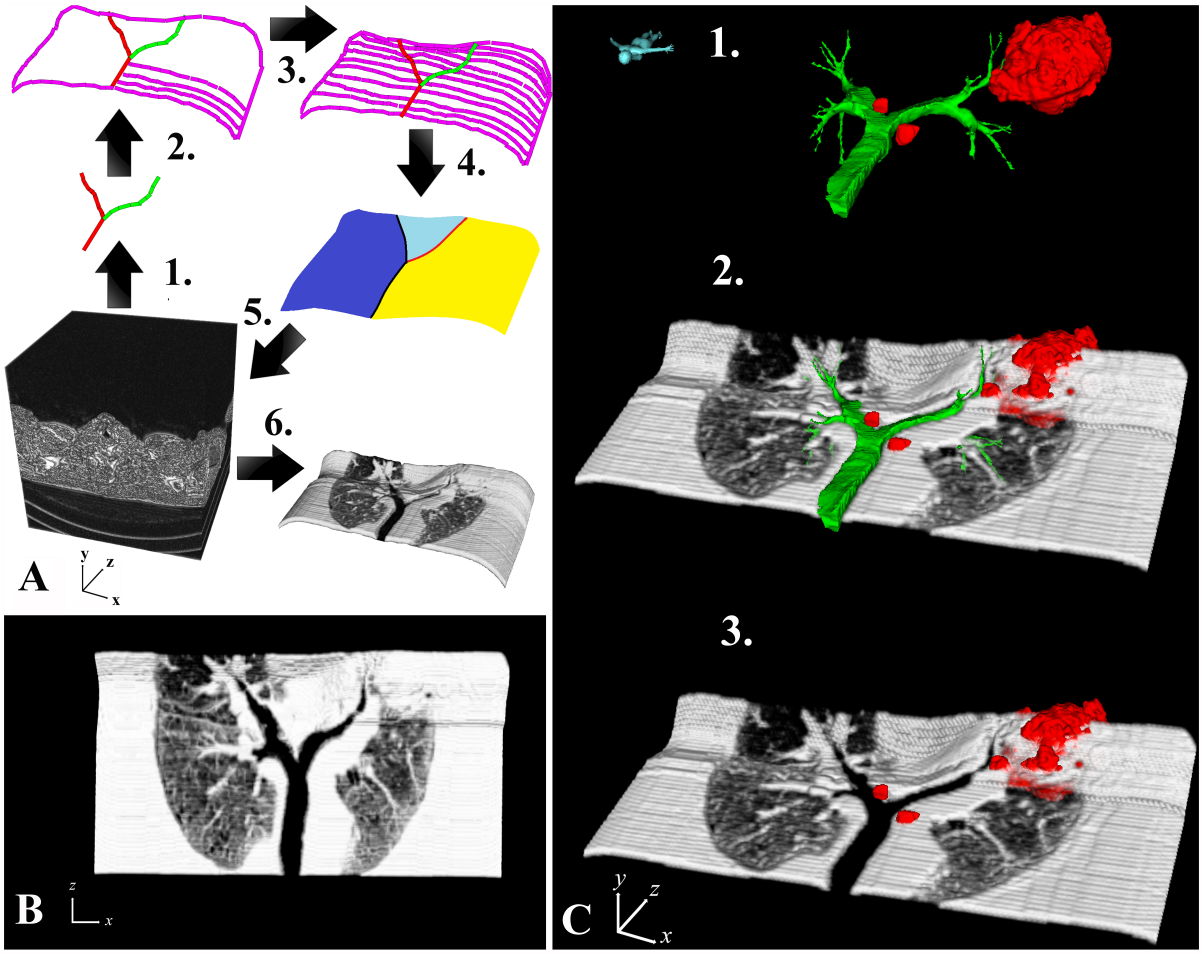

Figure. A Overview of ACCuSurf visualization: 1. Two airway centerlines paths extracted from a 3D CT scan of the airways. 2. Extraction and Bezier smoothing of perpendicular coordinate voxel spline strips information from the 3D CT data from each of the paths to the left and right edges (of the CT data). 3. Interpolation between paths below the separation at the carina. 4. Bezier splines form Bezier smoothed surface coordinates. 5. The coordinate mask used for extraction of Hounsfield information from the CT data. 6. The final form of the ACCuSurf display. B. 2D Projection of the ACCuSurf demonstrating anatomical detail from the original CT data. C. Comparisons between ACCuSurf and 3D reconstruction in virtual bronchoscopy between 1. Virtual Bronchoscopy with 3D airway reconstruction with lesions. 2. Combination of ACCuSurf and 3D reconstruction. 3. ACCuSurf with lesion. Patient orientation on upper left corner.

The presenting author has the following conflicts of interest that relate to this abstract: *DISCLOSURE OF FUNDING SOURCE(S): abstracts must provide the funding source (industry name, grant name, or other applicable funding) if one exist. Commercial names, trade names and company brands should not be mentioned in the abstract title: however, they may be mentioned in the body of text. Abstract containing elements that might lead to patient identification shall be disqualified.*

id 233

19th WCBIP / WCBE World Congress
JOINT MEETING OF THE WORLD ASSOCIATION FOR BRONCHOLOGY AND INTERVENTIONAL PULMONOLOGY & THE INTERNATIONAL BRONCHOESOPHAGOLOGICAL SOCIETY
www.wcbipwcbe2016.org
Fortezza da Basso
May 8-11, 2016
Florence (Italy)

Effectiveness and complications 90 days post coil-ELVR (endoscopic lung volume reduction) treatment

Konstantina Kontogianni[1], Vasiliki Gerovasili[2], Daniela Gompelmann[1], Claus-peter Heußel[3], Hans Hoffmann[4], Felix Herth[1], Ralf Eberhardt[1]

[1]Department of Pulmonology and Respiratory Care Medicine, Thoraxklinik at the University of Heidelberg and Translational Lung Research Center Heidelberg, Member of the German Center for Lung Research DZL - Germany
[2]Cardiopulmonary Exercise Testing and Rehabilitation Laboratory,First Critical Care Department, 'Evgenidio' Hospital - Greece
[3]Diagnostic and Interventional Radiology with Nuclear Medicine, Thoraxklinik at the University of Heidelberg and Translational Lung Research Center Heidelberg, Member of the German Center for Lung Research DZL - Germany
[4]Department of Thoracic Surgery, Thoraxklinik at the University of Heidelberg - Germany

Introduction
Treatment with lung volume reduction coils may be effective in patients with severe heterogeneous emphysema and bilaterally incomplete fissures. What about the safety of this treatment?

Objective
To evaluate the effectiveness but also the complications 90 days post coil- ELVR treatment.

Methods
In this retrospective analysis 85 patients (?/?:40/45, age: 64±7years) were included. A total of 10 coils were implanted in a single lobe. 25 patients received additional treatment of a contralateral lobe. All patients had severe heterogeneous emphysema and bilateral incomplete fissures. At 90 days follow-up changes in pulmonary function tests (PFT), 6-Minute-Walk-Test (6MWT) and modified Medical Research Council (mMRC) dyspnea scale, as well as possible complications were recorded.

Results
Forced expiratory volume in the 1st second (0.70±0.19L vs 0.75±0.22L, p=0.001), vital capacity (2.08±0.69L vs 2.33±0.77L, p<0.0001) and residual volume (6.07±1.38L vs 5.60±1.33L, p<0.0001), all improved at 90 days significantly. 6MWT (244±90m vs 274±80m, p<0.0001) and mMRC also improved. The complication rate was 63% (n=69) in a total of 110 procedures. 3 patients passed away (2.72% mortality) after suffering severe pneumonia of the treated lobe followed by sepsis and death; 2 of them developed abscesses around the coils. Significant complications (32%, n=35) included: severe hemoptysis in 9 patients (8.2%) which in 3 cases required surgical intervention, pneumonias treated with intravenous antibiotics in 18 patients (16.4%) two of them requiring hospitalization in intensive care unit, and finally pneumothorax requiring chest tube draining in 8 patients (7.3%) which in 3 cases required further surgical intervention due to persistent fisteling or lung perforation by coils. Light, self-limited hemorrhage occurred in 16 patients (14.5%), pneumonia that required only oral antibiotics in 10 patients (9%), pleural pain/discomfort in 4 patients (3.6%).

Conclusions
ELVR with coils improved PFT, 6MWT and mMRC up to 90 days post intervention, however we observed 3 deaths amongst our patients and a significant severe complication rate which requires further elucidation.

id 234

19th WCBIP / WCBE World Congress
JOINT MEETING OF THE WORLD ASSOCIATION FOR BRONCHOLOGY AND INTERVENTIONAL PULMONOLOGY & THE INTERNATIONAL BRONCHOESOPHAGOLOGICAL SOCIETY
www.wcbipwcbe2016.org
Fortezza da Basso
May 8-11, 2016
Florence (Italy)

One-year effectiveness of unilateral endoscopic lung volume reduction (ELVR) using coils

Konstantina Kontogianni[1], Vasiliki Gerovasili[2], Maren Schuhmann[1], Daniela Gompelmann[1], Claus-peter Heußel[3], Felix Herth[1], Ralf Eberhardt[1]

[1]Department of Pulmonology and Respiratory Care Medicine, Thoraxklinik at the University of Heidelberg and Translational Lung Research Center Heidelberg, Member of the German Center for Lung Research DZL - Germany
[2]Cardiopulmonary Exercise Testing and Rehabilitation Laboratory, First Critical Care Department, 'Evgenidio' Hospital, NKUA - Greece
[3]Diagnostic and Interventional Radiology with Nuclear Medicine, Thoraxklinik at the University of Heidelberg and Translational Lung Research Center Heidelberg, Member of the German Center for Lung Research DZL - Germany

Introduction
ELVR with coils has so far been shown to be effective on short term observations for treating patients with severe heterogeneous emphysema and bilaterally incomplete fissures

Objective
Evaluation of long-term effectiveness of ELVR using coils

Methods
In this prospective analysis 30 patients with severe chronic obstructive pulmonary disease (?/?:15/15, age: 64±7 years), heterogeneous emphysema and bilaterally incomplete fissures were included. 10 Coils were implanted unilaterally. Patients were followed up at 90, 180 and 365 days after treatment and changes in pulmonary function tests (PFT), 6-Minute-Walk-Test (6MWT) and modified Medical Research Council (mMRC) dyspnea scale were recorded.

Results
At 90 days the forced expiratory volume in the 1st second improved (0.68±0.16L vs 0.79±0.21L, p=0,001) but the improvement was not sustained at the 180 (0.68±0.16L vs 0,72±0,16) and 365-day follow up (0.68±0.16L vs 0,69±0,17). Vital capacity improved significantly at the 90-day (2.0±0.62L vs 2.37±0.74L, p=0,002) and 180-day follow up (2.0±0.62L vs 2.29±0.74, p=0,007) but improvement was lost after 365 days (2.0±0.62L vs 2.1±0.63). Similarly, residual volume improved significantly at 90 days (6.3±1.44L vs 5.54±1.28L, p=0,004) but the improvement was not sustained at the 180-day (6.3±1.44L vs 5.94±1.22) and 365-day follow up (6.3±1.44L vs 6.33±1.41); Total lung capacity did not differ significantly. 6MWT improved at 90 days although the value did not reach statistical significance (218±99m vs 249±72m) and decreased after 180 days (218±99m vs 242±87) and also at 365-day follow up (218±99m vs 239±92). Finally mMRC improved significantly at 90 days and at 180 days, losing benefit after one year though.

Conclusions
We observed in this study that unilateral treatment with coils, initially helps improve PFT, exercise capacity and perception of dyspnea at 90 days, for some parameters even at 180 days, post intervention; these benefits are nevertheless not sustained until one-year post procedure. Further large scale studies are needed to assess longer term effects of coil-implantation and possible long term sustainable benefits of a bilateral treatment.

id 235

19th WCBIP / WCBE World Congress
JOINT MEETING OF THE WORLD ASSOCIATION FOR BRONCHOLOGY AND INTERVENTIONAL PULMONOLOGY & THE INTERNATIONAL BRONCHOESOPHAGOLOGICAL SOCIETY
www.wcbipwcbe2016.org
Fortezza da Basso
May 8-11, 2016
Florence (Italy)

Criteria for differentiating tuberculosis from sarcoidosis in the material of lymph nodes aspirates

Igor Vasilev[1], Grigoriy Kudryashov[1], Ivan Zaycev[1], Gleb Belyaev[1], Vyacheslav Ghuravlev[2], Tatyana Novitskaya[3], Piotr Yablonskii[1]

[1]Thoracic surgery, Saint-Petersburg Research Institue of Thoracic surgery and TB - Russia
[2]Molecular diagnostics, Saint-Petersburg Research Institue of Thoracic surgery and TB - Russia
[3]Pathology, Saint-Petersburg Research Institue of Thoracic surgery and TB - Russia

Introduction

The main problem of wide use of EBUS tbna in the differential diagnosis of mediastinal lymphadenopathy – are difficulties of differentiating tuberculosis from sarcoidosis in country with high burden of tuberculosis. Now we have some options, which can help to resolve this situation. (Dhooria S., 2014). Until now, it is unresolved problem. We have experience of more than 200 cases of EBUS-TBNA in last 4 years.

Objective

To determine the optimal criteria of differentiating tuberculosis from sarcoidosis by EBUS-TBNA in cases of mediastinal lymphadenopathy.

Methods

A single-center, prospective trial. Inclusion criteria: all patients, who were admitted in the clinic with preliminary diagnosis: mediastinal lymphadenopathy, age no more than 18 years, informed consent to the study. Time from September 2010 until November 2014. Methods: EBUS-TBNA with conventional cytology examination of slides and cytoblocks, PCR for MBT. Reference methods: diagnostic VATS procedure, 6-month follow-up. Patients: 120 (65 males and 55 females) were included in the trial. Mean age was 39,7 (19-73) years.

Results

Final diagnosis were sarcoidosis-88 (73%), tuberculosis-15 (12%), metastasis of cancer of different origin – 12 (10%), nonspecific inflammation – 4 (3%), lymphoma – 2(2%). Overall sensitivity of EBUS TBNA – 62%. In 100 cases, we had to differentiate sarcoidosis and tuberculosis. Sensitivity of non-caseating granuloma for sarcoidosis - 57.95% (Sarcoidosis 1 - 66,6, Sarcoidosis 2 – 55,38%), specificity – 85.71%, PPV – 90%, NPV – 22,78%. Sensitivity of caseating granuloma for tuberculosis is - 80%, specificity – 100 %, PPV – 100%, NPV – 95,24%. Sensitivity and specificity of PCR for MBT for diagnosis tuberculosis were 100 %.

Conclusions

The optimal criteria for differentiating tuberculosis from sarcoidosis in the material of lymph nodes aspirates is PCR-MBT.

Bibliography

Dhooria, Sahajal et al. The Journal of Thoracic and Cardiovascular Surgery , Volume 148 , Issue 2 , 662 - 667

19th WCBIP / WCBE World Congress
JOINT MEETING OF THE WORLD ASSOCIATION FOR BRONCHOLOGY AND INTERVENTIONAL PULMONOLOGY & THE INTERNATIONAL BRONCHOESOPHAGOLOGICAL SOCIETY
www.wcbipwcbe2016.org
Fortezza da Basso
May 8-11, 2016
Florence (Italy)

A case report of airway stenosis treated with APC followed by photodynamic therapy

Takaaki Tsuchida, Takehiro Izumo, Yuji Matsumoto, Yoshihisa Hiraishi

Departmeint of Endoscopy, National Cancer Center Hospital - Japan

Introduction

Photodynamic therapy (PDT) for airway stenosis of advanced lung cancer was shown its superiority in a overall survival and time to restenosis compared to laser ablation therapy as a result of previous randomized trial1). However, PDT and ablation therapy have strong and weak points in each. The weak points of PDT are that the effect is only to the surface layer up to 5mm depth and that there is no immediate effect. On the other hand, ablation therapy can compensate those weak points. We present a case in which good results were obtained by very high frequency (VHF) ablation therapy followed by PDT.

Methods

The patient is a 73 year-old man. Lung adenocarcinoma of the right lower lobe was diagnosed in 2006. EGFR and ALK-IHC were negative. Four courses of CDDP+VNR were performed. However, multiple brain metastases were obtained in 2008. Gamma knife therapy was performed for the brain metastases. The second line series of chemotherapy with Docetaxel were performed 7 courses in 2008. The third line series of chemotherapy with TS-1 were performed 3 courses in 2009. The fourth line series of chemotherapy with Pemetrexed were performed 5 courses in 2009. Palliative therapy had been performed from 2010. The patient was admitted in our hospital because of dyspnea and hemoptysis in 2015. Bronchoscopy as performed and severe stenosis of the right main bronchus was obtained. VHF ablation with APC was performed to improve the stenosis. One week after the ablation, we performed PDT with Talaporfin sodium as a photosensitizer because the stenosis had still remained. The dose of Talaporfin sodium was 40mg/m2. Four hours after injection of the photosensitizer, laser irradiation was performed. The dose of laser was 100 joules/m2 with radial probe for stenotic area, and 100 joules/m2 with direct probe for proximal side of the stenosis. Seven months after PDT, the stenosis had been still improved well.

Conclusions

VHF ablation followed by PDT is one of the options to release airway stenosis. These therapies may complement the weak points of each other.

Bibliography

1) J.P. Diaz-JimeÂnez, et. al., Efficacy and safety of photodynamic therapy versus Nd-YAG laser resection in NSCLC with airway obstruction Eur Respir J 14, 800-805, 1999.

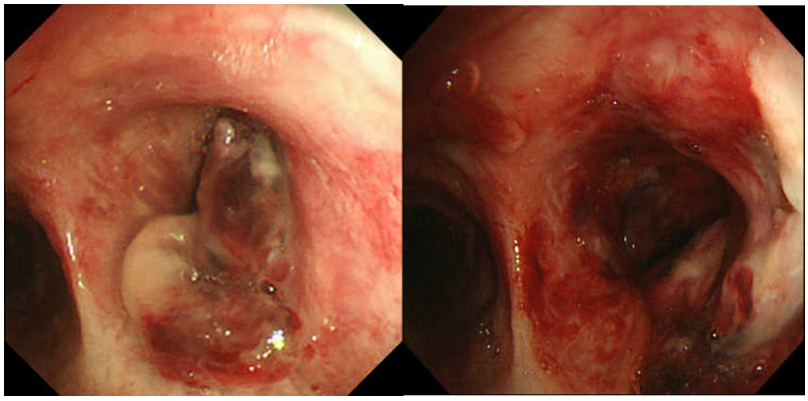

19th WCBIP / WCBE World Congress
JOINT MEETING OF THE WORLD ASSOCIATION FOR BRONCHOLOGY AND INTERVENTIONAL PULMONOLOGY & THE INTERNATIONAL BRONCHOESOPHAGOLOGICAL SOCIETY
www.wcbipwcbe2016.org
Fortezza da Basso
May 8-11, 2016
Florence (Italy)

Bronchoscopy using virtual navigation and EBUS-GS with or without fluoroscopy for peripheral lesions

Motoko Tahihara, Daisuke Tamura, Tatsunori Kiriu, Daisuke Hazama, Ryota Dokuni, Kanoko Umezawa, Haruka Nishimura, Kei Kunimasa, Syuntaro Tokunaga, Suya Hori, Haruko Shinke, Nobuko Hazeki, Hiroshi Kamiryo, Kazuyuki Kobayashi, Yoshihiro Nishimura

Division of Respiratory Medicine, Department of Internal Medicine, Kobe University Graduate School of Medicine - Japan

Introduction
Endobronchial ultrasonography and guide sheath (EBUS-GS) technique has high diagnostic yield in especially nodule with CT-bronchus sign. Virtual bronchoscopic navigation (VBN) can leads bronchoscope to the target bronchi.

Objective
The aim of this prisoective study was to compare the diagnostic yield of two bronchoscopic procedures: bronchoscopy under EBUS-GS and VBN with or without X-ray fluoroscopy in small peripheral pulmonary lesions(<=30mm) with apparent CT-bronchus sign (predictable EBUS image; within) between September 1, 2012, and September 30, 2015.

Methods
Estimated sample size was 140, but we couldn't accumulate appropriate cases in the planned periods. 31 patients with small peripheral pulmonary lesions were randomly assigned to X-ray or non-X-ray groups (18 with X-ray and 13 without X-ray). A bronchoscope was introduced into the target bronchus using the VBN system. Sites of specimen sampling were verified using EBUS-GS with or without fluoroscopy. When an EBUS image could not be obtained in non-X-ray group, we changed to the bronchoscopic examination under fluoroscopy.

Results
Lung cancer was diagnosed in 14 patients in X-ray group and in 9 patients in non-X-ray group. Lung cancer diagnostic yield was 82% (14/17) in the X-ray group and 82% (9/11) in non-X-ray group. Two lesions in non-X-ray group could not be visualized with EBUS and moved on to bronchoscopy under fluoroscopy. The duration of the examination and time elapsed until the first EBUS visualization were similar in X-ray and non-X-ray groups (median (range), 8.97 (5.83-20.0) min vs 11.0 (5.27-17.33) min, p=0.56) and 2.52 (1.33-14.2) min vs 4.09 (1.42-8.17) min, p=0.26, respectively). The X-ray fluoroscopy exposure time was 3.72 (2.87-10.58) min. The only adverse event was mild pneumothorax in a patient from the non-X-ray group who had consequent TBB under fluoroscopy.

Conclusions
VBN-guided EBUS-Transbronchial diagnosis without fluoroscopy is equivalent to that under fluoroscopy without the accompanying radiation exposure. The possible role of endobronchial ultrasound as an imaging method of choice for the biopsy of peripheral pulmonary lesions.

id 238

19th WCBIP / WCBE World Congress
JOINT MEETING OF THE WORLD ASSOCIATION FOR BRONCHOLOGY AND INTERVENTIONAL PULMONOLOGY & THE INTERNATIONAL BRONCHOESOPHAGOLOGICAL SOCIETY
www.wcbipwcbe2016.org
Fortezza da Basso
May 8-11, 2016
Florence (Italy)

Angiogenic factors in recurrent respiratory papillomatosis

Shigeyuki Murono

Otolaryngology-Head and Neck Surgery, Kanazawa University - Japan

Introduction

Recurrent respiratory papillomatosis (RRP) is mainly associated with human papillomavirus (HPV) types 6 and type 11. Although surgical removal of these lesions is a standard treatment, adjuvant therapies will be required because the disease is characterized by the recurrent growth of tumor in respiratory tract. One of these therapies recently focused on is anti-VEGF antibody, bevacizumab.

Objective

Based on effectiveness of bevacizumab for RRP according to published literatures, identifying histological characteristics of angiogenesis as well as expression of aniogenic factors were investigated.

Methods

Histological analyses as well as immunohistochemical analyses of angiogenic factors in surgically removed specimens were performed.

Results

Fourteen specimens were available. Histologically, all 14 specimens demonstrated characteristic fibrovascular cores in each papillary tumor. VEGF expression was mainly observed in tumor cells surrounding these fibrovascular cores in more than half of cases. Expression of other angiogenic factors as well as distribution of microvessels will be presented on an updated poster.

Conclusions

Angiogenisis in fibrovascular corse in RRP is induced by expression of angiogenic factor(s) including VEGF. These results will support clinical effectiveness of bevacizumab for RRP.

id 239

Choke point physiology for airway stenting

Teruomi Miyazawa Miyazawa[1], Hiroki Nishine Nishine[1], Hiroshi Handa Handa[1], Masamichi Mineshita Mineshita[1], Seiichi Nobuyama Nobuyama[2]

[1]Division of Respiratory Medicine, Department of Internal Medicine, St.Marianna University School of Medicine - Japan
[2]Department of Respiratory Medicine, International University of Health and Welfare Atami Hospital - Japan

Introduction
Airway stenting at the wave-speed flow-limiting segment (choke point) is assessed by measuring the difference between lateral pressure and plural pressure using a catheter via the working channel of a stereoscopic bronchoscope. Flow limitation during forced expiration is affected by the relationship between transmural pressure (Ptm) and cross-sectional area (A) of the airway. Wave speed is dependent on the stiffness of the airway wall, i.e., compliance of the airway and on the cross- sectional airway itself (dA/dPtm).

Objective
To demonstrate the difference between the functional success of airway stenting in patients with various tracheobronchial stenosis such as malacia.

Methods
Airway stenting at the wave-speed flow-limiting segment (choke point) is assessed by measuring the difference between lateral pressure and plural pressure using a double-lumen airway catheter via the working channel of a stereoscopic bronchoscope. The catheter was inserted into the airway during bronchoscopy. The site of maximal obstruction was evaluated on the basis of the pressure difference between the proximal and distal sites of the stenosis. Lateral pressure and plural pressure was measured simultaneously at two points during spontaneous breathing with light general anesthesia during stenting. Stereoscopic bronchoscopy, which utilizes two lenses at the tip of the flexible fiberscope, can effectively measure the diameter and cross-sectional area of the airway.

Results
In patient with tracheobronchial malacia, after placement of the Silicone Y-stent for carina, there was no collapse seen in the trachea. Reciprocal of the slope at the choke point indicates stiffness of the airway wall. The relation between driving pressure and the cross-sectional area can be seen in Figure 1. The cross-sectional area was unchanged by the increase in transmural pressure.

Conclusions
Stenting at the choke point can improve expiratory flow limitation by increasing the cross-sectional area and supporting the weakened airway wall, while relieving dyspnea. It is important to locate the exact position of the stenosis for the correct positioning of the stent to provide the greatest functional benefit to patients with tracheobronchial stenosis.

Bibliography
1. Nishine H, et al. Am J Respir Crit Care Med. 2012; 185:24-33. 2. Miyazawa T, et al. Am J Respir Crit Care Med 2004; 169: 1096–1102.

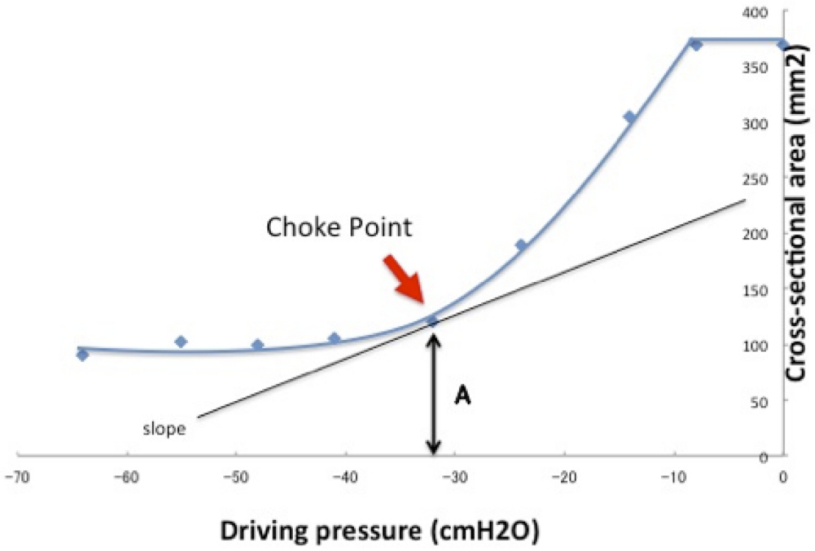
Choke Point
slope
A
Cross-sectional area (mm2)
Driving pressure (cmH2O)
400
350
300
250
200
150
100
50
0
−70
−60
−50
−40
−30
−20
−10
0

id 240

Open-source Virtual Bronchoscopy in Pre-clinical Validation

Pietro Nardelli[1], Alexander Jaeger[1], Conor O'shea[1], Kashif Ali Khan[2], Marcus Peter Kennedy[2], Pádraig Cantillon-murphy[1]

[1]School of Engineering, University College Cork - Ireland
[2]Department of Respiratory Medicine, Cork University Hospital - Ireland

Introduction

When a patient is diagnosed with a suspiciously malignant lung cancer, the physician may decide to proceed with biopsy or cancer exportation. To do so, the CT image of the patient is analysed and anatomy of the airways is mentally reconstructed from the CT scan to identify the best path toward suspect nodules. This is then followed by a physical bronchoscopy to evaluate or biopsy the nodule.

Objective

Goal of this study was the implementation of a novel open-source method for virtual bronchoschopy (VB) starting from chest CT images. The system has been optimized to be used in combination with the EM tracking system described in [1] to help navigation towards regions of interest in the lung.

Methods

The proposed VB system has been developed using the freely available software platform, 3D Slicer [2]. The system enables direct pre-operative CT-based procedure planning and provides direct guidance during bronchoscopy. Distance information between the current location and the biopsy site is interactively provided during navigation. Video image registration between the real and the virtual camera has been implemented to compensate for possible roll angle misalignment. The centreline of the 3D rendered airway view is used to avoid registration issues. The VB technology was tested in-vitro in a breathing lung model, to verify performance and usability in a simulated setting. Then, two animal studies were carried out to further evaluate VB in a realistic setting. Figure 1 shows a scheme representing the system implementation.

Results

For testing with the breathing pig lung model, three separate targets were reached by nine different physicians in the field of respiratory medicine. Even participants who never performed a bronchoscopy before were able to reach targets in reasonable clinical time frames. Moreover, 80% of participants found the system usable above average, and VB was found easy to use and accurate in replicating the clinical setting. During the a first pilot animal study, all the placed tumour models were successfully navigated using manual bronchoscopic steering with virtual navigation. During the second animal study, four targets out of six were successfully navigated. During navigation, image registration successfully aligned real and virtual images at branching points and satisfaction at the VB system was noted.

Conclusions

A novel open-source virtual bronchoscopy system to be coupled with EM tracking system was proposed. The method proved reliable and easy to use, although improvements are necessary to create a complete VB system for lung navigation.

Bibliography

(K. O'Donoghue, et al. IEEE Transactions on Magnetics 2014, 50(7): 1-9) (www.slicer.org)

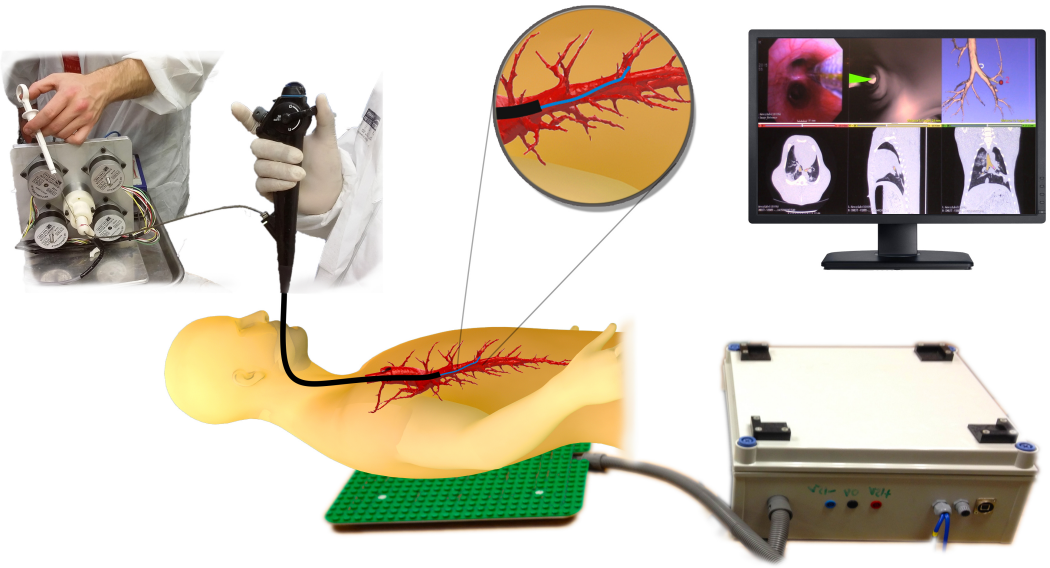

id 241

Comparison of two virtual navigation systems for bronchoscopy targeting to peripheral lesions

Yuta Takashima Dr, Naofumi Shinagawa Dr, Shoji Tetsuaki Dr, Megumi Morimoto Dr, Hajime Kikuchi Dr, Yasuyuki Ikezawa Dr, Taichi Takashina Dr, Hidenori Mizugaki Dr, Eiki Kikuchi Dr, Junko Kikuchi Dr, Jun Sakakibara-konishi Dr, Satoshi Oizumi Dr, Masaharu Nishimura Dr

First Department of Medicine, Hokkaido University School of Medicine - Japan

Introduction

Virtual navigation system for bronchoscopy is an effective way for approaching peripheral pulmonary lesions. In Japan, the original system, Bf-NAVI was launched in 2008, and the new one, DirectPath in 2014. In either system, the bronchial pathway to the target lesion can be automatically constructed to limited extent, so that, in most cases, manual maneuver would be required for reaching the target site. In Bf-NAVI (BN), an operator had to manually set the starting point before automatic construction of any bronchial pathway, which caused inconsistent outcome on the pathway obtained. This inconvenience has been resolved in DirectPath (DP), where the starting point is automatically set at the center of tracheal.

Objective

The aim of this study is compare the ability of automatic bronchial construction between the two virtual navigation systems.

Methods

We used a data set of 100 cases, which had been obtained in our department from March 2012 to December 2012. Using the data stored as digital imaging and communications in medicine (DICOM), we made the image of bronchial pathway to the target lesion, first with use of BN, and then DP. We counted the bronchial generation automatically constructed in both systems and compared between the two.

Results

The mean diameter of target lesions was 23.7 mm on high-resolution computed tomography (HRCT) scans. For these lesions, the bronchial generation automatically constructed was 4.4 for BN and 4.6 for DP. (p=0.08?The bronchial generation to the target lesion eventually constructed with addition of manual maneuver was 6.0 for both. The location of lesions was not related to the bronchial generation automatically constructed. DP was superior to BN in 11 cases by more than two bronchial generations automatically constructed, while BN was superior to DP only in 6 cases by the same criteria.

Conclusions

The new version of virtual navigation system for bronchoscopy, DirectPath, is improved over the original one for the ability of automatic bronchial construction.

id 242

Treatments in Patients with Severe Persistent Asthma

Junko Saji[1], Teppei Inoue[2], Rintaro Onoe[2], Ayano Usuba[2], Hiroshi Handa[2], Teruomi Miyazawa[2], Masamichi Mineshita[2]

[1]Division of Respiratory Diseases, Department of Internal Medicine, Kawasaki Municipal Tama Hospital - Japan
[2]Division of Respiratory Disease, Department of Internal Medicine, St. Marianna University School of Medicine - Japan

Introduction
Even though asthma patients are treated with anti-asthma agents, some patients do not respond very well to them. The efficacy of omalizumab, an anti-IgE antibody, has been studied in patients with severe bronchial asthma. It has been reported that omalizumab improves subjective symptoms and reduce exacerbations in asthma patients. On the other hand, Bronchial Thermoplasty (BT) improves asthma-related quality of life for patients with severe asthma by reducing asthma attacks. However it can be difficult to select the best therapy and the best timing to start the therapy.

Objective
To evaluate the best therapy for the patients with severe bronchial asthma.

Methods
Omalizumab was administered subcutaneously every 2 or 4 weeks based on serum IgE levels and body weight in patients. Pulmonary function tests, Asthma Health Questionnaire (AHQ), Asthma Control Test (ACT), number of emergency visits and the dosage of methylprednisolone during the 12-month period were compared with the previous year.

Results
Twenty patients received omalizumab therapy at our hospital. Eleven patients continued omalizumab for more than 12 months. Treatment with omalizumab yielded no improves for lung function; however, the number of emergency visits (19.2 to 1.4, p=0.013) and dosage of methylprednisolone (883.2 mg to 142.3mg, p=0.030) showed significant reductions when compared to the previous year. AHQ and ACT improved significantly compared to study baseline in 16 weeks. Four patients continued the treatment with omalizumab for five years. Omalizumab reduced the adverse events. Three patients who had 1-2 year history of asthma could maintain good control after finishing omalizumab. One patient with a 27-year history of asthma with osteoporosis was unable to quit oral corticosteroid during omalizumab therapy. BT was considered for this patient, but her condition was stable with current medications, and did not want to undergo further treatment. Furthermore, the height (144cm) and the narrowed bronchi of the patient were considered in the decision not to undergo BT treatment.

Conclusions
Omalizumab significantly reduced the number of emergency visits and methylprednisolone usage. Omalizumab therapy has the potential to reduce the rate of asthma exacerbations. The cost of omalizumab is very high and usually patients have to continue the therapy for over several years. On the other hand, BT is also an expensive therapy option but it can be concluded after 3 sessions. It is very important to consider which therapy is better suited for each patient from the viewpoint of medical economy.

id 243

Rare & Orphan Lung Diseases: Pulmonary Calcification

J. Francis Turner, Jr.[1], Tina Dudney[1], Rishi Sehgal[1], Clay Callison[1], Robert Browning[2], Scott Parrish[3]

[1]Department of Medicine, Division of Pulmonary & Critical Care Medicine, University of Tennessee Graduate School of Medicine - Usa
[2]Interventional Pulmonary Medicine, Walter Reed National Military Medical Center - Usa
[3]Interventional Pulmonology, Walter Reed National Military Medical Center - Usa

Introduction

Rare diseases are those which affect less than 200,000 people, or so-called, ultra-rare disorders where less than one in 2,000,000 are affected (1). In rare diseases of the lung, interventional pulmonary medicine may be called upon to help establish the diagnosis and manage complications associated with respiratory failure or massive hemoptysis.

Methods

We present two rare cases of pulmonary calcification where we provided diagnostic and therapeutic assistance. Case 1: A 45 year old male complained of increasing shortness of breath over the preceding six months with imaging showing hyper dense opacities in the upper lobes. The patient's history was remarkable for a 20 pack per year smoking history and renal failure requiring hemodialysis. A bronchoscopy and biopsy were performed. Case 2: A 59-year-old female was referred with recurrent dyspnea, which had symptomatically previously improved with whole lung lavage. Computerized tomography demonstrated diffuse calcified micronodularity (Fig. 1).

Conclusions

Diffuse pulmonary calcification, as seen in case 1, has been predominately described in metastatic pulmonary calcinosis, calciphylaxis associated with renal failure, severe hypercalcemia associated with elevated parathyroid hormone, or malignant humoral hypercalcemia. Calciphylaxis may widely affect different organs leading even to severe soft tissue calcification. Case 2 was caused by a more rare autosomal recessive disorder characterized by the deposition of intra-alveolar calcium in a patient without abnormal calcium metabolism or cancer diagnosis (2). Pulmonary alveolar microlithiasis is seen among all age groups with 2/3rds being sporadic and the remaining familial, with an abnormality in the short arm of chromosome 4 (4p15) on the SLC34A2 gene. Often these patients will have a slowly progressive course with gradual deterioration and development of end stage lung disease. Both steroids and whole lung lavage have been found to be ineffective, with disodium etidronate only sometimes of benefit. As these patients progress consideration for lung transplantation should be discussed. Rare and orphan lung diseases are uncommonly seen and best served with disease specific consultants such as geneticists, endocrinologists, and renal physicians. We believe a multi-disciplinary approach for these Rare & Orphan Lung Diseases will help in their rapid identification and research into additional therapy.

Bibliography

1. Spagnolo P, et al. Rare lung disease and orphan drug development. Lancet Respir Med 2013; 1:479-487. 2. Angelica FF Flavia, et al. Respiratory Medicine 2013; 107:1-9.

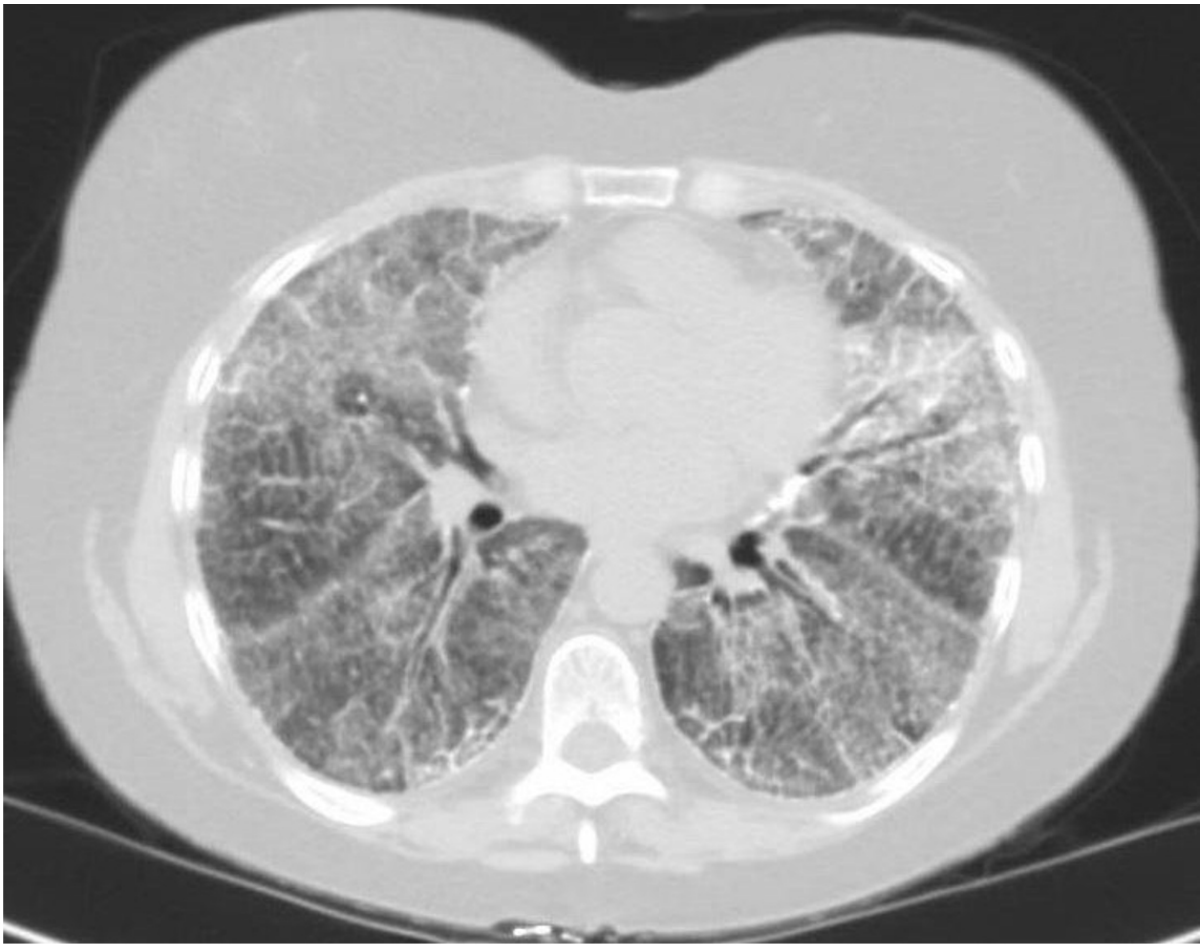

Figure 1. Chest CT of patient with pulmonary alveolar microlithiasis

id 244

19th WCBIP / WCBE World Congress
JOINT MEETING OF THE WORLD ASSOCIATION FOR BRONCHOLOGY AND INTERVENTIONAL PULMONOLOGY & THE INTERNATIONAL BRONCHOESOPHAGOLOGICAL SOCIETY
www.wcbipwcbe2016.org
Fortezza da Basso
May 8-11, 2016
Florence (Italy)

The feasibility and acceptability of Google Glass at chest drain training sessions

Tudor Toma

Respiratory Medicine, University Hospital Lewisham & Greenwich NHS Trust, King's College. - Uk

Introduction

Insertion of a Seldinger pleural drain has numerous procedural steps that need to be performed precisely, in order to achieve safe, painless and efficient pleural drainage. Google Glass (GG) offers the possibility to keep an eye on the insertion checklist, while performing the procedure.

Objective

To explore the feasibility and acceptability of GG at chest drain training sessions on a simulator.

Methods

We asked 10 doctors without experience in chest drains or GG to attend a one to one session of a Seldinger chest drain insertion on a plastic thorax simulating the pleural cavity. An insertion check list of the procedure was sent in advance to every student, alongside with a video demonstrating the procedure. Students were asked to perform the procedure on their own, in the presence of an instructor, but without any direct help from the instructor. The checklist was discussed with the student at the beginning of the session, and then the student was trained for 5-10 min in using GG. Throughout the training session the checklist was projected by the GG in the peripheral visual field of the student. At the end of the session the students were given a link to complete independently an online evaluation questionnaire.

Results

Only 8 of 10 students tolerated the use of GG during the whole training session. Overall, the GG ease of use was scored 4/10 (10 is very difficult). Comfort with GG was scored 6.13/10. The utility of GG in the training process was evaluated at 6.87/10. Students suggested the need for more time to familiarize with GG, and wished to video record of the procedure.

Conclusions

GG can be used to support learning a complex checklist procedure such as Seldinger chest drain insertion. However, a specific period of familiarization and training with GG is necessary. Randomized studies are needed to demonstrate the educational benefits of GG.

id 245

Quality of life in patients with benign tracheal stenosis treated by stenting or tracheostomy

Mauro F. L. Tamagno, Benoit J. Bibas, Paulo F. G. Cardoso, Helio Minamoto, Ricardo M. Terra, Paulo M. Pêgo-fernandes

Division of Thoracic Surgery, Heart Institute (InCor) - Hospital das Clinicas, Faculty of Medicine of the University of São Paulo - Brazil

Introduction

Patients with post-intubation tracheal stenosis that are considered unfit for tracheal resection are dealt with by stenting and/or tracheostomy which may have an impact on health related quality of life (QOL). To date there have been no studies focusing on QOL in patients with tracheal stenosis using tracheal appliances.

Objective

To evaluate overall QOL of patients with benign post-intubation tracheal stenosis focusing on the differences in the QOL between Dumon silicone stent, Montgomery T-Tube and tracheostomy.

Methods

Prospective study with data collection between August and December 2014. Inclusion criteria were age between 18 and 65 years; patients with benign tracheal stenosis treated with Dumon stent, Montgomery T-Tube or tracheostomy; sign the informed consent; cognitive skills to complete the survey. Exclusion criteria were previous tracheal resection; acute or chronic disabling diseases. Patients were randomly selected to enroll in the study. QOL was evaluated in a single session using the SF-36 questionnaire. Scores were analyzed as median. Difference between groups were evaluated with Kruskal-Wallis, and corrected with Dunn´s test. Linear regression model evaluated the influence of variables on the QOL scores. Statistical significance was set at the 5% level.

Results

Ninety-three patients (62 males) were included with a mean age of 38 + 14 years. Mean treatment time was 4.4 + 3.5 years. Treatment modalities were T-Tube (n=56; 60%) tracheostomy (n=24), and Dumon stents (n=13). Median QOL in patients with tracheal stenosis was generally poor. Lowest scores were found in the domains role physical (RP) (12.5), bodily pain (22), and role emotional (33). Scores in patients with Dumon stents were higher than other treatment modalities. This difference was statistically significant only in the RP domain (p=0.04); Dumon vs tracheostomy, p=0.001; Dumon vs T-Tube, p=0.01. Results were compared with the SF-36 norm-based scores (USA population). Dumon stents provided the best QOL with 6 domains within mean values. RP and bodily pain were the most affected, but remained just 1 SD below the mean. Patients with tracheostomy had the worst QOL, with all domains below at least 1 STD from the mean. Treatment time significantly influenced QOL in the RP domain (f=463.3 years; p=0.002; 95% CI 1.24-5.52).

Conclusions

QOL of patients with tracheal stenosis is poor. Differences exist according to the treatment. QOL Scores in patients using Dumon stents were similar to the general population. Tracheostomy severely impaired QOL.

id 246

Cryobiopsy during medical thoracoscopy

Luca Viglietta[1], Cristina Pavano[2], Claudia Ravaglia[3], Carlo Gurioli[3], Sara Tomassetti[3], Sara Piciucchi[4], Alessandra Dubini[5], Giuseppe Ugo Di Maria[2], Christian Gurioli[3], Leonello Fuso[1], Venerino Poletti[3], Venerino Poletti[6]

[1]Pulmonology Unit, Fondazione Policlinico Universitario A. Gemelli, Università Cattolica del Sacro Cuore - Italy
[2]Pulmonology Unit, Policlinico G. Rodolico, University of Catania - Italy
[3]Pulmonology Unit, Department of Thoracic Diseases, GB Morgagni-L Pierantoni Hospital - Italy
[4]Departments of Radiology, GB Morgagni-L Pierantoni Hospital - Italy
[5]Departments of Pathology, GB Morgagni-L Pierantoni Hospital - Italy
[6]Department of Respiratory Diseases and Allergology, Aarhus University Hospital, - Denmark

Introduction
Thoracoscopic forceps biopsy has been used in localised and diffuse pleural and pulmonary lesions. Pleural and lung cryobiopsieses (CB) during rigid medical thoracoscopy (RMT) is an innovative diagnostic tool but its role is not well defined.

Objective
This study evaluated CB feasibility and safety during RMT. The secondary aim was to observe CB diagnostic value.

Methods
In this retrospective study we included patients that underwent cryobiopsy during RMT in our center from September 2013 to November 2015. Biopsies were obtained using a flexible CO2 cryoprobe (ERBE, Germany) 2.4 mm in diameter, freezing time: 2 seconds. A pathologist assessed specimen adequacy.

Results
We enrolled 28 patients which features are described in table 1. Thoracoscopies were right in 15 cases and left in 13. Lung CB were performed in 25 patients (89%), parietal pleural CB in 5 (17%) and 2 subjects (7%) underwent both lung and parietal pleural CB. After thoracoscopy a chest tube drainage was placed for 6+3 days in all cases and suction was applied until the fully expansion of the lung in 82% of cases. Talc pleurodesis was performed in 46% of patients. The reported complications were pneumothorax (7%) and fever (14%). No important bleeding nor acute respiratory failure after procedure were observed. The mean hospitalization was 7+3 days. 27 of 28 specimens (96%) were adequate for histological diagnosis: metastasis 6 (22%), lymphoma 2 (7%), mesothelioma 4 (14%), lung adenocarcinoma 5 (18%), pleurisy 6 (22%), tubercolosis 1 (3%), anthracosis 1 (3%), CTD-ILD 1 (3%) and atelectasis 1 (3%). CB didn't meet diagnosis in one case and video-assisted thoracoscopy (VATS) was performed: lymphangioleiomyomatosis was definitive histological diagnosis.

Conclusions
CB during RMT is feasible, safety and efficacy as our preliminary data suggest. Prospective trials are required for a better evaluation of its role as an alternative diagnostic tool to VATS in the hands of trained pulmonologists.

Patients' features

N°Tot	28
Age (years) - mean value±SD	63 ±15
M/F	17/11
VC (%) - mean value±SD	74 ±21
FEV1 (%) - mean value±SD	73 ±22
FEV1/VC (%) - mean value±SD	77±11
DLCO (%) - mean value±SD	55 ±11

Main results

Hospitalization (days) - mean value±SD	7±3
Drainage (days) - mean value±SD	6±3
Pleurodesis % (n)	46 (13)
Complications % (n)	21 (6)
Pneumothorax % (n)	7 (2)
Fever % (n)	14 (4)
VATS % (n)	3 (1)

id 247

Bronchoscopic lung cryobiopsy in diagnosis of pulmonary lymphomas

Cristina Pavano[1], Luca Viglietta[2], Sara Tomassetti[3], Sara Piciucchi[4], Alessandra Dubini[5], Silvia Asioli[5], Claudia Ravaglia[6], Christian Gurioli[6], Carlo Gurioli[6], Giuseppe Ugo Di Maria[1], Francesco Varone[2], Venerino Poletti[6], Venerino Poletti[7]

[1]Pulmonology Unit, Policlinico G. Rodolico, University of Catania - Italy
[2]Pulmonology Unit, Fondazione Policlinico Universitario A. Gemelli, Università Cattolica del Sacro Cuore - Italy
[3]Pulmonology Unit, Department of Thoracic Diseases, GB Morgagni L.Pierantoni Hospital - Italy
[4]Department of Radiology, GB Morgagni L. Pierantoni Hospital - Italy
[5]Department of Pathology, GB Morgagni L. Pierantoni Hospital - Italy
[6]Pulmonology Unit, Department of Thoracic Diseases, GB Morgagni L. Pierantoni Hospital - Italy
[7]Department of Respiratory Diseases and Allergology, Aarhus University Hospital - Denmark

Introduction

Lymphomas involve lung parenchyma either as primitive lesions or through haematogenous and contiguous dissemination. Primary pulmonary lymphomas are rarities, accounting for 0.3% of primary pulmonary malignancies. Metastatic lung involvement is much more common and it's characteristic of both Hodgkin and non Hodgkin lymphomas, with a slightly higher incidence for the first form. The diagnosis of pulmonary lymphoma requires adequate parenchymal samples for histological, immunophenotypical, immunohistochemical and molecular/genotypic tests. Endoscopic bronchial and transbronchial biopsy together with computed tomography (CT)-guided percutaneous core needle biopsy are the most frequently used techniques. On the other hand, these procedures often fail such diagnosis because of inadequete samples or presence of "crash" artifacts. In these cases the diagnosis is met through surgical lung biopsy/mediastinoscopy. Bronchoscopic lung cryobiopsy (BLC) provides larger tissue specimens and minimizes sample's artifacts if compared to traditional transbronchial biopsy; thus have a higher diagnostic yield in diffuse parenchimal lung diseases.

Methods

We report five cases of pulmonary parenchymal lymphomas diagnosed using BLC. Patients were two males and three females, aged between 38 and 70 years. Four of them presented sistemic symptoms, three reported respiratory symptoms. Laboratory tests were suspicious for lymphoproliferative disease and CT - scan identified lung consolidations in all cases, ground glass opacity in two and peribronchovascular consolidations in four of the five cases. Bronchoalveolar lavage showed lymphocytosis only for two of them and monoclonal component was detected in one case. All patients underwent to BLC. In most cases biopsy was performed on a single segmental bronchus (4/5), while the samples' number varied from 2 to 6. Main samples' area was 41,19 mm2 and all the collected speciments were adequete for histological, immunophenotypical and immunohistochemical analisis, allowing the diagnosis. In three cases Fluorescence in situ hybridization (FISH) was performed in order to increase the diagnostic confidence (see Fig 1). None of the four patients developed complications. The hystological diagnosis were the following: lung involvement in intravascular B cell lymphoma (two cases), MALT-lymphoma (two cases) and pulmonary lymphomatoid granulomatosis.

Conclusions

The diagnosis of pulmonary lymphomas requires adequate parenchymal samples for histological, immunophenotypical, immunohistochemical and molecular/genotypic tests. BLC provides larger tissue specimens and minimizes sample's artifacts if compared with traditional transbronchial biopsy. Cryoprobe biopsy could improve diagnosis of pulmonary parenchymal lymphomas and avoid complications related to much more invasive approches.

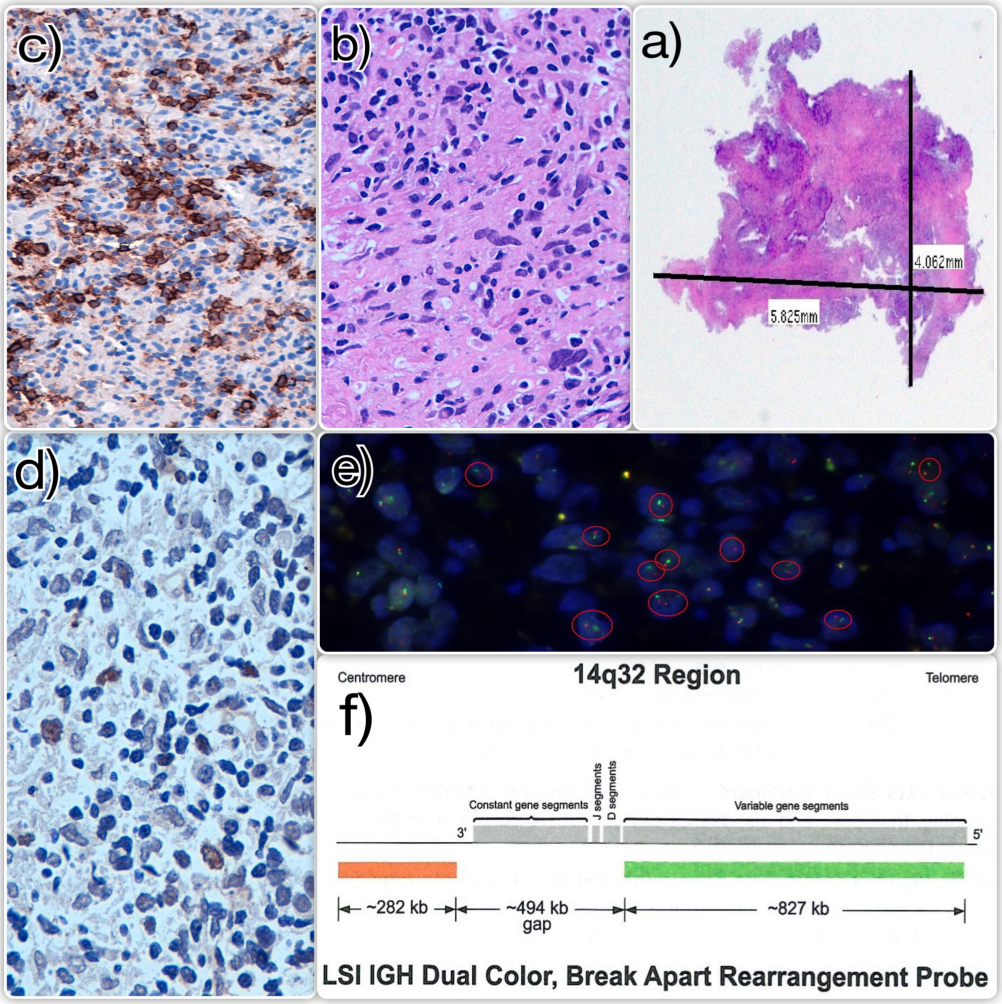

Fig.1:Lymphomatoid granulomatosis a) Cryoprobe biopsy; b) Hematoxylin-eosin stain; c) Immunophenotypical analysis -CD20+ cells; d) In situ hybridization with EBER probe-EBV+ cells; e+f) Fluorescence in situ hybridization-LSI IGH 14q32

id 248

19th WCBIP / WCBE World Congress
JOINT MEETING OF THE WORLD ASSOCIATION FOR BRONCHOLOGY AND INTERVENTIONAL PULMONOLOGY & THE INTERNATIONAL BRONCHOESOPHAGOLOGICAL SOCIETY
www.wcbipwcbe2016.org
Fortezza da Basso
May 8-11, 2016
Florence (Italy)

Endobronchial metastases from melanoma: a survival analysis

Chaussende Amandine

Pneumology, Hôpital Nord, CHU Saint-Etienne - France

Introduction

Metastatic spread to the tracheobronchial tree from other than bronchopulmonary tumors is a common clinical problem. However, malignant melanomas, a highly metastatic potential tumor, is rarely metastasing in the airways. Therefore little is known about survival of patients with endobronchial metastasis from melanoma.

Objective

The aim of our study was to assess survival of patients with endobronchial metastasis of melanomas according to clinical and radiological features, to determine any possible factor affecting survival.

Methods

This retrospective study included 19 patients who underwent a bronchoscopy from 11 different hospitals. Data about patients' demographics, symptoms, radiographic, endoscopic findings and treatment were investigated to evaluate any possible impact on survival.

Results

Endobronchial metastases occurred at a median of 48 months (range 0-120) following the diagnosis of the primary tumor. 73.7% of patients had other proven metastases when the endobronchial involvement was diagnosed. Symptoms are not specific as well as radiological features. Median overall survival of the studied population was 6 months (range 1-46). Factors of poor survival were multiple metastatic sites (p=0.019), pleural (p=0.0014) and soft tissue metastasis (p=0.024). Different treatment modalities applied in our patients showed no effect on survival.

Conclusions

Patients with endobronchial metastasis have overall poor survival, affected by multiple organ involvement, the presence of pleural and soft tissue disease, while no impact on survival has been shown by any treatment applied.

id 249

19th WCBIP / WCBE World Congress
JOINT MEETING OF THE WORLD ASSOCIATION FOR BRONCHOLOGY AND INTERVENTIONAL PULMONOLOGY & THE INTERNATIONAL BRONCHOESOPHAGOLOGICAL SOCIETY
www.wcbipwcbe2016.org
Fortezza da Basso
May 8-11, 2016
Florence (Italy)

Prevalence of gastro-esophageal acid reflux in benign upper airway stenosis

Paulo F. G. Cardoso[1], Juliana M. Trindade[1], Ary Nasi[2], Helio Minamoto[1], Angela M. Falcão[3], Edno T. Bianchi[4], Sergio Szacnowicz[4], Rubens Sallum[4], Christopher K. Nagao[5], Ivan Cecconello[4], Paulo M. Pêgo-fernandes[1]

[1]Division of Thoracic Surgery, Heart Institute (InCor) - Hospital das Clinicas, Faculty of Medicine of the University of São Paulo - Brazil
[2]Department of Gastroenterology, Discipline of Surgery of the Digestive Tract, Esophageal Function Laboratory, Hospital das Clinicas, Faculty of Medicine of the University of Sao Paulo, Sao Paulo - Brazil
[3]Department of Gastroenterology, Discipline of Surgery of the Digestive Tract, Esophageal Function Laboratory, Hospital das Clinicas, Faculty of Medicine of the University of Sao Paulo - Brazil
[4]Department of Gastroenterology, Discipline of Surgery of the Digestive Tract, Hospital das Clinicas, Faculty of Medicine of the University of Sao Paulo - Brazil
[5]Division of Thoracic Surgery, Faculty of Medicine of the University of Sao Paulo - Brazil

Introduction
Preliminary data from our center showed that patients with benign airway stenosis had a high incidence of gastroesophageal acid reflux (GER) in with a predominance of supine and supraesophageal reflux. Based on the hypothesis that GER may play a role and affect upper airway healing the study was expanded.

Objective
To assess the prevalence and characteristics of acid GER in a larger sample of patients with benign tracheal stenosis

Methods
Cross-sectional study including patients with airway stenosis (post-intubation, idiopathic stenosis or a recurrence of the stenosis following previous airway resection). Patients submitted to previous anti-reflux surgery, esophagectomy and/or gastrectomy were excluded. Patients underwent stationary esophageal manometry using an 8-channel water perfused catheter connected to a low compliance pneumohydraulic pump (Multiplex II, Alacer Biomedica, Brazil). The assessment included lower esophageal sphyncter (LES) position and pressure, motility and pressures of the esophageal body and upper esophageal sphyncter pressure. The 24-hour pH study used a dual channel antimony electrode catheter and a logger (AL-3, Alacer Biomedica, Brazil). Demographic data was collected in all patients and the results of the manometry and esophageal pH studies utilized reference values.

Results
One hundred and ninety patients (118 males, 72 females, mean age 41+17 years) were included. Post-intubation stenosis was the cause of airway stenosis in 87% of the patients and 82% had a tracheostomy. Typical GER symptoms were found in 40% of the patients and heartburn was the most prevalent (31%). A hypotonic LES on esophageal manometry was found in 41 patients (21,5%) and 10 (25%) of such patients had supraesophageal reflux on the pH study. Esophageal 24-hour pH studies were performed in 179 patients and showed pathologic acid GER in 75 (41,9%), with a predominance of supine reflux (Table). Supraesophageal acid reflux was detected in 22% of patients with a normal pH study (0,5 episodes/patient; normal value=zero) and in 44% of abnormal pH studies (2 episodes/patient; normal value=zero).

Conclusions
Patients with benign tracheal stenosis in this cohort showed a high prevalence of abnormal acid reflux exposure with a predominance of supine reflux with a high upper esophageal acid exposure. This occurred in a setting of relatively low incidence of typical GER symptoms and in the presence of normal esophageal motility in the majority of the patients. Such findings altogether suggest that GER may have impact in the outcome of tracheal stenosis and deserve further investigation.

Esophageal pH study Parameters	ABNORMAL pH studies (N=75)	NORMAL pH studies (N=104)	*Reference Values (*)*
Total time with pH < 4 (%)	8,9 ± 5,4	1,8 ± 2	*4,5%*
Ortostatic reflux (%)	9,7 ± 7,6	2,4 ± 2,4	*8,4%*
Supine reflux (%)	7,4 ± 7,9	0,9 ± 2,1	*3,5%*
Number of reflux episodes	54,3 ± 27	20,2 ± 15,9	*50*
DeMeester score	36,2 ± 20,5	7,9 ± 0,4	*14,7*
Number supraesophageal reflux	2,0	0,5	0

Average ± standard deviation ; (*) Johnson & DeMeester. Am J Gastroenterol 1974;61:325

id 250

19th WCBIP / WCBE World Congress
JOINT MEETING OF THE WORLD ASSOCIATION FOR BRONCHOLOGY AND INTERVENTIONAL PULMONOLOGY & THE INTERNATIONAL BRONCHOESOPHAGOLOGICAL SOCIETY
www.wcbipwcbe2016.org
Fortezza da Basso
May 8-11, 2016
Florence (Italy)

Virtual bronchoscopic navigation and radial-EBUS for the diagnosis of peripheral lung nodules

Wei Zhang[1], Tawimas Shaipanich[2], Alexander Ritchie[3], Stephen Lam[2]

[1]Department of Integrative Oncology, British Columbia Cancer Research Center & Peking University First Hospital - Canada
[2]Department of Integrative Oncology, British Columbia Cancer Research Center - Canada
[3]Department of Integrative Oncology, British Columbia Cancer Research Center & Royal Brisbane Hospital - Canada

Introduction

The application of Radial-endobronchial ultrasound (R-EBUS) with guide sheath improves the biopsy yields of peripheral lung nodules. However, the navigation of the EBUS probe to the lesion is still challenging for bronchoscopists.

Objective

The aim of this study is to determine if the addition of virtual bronchoscopic navigation (VBN) improves the diagnostic yield of peripheral lung lesions and the factors that might influence the biopsy results.

Methods

Patients who were referred to BC Cancer Agency, Vancouver, Canada for evaluation of peripheral lung lesions underwent R-EBUS guided biopsies. VBN (Lungpoint, Broncus Medical, Inc., Mountain View, CA, USA) was used at the discretion of the bronchoscopist. The diagnostic yields with or without the use of VBN were compared. Multiple logistic regression analyses were performed to identify factors which may impact the results.

Results

R-EBUS biopsies were performed in 141 consecutive patients; 75 with and 66 without VBN guidance. The median size of those lesions was 2.3 (0.9 to 5.9) cm and 3.4 (1.2 to 8.5) cm respectively ($P<0.01$). There was no significant difference in diagnostic yields between the two groups (61.3% versus 62.1% with and without VBN, respectively, $p=0.923$). For lesions with a maximal diameter of <= 2 cm the diagnostic yield was slightly higher with VBN but the difference was not statistically different ($P=0.288$). It was more likely to obtain a positive biopsy if the R-EBUS probe was inserted adjacent to the lesion (OR=2.779, 1.938-133.815) or cannulated into the centre of the nodule (OR=4.162, 8.002-515.416). Other factors such as the type of the nodule (solid, semisolid or non-solid), the location (right or left upper, middle, lower lobe, or difficult segments such as Lb1+2, RB1, or LB6 and RB6) of the nodule or bronchus sign in the CT scan did not affect the results.

Conclusions

R-EBUS with guide sheath improves the diagnostic yield of peripheral nodules if the EBUS probe could be successfully inserted inside the lesions. Since the number of generations of airway visible with VBN is relatively small especially for small peripheral lesions, it does not add information for the biopsy if the bronchoscopist is able to navigate the EBUS probe to the correct location based on findings on the CT scans. The value of VBN in the diagnosis of smaller lesions (<=2cm) requires a larger randomized clinical trial.

id 251

19th WCBIP / WCBE World Congress
JOINT MEETING OF THE WORLD ASSOCIATION FOR BRONCHOLOGY AND INTERVENTIONAL PULMONOLOGY & THE INTERNATIONAL BRONCHOESOPHAGOLOGICAL SOCIETY
www.wcbipwcbe2016.org
Fortezza da Basso
May 8-11, 2016
Florence (Italy)

Tracheal reconstruction of defect in salvage surgery for cervical esophageal cancer

Masahiro Niihara[1], Yasuhiro Tsubosa[2], Katsushi Takebayashi[1], Eisuke Booka[1], Ayako Shimada[1], Tetsuro Onitsuka[3], Masahiro Nakagawa[4]

[1]Division of Esophageal Surgery, Shizuoka Cancer Center - Japan
[2]Division of Esophageal Surgery, Division of Shizuoka Cancer Center - Japan
[3]Division of Head and Neck Surgery, Shizuoka Cancer Center - Japan
[4]Division of Plastic and Reconstructive Surgery, Shizuoka Cancer Center - Japan

Introduction

Main lesions and/or metastatic lymph nodes of cervical esophageal cancer often involve the trachea below the level of the thoracic aperture. Tracheostomy in the anterior mediastinum, as it is called “Grillo’s procedure”, might be accomplished for complete resection. However, the necrosis of the residual trachea is especially prominent in the salvage surgery after definitive chemoradiotherapy and often potentially-lethal.

Methods

A 68-year-old male was being examined during a follow-up of 7 years after definitive chemoradiotherapy for cervical esophageal cancer (Ce cT2N1M0 cStageIIB). Esophagogastroduodenoscopy revealed the ulcerative lesion at 20 cm from the incisor tooth with a diagnosis of local recurrence. The tumor spread the right side of the trachea below the level of the thoracic aperture. The pharyngo laryngo esopagectomy was performed for tumor resection. The defect of the trachea was reconstructed using bilobed deltopectoral flap. This patient made an uneventful recovery except transitory tracheal stenosis and was discharged on postoperative day 19.

Conclusions

The tracheal defect below the level of the thoracic aperture in salvage surgery could be safety reconstructed with bilobed deltopectoral flap avoiding tracheostomy in the anterior mediastinum.

id 252

19th WCBIP / WCBE World Congress
JOINT MEETING OF THE WORLD ASSOCIATION FOR BRONCHOLOGY AND INTERVENTIONAL PULMONOLOGY & THE INTERNATIONAL BRONCHOESOPHAGOLOGICAL SOCIETY
www.wcbipwcbe2016.org
Fortezza da Basso
May 8-11, 2016
Florence (Italy)

Direct visualization of pulmonary nodules under water immersion using ultrathin bronchoscope

Katsuhiko Morita[1], Noriaki Kurimoto[2]

[1]Chest surgery, Japan Community Health care Organization, Shimonoseki Medical Center - Japan
[2]Chest surgery, St. Marianna University - Japan

Introduction
Precise direct observation of a peripheral pulmonary nodule (PPN) is difficult even with ultrathin bronchoscopy due to the accumulation of mucus or collapse of peripheral airways.

Objective
We aimed to demonstrate the impact on the peripheral airway of saline insertion during bronchoscopy.

Methods
At our institution, 20 PPNs were directly observed under water immersion by saline insertion in the peripheral airways using an ultrathin bronchoscope (XP290, 3.1 mm tip diameter, Olympus) under virtual navigation and fluoroscopy between March and November 2015. Once the PPN was directly visualized, the XP290 was slowly withdrawn while memorizing its course, and a thin bronchoscope (P290, 4.2 mm tip diameter, Olympus) was introduced for endobronchial ultrasonography using a guide sheath (EBUS-GS). Direct visualization by insertion of saline in the peripheral airways enabled insertion of the GS probe into the appropriate bronchi even through the thin bronchoscope. Bronchiolar abnormalities on direct observation of the bronchioles in patients with peripheral type pulmonary carcinoma were classified by Tanaka1) into three morphological types: 1) submucosal obstruction type (lesions located below the mucosa of the airway lumen), 2) exposed type (lesions visible in the lumen), and 3) nodal type (polyp-like lesions within the airway lumen). In addition to these types, we proposed 4) pale type without morphological abnormalities (lesion seen through the thin normal bronchiolar wall in the lepidic growth area, occasionally with traction bronchiectasis).

Results
All the PPNs, with mean dimensions of 26.5±9.4 x 21.3±6.9 mm, were revealed to be neoplasms by EBUS-GS (adenocarcinoma in 18 and squamous cell carcinoma in 2). The generation number of bronchioles in which the PPN could be directly visualized was 6.8±1.3 (in this study, subsegmental bronchi were defined as third generation bronchi, and daughter branches were calculated as one branch because of their difficult definition). The directly observed PPNs were classified as submucosal obstruction type in 10 cases (all 10 were adenocarcinomas), exposed type in 2 (both adenocarcinomas), nodal type in 2, (1 adenocarcinoma and 1 squamous cell carcinoma), and pale type in 5 cases (4 adenocarcinomas and 1 squamous cell carcinoma). In one patient with adenocarcinoma, the PPN could not be directly visualized except for bleeding prior to bronchoscopy.

Conclusions
EBUS-GS using a thin bronchoscope after direct observation of the PPN by saline insertion in the peripheral airways for ultrathin bronchoscopy is an easy and reliable diagnostic technique.

Bibliography
1. Tanaka M.: Advances and usefulness of ultra-thin bronchofiberscopes. Keio J Med 1996; 45: 296-300

Endoscopic treatment of malignant tracheobronchial stenoses

Serena Conforti[1], Stefano Fieschi[2], Fiorini Eleonora[2], Marco Reda[2], Alessandro Rinaldo[2], Massimo Torre[2]

[1]thoracic surgery, niguarda hospital - Italy
[2]thoracic surgery division, niguarda hospital - Italy

Introduction

Background: Tracheobronchial obstruction due to malignancy is a life-threatening condition with respiratory distress symptoms. The main problem in improving airway patency in inoperable cases is the Y- shaped configuration of the carinal bifurcation. Airway stent insertion is an effective method of relieving the airway obstruction.

Objective

Objective: Evaluation of a newly developed Y-shaped stent in the palliative treatment of advanced carina and main bronchi cancer.

Methods

Methods: We performed retrospective review of 23 consecutive patients (15 lung and 6 esophageal locally advanced cancers, 1 breast , and 1 kidney metastasis) who underwent placement of self-expandable Y-shaped covered metallic stent for the treatment of malignant tracheobronchial stenosis between August 2010 and November 2015.

Results

Results: All stents were safely and easily placed, under deep sedation, through a rigid tracheoscope under bronchoscopic guidance, within 24 hours of admission. All patients showed immediate benefit after stenting and no major adverse event directly related to the procedure was observed. The actual insertion time required less than 2 minutes; the average time of all procedures was 30 minutes Perioprocedural mortality was 40%. Average mean survival after stent placement was 12,2 weeks.

Conclusions

Conclusion: Placement of Y-shaped self expanding stents is safe and effective procedure for the palliation of malignant trachebronchial stenosis. Currently, this type of stent is our first choice in the treatment of this subgroup of patients.

Bibliography

References: 1. Chen C, et al. Ann Thorac Surg 2008; 85:2100-4. 2.Han XW, et al. J Vasc Interv Radiol. 2008;19:742-47.

id 254

Serratus anterior plane block in Nuss procedure for pectus excavatum surgery

Angelo Raffaele Calini1 Calini[1], Fabio Rubino[2], Maria Pia Gagliardone[1], Alessandro Rinaldo[3], Massimo Torre[3], Marco Reda[3]

[1]thoracic surgery- intensive care unit -cardio thoracic vascular department, niguarda hospital - Italy
[2]thoracic surgery- intensive care unit -cardio thoracic vascular department, Niguarda Ca' Granda Hospital - Italy
[3]thoracic surgery division, niguarda hospital - Italy

Introduction

Pectus excavatum is the most common congenital chest wall deformity1. It represents both an anatomic and functional problem, limiting normal expansion of the lungs and heart. Restrictive/obstructive respiratory patterns, dysrhythmias, mitral valve prolapse, cardiac compression/displacement are the most frequent consequences and represent inclusion criteria for surgical repair. Nuss procedure is the technique of choice for the last couple of decades. It involves creation of a transthoracic, substernal tunnel anterior to the heart, using thoracoscopic guidance, through which a prebent, convex steel bar is inserted, rotated into position to elevate the sternal depression, and fixed securely to the chest wall. Postoperative pain is considerable, making multimodal analgesia the hallmark of postoperative pain control. The thoracic epidural block plays a leading role. Its insertion, however, may be difficult in more immature teenagers and young children. Moreover, hypotension, failed epidural block and epidural hematoma/abscess may be relevant side effects.

Methods

We report a case of a sixteen years old boy underwent to Nuss procedure who received a bilateral Serratus Anterior Plane block (SAP) as intraoperative and postoperative pain management along with intravenous (iv) narcotics and NSAIDs. Since boy's parents opposed to epidural catheter, we proposed this as an alternative to other regional, less effective or more invasive techniques: wound infiltration, selective intercostal nerve blocks and thoracic paravertebral blockade. After the induction, with a linear ultrasound transducer, we identified the fifth rib in the midaxillary line. According to the literature2(Figure 1), we used as landmarks the latissimus dorsi, the theres major and the serratus, and we performed a bilateral single shot bolus of local anaesthetic (Ropivacaine 3.75 %, 15 ml). We preferred a superficial plane approach to the serratus anterior muscle since more effective then the deeper approach2. During surgery, we had a sparing effect on iv narcotics infusion. Before the emergence and extubation, throughout a similar ultrasound approach, we bilaterally inserted a catheter to allow an intermittent bolus infusion (six hourly) of local anaesthetic solution (Ropivacaine 3,75%, 15ml plus Lidocaine 2%, 5ml). Postoperatively we had a successful pain control, registering a Numerical Rating Scale score less than 5. Catheters were removed on day 5 post surgery.

Conclusions

Already used post breast surgery and thoracotomy, we are the first to report the use of SAP for Nuss procedure. We believe that this may be a viable alternative to paravertebral blockade and thoracic epidural analgesia, but this finding must be confirmed in a clinical trial.

Bibliography

1Nuss D, Indications and technique of Nuss procedure for Pectus excavatum. 2010 Thorac Surg Clin 20:583-597 2Blanco R, Serratus plane block: novel ultrasound thoracic wall nerve block. 2013, Anaesthesia 68:1107-1113

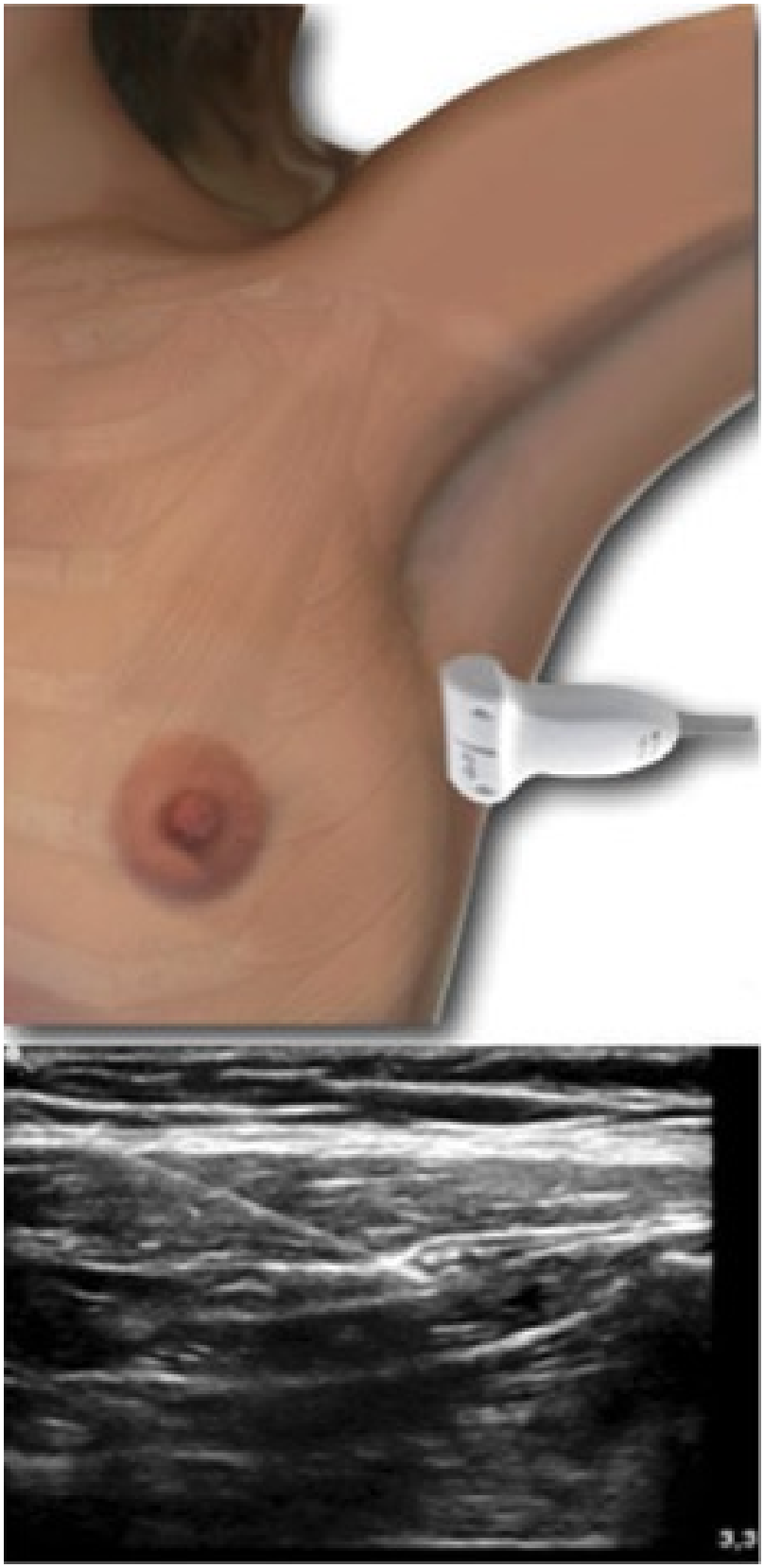

id 255

19th WCBIP / WCBE World Congress
JOINT MEETING OF THE WORLD ASSOCIATION FOR BRONCHOLOGY AND INTERVENTIONAL PULMONOLOGY & THE INTERNATIONAL BRONCHOESOPHAGOLOGICAL SOCIETY
www.wcbipwcbe2016.org
Fortezza da Basso
May 8-11, 2016
Florence (Italy)

Endoscopic stenting of benign and malignant laryngotracheal stenosis

Serena Conforti, Sava Durkovic, Eleonora Fiorini, Stefano Fieschi, Marco Reda, Alessandro Rinaldo

thoracic surgery division, niguarda hospital - Italy

Introduction

Fully covered self-expandable metallic stents (SEMS) are increasingly employed for the management of both benign and malignant airways obstructions. However, at present only limited evidence is available on the real benefits and complications of this treatment modality.

Objective

We describe the clinical outcome of fully covered SEMS placement in patients with malignant and benign tracheal stenosis.

Methods

We retrospectively reviewed the medical records of all patients referred to our department for proximal tracheal stenosis who underwent fully covered SEMS placement between 2010 and 2015. All prostheses were positioned via rigid bronchoscopy. A total of 47 patients were enrolled: 27 males, 20 females, mean age 66.3 years (range 10-89 years). Mean follow-up was 11 months (range 1- months). Data recorded included symptoms at presentation and indication for SEMS placement. The efficacy of the procedure was assessed in terms of its ability to restore tracheal patency and the frequency and type of stent-related complications.

Results

All patients were symptomatic for moderate or severe dyspnea at presentation. Of those, 23 patients had malignant tracheal stenosis and 24 patients had a benign cause of tracheal obstruction. All patients were excluded from surgical resection. No perioperative deaths or complications occurred. In all cases treatment succeeded in restoring tracheal patency and provided immediate subjective symptomatic relief. Mean duration of stent placement was 25 weeks (range 1-154 weeks). The overall post-operative complication rate was 38%. The most common complication was stent migration (n=9), followed by excessive granulation tissue formation at the distal end of the prosthesis (n=8). Restenosis proximal to the stent was observed in one case. Among all patients whit benign disease, complications led to stent removal in 8 cases, 3 of which required tracheostomy.

Conclusions

The present study suggests that fully-covered SEMS are easily placed and removed devices which can provide valuable short-term symptoms palliation and significant improvement of quality of life in patients with tracheal stenosis, especially of malignant origin. However, due to the high rate of long-term complications observed, their use in patients with benign stenosis and long life expectancy appears to be unwarranted. Hence, the optimal management of benign inoperable tracheal strictures remains to be defined.

id 256

Radial mini-probe EBUS guided TBNA and brushing for diagnosis of peripheral lung lesions

Maciej Gnass, Artur Szlubowski

Endoscopy Unit, John Paul II Hospital in Cracow, Jagiellonian University - Poland

Introduction

Endobronchial ultrasound (EBUS) guided transbronchial biopsy techniques are becoming routine for diagnosis of peripheral lung lesions. There are many methods of sampling lesions after their localization. A tissue for histological assessment can be obtained by forceps or kryo- biopsy, but the risk of complications, such as significant bleeding or pneumothorax, seems to be higher while using methods leading to cytological assessment. A diagnosis of peripheral lung lesions should be assessed by the most efficient and safe, but also easy to learn in a clinical practice method.

Objective

The aim of this prospective, observational study was to evaluate the diagnostic yield and safety of the transbronchial needle aspiration (TBNA) followed by brushing of peripherally located lung nodules after their localization with radial endobronchial ultrasound mini-probe (rEBUS mini-probe).

Methods

After systematic evaluation of lung CT-scans radial EBUS mini-probe (UM-S20, Olympus Co, Japan) without disposable guide sheath (DGS) was used to localize the nodule. Within successfully localized lesions TBNA followed by cytological brushing were performed and smears were prepared for cytological assessment.

Results

115 patients (74 males, 41 females), were enrolled to the study. Age median was 68 years (31-85). Median of lesion diameter was 22mm (12-42). Lesions were detected within 99 cases (detection ratio – 86.1%). Whether 8 patients were lost to follow up, in 107 cases cytological diagnosis was established. 66 lesions occurred to be malignant and 41 benign. The median of the time of the procedure was 15 minutes (10-23). Sensitivity, specificity, accuracy, positive predictive value (PPV) and negative predictive value (NPV) for TBNA and brush were calculated separately and when combined. For TBNA values were 75%, 97%, 83%, 97% and 70% respectively. Corresponding values for brush were 56%, 100%, 72%, 100% and 57%. For joined biopsy techniques values were 79%, 97%, 86%, 98% and 73% respectively. There were no statistically relevant differences in sensitivity, accuracy and NPV between TBNA and TBNA combined with brush (P values were 0.159, 0.163 and 0.156 respectively). No serious complications were observed.

Conclusions

rEBUS, without DGS, TBNA with brush guided biopsy is efficient, feasible and safe for cytological diagnosis of peripheral lung lesions. This procedure should be considered as the reasonable alternative for transthoracic approach especially considering its low complication ratio. Brushing lesions after TBNA should not be considered as a standard procedure but may be helpful in selected cases.

	TBNA	BRUSH	TBNA+BRUSH
Sensivity	75%	56%	79%
Specificity	97%	100%	97%
Accuracy	83%	72%	86%
PPV	97%	100%	98%
NPV	70%	57%	73%

id 257

19th WCBIP / WCBE World Congress
JOINT MEETING OF THE WORLD ASSOCIATION FOR BRONCHOLOGY AND INTERVENTIONAL PULMONOLOGY & THE INTERNATIONAL BRONCHOESOPHAGOLOGICAL SOCIETY
www.wcbipwcbe2016.org
Fortezza da Basso
May 8-11, 2016
Florence (Italy)

Airways foreign bodies in children: our experience

Serena Conforti, Durkovic Sava, Marco Reda, Massimo Torre

thoracic surgery division, niguarda hospital - Italy

Introduction

Foreign body aspiration (FBA) is the most common cause of accidental death, usually in children younger than 3 years of age, requiring prompt recognition and early treatment to minimize the potentially serious and sometimes fatal consequences. The symptoms of FBA range from none to severe airway obstruction. In the absence of chocking event, the diagnosis may be delayed for weeks to months and contribute to worsening lung disease. Bronchoscopy remains the definitive method for diagnosis and the therapy of choice for removal.

Objective

The challenge is to avoid mortality. Prevention and public education is the most critical element in reducing morbidity.

Methods

We retrospectively reviewed the clinical records of 43 patients admitted to our Department from 2012 to 2015 for suspected FBA. The following data were collected: sex, age, socioeconomic status, availability of definite history, symptoms, type of FB, anatomic location, radiological and bronchoscopical findings, length of hospital stay and complications. All patients underwent to flexible bronchoscopy for diagnosis and operative rigid technique when FBA was confirmed.

Results

The presence of FB was confirmed in 38 cases; 5 cases were excluded from the study. Of 38 subjects, 25 (65,7%) were male and 13 (34,3%) were female. Most patients (76%) were below 3 years of age, the median age was 3,1 years (2 months-14 years). Choking, coughing, dyspnoea, wheezing and irritability were the most common symptoms. Bronchoscopy showed oedema and granulation tissue in 90% cases and purulent secretions in 15% cases. In 55% of the patients the FB was lodged in the right bronchial tree. In 8 patients (21%) chest X-rays were normal; the most frequent radiological findings were localized air trapping and atelectasis. Of the 38 FB retrieved, 26 (68,4%) were nuts. Removals were performed by rigid bronchoscopy. Majority of patients were discharged the next day of removal; 15 (38%) patients stayed for more than 4 days because of observation, medical treatment or respiratory assistance. No cases of death were recorded

Conclusions

Early recognition through bronchoscopy in suspicion of a FBA is essential to avoid ineffective medical therapy. The prompt management and coordinated efforts between the members of the surgical team will help ensure the child is managed safely and effectively. Patients should be sent to experienced centres. Public awareness through the mass media should draw attention and help prevent FBA.

id 258

VAM and VAMLA for the invasive investigation of mediastinum. A single centre experience

Gabriella Giudice, Rita Marasco, Aniello Della Morte, Cosimo Lequaglie

Thoracic Surgery, IRCCS - CROB Referral Cancer Center - Italy

Introduction

The invasive techniques of mediastinal investigation are gradually improved over time, especially in recent years; this thanks to the considerable technological evolution that led the mediastinoscopy, developed by Carlens in 50's (that allowed the exploration of limited areas of mediastinum) to the execution of extended mediastinoscopies, that arrives to the left nodal stations, as well as loow the complete removal of mediastinal lesions. This techniques, including Video Assisted Mediastinoscopy (VAM), and Video Assisted Mediastinoscopic LimphAdenectomy (VAMLA), not only provide more accurate diagnosis and staging of lung cancer, but also allow to perform surgical resections, even in combination with other techniques of video- surgery.

Objective

To verify effectiveness and feasibility of VAM–VAMLA in our Division of Thoracic Surgery.

Methods

From June 2011 to December 2015, we have observed 84 patients, 72 affected by mediastinal lymphnodes 837 lung cancers, 35 no specified) and 12 mediastinal masses. All the patients are submitted to VAM (38) or VAMLA(46) with diagnostic intent and therapeutic also, in some cases. For the first 14 patients, from 2011, we have used in "naif" mode a 5 mm optics into the classic Carlens mediastinoscope. After, we have purchased the new Linder- Dahan videomediastinoscope (R.Wolfe, Knittlingen,D).

Results

In 12 of 37 patients with lung cancer we have found mediastinal lymphnodes metastases; 17 patients presented lymphnodes affected by other tumors (5 colon - 2 thyroid – 1 prostate – 1 ovarium – 4 HD – 4 NHD); 23 patients were affected by sarcoidosis; 7 removal of mediastinal masses (2 abscesses – 2 thyroids – 3 mesothelial cysts). The mean operative time was 27 + 5 min; operative mortality: 0; major complication: 1 hemorrage for azygos vein lesion; the mean number of lymphnode compartments harvested was 5. The 7 mediastinal lesions have been removed with only the VAM. There were no false negative results in those patients who procedeed to pulmonary resection (25 patients).

Conclusions

Today, many techniques of surgical exploration of the mediastinum are available, for diagnosis, staging and therapy also (VATS, VAM, ECM, TEMLA, VAMLA) and they may be employed alone or in combination. VAM and VAMLA are surely techniques effective and feasible, but the choice depens on the evaluation ofeach clinical case, on the presence of specific diagnostic doubts and on general clinical condition of the patient.

id 259

19th WCBIP / WCBE World Congress
JOINT MEETING OF THE WORLD ASSOCIATION FOR BRONCHOLOGY AND INTERVENTIONAL PULMONOLOGY & THE INTERNATIONAL BRONCHOESOPHAGOLOGICAL SOCIETY
www.wcbipwcbe2016.org
Fortezza da Basso
May 8-11, 2016
Florence (Italy)

Spontaneous suppurative costochondritis in acute lymphoblastic leukemia

Marco Reda, Alessandro Rinaldo, Serena Conforti, Durkovic Sava, Eleonora Fiorini, Stefano Fieschi, Massimo Torre

thoracic surgery division, niguarda hospital - Italy

Introduction

Suppurative costochondritis is a pathology with a chronic course beyond all expectation Cronicity results from the avascular nature of the cartilage which behavour is similar to a foreign body. Meanwhile xyphoid process can promotes controlateral spread. In the past, most chondritis was spontaneous, usually caused by tuberculosis. Nowadays most infections are surgical complications. Occasionally, fungal or bacterial infections may burrow through the chest wall to cause chondritis especially in immunodepressed patients. If uncorrectly treated costochondritis may result demoralizing for patient and surgeon alike.

Methods

We report the case of a 53 year-old caucasian male admitted to hematology dept. for Type B very high risk acute lymphoblastic leukemia (ALL). He underwent three cycles of GIMEMA chemotherapy achieving complete remission after the first cycle. Patient was then scheduled for bone marrow transplant. Soon after completion of chemotherapy patient complained of spontanous pain and tenderness over the left costal arch that extended, during the following weeks, toward the right side. The skin in the region of xyphoid process became inflamed and a spontaneous pus leaking appeared (Figure 1A). Chest CT scan demonstrated signs of bilateral costochondritis with marked perichondrial thickening and an area of cutaneous sinus tract (Figure 1B, black and white arrows respectively). The patient underwent single stage, bilateral costal arch, and xyphoid process resection. Cultures of the surgical specimen were positive for Staphyloccocus warneri and epidermidis, and Aspegillus fumigatus. All gram stains taken intraoperatively were negative.

Conclusions

In a patient with high risk ALL who achieved complete clinical remission, necessitating in a near future bone marrow transplant for cure, the treatment of bilateral suppurative costochondritis must be timely, aggressive and radical. Surgery consists in radical resection of bilateral costal arch and xyphoid process.

Bibliography

1. General Thoracic Surgery 7th edition, authors: Shields, MD, Thomas W.; LoCicero, Joseph; Reed, Carolyn E.; Feins, Richard H.

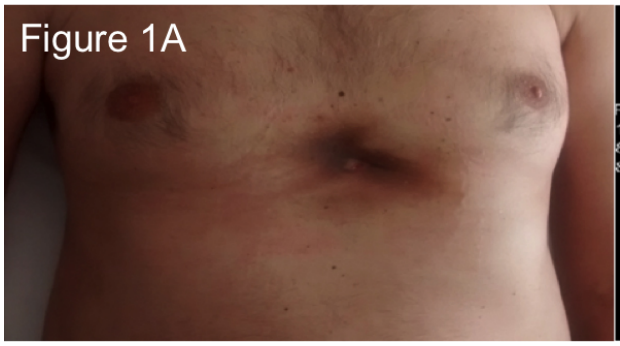

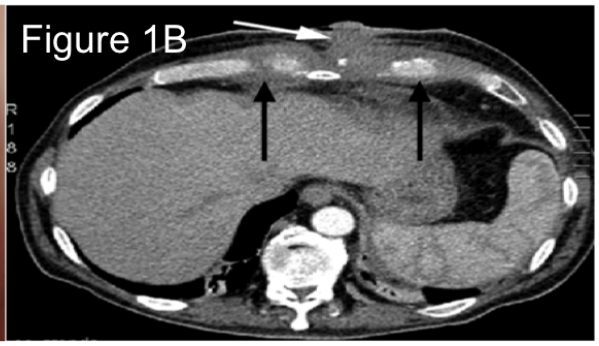

19th WCBIP / WCBE World Congress
JOINT MEETING OF THE WORLD ASSOCIATION FOR BRONCHOLOGY AND INTERVENTIONAL PULMONOLOGY & THE INTERNATIONAL BRONCHOESOPHAGOLOGICAL SOCIETY
www.wcbipwcbe2016.org
Fortezza da Basso
May 8-11, 2016
Florence (Italy)

The past, the present and the future of interventional pulmonology in China

Guangfa Wang

Dept of respiratory and critical medicine, Peking University First Hospital - China

Objective

China is the largest developing country with over 10 billion population. In the past, as the limitation of economy, medical service system lack enough investment. This made the quality of medical service in China was low. Before 1980, there were only few hospitals equipped with rigid bronchoscope which were almost mastered by ENT clinicians. Almost non hospital had fiber bronchoscope. Since 1980, fiber bronchoscope had begun to enter China.

Methods

The fundamental techniques such as brush, biopsy, BAL and TBLB began to be mastered by pulmonologists by large teaching hospitals. In the next 2 decades, the interventional pulmonology developed slowly and were mainly focusing on diagnostic techniques. With the rapid growth of economy since 1990s,bronchoscope began to be equipped by more and more hospitals and some interventional techniques such as metallic stent implantation, electrocautery and balloon dilation began to be used in a few hospitals.

Results

After entering the new millennium, the development of interventional pulmonology in China began to accelerate. The importance of rigid bronchoscope had been reconized by Chinese pulmonologists gradually. APC, cryotherapy and laser began to be used in the management of central airway stenosis. In recent years, silicon stent, valve and thermoplasty was imported in China, as well as EBUS and other diagnostic techniques. Chinese clinicians have some innovations on devices or equipments. Some crucial devices and equipments to IP can be produced in China. Chinese clinician has formed some academic consensus on in some area including benign stenosis management, large hemptysis therapy basing on the condition and researches in China.

Conclusions

Also Chinese pulmonologist have began to establish transthoracic techniques such as microwave ablation, cryotherapy and radioactive particle implantation. Chinese interventional pulmonologist have accumulated more experience in the treatment of some diseases like TB which are more popular in China and other developing countries. Chinese clinicians also have some innovations on devices or equipments. Some crucial devices and equipments to IP can be produced in China. In the future, interventional pulmonology will have a huge demand as the high incidence of chronic airway diseases, lung cancer and other cause central airway diseases. This will provide more opportunity for Chinese interventional pulmonologist to make more contribution to the development of interventional pulmonology. The hot spots will be early diagnosis of lung cancer, palliative therapy of late lung cancer, chronic airway disease treatment and better therapy of benign central airway stenosis as well as interventional therapy of early lung cancer.

id 261

Treatment of recurrent spontaneous pneumothorax in medical thoracoscopy with semi-rigid pleuroscope

Francesca Savoia, Paolo Lucernoni

Interventional Pulmonology, Ca' Foncello Hospital - Italy

Introduction

Spontaneous pneumothorax (SP) is divided into primary SP (PSP) and secondary SP (SSP). PSP involves healthy people. SSP is associated with underlying lung diseases. PSP remains a significant global problem occurring in healthy subjects with a reported incidence of 18- 28/100000 cases per annum for men and 1.2-6/100000 for women. The annual incidence of SSP is about 6 per 100000 in males and 2 per 100000 in females. The therapeutic challenge in the managment of SP is to prevent recurrence, which occurs particularly frequently after second episode. For this reason several procedures have been developed for the treatment of recurrent pneumothorax: insertion of chest tube, chemical pleurodesis via medical thoracoscopy (MT), surgical pleurodesis via thoracotomy or video-assisted thoracoscopic surgery (VATS).

Objective

Traditionally, in Italy, the pneumothorax is managed by thoracic surgeon. In the last ten years our interventional pulmonologists team have gained considerable experience in the management of pleural effusions through MT. For this reason, as suggested by the recent medical literature, that considerered pneumothorax an excellent indication for MT, this procedure was applied to cases of recurrent PS from our team. So, our study wants to analyze the safety, efficacy, cost saving of MT for the treatment of recurrent PS.

Methods

All patients who were hospitalized in our Department from June 2010 to June 2015 for recurrent SP were included in the study. All of them were already treated with insertion of chest tube in the first episode of SP. At the second episode, patients were subjected to MT with semi-rigid pleuroscope and chemical pleurodesis with talc poudrage technique.

Results

13 patients, aged between 17 and 78 were treated in MT: 4 with PPS, 9 with SSP. The procedure was well tolerated with no immediate complications; the chest tube was kept in place for a median of 4 days with a full resolution of the SP in 92% of cases; hospitalization lasted 9 days in median.

Conclusions

Our study confirms that pneumothorax is an excellent indication of MT. This procedure is safe and effective treatment for recurrent SP, as suggested by the recent literature. So this method is to be considered as an alternative to surgical approach, which is more invasive and more expensive. Also in Italy, it should be managed by interventional pulmonologists with proven experience in the MT.

id 262

19th WCBIP / WCBE World Congress
JOINT MEETING OF THE WORLD ASSOCIATION FOR BRONCHOLOGY AND INTERVENTIONAL PULMONOLOGY & THE INTERNATIONAL BRONCHOESOPHAGOLOGICAL SOCIETY
www.wcbipwcbe2016.org
Fortezza da Basso
May 8-11, 2016
Florence (Italy)

New methods for the assessment in endoscopic lung volume reduction with one-way valves for emphysema

Felipe Nominando[1], Paulo F. G. Cardoso[2], Vinicius Torsani[1], Regina C. Pinto[1], Frederico A. Fernandes[1], Cibele Berto[3], Celso R . F. Carvalho[3], Viviane R. Figueiredo[4], Andrea C. Gomes[5], Maria C. Chammas[5], Marcelo B. P. Amato[1], Carlos R. R. Carvalho[1], Paulo M. Pêgo-fernandes[2]

[1]Division of Pneumology, Heart Institute (InCor)-Hospital das Clinicas, Faculty of Medicine, University of Sao Paulo - Brazil
[2]Division of Thoracic Surgery, Heart Institute (InCor)-Hospital das Clinicas, Faculty of Medicine, University of Sao Paulo - Brazil
[3]Department of Physical Therapy, Hospital das Clinicas, Faculty of Medicine, University of Sao Paulo - Brazil
[4]Service of Respiratory Endoscopy, Heart Institute (InCor)-Hospital das Clinicas, Faculty of Medicine, University of Sao Paulo - Brazil
[5]Department of Radiology, Hospital das Clinicas, Faculty of Medicine, University of Sao Paulo - Brazil

Introduction
Assessment before and after endoscopic lung volume reduction with one-way valves (ELVR) for emphysema relies mostly on pulmonary function, exercise capacity and imaging procedures that overlook other parameters such as chest wall motion, volume redistribution within the lungs and diaphragmatic mobility.

Objective
This case series focuses on the use of non-invasive methods approved for clinical use, such as optoelectronic plethysmography (OEP), electrical impedance tomography (EIT) and diaphragmatic mobility by ultrasound (USD) in addition to the assessments used pre and post-ELVR.

Methods
Patients signed an informed consent form. Inclusion criteria were dyspnea MRC>=2; Heterogeneous emphysema (>=15%); post-bronchodilator FEV1<45%, TLC>=100%, RV>=150%, DLCO<=50%. Exclusion criteria were giant emphysematous bulae; asthma; clinically significant bronchiectasis; pulmonary hypertension. Patients underwent pulmonary rehabilitation before and after ELVR. Assessments were performed before and at 1, 3 and 6 months after ELVR. The parameters assessed were: Lung volumetry by CT scan; total body plethysmography; 6MWT; dyspnea and quality of life (MRC and SGRQ); OEP; USD. The EIT analysis was limited to the procedural data. Collateral ventilation (CV) was assessed in the target lobe and one-way endobronchial valves were placed in the target lobe using flexible bronchoscopy under sedation and a laryngeal mask (Chartis; EBVZephyr, Pulmonx, USA).

Results
Six patients were submited to ELVR. Three were excluded from the analysis due to incomplete follow-up data and the other 3 patients (2 females; median age 59±5years) were evaluated. Patients A and C were CV negative on Chartis assessment whereas patient B was CV positive. The left upper lobe was treated in patients A and C, and right upper lobe on patient B. Pulmonary function and SGRQ revealed improvement in patients A and C as opposed to patient B (table). OEP showed that patients B and C presented greater abdominal contribution (>50%) than patient A before ELVR. Patients B and C also demonstrated an increase in the chest wall volumes (>10%) one month after ELVR and both sustained the benefit at 6 months of follow-up. The greatest change in diaphragm mobility was found on patient A at 3 and 6 months (47% and 48%, respectively) regardless the small improvement in pulmonary function. EIT recordings revealed immediate loss of regional aeration (decrease in regional impedance) of the treated lobe on patient A and redistribution of ventilation in all patients during the procedure.

Conclusions
EIT was capable of detecting peri-procedural atelectasis. The assessment of diaphragm mobility and chest wall compartments before ELVR can establish the patient that best benefit from ELVR.

FEV_1 Liters (%)	Before ELVR	1 month	3 months	6 months	SGRQ Points	Before ELVR	1 month	3 months	6 months
patient A	0,72 (31%)	1,15 (42%)	0,91 (33%)	1,01 (37%)	**patient A**	58	43	23	50
patient B	1,16 (41%)	1,10 (36%)	1,03 (34%)	1,02 (33%)	**patient B**	46	43	30	42
patient C	0,66 (28%)	0,79 (34%)	0,80 (34%)	0,77 (33%)	**patient C**	43	27	N/A	36
AVG±STD	0,85±0,2	1,01±0,1	0,91±0,1	0,93±0,1	**AVG±STD**	49±10	37±9	26±10	42±7

The presenting author has the following conflicts of interest that relate to this abstract: *-Disclosure of funding source: FAPESP (Fundação de Amparo a Pesquisa do Estado de Sao Paulo; 2012/00100-2) -Author and co-author are investigators in the Liberate Clinical Trial*

id 263

19th WCBIP / WCBE World Congress
JOINT MEETING OF THE WORLD ASSOCIATION FOR BRONCHOLOGY AND INTERVENTIONAL PULMONOLOGY & THE INTERNATIONAL BRONCHOESOPHAGOLOGICAL SOCIETY
www.wcbipwcbe2016.org
Fortezza da Basso
May 8-11, 2016
Florence (Italy)

Medical thoracoscopy with semi-rigid pleuroscope in the management of pleural effusion

Francesca Savoia, Cosimo Catino, Manuele Nizzetto, Giuseppe Zanardi, Paolo Lucernoni

Interventional Pulmonology, Ca' Foncello Hospital - Italy

Introduction

The medical thoracoscopy (MT) is a useful, safe, effective and convenient procedure in the management of pleural effusion (PE). PE remains free of diagnosis in about 25% of the cases submitted to thoracentesis or percutaneous biopsy. MT allows direct viewing of the pleural cavity, performing biopsies under direct vision and pleural talc. Most operators use the rigid thoracoscope, but it is currently also available a semi-rigid pleuroscope, easy to handle, similar to a video-bronchoscope.

Objective

From seven years our interventional pneumologists team performs MT with the semi-rigid pleuroscope for the management of PE. The aim of this study is to evaluate the safety and the diagnostic yield of all procedures.

Methods

From April 2008 to November 2015 all patients, who accessed at our centre for unilateral PE of unknown origin, underwent to MT . The procedures were performed by two interventional pulmonologists in our endoscopy room with semi- rigid pleuroscope (Olympus LTF-160). During MT pleural parietal biopsies, chemical pleurodesis with "talc poudrage" technique and placement of chest tube were performed.

Results

All the 377 procedures performed were well tolerated, with no complications. The biopsies, performed in 357 cases, documented: 203 (57%) of tumor localization (27% mesotheliomas, 34% lung cancer metastasis, 39% extra-thoracic tumors metastasis); 36 (10%) empyema; 92 (26%) non- specific pleuritis; 13 (3.6%) tuberculosis; 3 (0.8%) chronic systemic inflammatory diseases; 4 (1%) normal pleura; 6 (1.6%) macroscopically infiltrated pleura, not diagnostic at histological examination.

Conclusions

MT with semi-rigid pleuroscope is safe and effective in the management of PE. In fact certain histological diagnosis was obtained in 97% of cases, with similar results described in the literature using rigid pleuroscope. The high number of non-specific pleuritis obtained (26%) is in agreement with the medical literature; perhaps it might be avoidable with more numerous and deeper biopsies, both in the same place and in different pleural locations. Close clinical follow-up is recommended for the possible malignant evolutivity in this subgroup of patients.

id 264

Systematic vs targeted endosonographic staging of lung cancer improves loco-regional nodal staging

Laurence Crombag[1], Jolanda Kuijvenhoven[1], Jos Stigt[2], Christoph Dooms[3], Kurt Tournoy[4], Olga Schuurbiers[5], Daniel Korevaar[6], Peter Bonta[1], Jouke Annema[1]

[1]Respiratory Medicine, Academic Medical Center - The Netherlands
[2]Respiratory Medicine, Isala klinieken - The Netherlands
[3]Respiratory Medicine, University Hospital - Belgium
[4]Respiratory Medicine, OLV - Belgium
[5]Respiratory Medicine, UMCN - The Netherlands
[6]Clinical Epidemiology, Academic Medical Center - The Netherlands

Introduction
Endosonography (EBUS/ EUS) is recommended for mediastinal nodal staging of NSCLC (1). The value of a systematic nodal evaluation vs targeted sampling of suspected nodes based on PET-CT findings is unknown.

Objective
To investigate whether systematic endosonographic staging (i.e. assessment of all nodal stations) results in improved loco-regional nodal staging compared to PET-CT directed assessment (i.e. targeted approach of nodal stations).

Methods
Prospective, international multicentre (n=8) study (SCORE study, ClinicalTrials.gov Identifier: NCT02014324) in patients with (suspected) NSCLC and an indication for mediastinal nodal tissue staging. Prior to endosonography, nodal target(s) were defined based on PET-CT reports. During endosonography, a systematic evaluation of all reachable mediastinal/ hilar nodes by EBUS was followed by systematic EUS-B (EBUS scope in esophagus) and evaluation of paraesophageal mediastinal nodes. Both target nodes (defined beforehand on CT-PET imaging due to increased size (short axis > 10mm) or FDG avidity) as well as nodes with a short axis > 8 mm or those nodes judged to be sonographically suspected were routinely sampled. Surgical staging / nodal dissection at thoracotomy/VATS was the reference standard for nodal negative endosonography findings.

Results
229 patients with (suspected) NSCLC (mean age 65 years, 141 male) were investigated. Final diagnosis was 202 NSCLC, 13 SCLC, 11 benign and 3 other in patients, respectively. The prevalence of mediastinal (N2/3) metastases was 115/229 (50%). In 16 patients (7%) systematic staging resulted in an added value of nodal upstaging in comparison to the targeted approach: N0/N1 to N2 disease (n=6, added value based on lymph node metastasis in station 7 and 4R), single level N2 to multilevel N2 disease (n=7 added value based on lymph node metastasis in station 7,8, 4L and 4R) and N2 to N3 disease (n=3, added value based on lymph node metastasis in station 4L and 7).

Conclusions
Systematic endosonographic staging results in improved loco-regional staging compared to PET-CT directed “hit-and-run” approach and should therefore be the preferred endoscopic staging strategy of NSCLC.

Bibliography
(1) Vilmann P et al. Eur Respir J 2015 Jul;46(1):40-60.

19th WCBIP / WCBE World Congress
JOINT MEETING OF THE WORLD ASSOCIATION FOR BRONCHOLOGY AND INTERVENTIONAL PULMONOLOGY & THE INTERNATIONAL BRONCHOESOPHAGOLOGICAL SOCIETY
www.wcbipwcbe2016.org
Fortezza da Basso
May 8-11, 2016
Florence (Italy)

Vanishing medium bronchus in bilateral lung transplant after ex vivo lung perfusion

Paolo Solidoro[1], Filippo Patrucco[1], Massimo Boffini[2], Riccardo Bonato[2], Francesco Giuseppe De Rosa[3], Mauro Rinaldi[2]

[1]Cardiothoracic Department, Division of Respiratory Medicine, "Città della Salute e della Scienza" Hospital and University of Torino - Italy
[2]Cardiothoracic Department, Division of Cardiac Surgery, "Città della Salute e della Scienza" Hospital and University of Torino - Italy
[3]Medical Sciences Department, Infectious Diseases, "Amedeo di Savoia" Hospital and University of Torino - Italy

Introduction

Airways complications are some of the most important complications occurring during the first year after lung transplantation (LTx). The most severe form of bronchial stenosis reported in literature is the vanishing bronchus syndrome (VBS) when there is the obliteration with atresia of the ostium of a lobar bronchus, usually related to ischemia and infection. Ex-vivo lung perfusion is a novel strategy for lung allograft preservation that keeps the organs at physiological protective conditions but many ex vivo systems work with lungs in supine position and upper regions (medium lobe ang lingula) can have lower perfusion supply, running the risk of a relative ischemia.

Methods

A 45-yr-old man with end-stage interstitial lung disease underwent to bilateral LTx after EVLP. The 4th pod endobronchial examination revealed normal findings with pervious lobar and segmental bronchi; poor sterile endobronchial secretion. The first follow-up TBLB documented an acute A2 rejection and the patient underwent to pulse high dosage steroid therapy. At first spirometric evaluation: FEV1 50%, FVC 47%. He was discharged on 49th pod. During follow-up spirometric values didn't improve. At 3rd month chest CT reported the atelectasis of medium lobe. The fibrobronchoscopy revealed normal findigs with purulent secretions (Figure 1); acute A2 rejection was treated by pulse steroid therapy and immunosuppression shifting from cyclosporine to tacrolimus. Microbiological coltures were positive for Aspergillus fumigatus complex and voriconazole therapy was started. The 6th month CT confirmed the complete atelectasis of medium lobe and the lumen of the middle lobe bronchus was obliterated with presence of scar tissue (Figure 2). Biopsies showed minimum acute rejection A1 and spirometric values were stable (FEV1 48%, FVC 52%). In CT follow-up the middle lobe parenchyma was finally aerated with atelectasis resolution (probably because of collateral ventilation) with endoscopic persistence of obliteration.

Conclusions

Airways complications are one of the most common post-transplantation cause of morbility and death. The causes may be attributed to absence of blood supply to the donor bronchus and time of ischemia. One of the most difficult task during EVLP is keeping the isolated explanted lung edema free in order to increase the performance of the graft. As many ex vivo systems work with lungs in the supine position, upper regions have lower perfusion supply; moreover bronchial perfusion is anatomically guaranteed by bronchial arteries and during LTx this connection is interrupted and not restored. Cases of pre-transplant colonization and post-transplant infection by Aspergillus fumigatus and VBS are reported.

Bibliography

Shah SS, et al. Chest 2006: 130: 236S Kesavan RB, et al. Chest 2007: 132: 595S

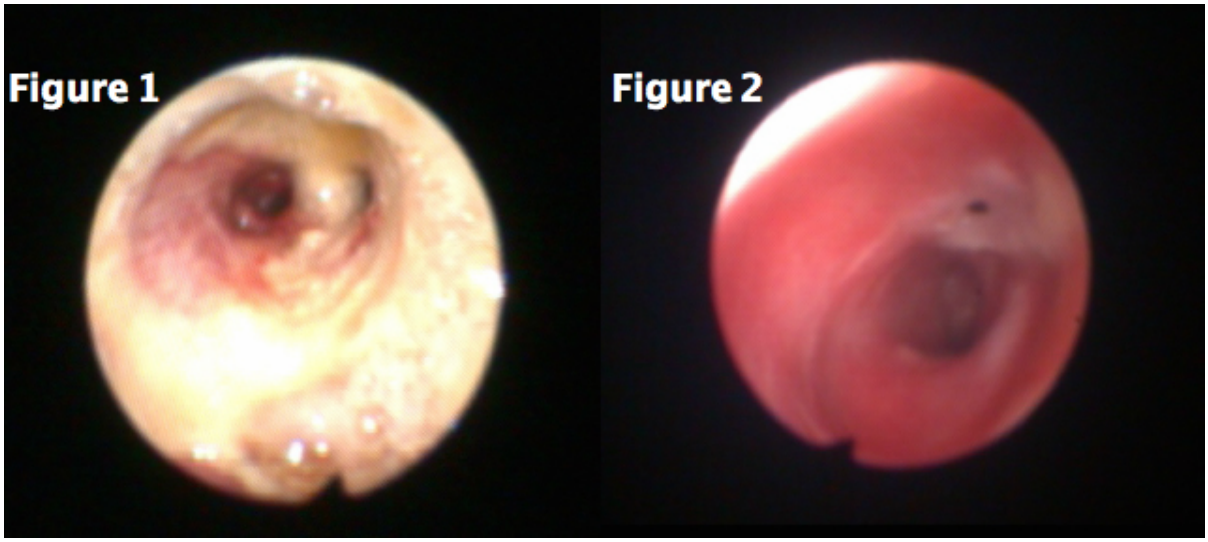

id 266

Foreign Body Aspiration in Adults and Children: an 18-year overview in a Pulmonology Department

Telma Sequeira, Luciana Bento, José Pedro Boléo-tomé, Rui Costa, Fernando Rodrigues

Pulmonology Department, Hospital Prof. Doutor Fernando Fonseca, EPE - Portugal

Introduction

Foreign body aspiration (FBA) is a potentially life-threatening event in children and adults. Flexible and rigid bronchoscopy have become the cornerstone of both diagnosis and treatment of patients with suspected FBA.

Objective

To assess clinical aspects and management of foreign body (FB) removal in adults and children, between 1997 and 2015, in a Pulmonology Department in Lisbon.

Methods

Retrospective study with a cohort comprising 44 patients (22 adults and 22 children). Data were collected from revision of case files.

Results

Adults – 64% of patients were male, with an average age of 67. Concerning risk factors for FBA, 8 patients (18%) had > 75 years, 4 patients (9%) had previous sedative use and one (2%) had a degenerative neurological disease; the remainder 31 patients (71%) lacked obvious risk factors. The nature of the inhaled objects was organic in 82% of cases, with food and small bones being the most frequent. Imaging findings on CT scan and X-ray were frequent (68%), with atelectasis (40%) and radiopaque image (33%) as the most prevalent. In 55% of cases the FB was found in the right bronchial tree, with predominance of mainstem or divisions of right lower lobe bronchus. Rigid bronchoscopy was used for extraction in 19 patients (86%) and flexible bronchoscopy in 3 cases (14%). Granulomas were found in 14 cases (64%), and relapsed in one patient with need of a silicone stent. 68% of patients were revaluated with a bronchoscopic technique (rigid or flexible), on average 59 days after FB removal. Children – Of a total of 22 children, 14 were boys with a mean age of 3 years old. FB were found to be organic in 68% of cases, with a predominance of peanuts and apple pieces; 50% were found on the right bronchial tree. Moreover, 45% of the cases presented X-ray findings, like hyperlucency or consolidation. Rigid bronchoscopy was used in all the cases and presence of granulomas was noted on 8 patients (36%), with only one relapse. Of the 22 children, 7 needed revaluation, on average 23 days after FB removal.

Conclusions

We found a great proportion of organic aspirated material in adults and children (75%), with small bones and peanuts remaining the most commonly aspirated FB. Rigid bronchoscopy was an effective therapy in both groups. Although our series are small, our data did not differ from published literature.

id 267

19th WCBIP / WCBE World Congress
JOINT MEETING OF THE WORLD ASSOCIATION FOR BRONCHOLOGY AND INTERVENTIONAL PULMONOLOGY & THE INTERNATIONAL BRONCHOESOPHAGOLOGICAL SOCIETY
www.wcbipwcbe2016.org
Fortezza da Basso
May 8-11, 2016
Florence (Italy)

EBUS-TBNA for hilar and mediastinal lymphadenopathy in extrathoracic malignancy

Viviane Figueiredo[1], Paulo Francisco Cardoso[2], Márcia Jacomelli[1], Sérgio Eduardo Demarzo[1], Regina Barros[3], Ricardo Mingarini Terra[2]

[1]Division of Respiratory Endoscopy, Heart Institute (InCor), University of São Paulo Medical School, São Paulo - Brazil
[2]Division of Thoracic Surgery, Heart Institute (InCor), University of São Paulo Medical School, São Paulo - Brazil
[3]Department of Pathology, Cancer Institute, Hospital das Clínicas, University of São Paulo Medical School - Brazil

Introduction

Intrathoracic lymphnode metastasis is a common finding in patients with extrathoracic malignancies. Since 30% of extrathoracic malignancies metastasize to the mediastinum, it is imperative to differentiate between inflammatory, infectious and malignant mediastinal lymphnodes prior to planning the treatment strategy. Endobronchial ultrasound with transbronchial fine needle aspiration biopsy (EBUS-TBNA) is a minimally invasive method capable of sampling mediastinal masses, as well as mediastinal and hilar lymphnodes.

Objective

To evaluate the diagnostic efficacy of EBUS-TBNA in mediastinal and hilar lymphadenopathy in patients with extrathoracic malignancies in an endemic setting for infectious conditions such as tuberculosis and fungal diseases.

Methods

Retrospective analysis of the local data bank of EBUS-TBNA. Inclusion criteria were diagnosis mediastinal adenopathy in patients with a confirmed diagnosis of extrathoracic malignancies and mediastinal lymphadenopathy on CT scan and/or PET-CT between August 2011 and October 2015.

Results

Seventy-nine patients with diagnosed extrathoracic malignancies and presenting with mediastinal/hilar lymphadenopathy of unknown etiology were included. EBUS-TBNA identified lymphnode metastases em 35 patients (44%), sarcoidosis in 12 (15%), fungal infection in 3 (4%) and tuberculosis in 2 (3%). Among the 22 patients in which EBUS-TBNA resulted in reactive lymphnode tissue, 3 were considered as false benign (1 confirmed by surgery and 2 by a 6-month long radiology follow-up). Four additional patients were lost to follow up and 15 were either confirmed by surgery (n=7) or followed radiographically (n=8). The remaining 5 patients had inconclusive results due to the scarce or bloody collected material considered (1 lymphnode metastase by surgery and 4 reactive lymphnode by a 6-month long radiology follow-up). There were no complications in this series. In this series, EBUS-TBNA for the detection of lymphnode metastases showed a sensitivity, negative predictive value and accuracy of 81%, 89% e 89% respectively. The overall diagnostic sensitivity of EBUS-TBNA incluing inflammatory and infectious disease was 85%.

Conclusions

EBUS-TBNA was safe and accurate for the diagnosis of mediastinal lymphadenopathy in patients with extrathoracic malignancy.

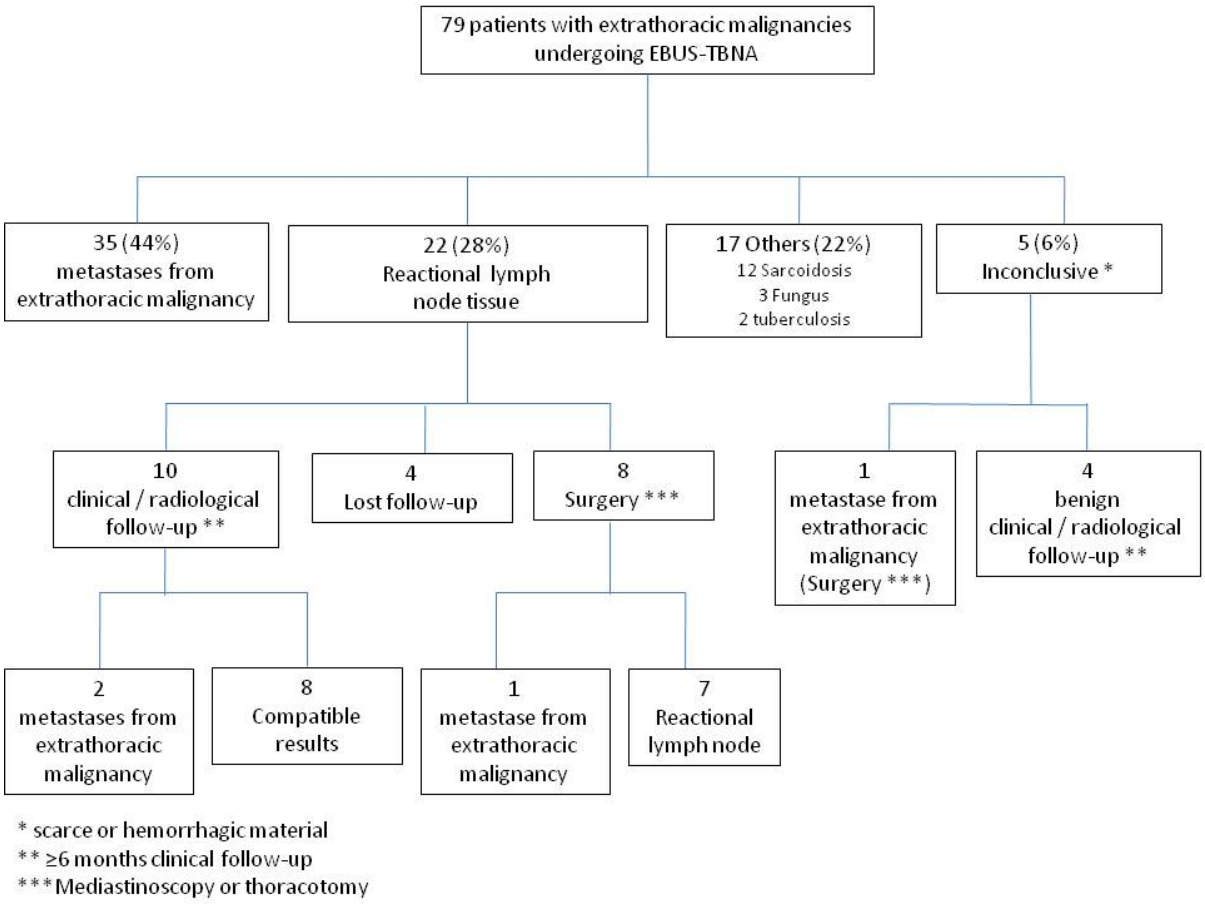
79 patients with extrathoracic malignancies undergoing EBUS-TBNA
35 (44%) metastases from extrathoracic malignancy
22 (28%) Reactional lymph node tissue
17 Others (22%)
12 Sarcoidosis
3 Fungus
2 tuberculosis
5 (6%) Inconclusive *
10 clinical / radiological follow-up **
4 Lost follow-up
8 Surgery ***
1 metastase from extrathoracic malignancy (Surgery ***)
4 benign clinical / radiological follow-up **
2 metastases from extrathoracic malignancy
8 Compatible results
1 metastase from extrathoracic malignancy
7 Reactional lymph node
* scarce or hemorrhagic material
** ≥6 months clinical follow-up
*** Mediastinoscopy or thoracotomy

id 268

Multiple airway carcinoids treated with laser resection

Wojciech Palka[1], Klaus Lessnau[2], Veronica Zeharia[1], Brian Husta[1]

[1]Interventional Pulmonology, Lenox Hill Hospital/ Hofstra University - Usa
[2]Interventional Pulmonary, Lenox Hill Hospital/ Hofstra University - Usa

Introduction
Typical carcinoid tumors of the airway are treated well with either endoscopic or surgical removal. However multiple occlusive airway carcinoids are extremely rare and may pose a management challenge.

Objective
Describe our experience with management of a patient who developed multiple occlusive central airway typical carcinoid tumors with liver and bone metastasis.

Methods
A 64 year old man presented with respiratory failure, hemoptysis and was found to have multiple carcinoids of the tracheobronchial tree with liver and bone metastases. He had been treated with right middle lobectomy, partial right lower lobectomy and partial liver resection. He was found to have carcinoids of the right subglottic trachea, the left midtrachea, two occlusive pericarinal lesions, one right mainstem tumor and three in left mainstem bronchus. The patient was treated during one admission in three sessions. Flexible bronchoscopy with moderate sedation was used, using midazolam and fentanyl. The left lung was treated during the first session, and the right lung was treated two days later. During the third session the left tracheal and right subglottic carcinoids were treated. Neodymium YAG laser with 15-17 Watts and non-contact technique was employed for “painting” to achieve “blanching” but not carbonization of the carcinoids. Parallel-to- wall laser beam positioning was used to avoid perforation. Sandwich technique (layer by layer) from the periphery to the base was used to prevent massive hemorrhage from vascular supply of the base, using 27 Watts. Argon plasma coagulation was used to control residual bleeding bleeding from the tumors bases. A large gastric forceps was helpful to excise the remaining tumors. Rigid bronchoscopy was on standby but not employed. There was no recurrence after eight months of follow up and the patient lives at home without respiratory symptoms. A repeat octreotide scan and bronchoscopy did not reveal tumor in the airway. There was marked improvement of respiratory status, quality of life and weight gain.

Results
Eight months after laser treatment there was no tumor recurrence.

Conclusions
Based on our experience with laser management of typical carcinoids, we observe that Neodymium YAG laser tissue interaction may have potent local antineoplastic activity.

Bibliography
Neyman K. Endoscopic treatment of bronchial carcinoids in comparison to surgical resection: a retrospective study. JBIP. 2015; 22:267-273. Huseyin Erhan Dincer. Pulmonary neuroendocrine tumors: part II. Treatment. JBIP. 2015; 22:351- 356.

The design and validation of a novel Semiautomatic Lung Navigation Platform

Kashif Ali Khan[1], Pietro Nardelli[2], Alex Jaeger[2], Conor O'shea[2], Padraig Cantillon-murphy[2], Marcus Kennedy[3]

[1]Department of Respiratory Medicine, Cork University Hospital/University College Cork. - Ireland
[2]School of Engineering, University College Cork - Ireland
[3]1Department of Respiratory Medicine, Cork University Hospital/University College Cork - Ireland

Introduction

In the era of lung cancer screening, tissue acquisition of peripheral lung lesions remains a challenge. Navigation bronchoscopy systems are novel technologies based on assisted computerized tomography images that guide the bronchoscopist towards the target peripheral lesion.

Objective

We have developed a 3D electromagnetic navigation platform with airway segmentation and virtual bronchoscopy using an open source 3D slicer environment.

Methods

The open source visualisation software (3D Slicer www.slicer.org) created a detailed airway segmentation and virtual bronchoscopy model from acquired CT images. A magnetic field emitter board provides tracking of a semiautomatic locatable sensor probe (SALP) in the working channel of the bronchoscopewith always-on tip tracked sensor and can be steered both manually and automaticaly with joy stick, for accurate localization of peripheral lung lesion. An extensive ex-vivo evaluation was performed in a breathing lung model that was developed using inflatable plasticized pig lungs in a negative-pressure. Following this, in-vivo real time navigation in a live porcine model using a selection of novel radioopaque fiducials placed endobronchially into distal airways.

Results

After completion of a selection of experiments using the breathing pig lung model, fiducials were placed endobronchially in our live porcine model. Thereafter, CT images were used to create a virtual airway 3D segmentation model. After multiplaner re-construction, land mark based registration was performed to align the CT and anaesthetised porcine. Manual and automatic navigation with the bronchoscope containing the SALP was performed (fig 1). The average navigation distance covered was 85.3mm. The navigational system accurately determined 84% of the navigation points within the airways. Figure 1: Electromagnetic Navigation System - live porcine model. A. Standard CT thorax, computer based software provides virtual bronchoscopy images in a multiplaner window (monitor screen). B. An emitter & tracking board (green) creates a magnetic field around the chest (blue). C. The placement of our probe in a flexible catheter allows passage of standard bronchoscopic instruments and biopsy. D. Our research includes the investigation of automation and remote control of our sensor probe and catheter.

Conclusions

In our model, there is good agreement between the position of the sensor probe during bronchoscopic navigation and as visualised in virtual bronchoscopy. The system is at developmental stages, however is distinctive due to being inexpensive and available open source software. Further work is being carried out to improve registration and accuracy of the navigational system before a pilot study in patients with peripheral lung nodules.


A: Computer based Navigation Software
D: Automation
Bronchoscope & EWC (extended working channel)

id 270

Ultrasonography in diagnosis of pneumothorax secondary to lung cryobiopsy in diffuse lung diseases

Luca Viglietta[1], Cristina Pavano[2], Sara Tomassetti[3], Christian Gurioli[3], Claudia Ravaglia[3], Sara Piciucchi[4], Alessandra Dubini [5], Francesco Varone[1], Giuseppe Ugo Di Maria[2], Carlo Gurioli[3], Venerino Poletti[3], Venerino Poletti[6]

[1]Pulmonology, Fondazione Policlinico Universitario A. Gemelli, Università Cattolica del Sacro Cuore - Italy
[2]Pulmonology Unit, Policlinico G. Rodolico, University of Catania - Italy
[3]Pulmonology Unit, Department of Thoracic Diseases, GB Morgagni - L Pierantoni Hospital - Italy
[4]Department of Radiology, GB Morgagni - L Pierantoni Hospital - Italy
[5]Department of Pathology, GB Morgagni - L Pierantoni Hospital - Italy
[6]Department of Respiratory Diseases and Allergology, Aarhus University Hospital - Denmark

Introduction

In the last few years, the classic surgical lung biopsy has been often joined by bronchoscopic lung cryobiopsy (BLC) in diagnosis of diffuse parenchymal lung diseases (DPLD). Our group reported a prevalence of pneumothorax (PNX) after BLC of 23% and it is not related to number and size of specimens [1]. Although routinely used, chest radiograph (CR) has a low diagnostic yield in diagnosis of PNX and chest computed tomography (CT) remains the gold standard. Transthoracic ultrasound (TU) has a greater diagnostic power than CR [2], but its role in detecting PNX secondary to cryobiopsy in interstitial lung disease is not well defined.

Objective

The aim of this study is to compare CR and TU detecting PNX in patients with diffuse lung disease who underwent BLC.

Methods

We prospectively enrolled 26 patients (clinical features in table 1) with a diagnosis of DPLD who underwent BLC at our center in September and October 2015. BLC was performed in deep sedation, by intubation with rigid tracheoscope. Three hours after biopsy patients underwent TU and subsequent postero-anterior CR in orthostatic position in inspiratory and expiratory phase. TU was performed by two blinded pneumologists on patients in supine position detecting, with linear probe, lung sliding and comet tail signs from paravertebral to media axillar line in apical, medial and basal thoracic regions. Two blinded radiologists read CR.

Results

PNX was detected by radiologists in 6/26 patients (23%). Chest tube was placed in two patients that were symptomatic (chest pain) and had CR PNX depth > 2 cm. Sensitivity of TU detecting PNX was 83% (95% confidence intervals (CI) 63-94%), specificity 85% (95%CI 65-95%), positive predictive value 63%, (95%CI 42-80%), negative predictive value 94% (95%CI 76-99%). There was a perfect concordance between radiologists (k=1) referring CR and pulmonologists (k=1) in TU. Three cases were false positive PNX but one of them developed PNX the day after cryobiopsy. We cannot exclude that CT in these cases may reveal PNX that CR does not detect; therefore we are implementing protocol performing CT when there is a discrepancy between data.

Conclusions

This study shows that UT in PNX detection is feasible with a very high concordance between observers. The high negative predictive value suggests that CR may be avoided in cases with negative UT.

Bibliography

1. Poletti V, et al. Respirology 2014; 19:645–654 2. Ding W, et al. Chest 2011; 140:859-66

Patients' clinical features	
N° Tot	26
Age (years)*	64±11
M/F	9/4
BMI (kg/m2)*	27±4
VC (%)*	85±15
FVC (%)*	82±15
FEV1 (%)*	88±16
DLCO (%)*	56±17
SpO2 (%)*	95±3

* (mean value±SD)

id 271

19th WCBIP / WCBE World Congress
JOINT MEETING OF THE WORLD ASSOCIATION FOR BRONCHOLOGY AND INTERVENTIONAL PULMONOLOGY & THE INTERNATIONAL BRONCHOESOPHAGOLOGICAL SOCIETY
www.wcbipwcbe2016.org
Fortezza da Basso
May 8-11, 2016
Florence (Italy)

Clinical and Sonographic Features According to EGFR mutation in Lung Adenocarcinoma by EBUS-TBNA

Young Min Lee

Pulmonary Dept. of Medicine, Busan Paik Hospital , Inje University - South Korea

Introduction

Endobronchial ultrasound-guided transbrochial needle aspiration (EBUS-TBNA) has become the standard minimally invasive modality with a high diagnostic yield for mediastinal staging of non-small cell lung cancer (NSCLC). The presence of EGFR mutation in advanced lung adenocarcinoma correlated with a good response to tyrosine kinase inhibitors.

Objective

The aim of this retrospective study was to assess the clinical characteristics and sonographic features according to EGFR mutation for advanced lung adenocarcinoma diagnosed by EBUS-TBNA.

Methods

From January 2011 to December 2014, 75 patients with advanced lung adenocarcinoma (ADC) diagnosed by EBUS-TBNA were enrolled. For each EBUS-TBNA sampling, we documented patient's characteristics, sonographic findings. 70 patients with ADC were tested for EGFR mutation by PCR and sequencing. The EBUS findings were categorized according to lymph node size, shape, margin , echogenicity, necrosis sign, matting and vascular patterns

Results

Somatic mutations of the EGFR gene were detected in 20 (40%) out of 70 patients in ADC (8 men and 12 women) and EGFR mutations in 50 (60%) were negative (35 men and 15 women). In smoking history, nonsmokers were 16 (80%) in EGFR (+) ADC and 8 (16%) in EGFR (-) ADC. CEA shows 24.5ng/ml in EGFR (+) , 41.6 ng/ml in EGFR (-) . Correlations between cytology and histopathology of EBUS sample were in 14(70%) in EGFR (+), 38(76%) in EGFR (-). The clinical staging shows stage III 3 (15%), stage IV 17(85% : IVa 41%, IVb 44%) in EGFR (+) and stage III 10 (20%), stage IV 40 (80% : IVa 28%, IVb 52%) in EGFR(-). 7 stage IVa EGFR (+) ADC pts have all malignant pleural effusions. The SUVmax of lymph node in PET-CT shows 6.1 (3.8-22) in EGFR (+) and 15.3 (4.1-26) in EGFR(-). In women group, SUVmax shows 5.2 (EGFR postive) vs 14.1 (EGFR negative) ($P<0.05$). A total 140 lymph nodes were analysed , the station 4R and 7 lymph nodes were frequently observed 85% in EGFR (+) , 88% in EGFR (-). In sonographic findings, the mean lymph node short axis diameters were 14.4mm in EGFR (+), 17.5mm in EGFR (-). In different EBUS image characteristics, a significant difference was found in presence of matting between EGFR (+) (45%) and EGFR(-) (76%) ($P<0.05$).

Conclusions

EBUS-TBNA is a effective procedure to evaluate for EGFR somatic mutation in advanced lung adenocarcinoma and EBUS feature of lymph nodes may be helpful in 1st line targeted therapy for lung adenocarcinoma.

id 272

19th WCBIP / WCBE World Congress
JOINT MEETING OF THE WORLD ASSOCIATION FOR BRONCHOLOGY AND INTERVENTIONAL PULMONOLOGY & THE INTERNATIONAL BRONCHOESOPHAGOLOGICAL SOCIETY
www.wcbipwcbe2016.org
Fortezza da Basso
May 8-11, 2016
Florence (Italy)

Endobronchial Tuberculosis (EBTB) Diagnostic Using Flexible Bronchoscopy (FB) (A Case Report)

Prasenohadi Pradono

Department of Pulmonology and Respiratory Medicine. Persahabatan Hospital., Faculty of Medicine, University of Indonesia - Indonesia

Introduction

EBTB is an inflammation of the bronchial walls caused by tuberculous infection. The diagnosis is established by culture of a mycobacterium from bronchoscopic biopsy material. The clinical, radiologic, and bronchoscopic presentation of EBTB is nonspecific, and it can easily be confused with common pulmonary disorders.

Methods

A 26 year-old woman with a history of hoarseness, sometimes with nonproductive chronic cough, breathlessness, and chest pain was admitted to the hospital. No symptoms of night sweats, hemoptysis, or weight loss, and she had no history of contact with tuberculosis. Her vital signs were under normal values also the physical examination were unremarkable. Chest X-ray showed left hilar consolidation. The patient underwent a diagnostic FB, which showed cicatricial lession complete occlusion of the superior segment of the left lower lobe by a mucosal sessile fleshy lesion. Smears from bronchial washings were negative for acid-fast bacilli or other organisms. Biopsy specimens of the endobronchial lesion revealed multiple necrotizing granulomas without evidence of malignancy. Pathologic results of transbronchial biopsy specimens were positive for tuberculosis.

Conclusions

EBTB is a rarely reported disease that can mimic a variety of pulmonary disease processes. A high index of suspicion is necessary when making the diagnosis, especially in infiltrate-negative cases, diagnostic bronchoscopy with bronchial washings and endobronchial biopsies for acid-fast bacilli, and initiation of antituberculous therapy should be performed in the appropriate clinical setting.

id 273

Building up an algorithm for probability estimation of mediastinal involvement in NCSLC

Loris Ceron[1], Lucio Michieletto[1], Simone Perandini[2]

[1]Dept of Medicine, Pulmonology Unit, Ospedale dell'Angelo - Italy
[2]Dept of Radiology, Azienda Ospedaliera Universitaria Integrata - Italy

Introduction

It is well known that sensitivity and specificity represent two robust intrinsic characteristics of a test, unrelated to the quality of the sample, but of limited utility in clinical practice, as they cannot solve the crucial issue of interpreting the result of a diagnostic test. What completely satisfies the need for knowing the chances of a given diagnosis starting from a given test result is its positive or negative predictive value; the latter can be calculated when the prevalence of the disease being studied is known. The vast majority of literature proposed approaches to mediastinum considers more or less implicitly the “a priori” probability that a given lung cancer causes mediastinal metastasis, stating when the same situation (i.e. a negative PET or cytology) can be considered conclusive for the surgical decision, or conversely requires further examinations due to high probability of unexpected mediastinal metastasis. No work, to our knowledge, ever tried to integrate the performance of all diagnostic tests and lung cancer negative prognostic factors to build up one synthetic model where the evaluation of negative results is not absolute, but is related to the predictive value of the test.

Objective

We have suggested a mathematical model by using Bayes’ theorem, which enable us to predict the probability of nodal metastasis after a certain number of diagnostic procedures has been performed, giving us a simple way to evaluate, on the basis of the final probability, when a patient can undergo surgery or conversely further investigations are required [1].

Methods

The mathematical algorithm was the base for the development of a software that allows an instant approach to the decision analysis in mediastinal staging. The entire project (background, modeling, references and software) was then published in a web site (www.messiaproject.com); this allows an extended use of the calculator and the collection of data for statistical purpose.

Results

The expected result is a simple and rational, statistics-based tool to approach mediastinal staging in lung cancer.

Conclusions

We have developed a computer program that enables an instant approach to mediastinal evaluation in different clinical-radiological situations; the final value indicates when surgical threshold is reached or further investigations are required. The Bayesian calculator can be found and used in an internet site (www.messiaproject.com); after single user’s registration, processed data can be sended to a database, therefore permitting an “on line” multicenter study for the validation of the method.

Bibliography

1. Ceron L, Michieletto L, Zamperlin A, Mancino L. The Challenge of Mediastinal Staging. European Oncology & Haematology 2011;7(1):31-35

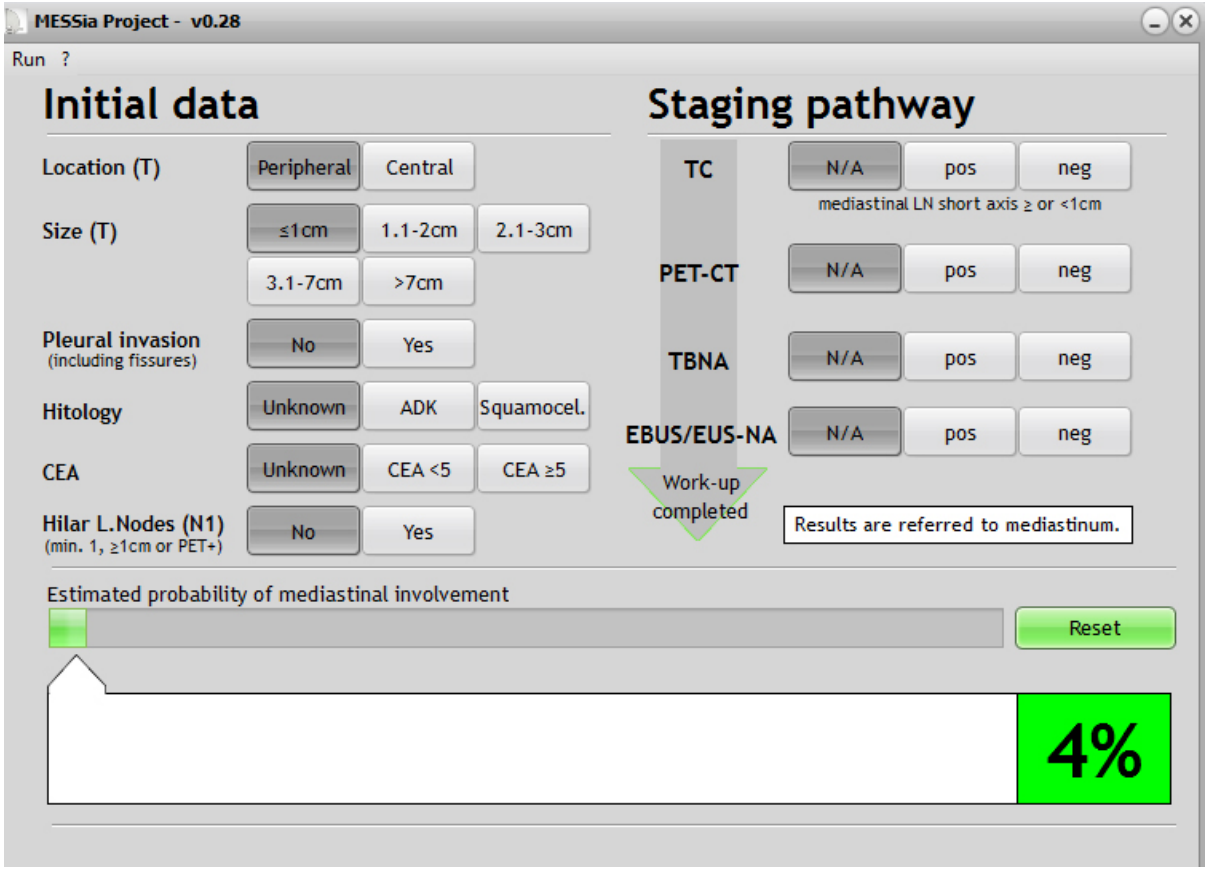
MESSia Project - v0.28
Run ?
Initial data
Location (T)
Peripheral
Central
Size (T)
≤1cm
1.1-2cm
2.1-3cm
3.1-7cm
>7cm
Pleural invasion
(including fissures)
No
Yes
Hitology
Unknown
ADK
Squamocel.
CEA
Unknown
CEA <5
CEA ≥5
Hilar L.Nodes (N1)
(min. 1, ≥1cm or PET+)
No
Yes
Staging pathway
TC
N/A
pos
neg
mediastinal LN short axis ≥ or <1cm
PET-CT
N/A
pos
neg
TBNA
N/A
pos
neg
EBUS/EUS-NA
N/A
pos
neg
Work-up
completed
Results are referred to mediastinum.
Estimated probability of mediastinal involvement
Reset
4%

id 274

Transbronchial re-biopsy protocol for peripheral pulmonary lesions after recurrence of EGFR-TKI

Shinji Sasada[1], Takehiro Izumo[2], Keiko Ohgino[1], Masaki Miyazaki[1], Saeko Takahashi[1], Yuji Matsumoto[2], Takaaki Tsuchida[2], Morio Nakamura[1]

[1]Department of Respiratory Medicine, Tokyo Saiseikai Central Hospital - Japan
[2]Department of Respiratory Endoscopy, National Cancer Center Hospital - Japan

Introduction
EGFR-TKI in patients with EGFR mutation-positive non-small-cell lung cancer respond, but recurrence by acquired resistance such as EGFR-T790M mutation, activation of the collateral route, conversion to small cell carcinoma, etc. Recently, the third generation EGFR-TKI for EGFR-T790M mutation was found to exhibit survival advantage, tumor sampling after recurrence (re-biopsy) becomes essential. Since re-biopsy of peripheral pulmonary lesions is recognized difficult, sampling procedure (bronchoscopy, CT-guided needle biopsy, or surgery) is selected depending on the lesion characteristics. However, bronchoscopy for peripheral pulmonary lesions may uncertain compared to CT-guided needle biopsy and surgery. In addition, tumor tissue biopsy after EGFR-TKI treatment is often difficult according to the fibrotic change.

Objective
To improve the tumor sampling ability for peripheral pulmonary lesions, we proposed transbronchial re-biopsy protocol by bronchoscopy.

Methods
Create thin-slice CT image and additional PET if possible; read affected bronchus on CT image or create virtual bronchoscopy; apply enough sedation during bronchoscopy; detect the lesion by endobronchial ultrasound with a guide sheath (EBUS-GS); add rapid on-site cytology evaluation (ROSE) on first forceps biopsy specimen; continue forceps biopsy if ROSE positive; add transbronchial needle aspiration (TBNA) through GS if ROSE negative and repeat forceps biopsy from the further lesion; fix specimens separately and submit positive tissue sample for gene analysis.

Results
Representative case is sixty-seven-years-old male who has right upper lobe adenocarcinoma accompanied with brain metastasis after recurrence of third- line treatment of afatinib, who underwent bronchoscopy under re-biopsy protocol. The analysis of tissue sample from peripheral pulmonary lesion revealed EGFR-T790M mutation.

Conclusions
In tumor sampling for peripheral pulmonary lesions after recurrence, it deems necessary by standardized procedure that consistent quality is maintained. The transbronchial re-biopsy protocol by bronchoscopy may be possible to maintain a constant quality.

Bibliography
Jänne PA et al. N Engl J Med 2015; 372: 1689-99

19th WCBIP / WCBE World Congress
JOINT MEETING OF THE WORLD ASSOCIATION FOR BRONCHOLOGY AND INTERVENTIONAL PULMONOLOGY & THE INTERNATIONAL BRONCHOESOPHAGOLOGICAL SOCIETY
www.wcbipwcbe2016.org
Fortezza da Basso
May 8-11, 2016
Florence (Italy)

Benefit of bronchoscopy in andean pediatric hospital: initial experience

Maria Eugenia Arauz-martinez[1], Ximena Villalva-valencia[2], Sonia Zumarraga-falcon[3], Adriana Jativa-cruz[2], Sandra Gabriela Zambrano-palma[4]

[1]Neumology/Endoscopy, Pediatric Hospital Baca Ortiz - Ecuador
[2]Laboratory, Pediatric Hospital Baca Ortiz - Ecuador
[3]Pathology, Pediatric Hospital Baca Ortiz - Ecuador
[4]Neumology, Pediatric Hospital Baca Ortiz - Ecuador

Introduction
In our country there are few public pediatric hospitals with bronchoscopy section and their experience is have not been published yet.

Objective
To describe our initial experience at rigid and flexible bronchoscopy and utility of bronchoalveolar lavage (BAL) in a public pediatric tertiary referral hospital located at high altitude.

Methods
Prospective, cross-sectional study. Period: February/2014 to January/2016. Data base of Pediatric Hospital Baca Ortiz. Rigid bronchoscopes 3.0x5.0x26 to 30 and flexible videobronchospe 5.4.

Results
124 procedure in 110 patients were performed. Age (years): mean 3 (r: 0.08- 17). Weight (kg): mean 9 (r: 3-53). We performed 42 (33.8%) rigid and 82 (66%) flexible bronchoscopies. Immunocompromised patients: 20 (18.2%) and immunocompetent ones: 90 (81.8%). The main diagnoses that motivated bronchoscopy were: nosocomial pneumonia 39 (31.4%), bronchiectasis 20 (16.1%) of which 5 cystic fibrosis patients received instillation of alfadornasa, persistent atelectasis 18 (14.5%) and foreign bodies 12 (9.6%). Brochoalveolar lavage: 110 (88.7%) with rigid and flexible probe, of which 84 (75.2%) were positive for bacteriological, fungal or parasites. Main bacteria: Pseudomonas aeruginosa (35.7%), Serratia marcescens (16.6%), Klebsiella pneumoniae (13%), Acinetobacter baumanni (8,3%). Fungal (11.9%): Candida albicans, Candida tropicalis and Histoplasma. Parasites: bronchopulmonary myiasis. All sample were representative. Mortality: 0. Major complication: 2 (1.6%).

Conclusions
In our hospital, both rigid and flexible bronchoscopy were very useful, serves as a therapheutic tool and also for etiologic diagnosis. Rescue microorganism in the bronchoalveolar lavage was high and determined change of conduct medical with good results. Our complication rate is low, similar to that reported by other groups.

Bibliography
Rodríguez Martínez C, et al. Arch Bronconeumol 2003; 39:501-6. Woodhull S, et al. J Bronchology Interv Pulmonol 2010;17:136-41.

19th WCBIP / WCBE World Congress
JOINT MEETING OF THE WORLD ASSOCIATION FOR BRONCHOLOGY AND INTERVENTIONAL PULMONOLOGY & THE INTERNATIONAL BRONCHOESOPHAGOLOGICAL SOCIETY
www.wcbipwcbe2016.org
Fortezza da Basso
May 8-11, 2016
Florence (Italy)

Apnea detection by capnography monitoring during bronchoscopy in sedation with midazolam

Tsukasa Ishiwata[1], Kenji Tsushima[1], Mai Fujie[2], Kenichi Suzuki[1], Kosuke Hirota[1], Mitsuhiro Abe[1], Naoko Kawata[1], Jiro Terada [1], Koichiro Tatsumi[1]

[1]Department of Respirology, Chiba University - Japan
[2]Medical Equipment Control Center, Chiba University Hospital - Japan

Introduction

Midazolam is a short-acting benzodiazepine hypnotic that is commonly used to achieve minimal to moderate sedation for anxiolysis and a depression of consciousness during bronchoscopy. Midazolam, however, has a potential risk of respiratory depression. Although some hypoxic events are detected by pulse oximetry, the actual frequency of apnea events during bronchoscopy has not been fully examined. We used capnography in this study, which is a measurement of CO2 concentrations in expired air, to detect an absence of airflow.

Objective

The purpose of this study was to examine the frequency of respiratory depressions by capnography in minimal to moderate sedated patients with midazolam during diagnostic bronchoscopy. This was a single-center retrospective observational study.

Methods

From April to December 2015, 86 consecutive patients for diagnostic bronchoscopy were retrospectively reviewed. The bronchoscope was inserted through the mouth. Midazolam was administered by an intravenous bolus injection with a start dose of 1- 3 mg and an additional dose of 0.5-1 mg as needed for minimal to moderate sedation.?The Capnostream 20P monitor (Medtronic, Ireland) was used for capnography to detect apneas, in addition to standard monitoring consisting of an electrocardiogram, heart rate, blood pressure and pulse oximetry. Capnography data were collected through an endoscopic bite block combined with a cannula that is designed to sample expired air for a continuous measurement of CO2 during O2 delivery. Apnea was defined as the absence of airflow for at least 10 seconds. All patients received a flow of 2L O2/min with a nasal cannula and the oxygen flow increased when SpO2 fell below 90%. A SpO2 decline (?SpO2) >= 4% from baseline was defined to be significant in this study.

Results

One hundred and fourteen apnea events following a bolus injection of midazolam were observed in 50 patients (58.1%). The median duration time of apnea was 32 seconds (interquartile range (IR) 24 to 46). Significant declines in SpO2 (?SpO2 >= 4%) occurred in 35 apnea events (30.7%); ?SpO2 ranged up to 13% (median 3; IR 2 to 5). The median time-lag between the apnea event and the detection of ?SpO2 >= 4% was 31 seconds (IR 28 to 42).

Conclusions

Apnea events detected only by means of capnography can occur after an intravenous bolus injection of midazolam during diagnostic bronchoscopy. Monitoring with capnography is able to detect apnea events leading to SpO2 decline prior to a change in pulse oximetry and may minimize the risk of complications associated with midazolam sedation.

id 278

A pilot study of a new Chinese nitinol alloy airway stent deployed system through bronchoscope

Junhong Jiang Jiang, Jingyu Mao Mao, Jianan Huang Huang

Department of Respiratory medicine, the First Affiliated Hospital of Soochow University - China

Introduction

Nitinol alloy airway stents are widely used for treatment of both benign and malignant airway obstructions. At present the airway stents are usually deployed under fluroscope guidance with flexible bronchoscope or led by conduct wire through bronchoscope, which will take time or unnecessary exposure to X-ray. We designed the airway stent (through the scope ,TTS?and stent release system directly through the bronchoscopy, and observed its clinical feasibility.

Objective

To assess the efficacy and safety of new Chinese nitinol alloy stent deployed through the flexible bronchoscope.

Methods

15 consecutive patients requiring tracheobronchial stent placement with inoperable malignant airway stenosis were observed in this pilot study. A new TTS stent was used and efficacy of symptom relief assessed by changes in dyspnea (WHO index). All patients?14patients of dyspnea grade ?and 1 patient of grade ?? presented with severe dyspnea. The deployed stents related complications and adverse reactions were recorded.

Results

Between January 2015 and December 2015, twenty TTS (19 uncovered, 1covered) were inserted in 15 patients (11 men and 4 women; median age of 56 years) with inoperable malignant airway stenosis using a flexible bronchoscope under both general anesthesia?7 laryngeal mask, 5 tracheal intubation ?and 3 local anesthesia. 10 cases were primary lung cancer (6 cases squamous carcinoma, 4 cases adenocarcinoma), 1 case had metastatic thymic carcinoma and 4 cases had esophageal cancer. Five stents were placed in the trachea (16 to 18 mm * 30 to 60 mm), seven in the left main stem bronchus (12 mm * 20 to 30 mm), second in the bronchus intermedius (12 mm *20 mm),and six in the right main stem bronchus (12mm * 20 to 40 mm). One of the left main bronchus stent was placed in patient with esophageal cancer , for esophagotracheal fistula after radiation treatment, original uncovered stents was taken out and reset with covered TTS. Twenty stent were successful released directly through 2.8 mm working channel bronchoscope, the location of stent was properly. Operation related complications and remarkable adverse reactions were not found in this study. The dyspnea index improved significantly after implantation.

Conclusions

The new airway stent and release system are effective and safe in relieving dyspnea caused by stenotic lesions of the central airway due to malignant tumor, especially this new stent release system has the advantages for simplified operation, easier manipulation, less time and accurate location of stent .

id 280

Use of FNAB through TBNA in the diagnosis of mediastinal Tuberculosis

Francesco Bini[1], Giuseppe Pepe[1], Giorgio Terzuolo[1], Franca Di Nuovo[2], Chiara Bianchi[2], Noemi Grassi[1], Giorgio De Bernardi [1], Chiara Papetti[1], Adriano Vaghi[1]

[1]Respiratory Disease, ASST Rhodense - Italy
[2]Pathology Unit, ASST Rhodense - Italy

Introduction

We report the case of a 48-year-old Pakistani patient that arrived at the Emergency Room for a fever and syncope, worsened by atrial fibrillation. Past medical history showed a significant weight loss of 20 kilos over four months, in the absence of comorbidity.

Objective

Objectives: Pleomorphism and Mycobacterium Tubercolosis; multidisciplinary approach TBNA: transbronchial needle aspiration FNAB: fine needle aspiration biopsy

Methods

Clinical and instrumental examinations of the chest showed a significant pericardial effusion, a solid mediastinal lesion, which was uneven, bullous- like, 6.5 cm in diameter, extending from the subcarinal area along the right side wall of the esophagus, associated with enlargement of mediastinal lymph nodes, without any lung parenchymal lesions. The patient was then transferred to the Department of Respiratory Diseases where he underwent: 1) global body PET which showed mediastinal involvement with widespread bone absorption, 2) videobronchoscopy with TBNA of the mediastinal lesions and 3)bronchoaspiration of the whole bronchial tree.

Results

Cytology exams of bronchoalveolar lavage, negative for malgnant tumor cells, but compatible with Tuberculosis infection, showed the presence of multinucleated giant cells of Langhans-type, surrounded by epithelioid cells, lymphocytes and necrobiotic-like substance, containing Candida and Aspergillus mycelial hyphae. The Tuberculosis was later confirmed by targeted microbiological investigations and histological exam of the tissue specimen of mediastinal lymph nodes taken during TBNA procedure that had shown the presence of a necrotizing granulomatous giant-cellular inflammatory process with caseous necrosis. Tuberculosis treatment was then provided with prompt remission of symptoms and rapid improvement of clinical conditions.

Conclusions

We report this clinical case to show how peculiar and complex tuberculosis onset may be, especially in extra-pulmonary forms. In these cases cytology tests can certainly facilitate the correct diagnosis. FNAB, a technique of rapid execution that allows to aspirate a quantity of material also useful to perform bacterial culture, together with cytology exams and a right multidisciplinary approach, can help diagnose the disease in a quick and appropriate manner, thus saving further clinicalinstrumental investigation costs.

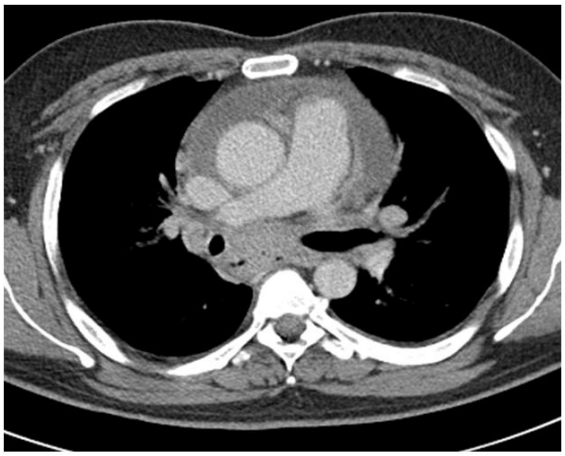

id 281

19th WCBIP / WCBE World Congress
JOINT MEETING OF THE WORLD ASSOCIATION FOR BRONCHOLOGY AND INTERVENTIONAL PULMONOLOGY & THE INTERNATIONAL BRONCHOESOPHAGOLOGICAL SOCIETY
www.wcbipwcbe2016.org
Fortezza da Basso
May 8-11, 2016
Florence (Italy)

Catamenial pneumothorax

Alessandro Rinaldo, Sava Durkovic, Stefano Fieschi, Serena Conforti, Marco Reda, Fiorini Eleonora, Massimo Torre

thoracic surgery division, niguarda hospital - Italy

Introduction

Catamenial pneumothorax is a rare clinical condition whose managment is based on medical evidence coming from small case series. Modern management entails surgery preferably by VATS and hormonal ovarian supression(1).

Methods

Case report 1: A 46 year old female underwent in another hospital right video-assited thoracoscopic resection of the apical lung for recurrent pneumothoraces in the January of 2015. The final pathological exam demonstrated the presence of bullous emphysema. The first subsequent recurrence occured three months later. The CT scan of the chest demonstrated small liver herniations in the tendinous portion of the diaphragm (Fig 1a). The patient underwent right posterolateral thoracotomy through the seventh intercostal space, triple closure of the holes in the diaphragm, parietal pleural biopsies and partial pleurectomy. Macroscopically, on the diaphragm surface no suspect nodules were observed. Histological exam of the parietal pleura demonstrated the presence of cystic hemorrhagic endometriosis. The patient was then placed on Gonadotropin-releasing hormone agonist for six months. For the time being no recurrence of pneumothorax occured. Case report 2: A 15 year old girl with behavioral disorder was treated for first episode of spontaeous pneumothorax in April 2015. Before undergoing right VATS six months later the patient had one left pneumothorax and two recurrences on the right. Intraoperatively many minute diaphragmatic openings were noticed along with apical lung tissue laceration from torn adhesion. Apart from apical lung resection, parietal pleura was coagulated with surgical diathermy. Final pathological exam demonstrated emphysematous changes in the resected lung tissue. Subsequenly the patient had one recurrence on the left and at lung base on the right (Figure 1b). At this point we decided to try to obtain pleurodesis with autologous blood patch. Talc pleuodesis is still not approved in Italy for non-malignant pleural pathology. The patient is currently on supressive hormonal therapy.

Conclusions

The best results in the treatment of catamenial pneumothorax are obtained by combining surgery (VATS in the first place, resection of endometriotic implants if present, diaphragmatic closure if holes present, and some form of pleurodesis) and hormonal ovarian supression. Attention to detail is essential as more than one pathogenic mechanism for occurence of pneumothorax may coexist.

Bibliography

1. Alifano M. Curr Opin Pulm Med 2010; 16:381-386.

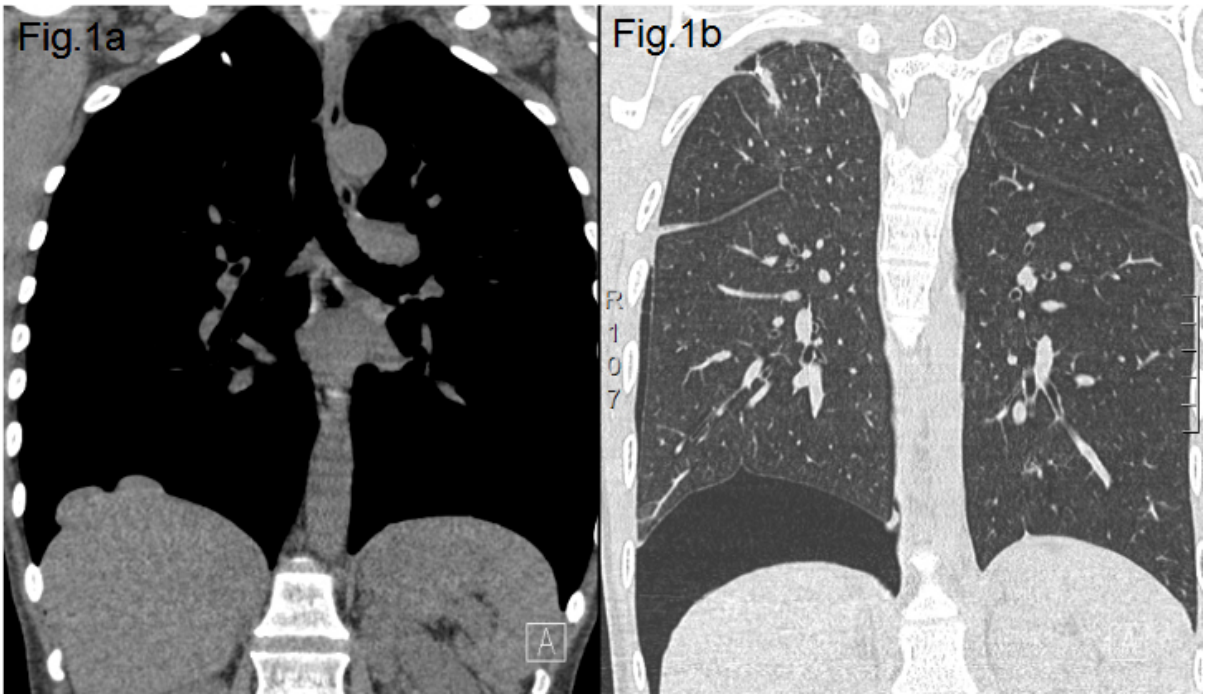

id 282

19th WCBIP / WCBE World Congress
JOINT MEETING OF THE WORLD ASSOCIATION FOR BRONCHOLOGY AND INTERVENTIONAL PULMONOLOGY & THE INTERNATIONAL BRONCHOESOPHAGOLOGICAL SOCIETY
www.wcbipwcbe2016.org
Fortezza da Basso
May 8-11, 2016
Florence (Italy)

Transbronchial cryobiopsy in diagnosis of ILD other than sarcoidosis with two scope technique

Thitiwat Sriprasart[1], Alejandro Aragaki[2], Robert Baughman[2], Kathryn Wickenhaiser-brokamp[3], Michelle Kirschner[2], Sadia Benzaquen[2]

[1]Internal Medicine, Chulalongkorn University - Thailand
[2]Medicine, University of Cincinnati - Usa
[3]Pathology, Cincinnati Children Hospital - Usa

Introduction
Transbronchial cryobiopsy have been used for establishing the diagnosis of interstitial lung disease in recent years. The procedure technique was variable among institution ranging from using the flexible bronchoscope with conscious sedation to using rigid bronchoscope with Fogarty balloon under general anesthesia. The diagnostic yield of transbronchial cryobiopsy was more than 70%. The complication rate varies among studies with reported pneumothorax rate of 0-29%.

Objective
We reported a two-scope technique and the result of transbronchial cryobiopsy at the university of Cincinnati.

Methods
This is a retrospective chart review of interstitial lung disease patients who underwent transbronchial cryobiopsy for evaluation of interstitial lung disease other than sarcoidosis. Bronchoscopy with transbronchial cryobiopsy was performed by board certified interventional pulmonologist with two-scope technique under general anesthesia. The first bronchoscope was advanced in the airway. An Erbe 1.9 or 2.4 mm cryoprobe was advanced through the working channel to the distal lung parenchyma under the fluoroscopy. The probe was withdrawn approximately 1 cm from the point of resistance. Then cryo freezing was activated with freeze times of 5-8 seconds. The bronchoscope and cryoprobe were then withdrawn en-bloc and passed to an assistant. Immediately, another bronchoscope was advanced into the airway and wedged at the bronchus to control bleeding. Pathology was read by pulmonary pathologist.

Results
57 patients underwent transbronchial cryobiopsy with two-scope technique. The mean age 56.39 +/-14.37 years. The mean tissue surface area was 58.67 mm2. Median anesthesia time was 87 minutes. 8 of 57 cases were non diagnostic. The diagnostic yield was 49/57 (85.96%). The most common diagnosis was usual interstitial pneumonia(12 cases), followed by organizing pneumonia(10 cases) and Non specific interstitial pneumonia(8 cases). Pneumothorax occurred in 3 cases (5.26%). There was one case with bronchoscopic related respiratory failure.

Conclusions
Transbronchial cryobiopsy with two scope technique was safe and sufficient in diagnosing various types of interstitial lung diseases.

Bibliography
1. Casoni et al. PLOS ONE 2014; 9(2):e86716 2. Poletti et al. Respirology 2014; 19:645-654

Table 1: Diagnosis made by transbronchial cryobiopsy

Diagnosis	Number
Usual Interstitial Pneumonia	12
Nonspecific Interstitial Pneumonia	8
Hypersensitivity Pneumonitis	6
Organizing Pneumonia	10
Capillaritis	2
DIP	1
RB-ILD	3
Diffuse Alveolar Hemorrhage	1
Malignancy(adenocarcinoma, CLL)	3
Others(PLCH, infections)	3
Non diagnosis	8

19th WCBIP / WCBE World Congress
JOINT MEETING OF THE WORLD ASSOCIATION FOR BRONCHOLOGY AND INTERVENTIONAL PULMONOLOGY & THE INTERNATIONAL BRONCHOESOPHAGOLOGICAL SOCIETY
www.wcbipwcbe2016.org
Fortezza da Basso
May 8-11, 2016
Florence (Italy)

Mediastinoscopy versus endosonography for mediastinal staging: does it affect 5 year survival?

Kuijvenhoven Jolanda[1], Korevaar Daniel[2], Tournoy Kurt[3], Malfait Thomas[4], Dooms Christoph[5], Rintoul Robert[6], Annema Jouke[1]

[1]Pulmonology, Academic Medical Center - The Netherlands
[2]Clinical Epidemiology, Biostatistics and Bioinformatics, Academic Medical Center - The Netherlands
[3]Pulmonology, O.L.V. Aalst and Ghent University hospital - Belgium
[4]Pulmonology, Ghent University Hospital - Belgium
[5]Pulmonology, Leuven University Hospitals - Belgium
[6]Thoracic Oncology, Papworth Hospital - United Kingdom

Introduction

Mediastinal staging is crucial in the management of lung cancer patients as it directs therapy and as it has prognostic value. To establish the optimal strategy for mediastinal nodal staging, the ASTER trial was performed in which patients with non-small cell lung cancer (NSCLC) were randomized to either mediastinoscopy alone (surgical strategy) or to endosonographic staging with both endobronchial ultrasound (EBUS) and transoesophageal ultrasound (EUS), if negative followed by surgical staging (endosonographic strategy). Although a significant difference in sensitivity was identified (79% versus 94%, respectively) in favor of the endosonographic strategy[1], it is unknown whether a more accurate staging has impact on the overall survival.

Objective

To analyze whether a superior mediastinal staging strategy results in an improved 5 year survival.

Methods

Patients' survival data of the ASTER trial were obtained. In a post-hoc analysis, the proportion survivors at 5 year following randomization was calculated for both staging strategies. We performed Kaplan-Meier analysis to compare the median survival .

Results

Five year survival data were obtained for 237 of the 241 patients (98%). The overall survival was 36% (42/116) for the surgical strategy versus 35% (42/121) for the endosonographic strategy (odds ratio 0.94 [95% CI 0.55 to 1.60]). In a Kaplan Meier analysis, the median survival was 33 months (95%CI 22 to 44) for surgical staging, compared to 31 months (95%CI 21 to 41) for endosonographic staging (p=0.96; Figure). In the subgroup of patients with N2/3 metastases, survival at 5 years was 23% (12/51) and 18% (11/61), respectively (odds ratio 0.80 [95%CI 0.32-2.04]). In the subgroup of patients with N0/1 metastases , survival at 5 years was 46% (30/65) and 52% (31/60), respectively (odds ratio 1.18 [95%CI 0.58-2.39]).

Conclusions

Five year survival rate was similar for both surgical and endosonographic staging strategy. It must be noted that the ASTER trial was designed and powered to evaluate significant improvements in diagnostic accuracy, not for survival rates.

Bibliography

1. Annema JT et al. JAMA 2010;304:2245-225 Mediastinoscopy vs. endosonography for mediastinal nodal staging of lung cancer: A randomized trial.

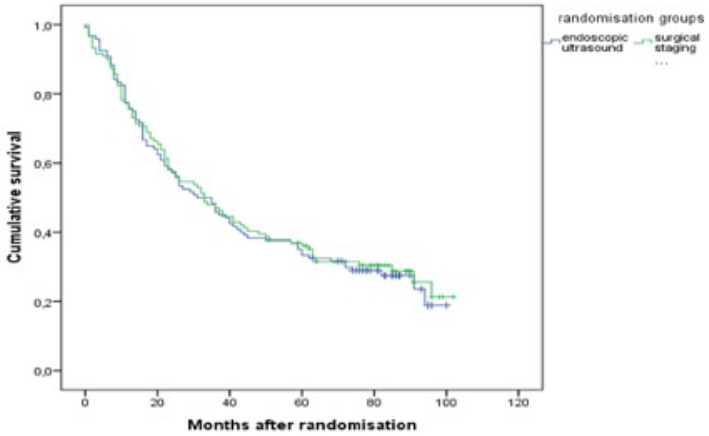
randomisation groups
endoscopic ultrasound
surgical staging
Cumulative survival
1,0
0,8
0,6
0,4
0,2
0,0
0
20
40
60
80
100
120
Months after randomisation

id 284

The bronchus sign predicts a positive diagnostic yield of peripheral pulmonary lesions from EBUS-GS

Reiko Matsuzawa[1], Keisuke Kirita[1], Shigeki Umemura[1], Shingo Matsumoto[1], Kiyotaka Yoh[1], Seiji Niho[1], Hironobu Ohmatsu[1], Masahiro Tsuboi[2], Koichi Goto[1]

[1]Division of Thoracic Oncology, National Cancer Center Hospital East - Japan
[2]Division of Thoracic Surgery, National Cancer Center Hospital East - Japan

Introduction

Endobronchial ultrasound with a guide sheath (EBUS-GS) is used widely and has been shown to improve the diagnostic yield of peripheral pulmonary lesions in several reports. However, it can be difficult to obtain adequate biopsy specimens for diagnosis by transbronchial biopsy (TBB) even with the use of EBUS-GS.

Objective

The purpose of this study is to elucidate the clinical factors that impact the diagnostic yield of TBB with EBUS-GS on small peripheral lung lesions.

Methods

We retrospectively reviewed 234 consecutive patients from April 2014 to October 2015 who underwent TBB with EBUS-GS for small peripheral lung lesions (<= 30mm in longest diameter). The final diagnoses were pathologically or clinically determined in all patients. We analyzed the relation between the diagnostic yield and the radiological features, including the computed tomography (CT) bronchus sign, lesion's visibility on chest X-ray, the lesion size, its features on CT (ground glass opacity (GGO)/ solid) and its distance from the pleura.

Results

A total of 234 patients (234 lesions) were included. The median long axis diameter of the lesions was 21mm (range 8-30mm). The CT bronchus sign was present in 183 (78%) lesions, and 184 (78%) lesions were visible on the chest X-ray. The final diagnoses were malignant in 171 lesions, and benign in 63 lesions. The total diagnostic yield in this study was 77%. In the univariate analysis, the CT bronchus sign ($p< 0.01$) and the lesion's visibility on chest X-ray ($p=0.04$) were significantly associated with a positive biopsy result. There were no other factors significantly associated with the diagnostic yield. In the multivariate analysis, only the CT bronchus sign remained as a statistically significant predictor of a positive biopsy result. ($p< 0.01$). Within the bronchus sign-negative group, EBUS-GS-transbronchial needle aspiration (TBNA) was performed in 6 patients, and adequate biopsy samples were obtained with a diagnosis made in all these patients.

Conclusions

The CT bronchus sign is a significant predictor of a positive diagnostic yield from TBB under EBUS-GS. In addition, EBUS-GS-TBNA may be useful for diagnosis of peripheral lung lesions without bronchus sign.

id 285

Adequacy of the ACCP guidelines for mediastinal staging of the N0 and T2a (stage IB) NSCLC

Davide Bianchi[1], Giorgia Tancredi[2], Luca Voltolini[2], Lorenzo Corbetta[3]

[1]Pulmonology and Thoracic Oncology - Centre Hospitalier de Troyes, University of Reims, France - France
[2]Thoracic Surgery Unit, University of Florence - Italy
[3]Interventional Pulmonology Unit, University of Florence - Italy

Introduction

An accurate mediastinal staging in NSCLC constitutes a diagnostic and prognostic factor of considerable importance. It provides detailed information about the extent of disease and address the clinician to establish an accurate prognosis and consequently, the best curative option.

Objective

Our purpose is to verify the adequacy of the ACCP guidelines in the staging of NSCLC peripheral with N0 and T2a (stage IB). We noticed that the ACCP guidelines for mediastinal staging of peripheral NSCLC in case of N0 and T2a (> 3 cm and <5 cm) TNM classification, do not propose any additional mediastinal staging while ESTS guidelines propose ulterior staging by EBUS/EUS or VAM.

Methods

We compared the ACCP guidelines : "Methods for staging Non-small cell lung cancer" published on CHEST in May 2013 with those of the ESTS "Revised ESTS guidelines for preoperative mediastinal lymph node staging for non-small cell lung cancer "published in the 'European Journal of Cardio-thoracic surgery on 26 February 2014. The ACCP guidelines for mediastinal staging gather case studies to draw up the guidelines dividing them in 4 radiological categories of NSCLC (CT scan) according to their mediastinal infiltration and assuming no distant metastasis. ESTS guidelines instead, propose a algorithm starting with the research of mediastinal lymph nodes positivity after radiological examination with PET / CT or PET and CT. We applied both staging guidelines to 11 patients with stage IB NSCLC who underwent surgery and we compared their clinical stage to the anatomopathological one, during the period 2011 - 2015 in the Bronchology department and in the Thoracic Surgery Unit at the Hospital Careggi in Florence. Other patients treated for potentially resectable NSCLC in the Pulmonology and thoracic oncology Unit at the Centre Hospitalier de Troyes, France, will be included soon in our study. We want to put in evidence an eventual discordance in the mediastinal staging process between the.two guidelines

Results

(preliminary results): 11 patients, 6 males and 5 females aged 57 to 76, mean age = 71,90, histologically 7 adenocarcinome (63,63%) and 4 squamous cell lung cancer (36,36%), after surgical staging showed a pT2aN0 classification accordingly with the clinical stage

Conclusions

by our experience about this small group of patients, the ACCP guidelines showed a 100% concordance between clinical and pathological staging for the specified stage IB. An ulterior invasive, would expose them to risks of postoperative complications and avoidable surgery costs without modifying therapeutical options and chances of survival.

Bibliography

1. Silvestri GA et Al. Chest. 2013 May;143(5 Suppl):e211S-E250S 2. De Leyn et Al. Eur J Cardiothorac Surg. 2014 May;45(5):787-98

Adequacy of the ACCP guidelines for mediastinal staging of the N0 and T2a (stage IB) Non-small-cell lung cancers

Interventional Pulmonology Unit and Thoracic Surgery Unit, Careggi University Hospital, Florence - Italy

abbreviations

Adk = adenocarcinome,

Squam = squamous cell

Sex, age	histology	Clinical stade	Pathological stage
Male, 72 yo	adk	cT2aN0	pT2aN0
Female, 76 yo	squam	cT2aN0	pT2aN0
Female, 76 yo	adk	cT2aN0	pT2aN0
Male, 67 yo	adk	cT2aN0	pT2aN0
Female, 57 yo	adk	cT2aN0	pT2aN0
Female, 72 yo	squam	cT2aN0	pT2aN0
Female, 74 yo	adk	cT2aN0	pT2aN0
Male, 76 yo	squam	cT2aN0	pT2aN0
Male, 74 yo	squam	cT2aN0	pT2aN0
Male, 73 yo	adk	cT2aN0	pT2aN0
Female, 74 yo	adk	cT2aN0	pT2aN0
11 patients			

id 286

Efficacy of EBUS-TBNA with the new Nitinol needle compared to a conventional needle

Omar Abbassi Abbassi[1], Syed A. Husain Husain[2], Saima Ayaz Ayaz[3], Bassam Younnes Younnes[4], Leon Decruz Decruz[5]

[1]Final Year Medical Student (MBBS-5), St.George's University of London - United Kingdom
[2]Respiratory consultant at Maidstone Hospital, Maidstone and Tunbridge Wells NHS Trust - United Kingdom
[3]Final year medical student, Windsor University School of Medicine - Caribbean
[4]Associate sepecialist histopathologist, Maidstone and Tunbridge Wells NHS Trust - United Kingdom
[5]Research associate, Maidstone and Tunbridge Wells NHS trust - United Kingdom

Introduction

Endobronchial ultrasound-guided transbronchial needle aspiration (EBUS-TBNA) is a safe and effective diagnostic procedure. Various needles of different makes can be used to aspirate samples. The extent to the type of needle used influences the procedure's diagnostic efficacy remains unclear.

Objective

1) Evaluate the difference in diagnostic efficacy of EBUS-TBNA when two different needles are used for two groups of patients. 2) Compare lymphocyte density as a contributor to diagnostic yield of samples aspirated from an identical lymph node using both needles.

Methods

Data from 141 patients who underwent EBUS-TBNA between October 2013 and December 2015 was included. The procedure was performed with a 22 gauge single use dimpled tip needle for 86 patients and a new 22 gauge single use Nitinol needle for 55 patients. All the procedures were performed by the same operator. Samples were aspirated from same lymph node station using both needles for a select 3 patients; comparative analysis as mean lymphocyte density per microscopic field was undertaken in four randomly selected fields.

Results

The overall sensitivity and specificity of EBUS-TBNA with the Nitinol needle was 93% and 100% respectively compared with 91% and 100% with the dimpled tip needle. For benign conditions, sensitivity and specificity values were 92% and 100% respectively with the dimpled tip needle compared to 100% and 100% with the Nitinol needle. For malignant diseases, the sensitivity and specificity values were 94% and 100% respectively compared to 89% and 100% with the Nitinol needle. There was a mean 52 cells/field with the Nitinol needle as opposed to 30 cells/field with the dimpled tip needle (Fig1.Visual comparison of microscopic fields of two samples aspirated from the same lymph node, one with each needle (40×). The left field represents the dimpled tip needle and the right field the Nitinol needle showing higher lymphocyte density). This was not viable for a larger group of patients due to cost-effectiveness issues with using two different needles during a single procedure.

Conclusions

We found the overall diagnostic efficacy of EBUS-TBNA to be slightly higher with the new Nitinol needle but particularly superior for benign diagnoses. It was preferred by the operator for greater flexibility in lesion access and in aspirating hard to reach nodes .In addition, the higher lymphocyte density in the samples aspirated with the Nitinol needle could warrant further investigation as a likely contributor to the needle's apparent superior efficacy.

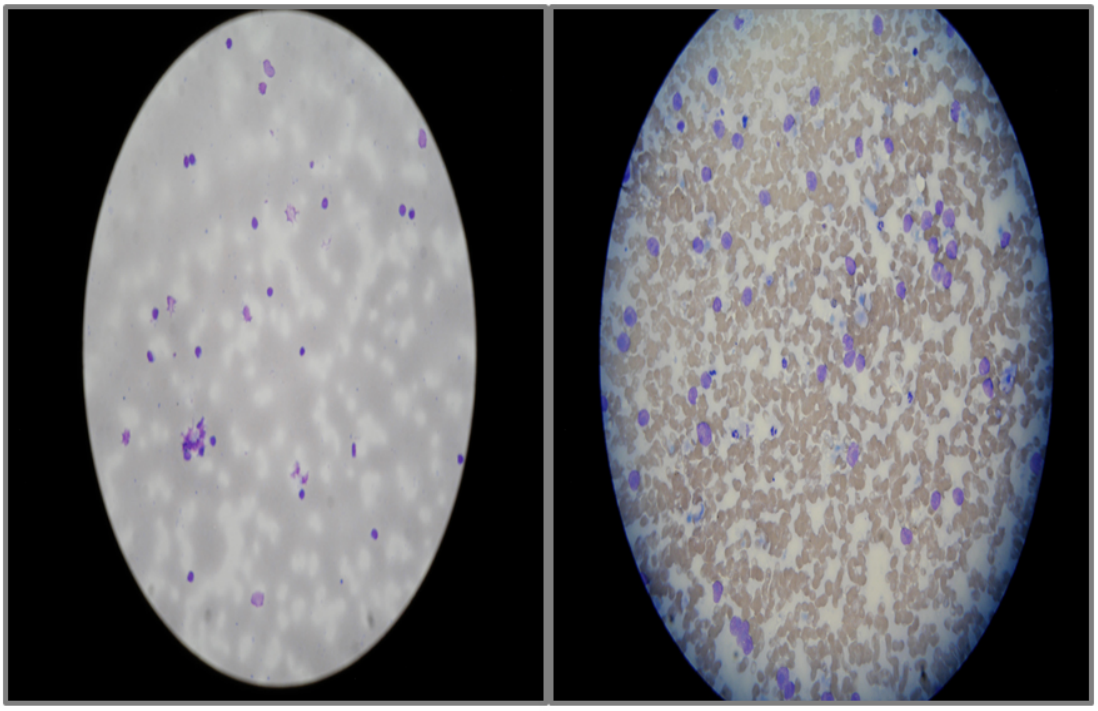

id 287

19th WCBIP / WCBE World Congress
JOINT MEETING OF THE WORLD ASSOCIATION FOR BRONCHOLOGY AND INTERVENTIONAL PULMONOLOGY & THE INTERNATIONAL BRONCHOESOPHAGOLOGICAL SOCIETY
www.wcbipwcbe2016.org
Fortezza da Basso
May 8-11, 2016
Florence (Italy)

Development and feasibility study of a new nasogastric tube to prevent reflux in the ICU

Heinrich D. Becker[1], Nigel Scorn[2]

[1]former Head Dept. Interdisciplinary Endoscopy, Thoraxklinik at Heidelberg University - Germany
[2]Intensive Care, Liverpool Heart and Chest Hospital - Uk

Introduction

Ventilator associated pneumonia (VAP) is one of the most common nosocomial infections in intensive care affecting up to 28% of patients(1). Gastro- oesophageal reflux plays a major role in the pathogenesis as supine positioning, nasogastric feeding and the presence of tracheal pepsin have all been demonstrated to be independent risk factors (2,3).

Objective

We developed a novel nasogastric aspiration tube (NutrisealR) which aims to reduce the risk of gastro oesophageal reflux. The tube incorporates six small channels arranged in its outer wall which exit in the distal and mid oesophagus. Low pressure suction is applied to these channels, drawing the oesophageal wall against the tube to create a sealing effect. In addition, any accumulated reflux contents in the oesophagus are actively aspirated from the suction ports.

Methods

After ethics board approval informed consent was gained from patients, prior to cardiac and thoracic aortic surgery. The device was inserted post-operatively in 16 adult patients when nasogastric tube was indicated on clinical grounds. Correct positioning of the tube was confirmed radiographically using integrated radiopaque markers. Oropharyngeal samples were obtained for pepsin assay, as a marker for reflux (3,4), prior to tube insertion and at 12 hourly intervals for the next 60 hours. The Mann-Whitney U test was used to compare pepsin levels during tube use with baseline samples. Clinician and nurse questionnaires were administered to assess ease of use.

Results

Nutriseal nasogastric aspiration tubes were inserted in 16 patients. The median length of tube in situ was 5.5days [IQR 2.7–9.4]. Sixty five oropharyngeal aspirates were sent for assay. Insertion of the NG aspiration tube resulted in a statistically significant reduction in pharyngeal pepsin levels from baseline with median values of 146ng/ml [IQR 28–214] vs. 27.5ng/ml [IQR 0–74] (P=0.036). Nursing staff and clinicians found use easy. There were no unexpected adverse incidents attributed to the device.

Conclusions

This proof of concept study shows the device is safe and easy to use in a cardiac intensive care setting. The tube significantly reduced gastro- oesophageal reflux which may decrease the risk of ventilator associated pneumonia as well as offsetting the risk of enteral feeding in mechanically ventilated patients.

Bibliography

1. Richards M. Nosocomial infections in medical ICUs in the US.Crit Care Med. 1999; 27:(887-892). 2. Metheny N. Tracheobronchial aspiration in critically ill patients. Crit Care Med 2006; 34:(1007-1015).

The presenting author has the following conflicts of interest that relate to this abstract: *The author was involved in the development of the device, conducted the animal experiments and the clinical study was supported by Swing Medical Ltd., Israel*

19th WCBIP / WCBE World Congress
JOINT MEETING OF THE WORLD ASSOCIATION FOR BRONCHOLOGY AND INTERVENTIONAL PULMONOLOGY & THE INTERNATIONAL BRONCHOESOPHAGOLOGICAL SOCIETY
www.wcbipwcbe2016.org
Fortezza da Basso
May 8-11, 2016
Florence (Italy)

Esophageal ultrasound (EUS) assessment of T4 status in patients with NSCLC

Kuijvenhoven Jolanda[1], Breen David[2], Vd Berk Inge[3], Braun J[4], Versteegh M[4], Annema Jouke[1]

[1]Pulmonology, Academic Medical Center - The Netherlands
[2]Pulmonology, Galway University Hospitals - Ireland
[3]Radiology, Academic Medical Center - The Netherlands
[4]Cardio-thoracic Surgery, Leiden University Medical Center - The Netherlands

Introduction

Patients with direct tumour involvement of the mediastinum/ large vessels (T4) have a 5 year survival of less than 5%. CT scan of the chest has limited accuracy to asses mediastinal tumour invasion. Inaccurate preoperative assessment of mediastinal invasion currently results in both over and under staging and exploratory thoracotomies. In addition to nodal staging, EUS can assess mediastinal invasion of centrally located lung tumours provided that are situated adjacent to the esophagus. The value of EUS for T4 assessment is unknown.

Objective

To assess the value of EUS for T4 assessment in patients with centrally located NSCLC and relate this to both CT and surgical-pathological staging.

Methods

Cases were retrospectively selected from two university hospitals [LUMC (1999-2011) and AMC (2012-2015)] based on the following criteria: patients who underwent EUS for the diagnosis and staging of lung cancer in whom the primary tumour was detected by EUS or EUS-B and who subsequently underwent a thoracotomy. Of each case, the T status was reviewed based on EUS, CT and thoracotomy findings. Surgical-pathological staging was the reference standard.

Results

In 421 patients, the lung tumour was detected by EUS. As most patients had advanced disease (mostly N2/3) just 72 patients underwent subsequent thoracotomy. . Surgical-pathological staging showed that 19 (26%) patients were staged T4 based on vascular (n=8, 42%)or mediastinal (n=8, 42%) tumour invasion or both (n=2 ,11%); a single patient (5%) had vertebral involvement. At EUS, 11 patients were judged to have stage T4, of which 8 were confirmed at subsequent surgery. The 3 false positive cases concerned suspected vascular invasion [pulmonary vein (n=1), pulmonary artery (n=2)]. The sensitivity, specificity, PPV, NPV of EUS (n=72), computed tomography (n=67) and the combination EUS/CT (both positive or negative for T4, n=38) for mediastinal/vascular T4 was 42%, 96%, 72%, 82% and 76%, 64%, 42%, 89% and 71%, 100%, 100%, 94% respectively.

Conclusions

EUS has a high specificity and PPV for T4 assessment of centrally located lung tumours and provides important added value to CT scan of the chest. Implication: in patients with lung tumours located adjacent to the esophagus, T4 assessment by EUS should be considered.

id 290

19th WCBIP / WCBE World Congress
JOINT MEETING OF THE WORLD ASSOCIATION FOR BRONCHOLOGY AND INTERVENTIONAL PULMONOLOGY & THE INTERNATIONAL BRONCHOESOPHAGOLOGICAL SOCIETY
www.wcbipwcbe2016.org
Fortezza da Basso
May 8-11, 2016
Florence (Italy)

The usefulness of IT knife for pleural effusion that diagnosis is difficult

Motohiro Tamiya[1], Norio Okamoto[1], Takayuki Shiroyama[1], Subaru Nishihara[1], Takuji Nishida[1], Ayako Tanaka[1], Manabu Hayama[1], Naoko Morishita[1], Hidekazu Suzuki[1], Tomonori Hirashima[1], Kunimitsu Kawahara[2]

[1]Thoracic Malignancy, Osaka Prefectural Medical Center for Respiratory and Allergic diseases - Japan
[2]Pathology, Osaka Prefectural Medical Center for Respiratory and Allergic diseases - Japan

Introduction

We usually use semiflexible thoracoscopy for diagnosis of pleural effusion or obtaining a tissue. However, we can't obtain a sufficient pleural tissue because of extensive fibrous pleura which are difficult to grasp by usual forceps, especially such as malignant mesothelioma. Therefore, in such case we use an insulated-tip diathermic knife (IT knife) during semiflexible thoracoscopy.

Objective

We evaluate the usefulness of IT knife for the patients with pleural effusion that their diagnosis have difficult.

Methods

When we judged the cases which was difficult to obtain the tissue by usual forceps, we added to use IT knife and the lesion was incised in a circular shape with full thickness by manipulating the IT knife after injecting saline with lidocaine and epinephrine below the affected pleura.

Results

From January 2006 to December 2013, A total of 241 patients received semiflexible thoracoscopy and 49 cases of this were performed the IT knife. The final diagnosis showed the malignancy were 23 cases and benign were 26cases. The total diagnostic yields was 93.9%; it was 91.3% and 96.2% for malignancy and benign cases, respectively. Furthermore, the diagnostic yields of usual forceps was 73.5% (73.9% and 73.1% for malignancy and benign cases) and those of IT knife was 85.7% (73.9% and 96.2% for malignancy and benign cases). In 49 cases, 2 cases had a complication (only pain) and there were no severe complication. To add the IT knife improved the diagnosis of pleural effusion which was difficult to obtain the tissue.

Conclusions

IT knife during semiflexible thoracoscopy was useful for diagnosis in cases with pleural lesions which are difficult to grasp by usual forceps.

Bibliography

Sasada S, et al. Surg Endosc. 2009 Aug;23(8):1901-7

Comparison between groups of Forceps and IT-knife

Diagnosis	Forceps,%(No.)	IT-knife,%(No.)	IT-knife/Forceps,%(No.)
Malignancy	73.9 (17/23)	73.9 (17/23)	91.3 (21/23)
Mesothelioma (Epi)	62.5 (5/8)	75.0 (6/8)	87.5 (7/8)
Mesothelioma (Sarco/Desmo)	75.0 (3/4)	75.0 (3/4)	100 (4/4)
Lung Cancer	100 (8/8)	75.0 (6/8)	100 (8/8)
Metastasis cancer (Breast/Esophagus)	0 (0/2)	50 (1/2)	50 (1/2)
Malignant lymphoma	100 (1/1)	100 (1/1)	100 (1/1)
Benign	73.1 (19/26)	96.2 (25/26)	96.2 (25/26)
Tuberculosis	66.7 (4/6)	83.3 (5/6)	83.3 (5/6)
Nonspecific pleuritis	71.4 (5/7)	100 (7/7)	100 (7/7)
Fibrosis pleuritis	76.9 (10/13)	100 (13/13)	100 (13/13)
Overall	73.5 (36/49)	85.7 (42/49)	93.9 (46/49)

id 291

19th WCBIP / WCBE World Congress
JOINT MEETING OF THE WORLD ASSOCIATION FOR BRONCHOLOGY AND INTERVENTIONAL PULMONOLOGY & THE INTERNATIONAL BRONCHOESOPHAGOLOGICAL SOCIETY
www.wcbipwcbe2016.org
Fortezza da Basso
May 8-11, 2016
Florence (Italy)

Laser therapy for central airway obstruction and stenosis with rigid bronchoscopy

Xi Wang, Hong Zhang, Ying Liu, Yuan Cheng, Guangfa Wang

Department of Respiratory and Critical Care Medicine, Peking University First Hospital - China

Introduction

Rigid bronchoscopy has a large diameter working channel, the ability to maintain proper ventilation during operation, and the capacity to deal with massive bleeding and other complications. The Nd:YAG laser, with its deep tissue penetration and therefore high ablation rate, combined with the delicacy of the shallow tissue penetration of the Ho:YAG laser for safe ablation in challenging anatomical locations. Therefore, laser therapy with rigid bronchoscopy might be more effective and safe.

Objective

Our purpose was to describe the effectiveness and safety of laser therapy with rigid bronchoscopy in central airway obstruction and stenosis?

Methods

We retrospectively analyzed the patients who had received rigid bronchoscopy for central airway obstruction in Department of Respiratory and Critical Care Medicine of Peking University First Hospital between October of 2013 and April of 2015. The advantages and limitations of the operations were analyzed through observing the changes of the degree of stenosis, the degree of dyspnea, and Barthel Index. Complications were also recorded.

Results

Totally 75 rigid bronchoscopic procedures were performed in 61 patients with central airway obstruction and stenosis(43 men; median age, 55.8 years; range, 21 to 83 years). The immediate relief of dyspnea after procedures was achieved in 63(84.0%) patients. The Barthel Index increased from 66.5±32.5 Punkte to 79.0±29.3 Punkte ($P<0.01$). Complications included 12 hemorrhages(>20ml), 2 hypoxemia and 1 ventricular tachycardia. There were no fatal complications?

Conclusions

Nd:YAG and Ho:YAG Laser therapy through rigid bronchoscopy is effective and safe in treatment central airway obstruction and stenosis.

id 292

19th WCBIP / WCBE World Congress
JOINT MEETING OF THE WORLD ASSOCIATION FOR BRONCHOLOGY AND INTERVENTIONAL PULMONOLOGY & THE INTERNATIONAL BRONCHOESOPHAGOLOGICAL SOCIETY
www.wcbipwcbe2016.org
Fortezza da Basso
May 8-11, 2016
Florence (Italy)

Bronchial Occlusion with Silicone Spigot for Secondary Spontaneous Pneumothorax

Makoto Sakugawa, Shinobu Hosokawa, Nobuaki Fukamatsu, Masamoto Nakanishi, Yoshiko Ogata, Akihiro Bessho

Department of Respiratory Medicine, Japanese Red Cross Okayama Hospital - Japan

Introduction

Secondary spontaneous pneumothorax due to pulmonary emphysema, interstitial pneumonia, and other pulmonary diseases is associated with significant morbidity and increased risk of mortality. The management of prolonged air leaks is often difficult because of the severity and the variety of underlying diseases. Treatment options are limited for the patients who are not good candidates for surgery. Bronchial occlusion with silicone spigot (endobronchial Watanabe spigot) was reported to be effective for secondary intractable pneumothorax, however; it is not reported whether treatment outcomes are different between underlying pulmonary diseases.

Objective

To investigate whether treatment outcomes of this procedure are different between frequent causes of secondary pneumothorax such as pulmonary emphysema (PE), interstitial pneumonia (IP), and lung cancer (LC).

Methods

Patient characteristics, air leak reduction rates, lung expansion rates, chest-tube removal rates, and complications after the procedure were retrospectively analyzed among the patients with secondary spontaneous pneumothorax who underwent this procedure in our institute between April 2000 and September 2015.

Results

Fifty patients of PE, 24 patients of IP, and 8 patients of LC were analyzed. Ages were similar between 3 groups, and home oxygen therapy before the onset of pneumothorax, mechanical ventilation before bronchial occlusion, and systemic administration of corticosteroid were frequent in IP group, compared with other 2 groups. Air leak reduction rates in the patients of PE, IP, and LC were 83.3%, 88.5%, and 87.5%, respectively. Lung expansion rates in the patients of PE, IP, and LC were 82.6%, 77.3%, and 42.9%, respectively. Chest-tube removal rates in the patients of PE, IP, and LC were 75.9%, 57.7%, and 75.0%, respectively. Average number of sessions and average numbers of spigots used were the highest in the PE group. Serious adverse events were relatively frequent in the IP group.

Conclusions

Chest-tube removal rates were the lowest in the IP group despite of high air leak reduction rates. It was suggested that factors such as respiratory failure, delayed wound healing due to corticosteroid, and serious adverse events had been concerned. The treatment outcomes of bronchial occlusion varied by the underlying diseases, however; this procedure appears to be one of the useful treatment options for intractable pneumothorax due to these underlying diseases.

id 293

19th WCBIP / WCBE World Congress
JOINT MEETING OF THE WORLD ASSOCIATION FOR BRONCHOLOGY AND INTERVENTIONAL PULMONOLOGY & THE INTERNATIONAL BRONCHOESOPHAGOLOGICAL SOCIETY
www.wcbipwcbe2016.org
Fortezza da Basso
May 8-11, 2016
Florence (Italy)

Role of Medical Thoracoscopy in Tubercular empyema: Review of 27 cases

Arjun Srinivasan, Pavan Yadav, Pattabhiraman Vallandaramam, Mahadevan Sivaramakrishnan

Department of Interventional Pulmonology, Kovai Medical Center and Hospital - India

Introduction

Tuberculosis is a common cause of empyema in a country like India. Management of tubercular empyema (TE) is a difficult proposition requiring multidiscipinary treatment including prolonged chest tube drainage, prolonged hospital stay with significant morbidity.

Objective

Role of Medical Thoracoscopy (MT) in management of TE is not clearly defined. The aim of this study is to report our experience and to analyze the efficacy and safety of (MT) in TE.

Methods

We performed a retrospective analysis of medical records of patients undergoing MT for multiloculated effusions and empyema at our center under moderate sedation between January 2012 and December 2015. All procedures were carried out in the presence of an anesthetist and a combination of flexirigid (Olympus LTF 160) and rigid (Wolf minithoracoscope) thoracoscope was used.

Results

A total of 378 MT were carried out during the study period. Of these, 93 procedures were done for empyema. In 27 out of 93 patients (29%) etiology of empyema was tuberculosis. There were 19 male and 8 female patients with a mean age of 37 .55 years. Average duration of symptoms before the procedure was 19.96 days (range 7-45). Diabetes was the most common co-morbidity seen in 8 patients (29 %). Complete adhesiolysis was achieved in 25 patients (92.5 %), while in two patients partial adhesiolysis could be achieved. Complete expansion of lung on chest radiology was seen on day one in 21 patients (77.77%) and lung was partially expanded in 6 patients. Suction was applied post procedure in 2 patients. Four patients developed complications post procedure (air leak in 2 patients, excessive bleed from incision site in 1 patient and sub cutaneous emphysema in 1 patient) all of which improved with conservative management. Chest tube was removed after an average 4.4 days (range 1-27) and time to discharge was 4.81 days (range 2-12). Two patients were discharged with tube in-situ and no patients required any other procedure for management of empyema. All patients received complete course of antitubercular therapy.

Conclusions

Medical thoracoscopy is a safe and effective way to manage tubercular empyema. It is a viable, minimally invasive first line alternative, which can reduce duration of intercostal tube and admission in these patients.

Bibliography

1. Malhotra P, et al. Respiratory medicine 2007;101:423-30. 2. Kundu S, et al. Lung India 2010;27:196-201.

19th WCBIP / WCBE World Congress
JOINT MEETING OF THE WORLD ASSOCIATION FOR BRONCHOLOGY AND INTERVENTIONAL PULMONOLOGY & THE INTERNATIONAL BRONCHOESOPHAGOLOGICAL SOCIETY
www.wcbipwcbe2016.org
Fortezza da Basso
May 8-11, 2016
Florence (Italy)

The complementary role of transbronchial lung cryobiopsies in the diagnosis of pulmonary sarcoidosis

Sadia Benzaquen[1], Alejandro Aragaki[2], Thitiwat Sripasart[3]

[1]Pulmonary and Critical Care, University of Cincinnati - Ohio
[2]Pulmonary and Critical care, University of Cincinnati - Usa
[3]Pulmonary and Critical care, Chulalongkorn University - Thailand

Introduction

Sarcoidosis is a multisystem disorder of unknown cause. It commonly affects young and middle-aged adults and frequently presents with bilateral hilar and mediastinal adenopathy, pulmonary infiltration, and ocular and skin lesions. The diagnosis is established when clinicoradiological findings are supported by histological evidence of noncaseating epithelioid cell granulomas. The 1999 ATS/ERS/WASOG Statement on Sarcoidosis recommends transbronchial lung biopsy (TBLB) as the procedure for tissue diagnosis. If TBLB is negative, other diagnostic modalities include endobronchial ultrasound bronchoscopy (EBUS), the more invasive video assisted thoracoscopic lung biopsy or open lung biopsy. Transbronchial lung cryobiopsies (TBLC) are under investigation to overcome the limitations of transbronchial lung biopsies and could be complimentary to EBUS.

Methods

A retrospective analysis of 20 patients in a single, tertiary-care academic medical center was conducted to describe the yield of both EBUS-FNA and TBLC in the diagnosis of suspected pulmonary sarcoidosis. All cases but one were performed under general anesthesia. Clinical data, post procedural outcomes and a final diagnosis using a multidisciplinary approach was made.

Results

Mean age of the patients was 48 years and 55% were male. 75% were Caucasian. Most common symptom was dyspnea (90%). Most common comorbidities were hypertension (45%) and GERD (35%). Average BMI was 29.95. All patients were referred with a diagnosis of ILD. The predominant radiographic stage of sarcoidosis was stage 0 (12 patients). However, 80% of patients had CT chest studies that included sarcoidosis in the differential diagnosis. When patients had evidence of mediastinal/hilar adenopathy, EBUS-FNA was performed. All patients underwent TBLC for tissue diagnosis. On average, patients had 5 TBLC; 80% of patients had the right lung biopsied. The average cryobiopsy area was 74 mm2. In 16 patients that had lymphadenopathy, both techniques provided the diagnosis of sarcoidosis in 9 patients (56.25%), while an additional 4 patients (25%) had a pathologic diagnosis by adding TBLC. Only 1 patient had a diagnosis via EBUS-FNA only. Overall, pathologic diagnostic yield for TBLC was 81.25%. 2 patients were diagnosed with sarcoidosis after a multidisciplinary discussion (chronic fibrosis on pathology). The remaining diagnosis included chronic hypersensitivity pneumonitis, respiratory bronchiolitis, aspergillosis and normal lung parenchyma. All patients had minor bleeding that was controlled with bronchoscopic wedging. Complications included pneumothorax (15%) that resolved with a small bore chest tube placement.

Conclusions

TBLC is a safe and complimentary technique to diagnose of sarcoidosis and should be considered part of the diagnostic armamentarium in bronchoscopic centers of excellence.

Successfull surgery resection of Tracheal Adenoid Cystic Carcinoma after endoscopic treatment

Annalisa Brianti, Maria Grazia Covesnon, Marco Leva, Lorenzo Ferrera, Caludio Francesco Simonassi

UO Pneumologia, ASL3 Genovese - Italy

Introduction

Adenoid Cystic Carcinoma (ACC), also known as cylindroma, is a rare primary tracheal tumor, which comprises 0.1-0.2% of all lung cancers. ACC is the 2nd most common primary tracheal neoplasm. ACC is a slowly growing, late metastasizing, and locally recurrent tumor with a prolonged natural history. It appears as a rounded lesion which derives from the tracheal mucosa invading the lumen and causing airway obstruction. Although the high rate of recurrence after resection, surgery is the standard of treatment if possible. In case of extended endotracheal lesions and to preserve airway ventilation, laser resection is indicated. We report a case of ACC that was successfully managed with Nd-YAG laser photoresection to ensure normal ventilation and to measure the extension of the lesion followed by surgical resection.

Methods

A 65-year-old woman, non smoker, with history of thyroid goiter, presented with cough for 2 months. Phisical examination was normal as well as Chest X-Ray. CT scan showed a tracheal mass of the upper lume of the trachea and the voluminous thyroid goitre. We performed rigid broncoscopy which showed a large endotracheal mass origing from the right lateral tracheal wall, starting 4 cm below the vocal cords, which extended 5,5 cm above the carina and causing an 70 % obstruction of the upper trachea(Fig.1. The mass was removed with Nd:Yag laser with subsequent recanalization. Byopsies revealed atypical cells derived from an epithelial neoplasm, consistent with ACC. The patient underwent tracheal surgical resection with secondary anastomosis. The patient is still negative for relapse of disease after 18 months.

Conclusions

ACC is a slowly growing, late metastasizing, and locally recurrent tumor of the trachea with a prolonged natural history. Patients can remain asymptomatic for years while ACC is growing and lastly can develop critical airway obstruction. As reported in our case above, debulking by using laser allows better airway ventilation as a palliative treatment and permit to evaluate the extension of the lesion for the surgical resection.

id 296

19th WCBIP / WCBE World Congress
JOINT MEETING OF THE WORLD ASSOCIATION FOR BRONCHOLOGY AND INTERVENTIONAL PULMONOLOGY & THE INTERNATIONAL BRONCHOESOPHAGOLOGICAL SOCIETY
www.wcbipwcbe2016.org
Fortezza da Basso
May 8-11, 2016
Florence (Italy)

Rigid bronchoscopic resection of endobronchial hamartoma - single center experience of 5 cases

Arjun Srinivasan, Pattabhiraman Vallandaramam, Mahadevan Sivaramakrishnan, Pavan Yadav

Department of Interventional Pulmonology, Kovai Medical Center and Hospital - India

Introduction

Hamartomas are rare primary tumors of the lung, parenchymal lesions are more frequently seen than endobronchial counterparts. Endobronchial hamartomas (EH) can have varied presentation, they require early recognition and management.

Objective

Most reports of bronchoscopic management are limited to case reports and larger series have only been reports of surgical management. Assess the efficacy and safety of bronchoscopic methods in management of EH in a tertiary care referral interventional pulmonology unit.

Methods

Retrospective review of case records of patients undergoing rigid bronchoscopy in a tertiary care referral interventional pulmonology unit for diagnosis of hamartoma between 2011 and 2013.

Results

142 rigid bronchoscopies were carried out in this period of which 5 patients had a diagnosis of hamartoma on histopathology. There were 3 male and 2 female patients with a mean age of 48.8 years (range 35-63). Presenting complaints consisted of post obstructive pneumonia in 2 patients, lung collapse in one, hemoptysis in one and stridor in one patient. Chest X-ray was abnormal for 2 of the 5 patients. Tumor was found to originate from right middle lobe in two patients, right upper lobe in one, left upper lobe in one and mid trachea in one patient. Electrocautery snare was deployed to remove the tumor in 3 patients and mechanical debulking in two patients. Bleeding was controlled in all by Argon Plasma Coagulation. Histopathology was consistent with lipomatous hamartoma in 3 and chondromatous hamartoma in 2 patients. There were no complications and no recurrence after a mean follow up of 18.8 months (range 11-31.

Conclusions

Rigid bronchoscopic removal is an effective and safe technique in the management of endobronchial hamartomas. It is minimally invasive and can prevent surgery if lesions are diagnosed early.

Bibliography

1. Celik A,et al Clin Ter. 2014;165(3):e191-3. 2. Zehani-Kassar A, et al Rev Mal Respir. 2011 May;28(5):647-53.

Foreign Body Aspiration in Children: A 7-year retrospective study

Christine Costa[1], Luís Martins[1], Salvato Feijó[1], Paula Monteiro[1], José Rosal Gonçalves[1], Cristina Bárbara[2]

[1]Unidade de Pneumologia de Intervenção, Hospital Santa Maria, Centro Hospitalar Lisboa Norte - Portugal
[2]Department of Pneumology, Centro Hospitalar Lisboa Norte - Portugal

Introduction

Foreign Body Aspiration (FBA) is very common in children requiring prompt recognition and early treatment to minimize the potentially serious and sometimes fatal consequences. FB aspiration/inhalation is still a cause of death in childhood.

Objective

To access type, location, value of imaging and outcome in foreign body aspiration in children.

Methods

We retrospectively collected data of all suspected foreign-body aspiration in patients under 18 years old that undergone a bronchoscopy in our unit from November 2008 to October 2015. We used SPSS V22 to analyse age, gender, imaging, interval time between aspiration and bronchoscopy, type and location of FB.

Results

During the time period, 66 children were submitted to bronchoscopy for suspected foreign body aspiration; 63,6% were male. The majority of the patients were under 3 years old (78,8%) with a mean age of 3,33 ± 3,29 years (minimum: 7 months; maximum: 12 years). The average time between aspiration and bronchoscopy was unknown in 21,2% of the cases and of 299 hours in the remaining cases (minimum: 1 hour; maximum: 2880 hours). Chest radiography was not performed in 21,2% of patients and presented alterations in 69,2% of the exams performed. Most frequently observed changes were hiperinflation (36,1%) and hypotransparency (36,1%). Flexible bronchoscopy was used in 7,6% of the cases. Fyfty foreign bodies (75,8%) were removed, most of them organic (62%). There is a bimodal variation in the type of foreign body removed: mostly inorganic until 1 year old and after 5 years old. The majority of the foreign bodies were found in the left side (42%). In 25% of the cases, chest radiography was not consistent with bronchoscopy (9,6% had radiographic changes, with no foreign body; 15,4% had foreign body without any change in radiography). Mortality rate was 0%.

Conclusions

Foreign body aspiration mostly occurs in children under 3 years old. Its diagnosis might be difficult not only because clinical history might not be reliable but also because its clinical presentation might be confused with asthma or airway infection. Since chest radiography might not be in line with presence/absence of foreign body, bronchoscopy should be performed in order to clarify any suspicious case.

id 298

19th WCBIP / WCBE World Congress
JOINT MEETING OF THE WORLD ASSOCIATION FOR BRONCHOLOGY AND INTERVENTIONAL PULMONOLOGY & THE INTERNATIONAL BRONCHOESOPHAGOLOGICAL SOCIETY
www.wcbipwcbe2016.org
Fortezza da Basso
May 8-11, 2016
Florence (Italy)

Role of interventional bronchoscopy for palliation in central airway malignant

Claudio Della Pona, Eugenio Ravalli, Casimiro Giorgetta, Francesco Inzirillo

General Thoracic and Thoracic Endoscopy Department, Morelli Hospital, ASST Valtellina e Alto Lario - Italy

Introduction

The advances in chemo/radiotherapy lead to an increase in lung cancer patients survival. The number of long-term survivors is growing and this requires a supply of palliative treatments that can provide a significant improvement in quality of life (QOL). In patients with obstructive bronchial tumors, even the modern therapies rarely resolve the airway obstruction and the related symptoms. For this reason, the bronchoscopic treatment of malignant lesions, acquires increasingly importance and its role needs to be reviewed as a complementary treatment to chemo/radiotherapy

Objective

The role of bronchoscopic treatments of obstructive malignant lesions need to be reviewed as a complementary tratment to chemotherapy and radiotherapy

Methods

Between June 2005 and June 2015, 362 patients were treated in our department. We performed 446 therapeutic bronchoscopies to manage central airways obstructions both benign and malign. 75 patients were affected by benign lesions, 287 patients had central airway malignant obstructions. We reviewed the management and the outcome of these 287 cases.

Results

148 males and 139 females (22-86; mean age 64,8), affected by airways malignant obstructions underwent 354 interventional bronchoscopies both rigid (RB) and flexible (FB) (52 patients received more than 1 procedure). The lesions involved trachea in 86 cases, left main bronchus 59 cases, right main bronchus 54 cases, intermedius bronchus 38 cases and lobar bronchi 50 cases. Rigid bronchoscopies were 324 (284 laser/mechanical ablation, 29 with balloon dilatation association and 11 stents removal). In 122 procedures one or more stents were placed (tracheal metallic 29 and silicone 26, bronchial metallic 34 and silicone 29, Y stents 34. multiple stents in 23 cases). 7 procedures were complicated by airway rupture without sequelae and only 1 procedure was complicated by massive hemorrhage and perioperative death. In the remaining cases there was significant relief of symptoms. Median survival was 8,4 months (1-26 months).

Conclusions

The increase of median survival in cancer patients require a revision of the role of various palliative treatments in order to maintain the QOL as good as possible. RB, more than FB, play a key role as palliative procedure. RB allows to perform impossible maneuvers in FB(for example placement of silicone stents or certain types of technical maneuvers). Furthermore the RB allows a more appropriate control of any major bleeding. Ultimately, in patients with endobronchial tumors in advanced stage, the last aim of all these bronchoscopic techniques is improvement in QOL, resolution of respiratory failure and ensure dignity in the last stages of life.

Bibliography

Hardavella G, et al. Breathe. 2015 Sep;11(3):202-12 Huret B, et al. Rev Mal Respir. 2015 May;32(5):477-84

Pleurodesis for recurrent pleural effusions of cardiac etiology

Valentina Pinelli[1], Massimiliano Sivori[1], Vanna Balestracci[1], Anne V. Gonzalez[2], Pier Aldo Canessa[1]

[1]Division of Pneumology, Hospital S. Bartolomeo, Asl 5 Spezzino - Italy
[2]Department of Medicine, McGill University Health Centre, Montreal Chest Institute - Canada

Introduction

Chemical pleurodesis is an effective treatment option for malignant pleural effusions but it role in the management of benign, refractory pleural effusions is not well established. Congestive heart failure (CHF) is the most common cause of benign pleural effusions; thoracoscopic or chest tube pleurodesis are therapeutic options in patients requiring frequent drainage. Nevertheless, this approach is not widespread due to concerns about side effects and the development of contralateral pleural effusions.

Objective

To evaluate the success rate of talc pleurodesis in patients with recurrent pleural effusions of cardiac origin.

Methods

Between 2010 to 2015 patients with a recurrent, symptomatic, pleural effusion secondary to heart failure who underwent at least tree ipsilateral thoracenteses in a month were included. Depending on their performance status and prognosis, they underwent either thoracoscopic or chest tube pleurodesis. The follow-up ranged from 6 months to 2 years. Length of hospital stay, rate of procedural complications, recurrence of the pleural effusion, and development of contralateral pleural effusion were evaluated.

Results

Ten patients (2 female, 8 male, median age 70.5 years) with recurrent pleural effusions of cardiac etiology were included in this analysis. Six patients underwent thoracoscopic talc pleurodesis and 4 patients underwent talc slurry pleurodesis. The mean hospital stay was 7 days with no difference between thoracoscopic or chest tube pleurodesis. The most common side effects were the fever and pain within 24 hours of pleurodesis, controlled by the use of paracetamol or opiates. There were no significant complications post pleurodesis. Complete success was observed in 9 cases, partial success in 1 case. No patient developed a contralateral pleural effusion during follow-up.

Conclusions

Thoracoscopic or chest tube pleurodesis is a valid therapeutic option for patients with recurrent pleural effusions of cardiac etiology requiring frequent drainage. The procedures can be performed safely, with a low probability of developing a contralateral pleural effusion

id 300

Fraxinus, a free navigation system for bronchoscopy

Håkon Olav Leira

Dept Thoracic Medicine, Trondheim University Hospital / Norwegian Univ. of Science and Technology - Norway

Introduction

For bronchoscopy, the reported success rates for diagnostics of smaller peripheral lung lesions are low, 5-30%. Image guidance/navigation systems for bronchoscopy have shown to increase this to 60-70%. But navigation systems are not widespread, probably mostly due to cost. This results in lower-than-necessary bronchoscopy quality in many hospitals.

Objective

Our objective is to develop a freely available, open-source navigation system for bronchoscopy.

Methods

Based on specifications from pulmonologists, Fraxinus is developed from a general open source image-guided intervention software platform, the CustusX platform (Askeland et al. 2015) (www.custusx.org). Fraxinus is technically a front end, containing all open source code and abilities of CustusX, but with a simplified and streamlined interface adapted to bronchoscopy procedures, planning and guidance. Special bronchoscopy-specific modules are developed, for extraction of airway architecture (segmentation) from the chest CT, shortest route to target, and lung-specific visualizations like virtual bronchoscopy and 3- dimensional models.

Results

The Fraxinus bronchoscopy navigation system will be available as a free software from www.custusx.org. It will require a PC running Windows, OS X, or Linux, and can be downloaded, installed, and run by medical doctors or other personell. The software will be distributed as a research system. It contains a user interface customized to the different phases of bronchoscopy planning: Import of CT Thorax images in DICOM format, target pinpointing, automatic anatomical segmentation of airways, and navigation. The navigation screen contains virtual bronchoscopy, 3D models of airways, and cross-sectional slices of the chest CT (Figure). For the target navigation, the system generates a route to the target, and the user navigates along this route using a mouse or keyboard. Fraxinus contains no real-time position tracking of bronchoscope or tools, but this can be included by integrating e.g. an electromagnetic tracking system.

Conclusions

We present Fraxinus, an open-source, free to download, bronchoscopy navigation system.

Bibliography

(Askeland C, et al 2015. CustusX: an open-source research platform for image-guided therapy. International journal of computer assisted radiology and surgery 2015; published online, 1-15)

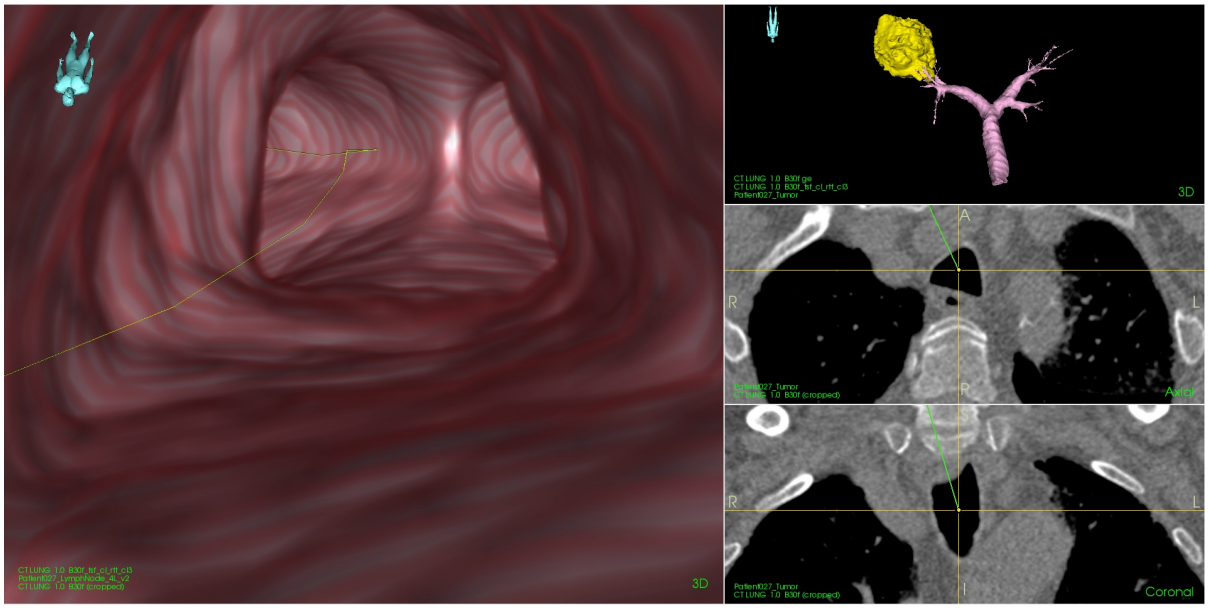
CT LUNG 1.0 B30f_trf_c1_rft_c13
Patient027_LymphNode_4L_v2
CT LUNG 1.0 B30f (cropped)
3D
CT LUNG 1.0 B30f ge
CT LUNG 1.0 B30f_trf_c1_rft_c13
Patient027_Tumor
3D
A
R
L
P
Axial
Patient027_Tumor
CT LUNG 1.0 B30f (cropped)
S
R
L
I
Coronal
Patient027_Tumor
CT LUNG 1.0 B30f (cropped)

id 301

19th WCBIP / WCBE World Congress
JOINT MEETING OF THE WORLD ASSOCIATION FOR BRONCHOLOGY AND INTERVENTIONAL PULMONOLOGY & THE INTERNATIONAL BRONCHOESOPHAGOLOGICAL SOCIETY
www.wcbipwcbe2016.org
Fortezza da Basso
May 8-11, 2016
Florence (Italy)

Pediartic interventional bronchoscopy for patient of pulmonary artery sling with stenosis

Leping Ye[1], Guangfa Wang[2], Xicheng Liu[3], Meizheng Zhan[1]

[1]Pediatric Pulmonology, The 2nd Affiliated Hospital & Yuying Children's Hospital of Wenzhou Medical University - China
[2]Respiratory and Critical Care Medicine, Peking University First Hospital - China
[3]Pediatric Interventional Pulmonology, Beijing Children's Hospital affiliated to Capital Medical University - China

Introduction

Treat a 6-month-old boy suffering from pulmonary artery sling with central airway stenosis after the slide tracheoplasty by comprehensive interventional therapy, analyze the value of the proper use of therapy, and accumulate the clinical intervention experience of pediatric center airway stenosis.

Methods

CASE REPORT:The pediatric patient was treated with children bronchoscopic intervention therapy for 8 times under general anesthesia, each interval from 3 to 10 days, for more than 2 months, applied with rigid bronchoscope and high frequency jet assisted ventilation, by bronchoscopic cryotherapy, balloon dilatation, holmium laser ablation and TBNA needle topical steroid injection and other methods of comprehensive interventional treatment for central airway stenosis. The narrowest place of trachea stenosis was about 2mm, the left and right main bronchus lumen stenosis, tracheal stenosis part lumen was significantly expanded to more than 4mm after balloon dilatation. Nine days later, the lower trachea was parallel and narrow, used holmium laser ablation and cryotherapy. Switching intubation cause invasive surgery can not proceed smoothly, it is inserted into the outer diameter of 5.7mm rigid bronchoscope under general anesthesia, muscle relaxant after direct laryngoscopy guide, the hard lens with jet assisted ventilation. Then insert soft bronchoscopy, lower trachea and main bronchus caused by large amounts of granulation tissue that was almost completely blocked, easy bleeding if touched. Remove part of clot by frozen probe, followed by holmium laser ablation of granulation tissue. the lower trachea stenosis reached about 90% of the normal lumen. With holmium laser for the right main bronchus opening of granulation tissue ablation, thawing frozen cut granulation treatment, rehabilitation balloon; and the bulge portion granulation with TBNA needle of Diprospan multipoint injection. After the treatments, the lower trachea and bronchus original narrow lumen were turned nearly normal. 2 weeks after successful extubation, placed Dumon silicone stent in the left and right main bronchus and lower part of trachea.

Results

Airway granulation tissue or scar contracture is the main cause of severe airway stenosis after Slide operation. Treatment strategies is to try to reduce the granulation tissue hyperplasia caused by the proliferation of new airway stenosis, so the treatment of the bronchial mirror and percutaneous balloon dilatation are of the first consideration. In addition, local use of corticosteroids can inhibit the proliferation of granulation tissue.

Conclusions

Treatment strategy : balloon dilatation + bronchoscopic cryotherapy surgery+ airway topical corticosteroid injection. If there are indications of benign airway stenosis, silicone stent is a good choice.

Bibliography

Kim, J.H., et al., Tracheobronchial laceration after balloon dilation for benign strictures: incidence and clinical significance. Chest 2007; 131(4): 1114-1117.


|010M|F
00841009
2015-04-30
11:59:26
NO.2 AFFILIATED HOSPITAL OF WZMU
OLYMPUS
Acc:201504300922
Ser:1
Img:3
150PT
Zoom : 212.85%
WL : 128
WW : 256

id 302

Transbronchial lung biopsy in lung transplant patients: efficacy and safety profile

David Bennett[1], Antonella Fossi[1], Claudia Ghiribelli[2], Luca Luzzi[2], Piero Paladini[2], Paola Rottoli[1]

[1]Respiratory Diseases and Lung Transplant, University of Siena - Italy
[2]Thoracic Surgery, University of Siena - Italy

Introduction

Lung transplantation (LTX) is nowadays accepted as a justified treatment option for selected patients with end-stage pulmonary disease, such as emphysema, cystic fibrosis (CF), pulmonary fibrosis and pulmonary arterial hypertension. Transbronchial lung biopsy (TBBx) is considered the gold standard for the diagnosis of acute rejection.

Objective

Aim of the present study was to analyse TBBx safety and efficacy in LTX patients.

Methods

A retrospective analysis on TBBx performed on the lung transplant population followed at our Institution was conducted. TBBx were routinely performed 20-40 days after LTX and on clinical indication thereafter.

Results

From 2001, on 121 patients who underwent to LTX (62 single Tx, 59 bilateral Tx, 51.1±10.6 age at LTX), 220 TBBx were performed (1.8 TBBx/patients, min 0 – max 7). Post-procedure pneumothorax developed in 5% of cases (in only one patient chest tube was necessary). Endobronchial bleeding was a minor complication; in only one case we experienced a significant bleeding. Pathologist considered 94% of tissue samples suitable for a conclusive diagnosis: acute rejection 41.7%, infection 18.9%, BOS 10.8%, other diagnosis 29.4, negative 9.2%.

Conclusions

TBBx confirmed to be a safe procedure in LTX patients. Diagnostic power is high, however inadequate sampling is still a major issue (6% in our experience). New endoscopic techniques, radiological advances in CT interpretation and non-invasive biomarkers development might improve diagnostic accuracy.

id 303

19th WCBIP / WCBE World Congress
JOINT MEETING OF THE WORLD ASSOCIATION FOR BRONCHOLOGY AND INTERVENTIONAL PULMONOLOGY & THE INTERNATIONAL BRONCHOESOPHAGOLOGICAL SOCIETY
www.wcbipwcbe2016.org
Fortezza da Basso
May 8-11, 2016
Florence (Italy)

A novel rendez-vous dual bronchoscopy technique for cryobiopsy

Bryan Husta[1], Wojciech Palka[1], Klaus Lessnau[1], Suhail Raoof[2]

[1]Interventional Pulmonology, Lenox Hill Hospital/ Hofstra University - Usa
[2]Pulmonology, Lenox Hill Hospital/ Hofstra University - Usa

Introduction
Bronchoscopic cryobiopsies for interstitial lung disease and peripheral lung nodules are increasingly used to avoid more invasive surgical techniques. Often, the use of cryobiopsy may be limited by a fear of major adverse effects such as massive airway hemorrhage and pneumothorax.

Objective
We describe a technique aimed at increasing the safety of cryobiopsy without compromising its yield. Our experience with rendez-vous bronchoscopy using two simultaneous working stations for a variety of indications in twenty-seven patients led us to explore the application of dual bronchoscopy for cryobiopsy.

Methods
Six patients underwent the rendez-vous cryobiopsy for interstitial lung disease. Bronchoscopes were introduced orally to spontaneously breathing, non-intubated patients who were under moderate sedation. The average tracheal area occupied by two bronchoscopes in adults was about 12.5%. Initial airway surveillance and debridement, to secure the contralateral airway for ventilation, was done with the Olympus BF-TH190 bronchoscope. The latter was next positioned at the segmental bronchus selected for the biopsy to provide uninterrupted, precise visualization. The second bronchoscope, Olympus BF-P190, was introduced parallel to the BF-TH190, and used to navigate the radial EBUS (Olympus UM-S20-17S, 20 MHz) probe to the biopsy site and to avoid proximity to vascular structures and pleura. The radial EBUS probe was removed and the 1.9 mm cryoprobe (ERBE, Marietta, Georgia) was positioned. The balloon 4 French occlusion catheter (LeMaitre, France) was inserted through the working channel of the BF-TH190 parallel to the cryoprobe. The position of both devices was confirmed with fluoroscopy. The cryoprobe freezing time was 4 seconds. BF-P190, with cryoprobe, was next removed en bloc with simultaneous balloon inflation. The balloon remained inflated for 2 minutes until the BF-P190 was reinserted. Argon-Plasma coagulation 1.6 probe with flow of 0.5 was used for control of persistent bleeding if needed.

Results
There was no uncontrolled pulmonary hemorrhage or pneumothorax in our series and the procedure was tolerated well.

Conclusions
In our experience, this technique allows for preemptive local control of bleeding. We believe that the risk of pneumothorax is decreased in the spontaneously breathing patient. By the virtue of having two bronchoscopes in the airway, we are able to optimize the visualization of the airways from two vantage points and at the same time maximize the application of instruments to procure biopsies and control bleeding.

Bibliography
Gasparini S, Bonifazi M. Cryobiopsy for Interstitial Lung Diseases. J Bronchology Interv Pulmonol. 2016 Jan;23(1):4-6. Poletti V1. Lung cryobiopsies: a paradigm shift in diagnostic bronchoscopy? Respirology. 2014 Jul;19(5):645-54.

Management of Metastatic Endobronchial Renal Cell Carcinoma

Alejandro Sardi[1], Muralidhar Kondapaneni[1], Larry Ladi[1], Rebecca Cloyes[1], Lori Muetzel[2], Thomas Olencki[2], Nitin Bhatt[1], Harsh Shah[1], Shailesh Pinto[1], Shaheen Islam[1]

[1]Interventional Pulmonary. Division of Pulmonary, Allergy, Critical Care and Sleep Medicine., Ohio State University Wexner Medical Center - Usa
[2]Medical Oncology, Ohio State University Wexner Medical Center - Usa

Introduction

Treatment with tyrosine kinase inhibitors (TKIs) has delayed the progression of Renal Cell Carcinoma (RCC) with a longer survival and greater tendency to metastasize. Although RCC metastasizes frequently to the lungs (50-60%), endobronchial metastasis (EBM) is uncommon (2-5%). EBM can cause hemoptysis, central airway obstruction, and post-obstructive pneumonia; and is difficult to treat due to a high tendency for bleeding (1) from these hyper-vascular tumors and treatment with TKIs, that tend to increase bleeding (2). We present a large series of RCC with EBM and describe the therapeutic or palliative treatments used.

Objective

We present a large series of RCC with EBM and describe the therapeutic or palliative treatments used.

Methods

Retrospective case series from 2008 to 2015 at Ohio State University. IRB approved.

Results

12 patients were included. Median age was 63.5 years (52-68 years) and 3:1 male-female ratio. Median smoking was 22-pack year (0-100). Presenting symptoms included hemoptysis (58.3%), central airway obstruction (83.3%) and dyspnea (100%). Ten patients had a lag period of <5 years between nephrectomy and bronchoscopy. Median Karnofsky score at presentation was 75%. Histology included clear cell (66.7%), clear-sarcomatoid cells (24.9%) and papillary (8.3%). A total of 77 procedures (median 1.5, range 1-29), with 69 (89.6%) flexible and 8 (10.3%) rigid bronchoscopies were performed. EBM locations are summarized in Figure 1. Tumor debulking was done with Nd-YAG laser in 25%, argon plasma coagulation in 30%, cautery snare in 9%, balloon dilatation in 29%, cryotherapy in 9%, brachytherapy 7%, photodynamic therapy 12%, and mechanical debulking with rigid or flexible forceps 36.4%. General anesthesia was used in 84% and moderate sedation in 16%. No bleeding was reported in 55%, mild 33%, moderate 9% and severe 4%. Airway recanalization was obtained in 77% of the procedures. Escalation on the level of care was needed in 5%, with 3 ICU and 1 telemetry hospitalization. Four patients died during the study period from other complications. The median survival from initial bronchoscopy was 12.5 months (range 5-73 months). There was no procedure related mortality.

Conclusions

Bronchoscopic intervention offers adequate palliation and successful airway recanalization in patients with RCC with EBM. Moderate to severe bleeding occurred in 13% of patients and escalation of level of care was needed in 5%. The small number of cases precludes adequate statistical inference. However this represents one of the largest case series reported in medical literature.

Bibliography

1. Dobbertin I, et al. Bronchoscopic aspects of renal cell carcinoma (RCC). Anticancer research. 1999;19(2c):1567-72. 2. Schutz FA, et al. Meta-analysis of randomized controlled trials... .J Clin Oncol 2012;30(8):871-7.

19th WCBIP / WCBE World Congress
JOINT MEETING OF THE WORLD ASSOCIATION FOR BRONCHOLOGY AND INTERVENTIONAL PULMONOLOGY & THE INTERNATIONAL BRONCHOESOPHAGOLOGICAL SOCIETY
www.wcbipwcbe2016.org
Fortezza da Basso
May 8-11, 2016
Florence (Italy)

Endobronchial ultrasound elastography in the evaluation of mediastinal and hilar lymph nodes

Cuiyan Guo, Guangfa Wang, Hong Zhang, Wei Zhang

department of respiratory and critical care medicine, Peking University First Hospital - China

Introduction

Elastography is a new method for characterizing tissue stiffness and is now used in various fields of medicine for predictiong maligancy lymph nodes , often in combination with ultrasound.

Objective

This study aims to evaluate the utility of endobronchial ultrasound elastography for mediastinal and hilar lymph nodes.

Methods

Twenty-five patients were underwent endobronchial ultrasound-guided transbronchial needle aspiration?EBUS-TBNA? meanwhile elastography performed. Fifty-six nodes were evaluated and classified based on color distribution as follows: Group 1, predominantly blue (blue area ?50%); Group 2, non-blue (green, yellow and red)??blue area ?50%?. The elastographic patterns were compared with the pathologic results from EBUS-TBNA

Results

Of all the 56 lymph nodes, 29 were malignant and 27 were benign. The lymph nodes that were classified as Group 1 on endobronchial ultrasound elastography were malignant in 25/29 (86.2%) and benign in 4/29(13.8%); for Group 2 lymph nodes,18/27 (66.7%) were benign and 9/27(33.3%) were malignant. Fisher exact test was used for categorical variables and P=0.00. If Group 1 was defined as ‘malignant’ and Group2 as ‘benign,’ the sensitivity, specificity, positive predictive value, negative predictive value were 86.2%, 66.7%, 73.5%, 81.8%, respectively.

Conclusions

Endobronchial ultrasound elastography in the diagnosis of mediastinum nodes is helpful in predicting maligancy.It is also promising as guidance of TBNA in different lymph node masses or limit the number of TBNAs performed

id 306

19th WCBIP / WCBE World Congress
JOINT MEETING OF THE WORLD ASSOCIATION FOR BRONCHOLOGY AND INTERVENTIONAL PULMONOLOGY & THE INTERNATIONAL BRONCHOESOPHAGOLOGICAL SOCIETY
www.wcbipwcbe2016.org
Fortezza da Basso
May 8-11, 2016
Florence (Italy)

Benign tracheal stenosis: brief and long term results in endoscopic and surgical treatment

Giacomo Cusumano, Salvatore Bellofiore, Ignazio Vasta, Carmelo Riscica Lizzio, Rosalia Giarlotta, Saita Salvatore, Alberto Terminella

General Thoracic Surgery, Vittorio Emanuele Policlinico Hospital - Italy

Introduction

Benign tracheal stenosis (TS) include a complex spectrum of conditions, that usually requires different and repeated treatments involving endoscopy and surgery.

Objective

We revised our experience of last 10 years in this setting with particular attention to the brief and long term results and to the clinical and anatomical prognostic factors to success of treatments.

Methods

We included in our study patients with TS who underwent interventional rigid bronchoscopy and/or surgical tracheal resection from 2004 to 2014 in our department. Clinical, etiological and surgical data were collected and analysed. Patients who were decannulated, asymptomatic with normal fibrobronchoscopy for at least 1 year were considered cured.

Results

58 patients received procedures under operative rigid bronchoscopy. Mean age was 54.1 years and Male/female ratio 36/24. Six patients (10.0%) underwent tracheal or laryngotracheal resection, two of these immediately surgically treated. At diagnosis 20(34.4%) patients had acute respiratory failure. The etiology distribution was: iatrogenic 48(80.0%), 37(61.6%) for prolonged intubation and 11(18.3) post tracheostomy, and idiopathic 12(20.0%) TS. In 10 (16.6%); 42(70.0%); 6(10.0%) and 2(3.3%) cases the stenosis involved the trachea in laryngo-tracheal, higher, medium and carenal space, respectively. Complex stenosis were 28(46%). Each patient underwent an average of 2.02 procedures during their course of treatment which included rigid bronchoscopy and mechanical debulking, laser, balloon dilatation and stenting. Mean follow up was 36.5+/-28.2 months. We recorded 3 cases of postoperative acute respiratory failure treated with tracheostomy in 2 cases. 38.4% and 72.2% of patients was considered cured at 1 and 3 years among the iatrogenic stenosis. Surgery was curative in 100% of cases. Complex stenosis ($p<0.001$) required an higer rate of procedure and it is poor factor for successful management ($p<0.05$).

Conclusions

Endoscopic treatment gives good brief and long term results but complex stenosis usually require open surgical procedure for successful management.

id 307

19th WCBIP / WCBE World Congress
JOINT MEETING OF THE WORLD ASSOCIATION FOR BRONCHOLOGY AND INTERVENTIONAL PULMONOLOGY & THE INTERNATIONAL BRONCHOESOPHAGOLOGICAL SOCIETY
www.wcbipwcbe2016.org
Fortezza da Basso
May 8-11, 2016
Florence (Italy)

Endobronchial valves in the treatment of pleuropulmonary fistula with empyema

Giacomo Cusumano[1], Salvatore Bellofiore[1], Daniele Lombardo[2], Ignazio Vasta[1], Carmelo Riscica Lizzio[1], Rosalia Giarlotta[1], Alberto Terminella[1], Salvatore Saita[1]

[1]General Thoracic Surgery, Vittorio Emanuele Policlinico Hospital - Italy
[2]Department of Pulmonary Medicine, Vittorio Emanuele Policlinico Hospital - Italy

Introduction
Pleuropulmonary fistula complicated by empyema is a life-threatening condition especially in patients with pulmonary emphysema. Surgical approaches (resuturing or placing of biological glues) are often disappointing and demolitive surgery, such as thoracostomy and thoracoplasty are often needed.

Objective
We reported a case series of 3 consecutive patients with persistent air leak and empyema, successfully treated by endobronchial valves placement and intracavitary antibiotics infusion.

Methods
All the bronchoscopic procedures included preliminary identification of the area of air leakage by bronchial occlusion using a balloon catheter. The nitinol and silicon valves (Pulmonx®) were inserted by means of flexible bronchoscopy under conscious sedation. Combined intravenous and intrapleural antibiotic treatment was administered in two of three cases. Chest drain was removed after negativity of microbiological essay from pleural liquid and normalization of blood inflammation markers.

Results
Patients were 2 male and 1 female (mean age of 74.6 years). Two patients had severe emphysema with chronic respiratory failure and smoking history. One had rheumatoid arthritis treated with immunosuppressive therapy. Two cases were postoperative air leakage for lung resection and one was persistent spontaneous pneumothorax refractory to chemical pleurodesis. Empyema was due to acynetobacter and pseudomonas aeruginosa in one case, while in the remaining two cases to pseudomonas aeruginosa and staphylococcus aureus, respectively. Procedures were successful in every case. Air-leaks stopped in the first 24 hours after procedure in two patients and 5 days in the remaining one and all were discharged within 8 days without complications. Follow-up was uneventful in all patients. Valves were removed in two patients after 3 and 4 months without complication.

Conclusions
Treatment of pleuropulmonary fistula complicated by empyema is still a challenging, requiring painful surgical solution. Insertion of endobronchial valves is a safe and effective method for treating persistent air leak even during empyema, as valid alternative to surgery, in selected cases.

id 308

Medical thoracoscopy vs VATS in diagnosis of cancer pleural. Our experience

Pietro De Pasquale[1], Riccardo Pellegrini[2], Arturo Roncone[3]

[1]U.O.S.D. Thoracic Surgery - Diagnostic and Operative Tracheobronchial Endoscopy, Azienda Ospedaliera di Cosenza - Italy
[2]U.O.S.D. Thoracic Surgery - Director, Azienda Ospedaliera di Cosenza - Italy
[3]U.O.S.D. Thoracic Surgery, Azienda Ospedaliera di Cosenza - Italy

Introduction

The Medical Thoracoscopy is an endoscopic procedure that follows the birth and the spread of Video-Assisted Thoracoscopy Surgical or VATS. Its diagnostic and therapeutic applications have achieved a fundamental role in the treatment of the pleural disease. At present, this technique is the "gold standard" among the diagnostic procedures and treatment of pleuropatie and, in particular, of the mesothelioma. It allows to perform: collection of pleural fluid; complete evaluation of the pleural cavity; multiple and targeted biopsies of the parietal and visceral pleura; chemical pleurodesis; the staging of pleural mesothelioma, in combination with CT imaging.

Objective

The present work aims to show how the adoption of the so-called Medical Thoracoscopy, performed in not intubated patient, that are spontaneously breathing and are kept in deep sedation and local anesthesia, will allow to get reliable diagnostic results that are overlapping to those performed with VATS. The VATS, instead, is performed in the operating room, under general anesthesia, with the patient selectively intubated to allow the ventilation of a single lung. The increasing interest in the Medical Thoracoscopy is, therefore, tied to its diagnostic reliability with respect to a reduced risk of complications for patients, provided that any contraindications are carefully evaluated and appropriate preventive measures are taken.

Methods

In the period January 2011/December 2015, 379 patients underwent Video- Assisted Thoracoscopy Surgical (VATS); 146 of these procedures were performed only for diagnostic purposes.

Results

The histological results obtained in 146 selected cases, have been reported in the attached table. In more than 1/3 of the patients treated with VATS, Medical Thoracoscopy could have been applied, instead, getting similar results with a lower anesthetic risk; less operating room occupancy; faster recovery of the patients; fewer days of hospitalization.

Conclusions

The practicality and safety of Medical Thoracoscopy makes it indispensable in cases of not otherwise diagnosed pleural effusion. The use of Medical Thoracoscopy has completely changed the approach towards the pleural mesothelioma, enabling the achievement of the diagnosis in almost all cases and allowing its identification in the early stages that are still sensitive to attempts at effective therapy. Moreover, it has identified the precancerous lesions from mesothelioma (black spots), undetectable with other diagnostic methods. The contribution of Medical Thoracoscopy in the diagnosis and management of pleural diseases is increasingly recognized. However, in some hospitals, it is still necessary to encourage the use of Medical Thoracoscopy highlighting its benefits and potentiality diagnostics.

Bibliography

Ryan M. Kern; Zachary S. DePew; Fabien Maldonado. Outpatient Thoracoscopy: Safety and Practical Considerations. Curr Opin Pulm Med 2015;21(4):357-362.

Cancer	N° Patients	%
Mesothelioma	9 patients	6.16 %
Stomach cancer	3 patients	2.05 %
Pancreas cancer	2 patient	1.36 %
Lung cancer	49 patients	33.56 %
Colon cancer	5 patients	3.42 %
Kidney cancer	9 patients	6.16 %
Breast cancer	23 patients	15.75 %
Lymphoma	18 patients	12.32 %
Bladder cancer	3 patients	2.05 %
Ovary cancer	6 patients	4.10 %
Sarcoma	1 patients	0.68 %
Pleurisy chronic nonspecific	18 patients	12.32 %

id 309

19th WCBIP / WCBE World Congress
JOINT MEETING OF THE WORLD ASSOCIATION FOR BRONCHOLOGY AND INTERVENTIONAL PULMONOLOGY & THE INTERNATIONAL BRONCHOESOPHAGOLOGICAL SOCIETY
www.wcbipwcbe2016.org
Fortezza da Basso
May 8-11, 2016
Florence (Italy)

Bronchial carcinoid tumour in childhood: a case report

Luciana Pimenta Bento[1], Telma Sequeira[1], João Eurico Reis[2], José Pedro Boléo-tomé[1], Ivan Bravio[2], Fernando Martelo[2], Fernando Rodrigues[1]

[1]Pulmonology Department, Hospital Prof. Doutor Fernando Fonseca, EPE Amadora - Portugal
[2]Thoracic Surgery Department, Centro Hospitalar de Lisboa Central, EPE - Hospital de Santa Marta - Portugal

Introduction

Carcinoid tumours are rare, well-differentiated, malignant neuroendocrine neoplasms. About 85% of these tumours develop in the gastrointestinal tract but other locations, such as bronchial carcinoids (BCs) have been described. In paediatric patients, despite accounting for the majority of primary lung cancer, their true incidence is not well defined. BCs in childhood often cause airway obstruction but are frequently misdiagnosed as benign conditions, resulting in delay in definitive diagnosis and treatment. Surgery represents the treatment of choice for BCs, and lung-sparing resections are recommended.

Methods

We present a case of a 12-year old boy which went to our emergency department with a 7-day history of haemoptysis. Physical examination and chest radiograph were unremarkable. He was admitted in Paediatrics Department for investigation. CT-scan showed a well-defined, round lesion of 1.6 cm, in the left main bronchus as well as left hilar lymph node enlargement. He underwent a flexible bronchoscopy, which revealed a smooth pink endoluminal mass in the left main bronchus, originating from the upper lobe bronchus opening. Due to high haemorrhagic risk, he was then submitted to rigid bronchoscopy for forceps biopsies. The exam also confirmed the integrity of the left inferior lobar bronchus. The histological analysis was compatible with a neuroendrocrine tumour – atypical carcinoid (2 mitoses/10HPF; Ki67 5%). He was referred to thoracic surgery and underwent left superior sleeve lobectomy - the left main and lower lobe bronchi were joined together. Despite the complexity of the anastomosis procedure, it was accomplished without intra or post-surgical complications. The tumour stage was pT1bN1. The flexible bronchoscopy 3 weeks after the procedure revealed no signs of anastomotic stenosis or leakage. Eighteen months after surgery, the patient has no complaints and just recently began swimming classes. He is under follow-up in Oncology, Pulmonology and Thoracic Surgery, with no evidence of relapse or bronchial stenosis.

Conclusions

BCs tumours are uncommon malignancies in paediatric patients. This case highlights not only the importance of being aware of this condition and promptly diagnosing it in this age group, but also the crucial role of correct surgical treatment, which will confer an excellent prognosis.

id 310

Bronchoscopic management of endobronchial chondromas: study of 7 cases

Tissot Claire[1], Chalbet Sophie[2], Forest Fabien[3], Sauvage Maxime[1], Foudarakis Marios[1], Vergnon Jean Michel[1]

[1]Service de Pneumologie, Hopital universitaire de Saint Etienne - France
[2]Service de Pneumogie, Hopital universitaire de Saint Etienne - France
[3]Service d'Anatomopathologie, Hopital universitaire de Saint Etienne - France

Introduction

Endobronchial chondromas are rare benign tumors. They may be a part of the Carney triad or be isolated. Because of the rarity of these tumors, associated clinicopathological features and outcomes have not been thoroughly described so far.

Objective

The aim of this study is to describe clinicopathological characteristics, bronchoscopic management and outcomes of patients with endobronchial chondromas.

Methods

We retrospectively collected clinicopathological characteristics, bronchoscopic findings, treatments and the outcomes of patients with endobronchial chondromas who underwent a bronchoscopy in our institution between January 1995 and December 2015.

Results

Endobronchial chondromas were identified in seven patients, consisting of 3 women and 4 men with median age of 73 years (46-87 years). Four patients were never smokers and three patients were current or former smokers. All patients were symptomatic, and the most frequent clinical presentation was obstructive pneumonia. The most common bronchoscopic finding were pedunculated, poorly vascularized, pink tumors. Treatment consisted in bronchoscopic mechanical resection in six cases, associated with HF electrocautery in 3 cases and with cryotherapy in 1 case. One patient underwent a lobectomy. None of the patients died and the outcome was favorable in all cases.

Conclusions

We report the largest series of endobronchial chondromas. Isolated endobronchial chondromas are extremely rare. They differ pathologically from endobronchial hamartomas or chondrosarcomas. Bronchoscopy is a useful tool for the diagnosis and is safe and effective for the treatment of endobronchial chondromas. A better knowledge of these benign tumors is important to improve the diagnosis and the management of endobronchial chondromas and prevent airway obstruction.

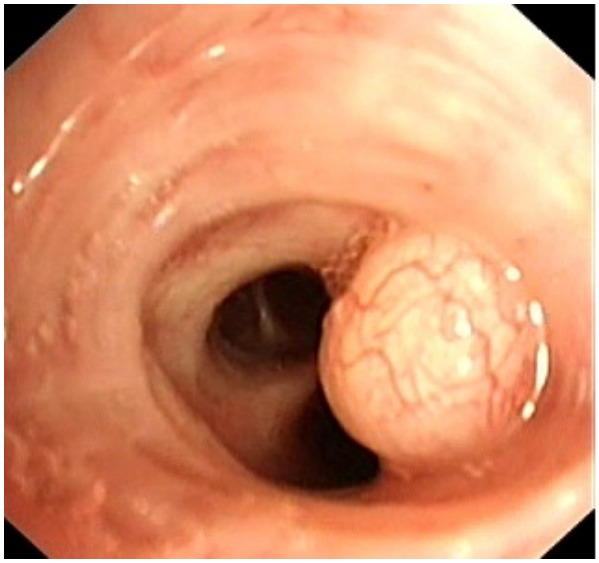

id 311

19th WCBIP / WCBE World Congress
JOINT MEETING OF THE WORLD ASSOCIATION FOR BRONCHOLOGY AND INTERVENTIONAL PULMONOLOGY & THE INTERNATIONAL BRONCHOESOPHAGOLOGICAL SOCIETY
www.wcbipwcbe2016.org
Fortezza da Basso
May 8-11, 2016
Florence (Italy)

Cerebral tumor embolism in a patient with stage IV lung cancer

Klaus D. Lessnau[1], Wojciech Palka[2]

[1]Interventional Pulmonology, Lenox Hill Hospital/ Hofstra University - Usa
[2]Pulmonology, Lenox Hill Hospital/ Hofstra University - Usa

Introduction
Airway hemorrhage and obstruction from stage advanced central airway lung cancer is a cause of significant morbidity and mortality. Palliative bronchoscopic control and debulking is often used to improve quality of life in such patients. Complications include uncontrolled airway hemorrhage, respiratory failure and gas embolism.

Objective
We describe an unusual thromboembolic event after bronchoscopy.

Methods
A 76 year old man with a history of atrial fibrillation on clopidogrel was newly found to have a stage IV poorly differentiated lung carcinoma. He presented with non-resolving pneumonia and worsening hemoptysis. He had pleuritic chest pain, cough with hemoptysis, and weight loss after a life long history of smoking. When he did not improve after antimicrobial treatment CT chest was obtained which showed an extensive mass of the right lung. PET scanning was consistent with stage IV lung cancer. Clopidogrel for coronary artery disease was on hold for five days prior to the procedure, and his atrial fibrillation resolved with metoprolol. The patient underwent flexible bronchoscopy with Neodymium YAG laser and argon plasma coagulation for control of hemorrhage and right central airway reopening. Moderate sedation was used with fentanyl (100 microgram) and titrated midazolam at 1 milligram aliquots, to a total of 9 milligrams. The Nd YAG laser was used with 18 Watts, intermittent pulse non-contact mode. Argon plasma coagulation was used with a flow of 0.7 L/min and 27 Watts. The procedure time was 59 minutes and continuous oxygen saturation was always in the 90s. After the bronchoscope was removed the patient suddenly developed bradycardia. This was treated instantly with low dose epinephrine and atropine. There was no evidence of hypotension. Hemodynamically the patient immediately recovered but did not gain complete consciousness and was aphasic. An immediate CT scan was normal without evidence of gas emboli. Transthoracic echocardiogram revealed a low ejection fraction of 25%. MRI on day two showed emboli consistent with fat. There was no evidence of air embolism. He was monitored for several days and with no additional events. His aphasia resolved partially. Radiation and chemotherapy were deemed to be unhelpful. The patient was transferred to a hospice for comfort care.

Results
This cases illustrates that lung cancer may extend into the pulmonary venous system and potentially cause tumor embolization of the brain. The incidence of such an event is low and the association with tumor debulking is not understood.

Conclusions
There is pathophysiology of stroke that is beyond gas and air embolism.

id 312

Endoscopic approach to post-tuberculosis bronchial stenosis: a case series

Luciana Pimenta Bento, Telma Sequeira, José Pedro Boléo-tomé, Rui Costa, Fernando Rodrigues

Pulmonology Department, Hospital Prof. Doutor Fernando Fonseca, EPE Amadora - Portugal

Introduction

In 2014, Portugal had a tuberculosis (TB) incidence of 20/100000, which highlights the importance of this disease in the country. Studies have shown that up to 70% of the patients with tracheobronchial tuberculosis can develop post-TB bronchial stenosis (PTBS), even if they completed the full treatment regimen. There is no consensus regarding the best endoscopic approach to these patients.

Objective

To describe PTBS cases diagnosed in our department and to assess the efficacy of endoscopic treatment in these patients.

Methods

Retrospective study of all PTBS case files since 2006 (10 years).

Results

We included 10 patients, 8 of which were female. The mean age was 45.0 [min 23; max 74]. A diagnosis of PTBS was concomitant with that of active TB in 60% of the cases. In average, the remaining PTBS cases were identified 48.7 months [min 3; max 96] after TB diagnosis. Total or partial atelectasis was the most common imaging finding (70% of the patients) and the majority of cases occurred in the right bronchial tree (60%). All patients underwent endoscopic treatment. Two of them were submitted exclusively to photocoagulation and mechanical dilatation, whereas the remaining 8 needed placement of silicone stents after dilatation. One patient was later submitted to left pneumectomy because of the extensive tracheomalacia and stenosis and another one was lost to follow-up. During follow-up time (median 31 months) the patients were submitted on average to two flexible bronchoscopies and four rigid bronchoscopies. The most common post-procedure complications were granulation tissue formation (5 patients) and bronchomalacia (4 patients). After removal of the first stent three patients had to place another one due to re-stenosis. Five patients kept the stent for an average of 5.5 months (min 2; max 27); three patients still have the stent (average time of 28 months). Despite symptomatic improvement in all patients, the following complaints are noticed: dry (n=5) or productive cough (n=4), the latest more common in patients with a stent in place; fatigue and dyspnea (mean score of mMRC scale 1.7).

Conclusions

Despite being rare, PTBS is associated with high morbidity. Bronchoscopy plays a crucial role in the restoration of the tracheobronchial tree, but also in the follow-up of all cases with endobronchial TB, even if they don't show stenosis at the time of diagnosis. Furthermore, after endoscopic treatment, re-stenosis rate is not negligible, so it is important to define the best endoscopic approach and the optimal timing of stent removal.

id 313

Robotic Catheter Control for Lung Navigation

Alexander Jaeger[1], Pietro Nardelli[1], Josef Tugwell[1], Kilian O\' Donoghue[1], Conor O\' Shea[1], Kashif Al Khan[2], Marcus Kennedy[2], Pádraig Cantillon-murphy[1]

[1]School of Engineering, University College Cork - Ireland
[2]Respiratory Medicine, Cork University Hospital - Ireland

Introduction

Image guidance is becoming an increasingly effective modality particularly for improving diagnostic yields for peripheral nodule biopsy. Commercially available electromagnetic navigation bronchoscopy (ENB) systems from SuperDimension and Veran Medical provide the clinician with a image guided navigation to the target nodule. This work describes the development of a novel image-guided automated working channel catheter and its application in lung biopsy.

Objective

The catheter designed in this work provides a working channel, position tracking and four steerable tendons. The tracking sensor is compatible with existing ENB systems while the working channel enables the use of standard endoscopic instruments. Four tendons are connected to an electromechanical system (see figure) allowing catheter deflection through a computer joystick. By combining virtual image guidance with joystick control of the catheter tip, we aimed to demonstrate and evaluate a navigation system capable of visually guiding and assisting clinicians in navigating the lung beyond the field of vision of traditional bronchoscopes.

Methods

The system was validated though ex-vivo experiments and an in-vivo animal study. The live animal study consisted of navigating to seven pre-placed phantom tumour models placed in the upper, middle and lower lung lobes of an anaesthetised pig. The radio-opaque tumour models consisted of both tripe samples and an agarose-based recipe. Image-guided navigation to highlighted tumour targets was performed using the open-source 3D Slicer imaging tool[1] with a custom electromagnetic tracking system [2]. The joystick was used to deflect the catheter tip through narrow bronchi en-route to each target. A usability study of the navigation system was also performed by demonstrating the navigation system to nine clinicians unaffiliated with this work. Each clinician was tasked with navigating to three pre-determined locations within an ex-vivo lung model. The system usability scale (SUS) was used to determine an overall Usability Score.

Results

Successful navigation biopsy of the seven tumour targets was achieved with an average navigation time of ~10 seconds. The catheter tip was successfully deflected using the joystick to assist in navigating narrow tertiary bronchi. The usability study featured an average navigation time of ~58 seconds.

Conclusions

We have shown catheter automation can be used in bronchoscopy to navigate and biopsy lung nodules. We have demonstrated the first reported design and pre- clinical study of a position-tracked working channel catheter capable of automated deflection. Results from the usability study indicated a positive response from all clinicians, with system complexity and learning difficulty being the primary concerns.

Bibliography

[1] K. O'Donoghue and P. C. Murphy, Catheter position tracking system using planarmagnetics and closed loop current control," IEEE Transactions on Magnetics, vol. 50,no. 7, 2014 [2] www.slicer.org



(a) Catheter actuation system (b) Catheter with forceps (c) Assembled system in-vivo study

id 314

19th WCBIP / WCBE World Congress
JOINT MEETING OF THE WORLD ASSOCIATION FOR BRONCHOLOGY AND INTERVENTIONAL PULMONOLOGY & THE INTERNATIONAL BRONCHOESOPHAGOLOGICAL SOCIETY
www.wcbipwcbe2016.org
Fortezza da Basso
May 8-11, 2016
Florence (Italy)

Diagnostic accuracy and safety of transaortic EUS-FNA in subaortic and para- aortic lymph nodes

Sara Colella, Cristina Pavani, Luca Viglietta, Sara Tomassetti, Claudia Ravaglia, Christian Gurioli, Carlo Gurioli, Venerino Poletti

Pulmonary Unit, Department of Thoracic Diseases, Azienda USL Romagna, GB Morgagni-L-Pierantoni Hospital - Italy

Introduction

Sub- aortic (station 5) and para- aortic (station 6) lymph nodes are not easy to access with endosonography due to the interposition of the aorta and of the left pulmonary artery. Taking a biopsy from those stations could be of value in lung cancer staging, especially in cases with a left upper lobe lung tumor. Surgery is to date the gold standard in the evaluation of mediastinal lymph nodes [1], but EUS-FNA (Endoscopic Ultrasound- Fine Needle Aspiration) has been proposed as a minimally invasive technique in the evaluation stations 5 and 6 through the trans- aortic approach, with a good diagnostic yield and a good safety profile [2].

Objective

To evaluate the diagnostic accuracy and the safety of the trans- aortic EUS-FNA in sub- aortic and para-aortic lymph nodes.

Methods

We retrospectively reviewed all patients admitted to our endoscopic unit from 2010 to 2015 that underwent trans- vascular EUS-FNA for an enlargement or a PET- CT (integrated 2-deoxy-2-fluoro- D-glucose positron emission tomography/computed tomography) positivity in mediastinal lymph nodes in station 5 and 6. Demographic characteristics, site and size of the lesion, needle size, final diagnosis and complications were collected.

Results

Eight patients were included in the analysis, 4 males, median age 61 years (range 45-73). EUS-FNA was performed under conscious sedation with a 22 Gauge needle in 6 patients and with a 21 Gauge needle in 2. Station 6 was sampled in six cases and station 5 in two, with a mean lesion size of 29,3 x 21,6 mm. The diagnosis was reached in 5 out of 8 patients (62.5%): 4 patients had a diagnosis of lung cancer (2 adenocarcinoma, 2 squamocellular carcinoma) and 1 patient had a diagnosis of benign process. Standard cytology allowed the diagnosis in 2 patients (2 adenocarcinoma), cell block in the remaining 3 patients (1 benign, 2 squamocellular carcinoma) in which standard cytology was negative. EUS-FNA did not reach the diagnosis in 3 patients, out of them one was confirmed to be negative for malignancy at clinical follow-up and 2 patients were lost in follow up. No complications occurred.

Conclusions

As reported in previous studies [2], our report confirms that EUS-FNA could be a valuable diagnostic tool in the evaluation of the mediastinal lymph nodes located in station 5 and 6, due to its good diagnostic yield and its safety.

Bibliography

1) Cerfolio RJ et al. Ann Thorac Surg. 2007 Sep;84(3):940-5. 2) von Bartheld MB et al. Gastrointest Endosc. 2009. Feb;69(2):345-9.

19th WCBIP / WCBE World Congress
JOINT MEETING OF THE WORLD ASSOCIATION FOR BRONCHOLOGY AND INTERVENTIONAL PULMONOLOGY & THE INTERNATIONAL BRONCHOESOPHAGOLOGICAL SOCIETY
www.wcbipwcbe2016.org
Fortezza da Basso
May 8-11, 2016
Florence (Italy)

Performance of EBUS-TBNA for diagnosis of isolated mediastinal and hilar lymphadenoapthy

Chung-chun Tyan[1], Tiago Machuca[2], Kasia Czarnecka[1], Hyang Mi Ko[3], Gilda Da Cunha Santos[3], Scott Boerner[3], Andrew Pierre[4], Marcelo Cypel[4], Tom Waddell[4], Gail Darling[4], Marc De Perrot[4], Shaf Keshavjee[4], William Geddie[3], Kazuhiro Yasufuku [4]

[1]Division of Thoracic Surgery and Division of Respirology, University Health Network, University of Toronto - Canada
[2]Division of Thoracic Surgery, University Health Network - Canada
[3]Department of Laboratory Medicine and Pathobiology, University Health Network, University of Toronto - Canada
[4]Division of Thoracic Surgery, University Health Network, University of Toronto - Canada

Introduction

Patients with isolated mediastinal and hilar lymphadenopathy (IMHL) pose a challenge to clinical diagnosis. Although many studies have assessed the diagnostic utility of Endobronchial ultrasound-guided transbronchial needle aspiration (EBUS-TBNA) in the context of a specific disease, few studies have assessed the overall diagnostic yield, sensitivity, accuracy and negative predictive value in patients with IMHL.

Objective

We evaluated the performance of EBUS-TBNA for diagnosing IMHL in a population with a high prevalence of concurrent or pre-existing non-pulmonary malignancy.

Methods

A retrospective chart review of patients who underwent EBUS-TBNA from October 2008 to April 2014 was performed to identify patients with IMHL. Patients with known or suspected primary pulmonary malignancy were excluded. When available, EBUS-TBNA results were cross-referenced with further diagnostic investigation or clinical diagnosis based on follow- up.

Results

EBUS-TBNA was used to sample 765 lymph nodes from 350 patients with a mean age of 57 years (+/- 14 SD). One hundred fourteen (33.3%) patients had a concurrent or pre- existing non-pulmonary malignancy. The overall yield of EBUS-TBNA for specific diagnosis was 87% (303/350). Amongst 47 non-diagnostic patients, 25 patients' EBUS-TBNA yielded an insufficient sample and 22 patients' EBUS-TBNA yielded a false negative diagnosis based on further investigations. The most common diagnosis was sarcoidosis (148, 42%) followed by reactive lymphocytosis (104, 30%), lymphoma (32, 9%; Hodgkin 9, 3%; Non-Hodgkin 23, 6%), metastatic lymphadenopathy from extrathoracic malignancy (25, 7%), necrotizing granuloma (18, 5%), lung cancer (16, 5%) and others (7, 2%). Complete pathologic workup using EBUS-TBNA samples alone was achieved in 83% (123/148) of sarcoidosis patients, 84% (27/32) of lymphoma patients, 80% (20/25) of metastatic lymphadenopathy from extrathoracic malignancy patients, and 72%(13/18) of patients with infectious lymphadenopathy. Further invasive investigations at the discretion of referring physicians were done 8% (29/350) of patients. Overall, EBUS-TBNA had a sensitivity of 91%, accuracy of 94% and a negative predictive value of 83%.

Conclusions

For patients with isolated hilar or mediastinal lymphadenopathy and high background prevalence of concurrent and pre-existing non-pulmonary malignancy, EBUS-TBNA is a reliable and accurate diagnostic investigation.

19th WCBIP / WCBE World Congress
JOINT MEETING OF THE WORLD ASSOCIATION FOR BRONCHOLOGY AND INTERVENTIONAL PULMONOLOGY & THE INTERNATIONAL BRONCHOESOPHAGOLOGICAL SOCIETY
www.wcbipwcbe2016.org
Fortezza da Basso
May 8-11, 2016
Florence (Italy)

Versatility of amplatzer device for endoscopic closure of bronchial fistulas

Eliseo Passera

Thoracic Surgery Departmente, Humanitas Gavazzeni Hospital - Italy

Introduction

Bronchial fistula (BF) represents an abnormal form of communication between the bronchial tree and one of its anatomical nearby structures, in particular pleural cavity, esophagus, vessels. These kinds of fistulas could be mainly a consequence of a surgical procedure or, more rarely, of oncologic treatments (chemotherapy or radiotherapy), infections or traumas. Amplatzer device (AD) has been successfully used for endoscopic closure of a BF since 2006.

Objective

We evaluated the safety and efficacy of Amplatzer device to close an abnormal communication between bronchus and every other structures (pleura, esophagus, vessels).

Methods

A total of 17 patients have been treated with Amplatzer device to close 17 fistulas of the airways as a complication of a surgical procedure or an oncologic treatment. BFs were sealed under moderate sedation with flexible bronchoscope by either AD (n=11) or AVP (n=6). The average follow-up period was 21.4 months (range 4-62 months).

Results

Between June 2010 and December 2015, 17 patients (15 men and 2 women) underwent an endoscopic closure of bronchial fistula: 11 were central broncho-pleural fistulas after lung resection, 2 peripheral bronchopleural fistulas (1 after lung resection and 1 after necrotizing pneumonia), 3 bronchovascular fistulas (1 after radiofrequency treatment, 1 post-TB infection, 1 in a patient with a bleeding lung metastasis from kidney neoplasia), 1 bronchoesophageal fistula (after chemo-radiotherapy for advanced esophageal neoplasia). All patients undersigned a consent form for an “off label” procedure. The underlying disease was oncologic in 11 patients. No mortality in a 30-day postoperative period has been observed. At follow up, 12 patients are still alive. In 3 out of 5 patients with late mortality, death was directly related to cancer relapse or cancer progression; no patient died due to BF recurrence. In all the patients, the bronchoscopic procedure was successful and symptoms related to BF disappeared following closure by the AD.

Conclusions

Endobronchial closure of BF using Amplatzer devices is a minimally invasive effective modality of treatment with high safety profile and satisfactory long-term outcome; versatility of this device could be a useful method to close different kinds of fistulas of bronchial tree.

id 317

Therapeutic workup of a relapsing tracheal complex stenosis

Maria Grazia Covesnon, Annalisa Brianti, Giovanni Paolo Ivaldi, Lorenzo Stellino, Claudio Francesco Simonassi

U.O. Pneumologia, ASL 3 Genovese - Italia

Introduction

Granulomatous repair may characterize the healing process in benign tracheal stenosis, most frequently due to either jatrogenic damage, as in case of prolongued intubation and tracheostomy, or to granulomatous diseases (granulomatosis with polyangiitis; sarcoidosis) and infections (TB, Mycosis). Regardless of the cause, morphological features lead to the treatment choice, being surgery the recommended approach for the so called tracheal complex stenosis

Methods

A 51-years-old man ex smoker with a past history of surgery for a basic cranial granulomatous disease was admitted to intensive care unit and submitted to tracheal intubation after status epilepticus caused by meningeal granulomatosis. About 2 months later, he developed dyspnea and underwent bronchoscopy. A tracheal restriction far 3 cm from the larynx with a lenght of 4,5 cm, equal to slightly more than 40% of tracheal extension, was observed. Tracheal enlargement was obtained endoscopically with nd:YAG laser application according to Shapshey, followed by mechanical dilatation. Tracheal biopsy revealed granulomatous lesion. A few days later, because of a further decrease in tracheal caliber, the patient underwent a new laser application followed by the placement of a silicon stent (Dumon 12X4). One month later, the treatment was repeated because the distal stent dislocation showed a critical stenosis with a diameter of 6 mm. Unfortunately, the attempt of positioning another stent was ineffective because of its incomplete opening, even using a caliber as small as possible (11X4) so the patient was led to percutaneous tracheostomy.

Conclusions

Besides etiology, lenght and morphological features of tracheal complex stenosis may give indication for endoscopic treatment firstly with laser and mechanical dilatation. Sudden relapses require tracheal stenting but when dislocation of the stent and recurrent relapses occur despite the use of silicon devices, the only choice left worth considering is tracheostomy.

id 318

Multidisciplinary approach to a patient with lung cancer

Mihovil Roglic[1], Sonja Badovinac[1], Marta Korsic[1], Marko Jakopovic[1], Zoran Janevski[2], Josip Joachim Grah[3]

[1]Department for respiratory diseases Jordanovac, University Hospital Center Zagreb - Croatia
[2]Department for thoracic surgery, University Hospital Center Zagreb - Croatia
[3]Department for oncology, University Hospital Center Zagreb - Croatia

Introduction

Lung cancer has the highest mortality among cancers, mostly due to late diagnosis and advanced stage of the disease. Not many therapeutic options are left at that point, especially not for radical therapy. Yet, sometimes combining different modalities of therapy can make a difference.

Methods

A 62-year old male presented to our hospital with dyspnea and cough. He had respiratory insufficiency and atelectasis of the right lung on chest X-ray. Bronchoscopy revealed a tumor obstructing the right main bronchus and biopsy confirmed a squamous cell carcinoma diagnosis. CT scan was not helpful because of atelectasis. Since tumor seemed polypoid and emerging from right upper bronchus we performed a rigid bronchoscopy and recanalization of the right main bronchus with electro cautery snare. Upon procedure patient felt much better, without dyspnea and chest X-ray confirmed reexpanded right lower and middle lobe. Repeat CT scan showed a locally advanced disease (T4N2M0). Thus we treated the patient with concomitant chemoradiotherapy. He received 60 Gy radiation in 2 Gy fractions and two cycles of cisplatin/etoposide combination chemotherapy, modified protocol for concurrent chemoradiotherapy. Reevaluation PET CT showed good response to therapy with regression of mediastinal lymphadenopathy as well as primary tumor. Patient then underwent surgery with resection of right upper lobe and mediastinal lymph nodes. Pathology confirmed squamous cell cancer diagnosis, stage IA (T1aN0M0). No adjuvant therapy was needed and patient has now regular check-ups.

Conclusions

In few lung cancer cases is possible to achieve radical effect with therapy and long term survival. Rarely can it be done with just one therapeutic modality. For that reason we need to combine several therapies whenever possible in order to produce better therapeutic response and prolong patient survival.

id 319

19th WCBIP / WCBE World Congress
JOINT MEETING OF THE WORLD ASSOCIATION FOR BRONCHOLOGY AND INTERVENTIONAL PULMONOLOGY & THE INTERNATIONAL BRONCHOESOPHAGOLOGICAL SOCIETY
www.wcbipwcbe2016.org
Fortezza da Basso
May 8-11, 2016
Florence (Italy)

Oki Stent application in different indications: Six cases

Mehmet Akif Özgül[1], Erdo?an Çetinkaya[1], Mustafa Çörtük[2], Elif Tanr?verdi O[1], Binnaz Zeynep Y?ld?r?m[1], Merih Balc?[3], Adamu Issaka[1], Güler Özgül[4]

[1]Chest Diseases, Yedikule Chest Diseases and Thoracic Surgery Training and Research Hospital - Türkiye
[2]Chest Diseases, Karabuk University Faculty of Medicine - Türkiye
[3]Chest Diseases, Kartal Kosuyolu Yuksek Ihtisas Training Hospital - Türkiye
[4]Chest Diseases, Bagcilar Education and Research Hospital - Türkiye

Introduction
We have used Oki stents in various different indications and have developed some experience on the subject. After discovering the limited reports in the literature, we were motivated to share our experience in Oki stenting.

Objective
Oki stent is a relatively recent development in pulmonology. While there is vast knowledge on double Y-stents, Oki stents are mainly a darker area. We have tried to show our collegues stenting of right secondary carina should be kept in mind in the obstructions of this region.

Methods
13x10x9 mm Oki stent was placed through rigid bronchoscopy under intravenous sedation.

Results
Oki stent can safely be used in clinical conditions such as bronchopleural fistula, aberrant subclavian artery and aortic arc compression and finally right bronchial fistula accompanying malacia. They are well-tolerated.

Conclusions
Oki stents can safely be used in many clinical conditions. Patients benefit greatly from stenting.

Bibliography
1-Oki M, et al. Chest 2013;144(2):450-5. 2-Lopez-Padilla D, et al. Eur J Cardiothorac Surg 2015.

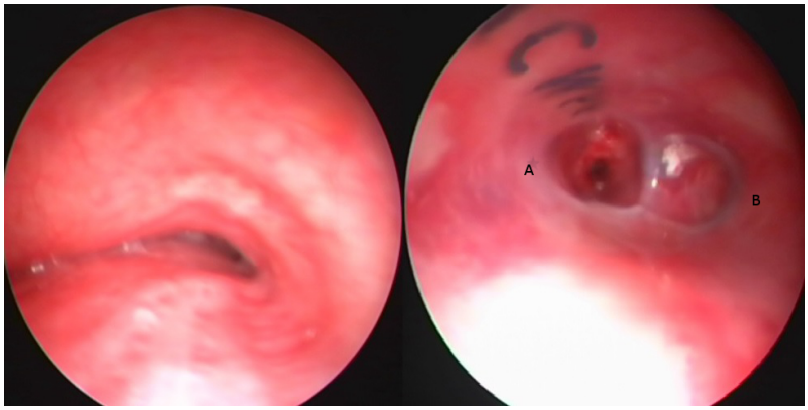

19th WCBIP / WCBE World Congress
JOINT MEETING OF THE WORLD ASSOCIATION FOR BRONCHOLOGY AND INTERVENTIONAL PULMONOLOGY & THE INTERNATIONAL BRONCHOESOPHAGOLOGICAL SOCIETY
www.wcbipwcbe2016.org
Fortezza da Basso
May 8-11, 2016
Florence (Italy)

Diagnostic bronchoscopy for primary lung cancer and EBUS-TBNA for lymph node stage on one-stage

Ayumu Otsuki[1], Masafumi Misawa[1], Ryuta Tsuzuki[1], Fumi Suzuki[1], Satoshi Yamawaki[2], Junko Watanabe[1], Masahiro Katsurada[1], Kei Nakashima[1], Satoshi Noma[1], Masahiro Aoshima[1]

[1]Pulmonary, Kameda Medical Center - Japan
[2]Pulomonary, Kameda Medical Center - Japan

Introduction

For the order-made treatment for lung cancer, to diagnose and to stage them pathologically is important. In our institution, owing to the utilization of the virtual bronchoscopic navigation (VBN) at the time of endobronchial ultrasonography with a guide sheath (EBUS-GS) since 2010, the examination time is getting shorter. Thus, we can perform VBN-EBUS-GS for the diagnosis of the lung cancer and endobronchial ultrasound-guided transbronchial needle aspiration (EBUS-TBNA) for lymph node staging on one-stage bronchoscopy. However, the evaluation of this one-stage bronchoscopy has not ever been reported.

Objective

We aimed to analyze the diagnostic results for the peripheral lung cancer cases with suspected lymph node metastases which underwent VBN-EBUS-GS alone, EBUS-TBNA alone and both of their one-stage performing.

Methods

From Jan. 2012 to Jul. 2015, we retrospectively assessed the 146 cases utilizing VBN-EBUS-GS alone for the primary lesion, the 29 cases utilizing EBUS-TBNA alone for lymph node staging and 27 cases utilizing both of their one-stage performing. Three types of video-bronchoscope (1T-260 Olympus®, P-260F Olympus®, UC-260FW Olympus®) and two types of VBN (LungPoint®, ziostation2®) were selected.

Results

As for only VBN-EBUS-GS cases, the median examination time was 28 minutes, the median diameter of the major axis of a primary lesion was 21.9 mm and its diagnostic accuracy was 76.0%. In only EBUS-TBNA cases, the median examination time was 33.0 minutes, the median diameter of the minor axis of a lymph node was 9.0mm, the median number of the lymph nodes punctured was 2.0 and the median puncturing time was 3.0 times. In one stage cases, the median examination time was 42 minutes, the median diameter of the major axis of a primary lesion was 24.7mm, the diagnostic accuracy of VBN-EBUS-GS was 66.7%, the median diameter of the minor axis of a lymph node was 11.0mm, the median number of the lymph nodes punctured was 1.0 and the median puncturing time was 2.0 times. There was no statistically significant difference in the accuracy of diagnosis between VBN-EBUS-GS alone and the one-stage performing ($p=0.34$). And there were no statistically significant differences in the diameter of the minor axis ($p=0.08$), the number of the lymph nodes punctured ($p=0.13$) and the puncturing time ($p=0.08$) between EBUS-TBNA alone and one- stage performing.

Conclusions

One-stage performing appears not inferior to VBN-EBUS-GS alone or EBUS-TBNA alone in its quality. So in urgent situation, one stage performing is also possible.

id 321

Prospective study of the safety of flexible bronchoscopy under propofol sedation in elderly patients

Marco Solís[1], Marcos Hernandez[1], Cesar Duran[2], Roberto Duré[1], Silvia Quadrelli[1]

[1]Pulmonology, Sanatorio Güemes University Hospital - Argentina
[2]Anesthesiology, Sanatorio Güemes University Hospital - Argentina

Introduction

There are many indications to undergo flexible bronchoscopy in elderly patients. The most of the elderly patients could have at any time, infections disease, oncologic symptoms or hemoptysis and we need to be sure to make the bronchoscopic correct decision

Objective

The BTS recommends that sedation for FOB should be offered to all patients. This study evaluates the safety of FOB under sedation in elderly patients.

Methods

Is a prospective observational study. Sedation was administered by a board-certified anaesthetist. Patients were premedicated (i.v.) with metoclopramide 10 mg., fentanyl initial dose: 25 µg, midazolam initial dose 2-3 mg. After an initial 50 mg i.v. propofol, the dose was then carefully titrated according to the ASA physical status classification

Results

The duration of the procedure was not different between the two groups (14.9 ±3.82 vs 14.7 ±3.75 min p = 0.698). Complications were very infrequent in both groups (13.9 vs 9.2%, p = 0.070). In the group of patients older than 65 years, there was no correlation between the lowest SaO2 during the procedure (p = 0.113) or the SaO2 at the end of the procedure (p = 0.429) and the baseline FEV1. Neither the presence of a fall in the SaO2 greater than 4 points (41.7 vs 39.1% p= 0.321) nor a SaO2 lower than 90% during the procedure (24.4 vs 17.5% p= 0.18). Procedures like bronchoalveolar lavage (BAL) and transbronchial biopsy (TBB) did not were different in both groups (p= 0.793 and 0.389 respectively)

Conclusions

We conclude that FOB under conscious sedation by a certified anesthesiologist is a safe procedure in elderly patients, and performing procedures as BAL and TBB does not increase the risk of complications.

Bibliography

Honeybourne D, et al. Thorax 2001; 56: I1–I21 Matot I, et al. Resp. Med. 2000; 94: 1145–53 Clark G, et al Eur. Respir. J. 2009; 34: 1277–83

	> 65 years n(%)	< 65 years n(%)	*P*
FEV < 50%	15 (9.9%)	29 (6.5 %)	0.113
Immunosuppressed	18 (11.9%)	54 (12.1 %)	0.554
Bad tolerance	2 (1.4%)	12 (2.7 %)	0.279
Good tolerance	97 (64.2%)	289 (64.7 %)	0.501
Complications	21 (13.9%)	41 (9.2 %)	0.070
Complications included SAT <90%	21 (24.4%)	43 (17.5 %)	0.108
Fall Sat O2 > 4 points	63 (41.7%)	175 (39.1 %)	0.321
Fall Sat O2 > 10 points	7 (4.6%)	25 (5.6 %)	0.416
SAT < 90% more than a 1 minute	10 (66.7%)	17 (37.1%)	0.043

id 322

An unespected, unusual, bronchoscopy

Mauro Bruno[1], Filippo Patrucco[2], Maurizio Spandre[1], Alida Andrealli[1], Claudio De Angelis[1], Michela Bellocchia[2], Francesco Guerrera[3], Paolo Solidoro[2]

[1]Department of Medical Sciences, Division of Gastroenterology and Hepatology, "Città della Salute e della Scienza" Hospital and University of Torino - Italy
[2]Cardiothoracic Department, Division of Respiratory Medicine, "Città della Salute e della Scienza" Hospital and University of Torino - Italy
[3]Cardiothoracic Department, Division of Thoracic Surgery, "Città della Salute e della Scienza" Hospital and University of Torino - Italy

Introduction

Since 2001, the diagnosis of small-bowel disorders has been revolutionized by the apparition of wireless capsule endoscopy. The most frequent complication of this technique is retention. Only few cases of inhalation of the videocapsule are reported in literature.

Methods

A 75 y.o. man with history of chronic anemia was referred for video capsule endoscopy of the small bowel. He had a positive fecal occult blood test but upper gastrointestinal endoscopy and colonoscopy were unrevealing for a cause of bleeding. The patient denied history of dysphagia or swallowing disorders. On ingestion of the device no coughing or respiratory symptoms appeared. The patient was invited to come back to the hospital 12 hours later to retrieve the data-recorder. Analysis of the video revealed that the capsule had stayed in his bronchial tree moving from the trachea to the right main bronchus, from the first to the seventh hour. During this period he had been completely asymptomatic. Seven hours after ingestion the first image of the esophagus appeared. The patient told us that bending forward he had found the capsule in his mouth and he had swallowed it again without any problem.

Conclusions

Wireless capsule endoscopy has allowed direct non-invasive mucosal investigation of the small bowel and has revolutionized the diagnosis and management of small bowel disorders, especially gastro-intestinal bleeding after negative gastroscopy and colonoscopy, Crohn's disease, assessment of celiac disease and familial polyposis syndrome. The retention is the most frequent complication, occurring in 0,75-3% of cases, and aspiration occours rarely. Capsule endoscopy is contraindicated in patients with documented swallowing disorders. In this kind of patients and in ones having difficulty in swallowing the capsule after two or three attempts, upper endoscopy can be useful in order to deploy the capsule directly into the duodenum. When real-time capsule location is more readily available, the abdomen can be scanned after the initial ingestion to be sure that the capsule reached the stomach. In literature, some cases reported the expulsion of the capsule by the cough, in another case the capsule had to be removed by rigid bronchoscopy. In these casse the most useful tool to use is a basket to avoid any bronchial injury; forceps can't be useful because of the smooth capsule surface. In asympthomatic cases of inhalation there isn't a clear timing for the recovery as the inhalation is often diagnosed during the data recovery.

Bibliography

Choi HS, et al. Gut Liver 2010; 4:114-116 Guy T, et al. Interact Cardiovasc Thorac Surg 2009; 8:568-570

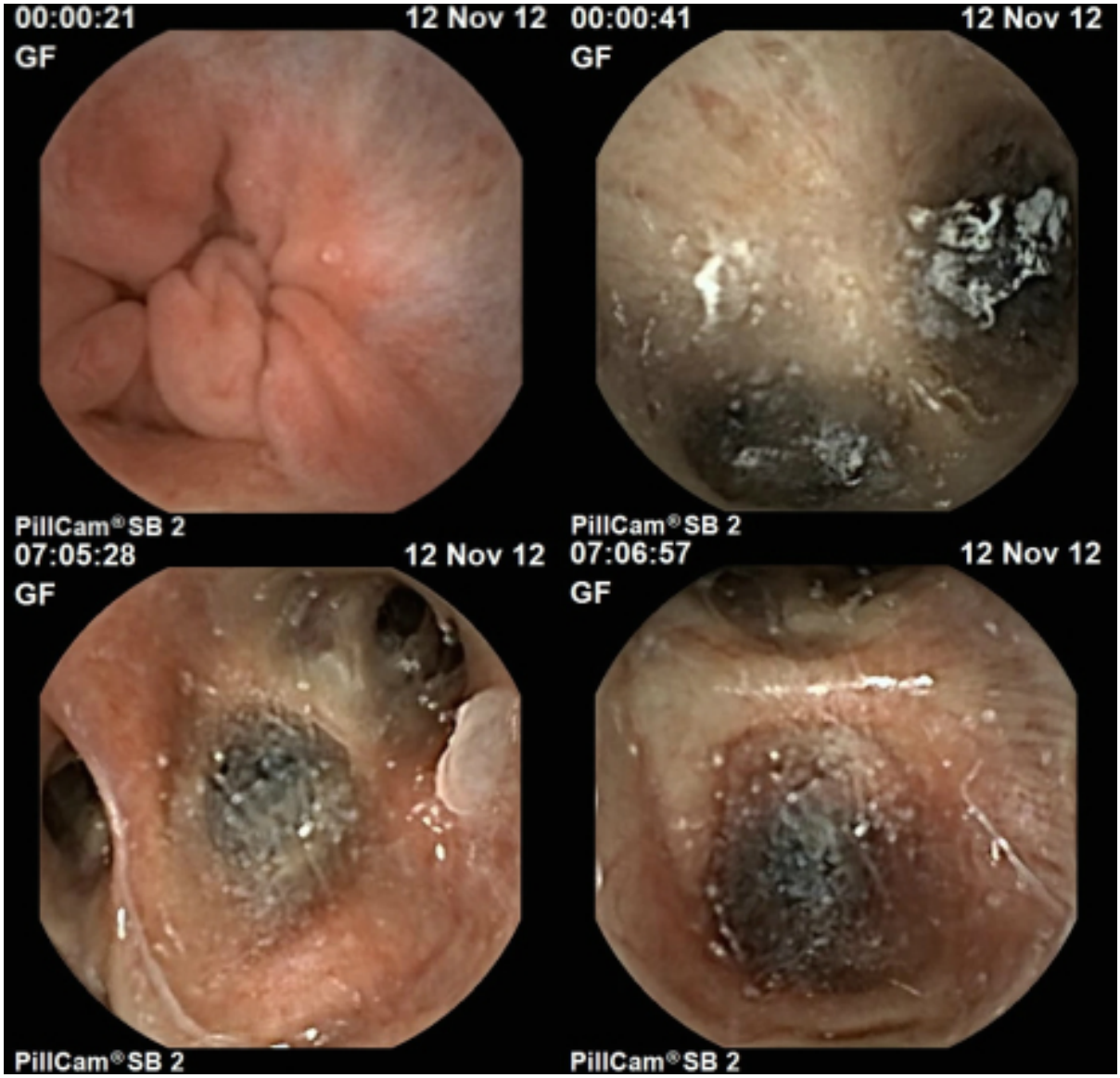
00:00:21
12 Nov 12
GF
PillCam® SB 2
00:00:41
12 Nov 12
GF
PillCam® SB 2
07:05:28
12 Nov 12
GF
PillCam® SB 2
07:06:57
12 Nov 12
GF
PillCam® SB 2

id 323

Role of broncheoalveolar lavage in bronchoscopy and its relationship to radiological findings

Rosa Maria Ortiz-comino, Clare Lynch, Jose Antonio Sanchez Martinez

Respiratory Medicine, South Warwickshire NHS Foundation Trust - United Kingdom

Introduction

For many years, bronchoalveolar lavage (BAL) is a commonly used diagnostic and research tool (1). However, current evidence is limited regarding standardisation of the technique and its indications.

Objective

The aim of the study was to compare the usefulness of BAL in patients with and without radiological findings and to analyse our diagnostic yield.

Methods

We conducted a retrospective analysis of bronchoscopies performed between December 2014 and November 2015 at an NHS Foundation Trust. Only patients who had BAL were included in the study. Data was collected regarding indication for bronchoscopy; radiology reported pre- bronchoscopy from chest x-ray or computerised tomography (CT) scans, bronchoscopy report and BAL analysis and patient´s definitive diagnosis. Patients were classified in two groups, those with normal and abnormal radiology.

Results

149 patients met the inclusion criteria, mean age 62 years and 81/149 (54%) were male. Indications for bronchoscopy included: haemoptysis 39/149 (26%), lung nodule/mass/collapse 75/149 (50%), lung infiltrates 34/149 (22.8%), lung cavity 1/149 (0.67%). 23/149 (15%) of patients had normal radiology pre-bronchoscopy. 23/23 had a normal bronchoscopy, 18 of whom were being investigated for haemoptysis. Of the 149 BAL's collected, 50 were sent for cytology and 20 for microscopic culture and mycobacterium culture. The remaining samples were sent for both. Bronchoscopic reports did not document the volume of saline used. At the end, 58/149 (39%) of patients were diagnosed with lung cancer, rather with bronchoscopy or further investigations. 25/58 (43%) individuals with lung cancer had a positive BAL. Our diagnostic yield from 129 samples sent for cytology was 74% (96/129). It is more difficult to comment on the diagnostic yield for microscopy but 24/99 (24.2%) cultures were positive.

Conclusions

It is a common practice to perform bronchoscopy for unexplained haemoptysis however guidelines do not specify whether samples need to be taken when bronchoscopy is normal (2). Our results indicated that if radiology and bronchoscopic findings are normal then BAL does not add more information. Bronchoscopies at the Trust are performed by different bronchoscopists therefore techniques and reporting vary, indicating a requirement to develop a standard protocol which may increase diagnostic yield in general and growth of microorganism in BAL´s microscopic culture in particular.

Bibliography

1. Reynolds HY, et al. J Lab Clin Med 1974;84:559–573 2. Du Rand IA, Blaikley J, Booton R, et al. Thorax 2013;68:i1–i44.

19th WCBIP / WCBE World Congress
JOINT MEETING OF THE WORLD ASSOCIATION FOR BRONCHOLOGY AND INTERVENTIONAL PULMONOLOGY & THE INTERNATIONAL BRONCHOESOPHAGOLOGICAL SOCIETY
www.wcbipwcbe2016.org
Fortezza da Basso
May 8-11, 2016
Florence (Italy)

Observation of bronchoscopy forceps in peripheral lung consolidation with transthoracic ultrasound

Giorgio Terzuolo[1], Sara Surbone[1], Francesco Bini[2], Roberto Venturini[1], Dimitrios Eleftheriou[1], Claudio Doria[1], Adriano Scoccimarro[1]

[1]UOC Pneumologia, ASST di Pavia - Italy
[2]UOC Pneumologia, ASST Rhodense - Italy

Introduction
Ultrasonography is able to detect the peripheral lung consolidations (PLC) in contact with the pleura. Bronchoscopy forceps are hyperechoic and visible with ultrasonography.

Objective
Ultrasonographic visualization of PLC and biopsy forceps during bronchoscopy.

Methods
Simultaneous observation of PLC and bronchoscopy forceps by ultrasonography. Patient was half seated or lying and monitored. It was administered mild or moderate sedation. 3.5 MHz ultrasound probe placed on the thoracic projection of the PLC. Bronchoscope Olympus BF1T180, forceps Olympus FB-241D. Informed consent was obtained.

Results
Ultrasonography identified the PLC directly below the parietal pleura or through the interposition of pleural effusion. On the basis of the topographical site of PLC it was introduced the forceps through the bronchoscope. The tip of the forceps progressed through the bronchoscope and it disappeared from the direct view distally. The probe has explored the PLC to detect the biopsy forceps inside. The correct insertion of the forceps mainly depended on the size of the consolidation and its viewing with ultrasonound during the respiratory movements. The forceps appeared as a hyperechoic image in the ultrasound field. To facilitate the visualization of the biopsy forceps as a linear image it was useful to place the probe with the axis toward the pulmonary hilum. The forceps when progressed within an air bronchogram provided a clear linearity. In the solid tissue the forceps remained well-defined along its course. The respiratory movements made it more difficult to follow the forceps in a continuous way. The forceps followed the breathing movements within PLC synchronously. While the biopsy was performed lung tissue underwent a movement of traction caused by the grip of the the forceps. After the biopsy lung tissue returned to the starting position. A hyperechoic image became visible in the biopsy site. The ride left by the forceps was similar to that of an air bronchogram with a more linear course. After of the biopsies ultrasound allowed to rule out the occurrence of a pneumothorax.

Conclusions
The forceps is visible with the transthoracic ultrasound in PLC with the advantage of avoiding the pleura during bioptic procedure. There is the difficulty of reaching small PLC with the forceps without a guidance system. Interestingly to advance the biopsy forceps toward the PLC viewed by the probe may be helpful guidance system that couples the position of biotic instruments on the field of the US image.

Bibliography
Lichtenstein DA. Crit Care Med 2007; 35(5):S250-S261 Terzuolo G, et al. Osservazione della pinza bioptica broncoscopica con ecografia in consolidazione polmonare periferica. Poster discussion at the XLIII AIPO-FIP 2015 congress.

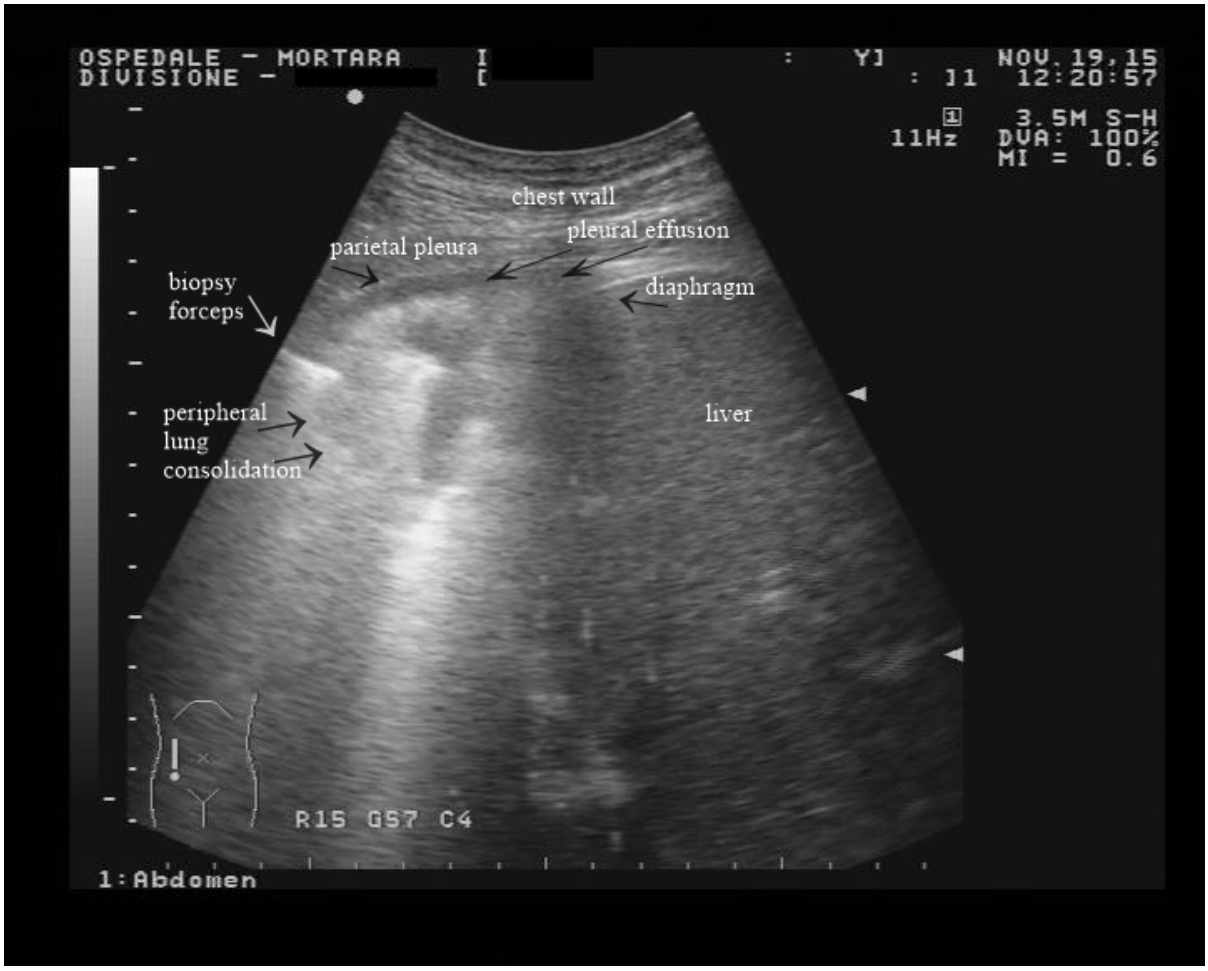
OSPEDALE - MORTARA
DIVISIONE -
NOV.19,15
12:20:57
3.5M S-H
11Hz
DVA: 100%
MI = 0.6
chest wall
pleural effusion
parietal pleura
diaphragm
biopsy
forceps
peripheral
lung
consolidation
liver
R15 G57 C4
1:Abdomen

id 325

EBUS-TBNA in intrathoracic lymphadenopathy in a tuberculosis-endemic country

Marcia Jacomelli Marcia[1], Viviane Rossi Figueiredo Viviane[2], Sergio Eduardo Demarzo Sergio[1], Paulo Francisco Guerreiro Cardoso Paulo[1], Ricardo Mingarini Terra Ricardo[3]

[1]Respiratory Endoscopy of Pulmonology and Thoracic Surgical Department, Heart Institute (InCor)-Hospital das Clinicas, Faculty of Medicine, University of São Paulo - Brazil
[2]Respiratory Endoscopy of Pulmonology Department, Heart Institute (InCor)-Hospital das Clinicas, Faculty of Medicine, University of São Paulo, Brazil; Cancer Institute of the State of Sao Paulo- Brazil; Hospital Sírio Libanês, São Paulo - Brazil - Brazil
[3]Thoracic Surgical Department, Heart Institute (InCor)-Hospital das Clinicas, Faculty of Medicine, University of São Paulo - Brazil

Introduction
Intrathoracic lymphadenopathy is a common finding in our clinical setting and it is important to differentiate between inflammatory, infectious and malignant diseases especially in our tuberculosis-endemic country. Endobronchial ultrasound with transbronchial fine needle aspiration biopsy (EBUS-TBNA) is a minimally invasive and safe diagnostic method for assessing mediastinal and hilar adenopathy.

Objective
The purpose of this study was to investigate the sensitivity of (EBUS-TBNA) in the diagnosis of mediastinal and hilar lymphadenopathy and describe the differential diagnosis especially in an endemic setting for infectious conditions such as tuberculosis.

Methods
Retrospective analysis of the local database of EBUS-TBNA. We included all patients with intrathoracic lymphadenopathy at thoracic computed tomography (CT) between August 2011 and October 2015. EBUS-TBNA was considered diagnostic if had: confirmed neoplastic cells in cell block; detected caseating or noncaseating granulomas compatible with tuberculosis, fungal infections, sarcoidosis or other granulomatous disease; had positive culture for specific microorganism from lymph node sample. For patients whose EBUS-TBNA resulted non- diagnostic, a definitive diagnostic was obtained by other procedure (transthoracic

Results
Two hundred thirty-eight patients were included in analysis (128 male and 110 female; mean age 58,42 years old). EBUS-TBNA identified neoplasm in 103 patients (43%), non caseating granulomatous disease (sarcoidosis and others) in 28 (11,8%), granuloma compatible with infectious disease (Mycobacterial, fungal and other) in 16 (6,7%), other disease in 4 (1,7%) and reactional lymph node in 64 patients (27%) confirmed as reactional in 39 (61%) of cases. Inconclusive results was found in 21 (8,8%) due to the scarce or bloody collected material. The sensitivity of EBUS-TBNA was 80,7% (n=192/238) and false negative results in 3% (n=7). There were no complications in this series.

Conclusions
EBUS-TBNA have high sensitivity rate for the diagnosis of intrathoracic lymphadenopathies. Although we are in high prevalence tuberculosis country we found low rate of tuberculosis in our series.

Bibliography
Madan K, et al. J Bronchology Interv Pulmonol. 2014;21(3):208-14 Sun J, et al. Ann Thorac Surg 2013;96:2021–7

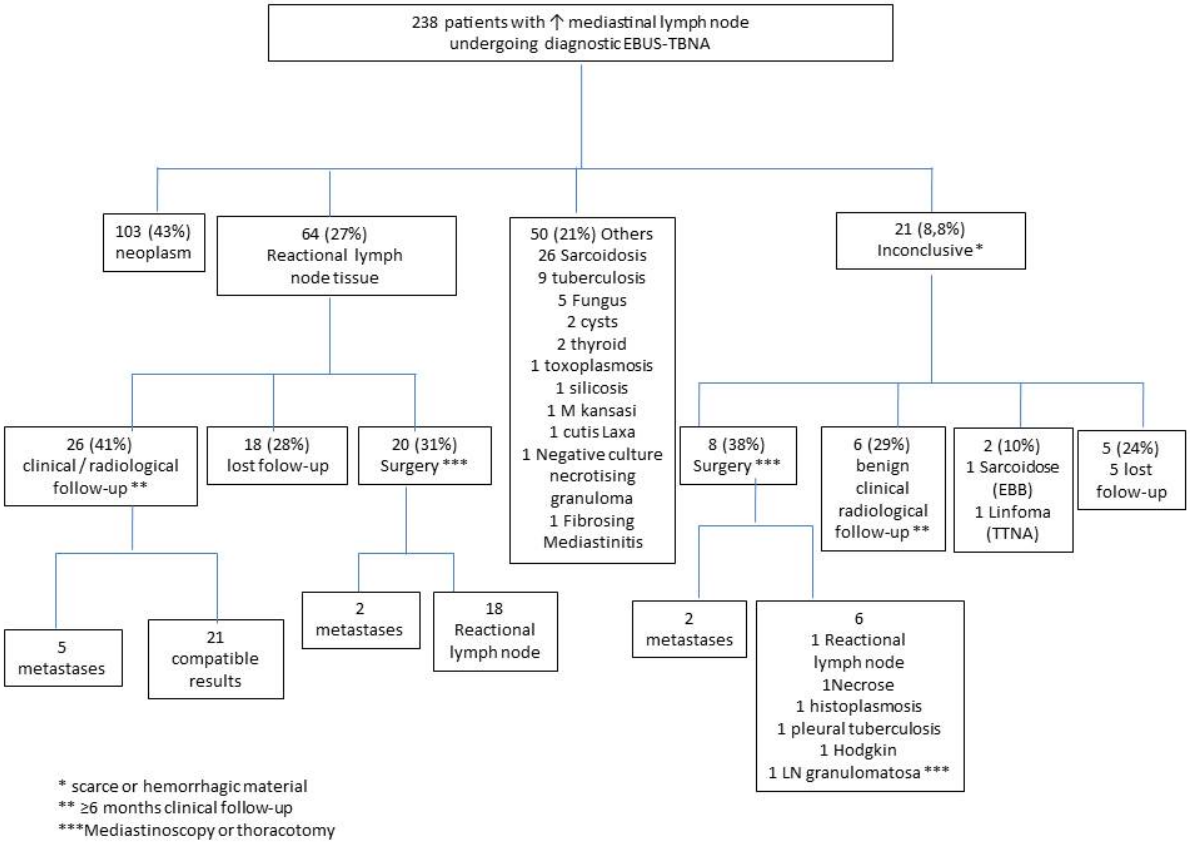
238 patients with ↑ mediastinal lymph node undergoing diagnostic EBUS-TBNA
103 (43%) neoplasm
64 (27%) Reactional lymph node tissue
50 (21%) Others
26 Sarcoidosis
9 tuberculosis
5 Fungus
2 cysts
2 thyroid
1 toxoplasmosis
1 silicosis
1 M kansasi
1 cutis Laxa
1 Negative culture
necrotising granuloma
1 Fibrosing Mediastinitis
21 (8,8%) Inconclusive *
26 (41%) clinical / radiological follow-up **
18 (28%) lost folow-up
20 (31%) Surgery ***
8 (38%) Surgery ***
6 (29%) benign clinical radiological follow-up **
2 (10%) 1 Sarcoidose (EBB) 1 Linfoma (TTNA)
5 (24%) 5 lost folow-up
5 metastases
21 compatible results
2 metastases
18 Reactional lymph node
2 metastases
6
1 Reactional lymph node
1Necrose
1 histoplasmosis
1 pleural tuberculosis
1 Hodgkin
1 LN granulomatosa ***
* scarce or hemorrhagic material
** ≥6 months clinical follow-up
***Mediastinoscopy or thoracotomy

id 326

Elastography strain ratio of mediastinal and hillar lymph nodes differs according to diagnosis

Ales Rozman[1], Bruno Escarguel[2], Julij Selb[3]

[1]Pulmonary, University Clinic Golnik - Slovenia
[2]Pulmonary, Hopital Saint Joseph - France
[3]Clinical immunology and genetics, University Clinic Golnik - Slovenia

Introduction

Elastography is a dynamic imaging technique based on ultrasound that noninvasively assesses the stiffness of tissues by measuring tissue deformation as a response to external compression or internal pulsations and movements. Strain ratio numerically represents the relative elasticity ratio between two selected areas.

Objective

The aim of this pilot study was to evaluate EBUS elastography strain ratio in the assessment of mediastinal and hilar lymph nodes in patients with several different conditions (lung cancer metastases, granulomas, normal lymph nodes).

Methods

EBUS bronchoscopy was performed on consenting consecutive patients referred to bronchoscopy for lung cancer staging or because of diagnostic work up of enlarged lymph nodes, found on the chest CT-scan. Elastoghaphy evaluation with strain ratio measurements was performed before EBUS-TBNA in each selected lymph node. The cytology sample was obtained thereafter to establish diagnosis.

Results

The study was performed in two tertiary interventional pulmonology centers. 175 patients with lung cancer, sarcoidosis and non-specifically enlarged lymph nodes participated in the study. We evaluated 358 different lymph nodes in the mediastinum in hilar regions. Cytological malignancy was confirmed from 149 (41,6%) nodes, granulomas from 18 (5,0%) and normal or reactive lymph node tissue from 191 (53,4%) lymph nodes. The average size of malignant, granulomatous and normal lymph nodes was 16,3 (± 6,3) mm, 16,2 (±4,5) mm and 10,9 (± 4,1) mm, respectively. The mean strain ratio for malignant lymph nodes was 23,4 ± 35,6, for granulomatous 6,0 ± 5,4, and for benign lymph nodes 8,6 ± 16,8. The strain ratio difference between malignant and benign (granulomas, normal lymph node tissue) lymph nodes was statistically highly significant in both cases ($p<0,001$), while there was no important difference between granulomatous and normal lymph nodes.

Conclusions

EBUS elastography strain ratio measurement can differentiate between malignant and benign lymph nodes in mediastinal and hilar regions. Malignant lymph nodes are stiffer than more elastic benign lymph node tissue. Strain ratio measurements and elastogram may complement standard EBUS-TBNA, help in selection of biopsy spot or even reduce the number of EBUS-TBNAs in lung cancer staging.

Bibliography

Xu W, et al. Gastrointest Endosc. 2011;74:1001–9. Rozman A, et al. Radiol Oncol. 2015;49:334-40.

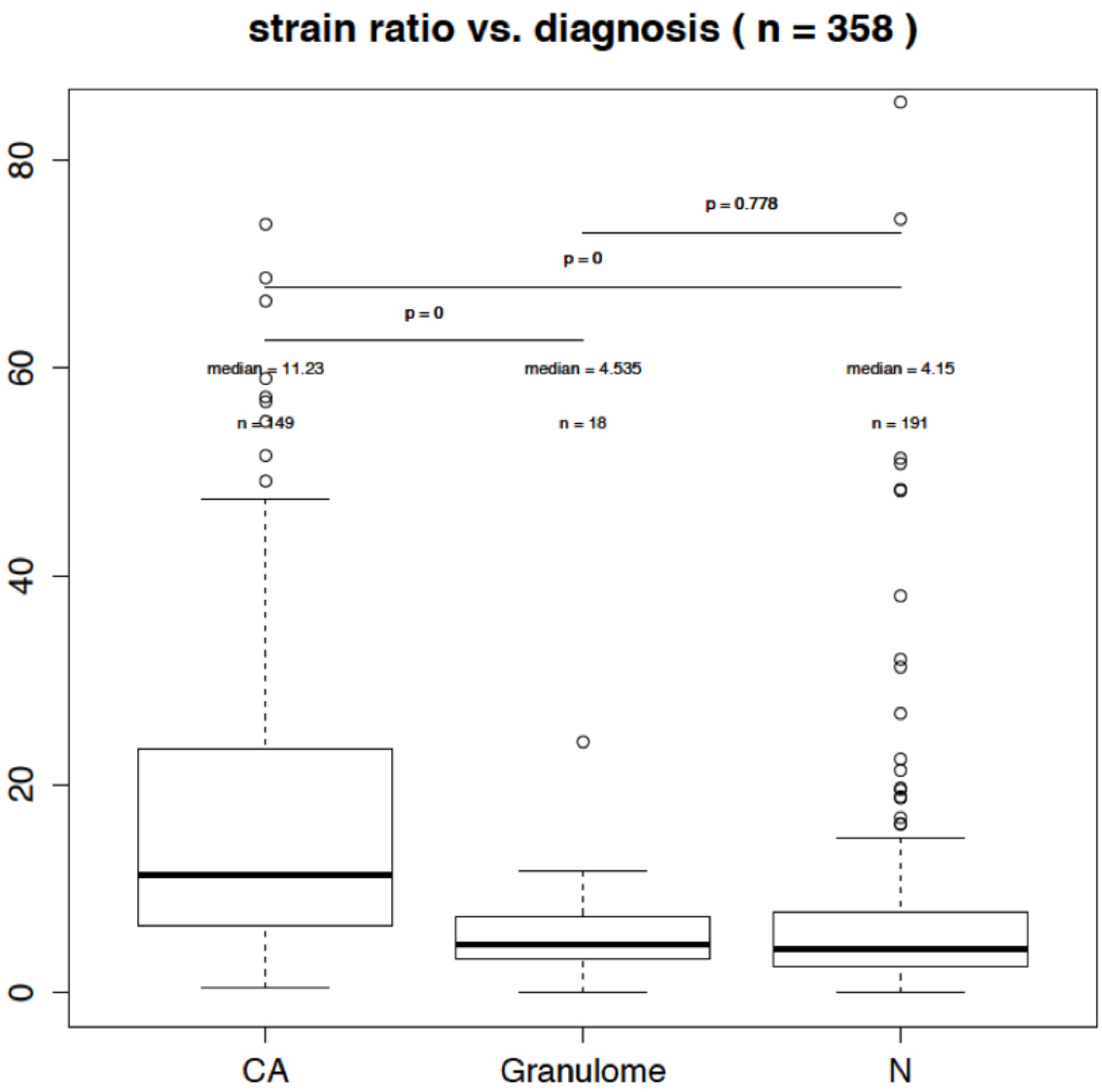

The presenting author has the following conflicts of interest that relate to this abstract: *Consultancy agreement with Olympus.*

id 327

Pediatric tracheotomy

Hideki Hirabayashi

Otorhinolaryngology, Dokkyo Medical University - Japan

Introduction
Indications for pediatric tracheotomy generally include bypassing airway obstruction, providing access for prolonged mechanical ventilation. There are many reasons why air cannot get to the lungs. The air way may be blocked by a swelling; by a severe injury to the neck, nose, or mouth; by a large foreign object; by bilateral vocal cord paralysis; or by a tumor. The patient may be in brain problems, or need a ventilator for a long period of time.

Objective
To investigate the short- and long-term complications of pediatric tracheotomy, emphasizing posttracheotomy tracheal stenosis. Pediatric tracheotomy technique; H-shaped tracheal opening: Reflect tracheal flaps inferiority or both inferiority and superiority. These can be tacked to skin edges with absorbable sutures to create a semipermanent stoma, or silk stay sutures can be placed in each tracheal 'flap', and taped to the chest and neck skin, facilitating replacement of a displaced tube in postoperative care.

Methods
Eighty-seven patients are nominated to two groups: flap tracheotomy, traditional vertical tracheotomy. The incidence of peristomal granulation and tracheal stenosis was compared.

Results
There are no significant difference between the vertical tracheotomy group and flap tracheotomy groups for granulation developing and tracheal stenosis. We found no significant risk of tracheal stenosis or adverse effects on tracheal growth for the flap tracheotomy.

Conclusions
This tracheotomy technique may be useful in the management of pediatric patients who require long-term bypass of the upper airway.

id 328

19th WCBIP / WCBE World Congress
JOINT MEETING OF THE WORLD ASSOCIATION FOR BRONCHOLOGY AND INTERVENTIONAL PULMONOLOGY & THE INTERNATIONAL BRONCHOESOPHAGOLOGICAL SOCIETY
www.wcbipwcbe2016.org
Fortezza da Basso
May 8-11, 2016
Florence (Italy)

Titrated combined sedation during medical thoracoscopy administerd by a trained pulmonologist

Marina Labor[1], Vesna Nisevic[2], Mateja Marc Malovrh[3], Luka Camlek[4], Josip Juraj[5], Ales Rozman[3]

[1]Pulmonology, University Hospital Center Osijek - Croatia
[2]Endoscopy, University Clinic Golnik - Slovenia
[3]Pulmonary, University Clinic Golnik - Slovenia
[4]ICU, University Clinic Golnik - Slovenia
[5]Department of Anatomy and Neuroscience, Faculty of Medicine Osijek - Croatia

Introduction

Medical thoracoscopy can be performed in local anesthesia, but sedation is increasingly being used to reduce patient's discomfort during the procedure. Protocols for sedation in medical thoracoscopy are different among institutions. Standard protocol for combined sedation was changed in our institution (tertiary pulmonary center) in the year 2012 and three pulmonologists were trained to substitute anesthesiologist, when the later was not available.

Objective

The aim was to assess safety by comparing the incidence and severity of hemodynamic and respiratory adverse events during thoracoscopy related to deep sedation conducted by an anesthesiologist or trained pulmonologist.

Methods

The study was prospective, observational, non-randomized. When anesthesiologist was not available, trained pulmonologist administered combined deep titrated intravenous sedation with fentanyl, midazolam and propofol according to the same principles as anesthesiologist. Involved pulmonologists were trained in ICU procedures including intubation and mechanical ventilation, resuscitation protocols and have additional training from anesthetic drugs and performed supervised sedations beforehand. All included patients were thoroughly examined before and monitored during the procedure. Performance status and procedure risk were graded according to ASA and WHO criteria. Depth of sedation was assessed using Observer's Assessment of Alertness/Sedation (OAAS) scale. Adverse events were defined as: hypoxemia, SpO2 <90% for >60 s; hypertension, systolic blood pressure (SBP) >=190 mmHg and/or a variation of >20% from baseline; hypotension, SBP <=90 mmHg, diastolic blood pressure (DBP) <=60 mmHg and/or a variation of >20% from baseline; tachycardia, HR >100/min; bradycardia, HR <60/min.

Results

207 adult patients underwent diagnostic or therapeutic thoracoscopy between August 2012 and September 2015. Forty-eight sedations (23.2%) were managed by pulmonologist, allowing us to compare cardiopulmonary safety profiles (Table 1). Hypoxemia was significantly more common during the pulmonologist's procedures (20.83% vs. 6.92%, p=0.01). Additional predictors for hypoxemia were: higher pleural effusion volume and longer smoking history (multivariate analysis). Significantly more patients with hypotension were found in the anesthesiologist's group (>20% for SBP or DBP; 83.65% vs. 43.75%, p<0.001). Additional predictors for hypotension were: higher baseline SBP, higher body mass and smoking history (multivariate analysis). Tachycardia and bradycardia were comparable between groups (p>0.05 for both). All adverse events were mild and corrected by additional oxygen application, chin lift and intravenous infusion.

Conclusions

The cardiopulmonary adverse events profile during titrated intravenous sedation conducted by trained pulmonologist was different (more hypoxemia but less hypotensive reactions), in relation to anesthesiologist. Adverse events were mild and easily corrected.

Adverse events	Anesthesiologist (n=159)	Trained pulmonologist (n=48)	Statistics (Fischer, Z-test)
Hypoxemia	11 (6.92%)	10 (20.83%)	**p=0.01**
Fall in SO_2, median (IQR)	2.1 (1.0-4.1) %	3.1 (1.1-5.2) %	Z=1.97, **p=0.049**
Hypertensive reaction	15 (9.43%)	9 (18.75%)	p=0.12
Hypotensive reaction	133 (83.65%)	21 (43.75%)	**p<0.001**
Tachycardia	37 (23.27%)	17 (35.42%)	p=0.13
Bradycardia	27 (16.98%)	9 (18.75%)	p=0.83

Table 1. Hemodynamic and respiratory adverse events during thoracoscopy.

id 329

19th WCBIP / WCBE World Congress
JOINT MEETING OF THE WORLD ASSOCIATION FOR BRONCHOLOGY AND INTERVENTIONAL PULMONOLOGY & THE INTERNATIONAL BRONCHOESOPHAGOLOGICAL SOCIETY
www.wcbipwcbe2016.org
Fortezza da Basso
May 8-11, 2016
Florence (Italy)

Esophageal adenocarcinoma and pleural effusion

Francesca Savoia[1], Cosimo Catino[1], Helena Rosa Heras Salvat[2], Licia Laurino[3]

[1]Pneumology, "Ca' Foncello" Hospital - Italy
[2]Gastroenterology, "Ca' Foncello" Hospital - Italy
[3]Anatomopatology, "Ca' Foncello" Hospital - Italy

Introduction

Among the causes of pleural effusion include the esophageal malignancy. The esophageal cancer is due to the uncontrolled growth of cells that line the esophagus or tubule cells that form glands that produce mucus. Endosonography esophageal ultrasound (EUS) accurately determines the infiltration of the layers of the esophageal wall and the presence of suspicious lymph nodes

Results

A man of 61 years, with a history of epilepsy in childhood then regressed with growth; metalworker. No smoking history. No alcohol abuse. As a young man was hospitalized for hemoptysis episode. Hypertension drug treatment. For about three months the patient began to complain of mild dyspnea efforts, associated with non-productive cough. No febrile episodes. Sometimes heartburn. Chest physical examination showed mild hypophonesis on the lung bases. Blood Gas: normal. Spirometry: mild restriction. Blood count, inflammatory markers, oncomarkers, already required were normal. Chest X-ray: baseline clouding bilateral. We proceeded: cardiac evaluation, proBNP and cardiac enzymes: meaningless results. Later they performed the following tests. CT scan: bilateral pleural effusions extension apical-basal with maximum thickness of 71 mm on the right and left of 50 mm. No significant aspects focal parenchymal lung. No significant mediastinal enlarged lymph nodes. Brain CT: negative. CT abdomen: circumferential wall thickening of the distal esophagus: findings suspicious for primitive cardia neoplasia. PET: negative. The patient was subjected to tracheobroncoscopia: tracheobronchial patency; cytological and microbiological analyzes on bronchial aspirates were negative. It was performed esophagogastroduodenoscopy: bulging mucous lower esophagus, gastric polyps; biopsies were performed: gastric mucosa without significant alterations and hyperplastic polyp. Medical right thoracoscopy with concomitant chemical pleurodesis and positioning transient drainage (24F) maintained in aspiration and removed after three days. The parietal pleura in the lower region appeared whith thickened areas in the form of linear whitish plaques; the biopsies showed fragments of adipose tissue with minimal inflammatory infiltrates and hyperplastic mesothelium. Cytology of pleural fluid: presence of aggregates compatible with papillary mesothelium hyperplastic, negative research culture. For the progressive increase of the left pleural fluid, we position chest tube (16F) and chemical pleurodesis was performed according to the method "talc slurry". Then it was performed a new esophagogastroduodenoscopy with biopsy needle (19G) near the peri esophageal distal thickening: presence of suspicious atipical squamous epithelia.. Endosonography esophageal ultrasound (EUS) with new needle biopsy (19G): presence of adenocarcinoma cells. The oncologist gave indication to chemoterapic treatment.

Conclusions

Pleural effusion may be the first manifestation of esophageal cancer disease

id 330

Factors related to diagnostic yield of flexible bronchoscopy in peripheral lung lesions

Jongmin Lee, Hye Seon Kang, Jick Hwan Ha, Hyeon Hui Kang, Chang Dong Yeo, Sung Kyoung Kim, Chan Kwon Park, Seung Joon Kim, Sang Haak Lee

Division of Pulmonary, Critical Care and Sleep Medicine, Department of Internal Medicine, The Catholic University of Korea, College of Medicine - Republic Of Korea

Introduction

Flexible bronchoscopy is the basic tool for evaluating peripheral lung lesions even though several diagnostic innovations increase the diagnostic yield of bronchoscopy. Few studies have addressed the yield of flexible bronchoscopy without fluoroscopic guidance.

Objective

The purpose of this study was to evaluate factors predicting the diagnostic yield of flexible bronchoscopy without guidance in peripheral lung lesions without endobronchial abnormalities.

Methods

The medical records of 204 patients who underwent flexible bronchoscopy for the evaluation of peripheral lesions were reviewed retrospectively. The analyzed variables included the etiology of lesion, lesion size, distance from pleura, and the presence of bronchus sign. Bronchus sign was grouped into two categories according to the presence or absence of exposure of tumor mass into the bronchial lumen. We performed a multivariate analysis of the predictive factors for the diagnosis using the logistic regression technique.

Results

One hundred fifty-one patients were included in the study, with a mean age of 65 ± 14 years. The overall diagnostic rate was 58.3%. Sensitivity was 43.2% in malignant disease and 78.1% in benign disease. The benign lung lesion ($P < 0.002$), lesion size ($P = 0.018$) and the presence of bronchus sign ($P < 0.001$) were factors influencing the yield of flexible bronchoscopy by univariate analysis. In multivariate logistic regression analysis, the exposed type of bronchus sign and benign lung lesions were independent determinant factors (OR 22.4, 95% CI 6.5-77.7, $P < 0.001$; OR 6.4, 95% CI 2.5-16.1), $P < 0.001$).

Conclusions

The presence of the exposed type of bronchus sign and the benign lung lesions are determinants of diagnostic yield in flexible bronchoscopy when evaluating peripheral lesions without endobronchial abnormalities.

id 331

19th WCBIP / WCBE World Congress
JOINT MEETING OF THE WORLD ASSOCIATION FOR BRONCHOLOGY AND INTERVENTIONAL PULMONOLOGY & THE INTERNATIONAL BRONCHOESOPHAGOLOGICAL SOCIETY
www.wcbipwcbe2016.org
Fortezza da Basso
May 8-11, 2016
Florence (Italy)

Intraoperative real-time transthoracic fiducial marker placement for lung wedge resection utilizing

Mohammed Alnijoumi[1], Syed M. Quadri[2], Carla Lamb[1]

[1]Interventional Pulmonary - Department of Pulmonary and Critical Care, Lahey Hospital and Medical Center - Usa
[2]Thoracic Surgery, Lahey Hospital and Medical Center - Usa

Introduction

Fiducial markers are radiopaque materials that are placed in or around soft tissue to enhance target localization in image-guided radiotherapy or radiosurgery. Fiducial markers may also play a role to assist the thoracic surgeon when localizing a ground glass opacity or small parenchymal nodule which would otherwise be difficult to localize. Typically, fiducial marker placement is performed by the interventional radiologist in the procedure suite and the patient then is transported to the operative suite which may be cumbersome and time consuming. Fiducial markers can also be placed bronchoscopically to achieve similar objectives. We present a case of fiducial marker placement performed by the interventional pulmonologist intraoperatively utilizing the Veran Spin-PercTM system (Veran Medical Technologies, St. Louis, MO, USA) to assist with pulmonary nodule localization to optimize surgical wedge resection.

Methods

This is a 60-year-old female with a 47 pack-year tobacco history, who was found to have a solitary pulmonary nodule that was increasing in size with sequential chest ct scan imaging. This was a spiculated, 1.9 X 1.4 cm, solid nodule located in the superior segment of the lingula. In light of her risk factors and radiographic features, she was taken to the operating room for surgical wedge resection. Given the size of the nodule, and the expected difficulty in localizing the nodule intraoperatively, fiducial marker placement (0.5 mm in diameter by 10 mm in length; Visicoil TM linear fiducial marker; IBA Dosimetry, Bartlett, TN, USA) was utilized to assist with tumor localization for surgical wedge resection. Using the electromagnetic navigational system, the nodule and placement sites around the nodule were planned preoperatively. Three gold fiducial markers were placed successfully without immediate complications of pneumothorax nor fiducial marker migration as confirmed with fluoroscopy. Surgical wedge resection was completed successfully with clear margins (figure 1). Final diagnosis confirms non-small lung cancer, of adenocarcinoma subtype. All fiducial markers were removed during wedge resection and confirmed on fluoroscopy intraoperatively.

Conclusions

Intraoperative, real-time placement of fiducial markers appears to be a safe, well tolerated and time-efficient way to better localize small pulmonary nodules or ground glass opacities that would otherwise be difficult to palpate for planned surgical wedge resection.

Bibliography

Ohta K, et al. J Radiat Res. 2013;54(5):957-961. Bolton WD, et al. Am Surg. 2015;81(7):659-662.

id 332

19th WCBIP / WCBE World Congress
JOINT MEETING OF THE WORLD ASSOCIATION FOR BRONCHOLOGY AND INTERVENTIONAL PULMONOLOGY & THE INTERNATIONAL BRONCHOESOPHAGOLOGICAL SOCIETY
www.wcbipwcbe2016.org
Fortezza da Basso
May 8-11, 2016
Florence (Italy)

Bronchoscopic Decompression for Severe Emphysema

Anupam Kumar, Louis Lam, Yvonne Meli, Thomas Gildea, Atul C Mehta

Respiratory Institute, Cleveland Clinic - Usa

Introduction

Bronchoscopic therapies for lung volume reduction in emphysema have been experimented for more than a decade. The benefits with most of these modalities have been largely confined to subjective improvement. In many cases, improvement in objective parameters may not equate to meaningful clinical improvement.

Objective

A pilot project that determines the impact of simple bronchoscopic suctioning ("Bronchoscopic Decompression") in patients with hyperinflation due to emphysema.

Methods

12 patients with advanced emphysema were selected after Institutional Review Board (IRB) approval. Inclusion criteria: Age 45-80, forced expiratory volume in 1 second (FEV1) 15-45%, residual volume (RV) >150%, total lung capacity (TLC) >100%, mMRC dyspnea scale >= 2, on maximal medical treatment for COPD, CT scan evidence of emphysema-heterogeneous or homogenous. Exclusion: Patients with positive bronchodilator response, PaCO2 >60 mmHg, oxygen requirement >6L per minute via nasal cannula (at rest, or exertion). Primary end points were: improvement in St. George Respiratory Questionnaire (SGRQ) score by 4 points, increase in six minute walk distance by 15%. Secondary end points:15% increase in FEV1 and 10% reduction in TLC and RV. Simple bronchoscopic intermittent suctioning for 5 minutes, or as tolerated, were performed in each individual hyperinflated segments under conscious sedation. FEV1, FVC, DLCO, TLC, RV, six minute walk distance, SF 36 and SGRQ scores were obtained at the baseline and post-procedurally at day 7, 1 month, 3 months, 6 months and 9 months.

Results

We report the 7 day post procedure data on 9 patients. 1 patient could not complete the procedure.Demographics: mean age 66.5 years; mean BMI 23.54; mean FEV1 28% predicted; mean TLC 126 % predicted; mean RV 236% predicted; mean DLCO 35.1% predicted, mean 6MWD: 56.25% predicted, mean mMRC score of 2.64. At Day 7: mean FVC change +8.36%; mean FEV1 change +10.43%; mean TLC change +1.64%; mean RV change -1.61%; mean 6MWD change + 5.40%; mean mMRC change -0.78 (statistically insignificant). There was statistically significant improvement in vitality scores and social functioning respectively (SF-36): +13.33, (95% CI: +5.01 to +21.66), +11.11 (95% CI: +0.75 to 2148).Data for 4 patients at 3 months: mean FVC change +4%; mean FEV1 change +4.18%; mean TLC change: -5.37%; mean RV change -9.71%; 6MWD change -1.10%; mean mMRC change +0.25. SGRQ improvement was statistically significant at -7.66 (95% CI: -1.04 to -14.27).

Conclusions

Bronchoscopic Decompression in patients with hyperinflation from emphysema results in statistically significant improvement in QOL at 7 days (SF 36) and 3 months (SGRQ scores).

The presenting author has the following conflicts of interest that relate to this abstract: *Spiration IBV, PulmonX No disclosure pertaining to the abstract methodology or interventions.*

id 333

19th WCBIP / WCBE World Congress
JOINT MEETING OF THE WORLD ASSOCIATION FOR BRONCHOLOGY AND INTERVENTIONAL PULMONOLOGY & THE INTERNATIONAL BRONCHOESOPHAGOLOGICAL SOCIETY
www.wcbipwcbe2016.org
Fortezza da Basso
May 8-11, 2016
Florence (Italy)

Clinical Manifestations of Fibrosing mediastinitis in Chinese Patients

Yan Hu[1], Jianxing Qiu[2], Jiping Liao[1], Hong Zhang[1], Zhe Jin[1]

[1]Department of Respiratory and Critical Care Medicine, Peking University First Hospital - China
[2]Department of Medical Imaging, Peking University First Hospital - China

Introduction
Fibrosing mediastinitis (FM) is a rare disease. The majority of cases were thought to be related with histoplasmosis. But China has a high prevalence of tuberculosis (TB). The clinical manifestation of FM in Chinese patients has not been analyzed.

Objective
In this study, the clinical, radiographic and bronchoscopic features of Chinese patients with FM were analyzed.

Methods
Between January 2005 and June 2015, 22 patients were diagnosed as FM in our hospital. The medical records and follow-up data were collected. The imaging and biopsy findings were reviewed by radiologists and pathologists.

Results
A total of 22 patients were analyzed (10 male and 12 female). The age range was from 43 to 88 years with a mean age of 70.1 years. Half of the patients had evidence of previous or latent tuberculosis. Clinical symptoms included dyspnea (81.8%)?cough (77.3%), expectoration (31.8%) and fever (13.6%). Chest CT scans showed a diffuse homogeneous soft tissue process throughout the mediastinum and pulmonary hili with multiple compressions of bronchi and pulmonary vessels. Calcification was common (68.2%). Pulmonary hypertension was present in 10 cases (45.5%). The common endobronchial findings included multiple black pigmentation of bronchial mucosa and bronchial stenosis. 9 patients were treated with anti-tuberculosis drugs and 3 of them reported obvious relief of the symptoms.

Conclusions
FM in Chinese patients is most likely associated with TB and the characteristics are different from the cases caused by histoplasmosis. Anti- tuberculosis therapy maybe effective for some patients, but it should be demonstrated by further larger scale studies.

id 334

19th WCBIP / WCBE World Congress
JOINT MEETING OF THE WORLD ASSOCIATION FOR BRONCHOLOGY AND INTERVENTIONAL PULMONOLOGY & THE INTERNATIONAL BRONCHOESOPHAGOLOGICAL SOCIETY
www.wcbipwcbe2016.org
Fortezza da Basso
May 8-11, 2016
Florence (Italy)

Usefulness of EWS (Endobronchial Watanabe Spigot) Combined with Surgery

Yasufumi Kato Dr[1], Kinya Furukawa Prof[1], Ryousuke Amemiya Dr[1], Kimitoshi Nawa Dr[1], Norihiko Ikeda Prof[2]

[1]Thoracic Surgery, Tokyo Medical University, Ibaraki Medical Center - Japan
[2]Thoracic Surgery, Tokyo Medical University - Japan

Introduction
The report of patients with respiratory disease who could receive surgery after EWS or EWS for complication after surgery is relatively rare.

Objective
To assess the usefulness EWS combined with surgery.

Methods
We experienced a total of 4 patients using EWS followed by surgery (lung cancer: 2, empyema with fistula: 2), 3 of whom were initially performed EWS occlusion, the other was initial surgery. We evaluated the clinical outcome retrospectively.

Results
EWSs were used to occlude the bronchi for the purpose of stopping aspiration of blood in 2 lung cancer patients, or purulent discharge in 2 empyema patients with fistula. In an advanced case of 2 lung cancer patients, reducing of massive bleeding after EWS was obtained, thereafter, we could perform salvage surgery. The other lung cancer case with recurrence after surgery was performed endobronchial EWS occlusion to stop bleeding from peripheral lung cancer, thereafter, we could perform BAE (bronchial artery embolization), and confirmed the hemostasis by bronchoscopy. In benign case, 2 patients of empyema with fistula were performed EWSs occlusions of drainage bronchi to improve aspiration pneumonia or depuration of empyema cavity by lavage, followed by thoracoplasty with muscle flap packing or omentopexy.

Conclusions
EWS followed by surgery is useful modality, and we should realize that there are some patients who can be treated by surgery after EWS because of improvements of their conditions. Also, EWS can be effective for reducing massive hemoptysis which is uncontrolled by the bronchoscopy alone, and temporary management of bleeding until BAE.

Bibliography
None

id 335

19th WCBIP / WCBE World Congress
JOINT MEETING OF THE WORLD ASSOCIATION FOR BRONCHOLOGY AND INTERVENTIONAL PULMONOLOGY & THE INTERNATIONAL BRONCHOESOPHAGOLOGICAL SOCIETY
www.wcbipwcbe2016.org
Fortezza da Basso
May 8-11, 2016
Florence (Italy)

Transcatheter arterial embolization before interventional bronchoscopy

Ying Liu[1], Zenglian Tian[2], Xiaohong Yang[3], Hong Zhang[1], Weihua Jia[2], Xuemei Wei[3], Guangfa Wang[1]

[1]respiratory and critical care medicine, Peking University First Hospital - China
[2]respiratory, General Hospital of TISCO - China
[3]respiratory and critical care medicine, People's Hospital of Xinjiang Uygur Autonomous Region - China

Introduction

As interventional pulmonology developed, we have faced more and more complex patients. The safety of the procedure is always important. When the lesions grow into the central airway causing obstruction, we can resect them with many techniques of bronchoscopy. But when the lesions are rich of blood supply, the safety of the procedure becomes the issue.

Objective

When lesions are rich of blood supply, how to resect them during interventional bronchoscopy avoiding massive hemorrhage.

Methods

There are six cases of central airway obstruction due to neoplasms. CT scan showed the lesions located in the main bronchi or the lower part of trachea causing various degrees of dyspnea. With contrast- enhanced CT scan, we found the lesions are all enhanced predominantly, more than 100HU of CT value, which means rich of blood supply and great risk of massive hemorrhage during biopsy or resecting. Considering of the risk, we did transcatheter arterial embolization to diminish the blood supply of the lesions before the interventional bronchoscopy. There were no serious bleeding in all these cases. The pathology of the lesions were all malignant except one tuberculosis.

Results

There are six cases of central airway obstruction due to neoplasms. CT scan showed the lesions located in the main bronchi or the lower part of trachea causing various degrees of dyspnea. With contrast- enhanced CT scan, we found the lesions are all enhanced predominantly, more than 100HU of CT value, which means rich of blood supply and great risk of massive hemorrhage during biopsy or resecting. Considering of the risk, we did transcatheter arterial embolization to diminish the blood supply of the lesions before the interventional bronchoscopy. There were no serious bleeding in all these cases. The pathology of the lesions were all malignant except one tuberculosis.

Conclusions

There are six cases of central airway obstruction due to neoplasms. CT scan showed the lesions located in the main bronchi or the lower part of trachea causing various degrees of dyspnea. With contrast- enhanced CT scan, we found the lesions are all enhanced predominantly, more than 100HU of CT value, which means rich of blood supply and great risk of massive hemorrhage during biopsy or resecting. Considering of the risk, we did transcatheter arterial embolization to diminish the blood supply of the lesions before the interventional bronchoscopy. There were no serious bleeding during interventional bronchoscopy in all these cases. The pathology of the lesions were all malignant except one tuberculosis.

id 336

19th WCBIP / WCBE World Congress
JOINT MEETING OF THE WORLD ASSOCIATION FOR BRONCHOLOGY AND INTERVENTIONAL PULMONOLOGY & THE INTERNATIONAL BRONCHOESOPHAGOLOGICAL SOCIETY
www.wcbipwcbe2016.org
Fortezza da Basso
May 8-11, 2016
Florence (Italy)

The Westmead nursing guide to safe EBUS procedure

Jenevieh Junio[1], Peter Wu[2], Ming-yan Teo[3], Geraldine Khong[4], Robyn Brown[1]

[1]Endoscopy Unit, Westmead Hospital - Australia
[2]Respiratory & Sleep Disorder, Staff, Westmead Hospital - Australia
[3]Respiratory & Sleep Disorder, Staff, Blacktown Hospital - Australia
[4]Anaethesia and Staff, Westmead Hospital - Australia

Introduction

Westmead is a tertiary level referral hospital in Western Sydney, with an endoscopy unit performing approximately 427 cases in 2015 in both diagnostic and therapeutic interventional bronchoscopy procedures, including Endoscopic Bronchial Ultrasound (EBUS) with Transbronchial Needle Aspiration (TBNA). EBUS is performed either under conscious sedation or under general anaesthesia using laryngeal mask airway (LMA). Complications are uncommon, but there are challenges due to shared airway between the anaesthetist and pulmonologist, the procedure itself and recovering a population of patients often with significant cardiac and respiratory comorbidities. As lung diagnostic and therapeutic ultrasound advances, endoscopy nurses are increasingly required to possess skills and knowledge in both anaesthesia and procedure-related emergencies. As endoscopy nurses with varied skill mix assist or recover post EBUS patients, there is a need for awareness in prevention and detection of possible complications in an early and timely manner. An algorithm of care may help ensure safe patient outcome.

Objective

To design a clinical a pathway for Westmead Hospital endoscopy nurses as reference guide that may assist the anaesthetist and pulmonologist in caring a patient before, during and after an EBUS procedure.

Methods

We performed a literature search using current guidelines using keywords EBUS, anaesthesia, nursing, algorithm and produced a useful reference for nurses involved in the care of EBUS patients. A collaborative team effort with anaesthetist, pulmonologist, clinical nurse educator and my experience as a bronchoscopy, anaesthetic and recovery nurse since 2005, we reached a final consensus pathway.

Results

We produced an EBUS nursing clinical pathway that highlights many anaesthetic considerations for nursing staff which are important in ensuring patient safety. We emphasized the importance of patient safety through prevention and early management of anaesthetic and procedure related complications.

Conclusions

This EBUS nursing clinical pathway will be an invaluable tool and guide for our endoscopy nurses. We plan to evaluate the procedural and patient outcomes before and after implementation of this pathway.

The Westmead nursing guide to safe EBUS procedure

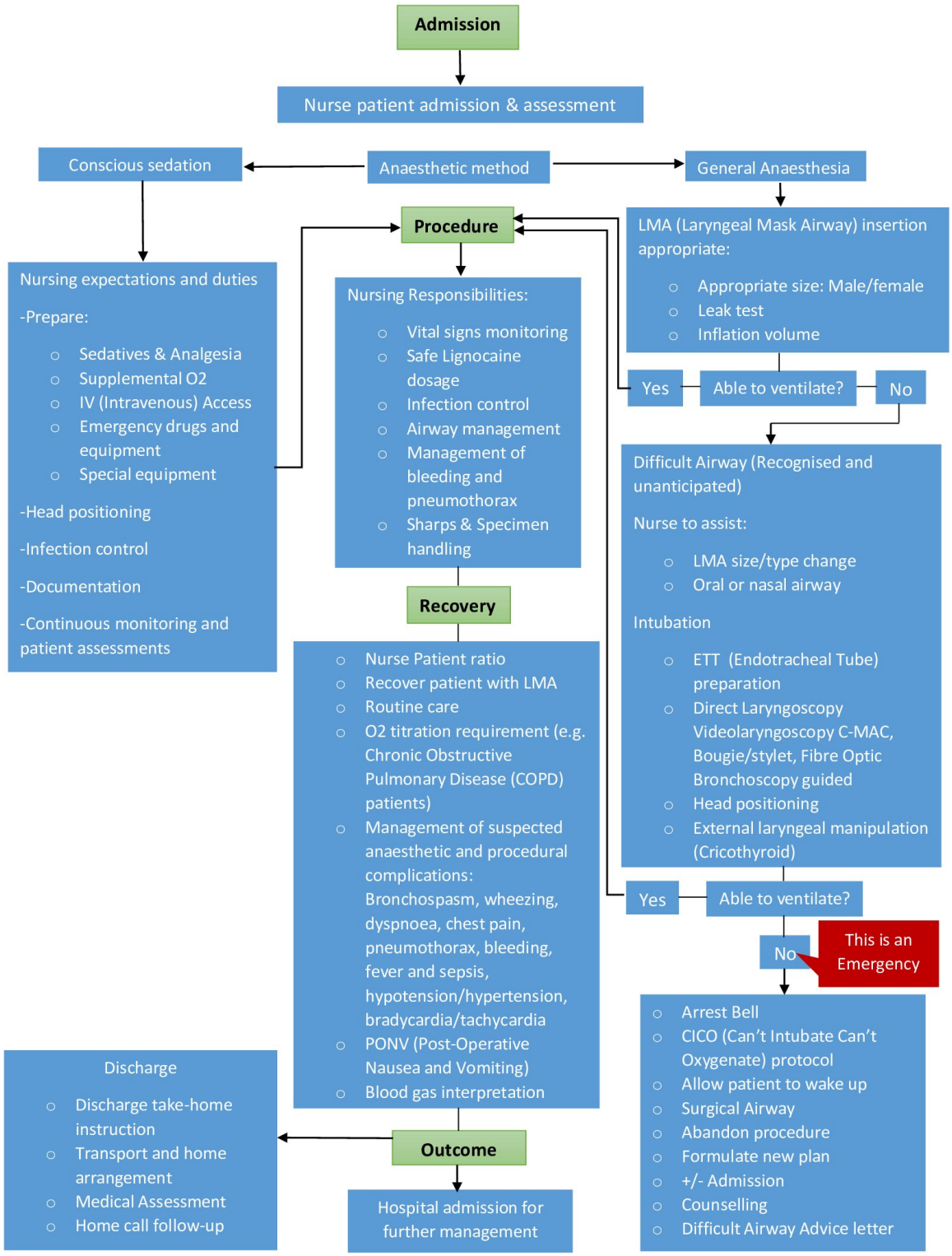

id 338

19th WCBIP / WCBE World Congress
JOINT MEETING OF THE WORLD ASSOCIATION FOR BRONCHOLOGY AND INTERVENTIONAL PULMONOLOGY & THE INTERNATIONAL BRONCHOESOPHAGOLOGICAL SOCIETY
www.wcbipwcbe2016.org
Fortezza da Basso
May 8-11, 2016
Florence (Italy)

Typical carcinoid tumors diagnosed by bronchoscopy with lymph nodes and distant metastases

Yoshitomo Kushima[1], Akihiro Takemasa[1], Taichi Shiobara[1], Naoya Ikeda[1], Takafumi Umetsu[1], Ryo Arai[1], Hidenori Takizawa[1], Kazuyuki Chibana[1], Masaaki Miyoshi[1], Yasuo Shimizu[1], Yoshimasa Nakazato[2], Yoshiki Ishii[1]

[1]Department of Pulmonary Medicine and Clinical Immunology, Dokkyo Medical University School of Medicine - Japan
[2]Department of Pathology, Dokkyo Medical University School of Medicine - Japan

Introduction
Typical carcinoid tumor is a well-differentiated neuroendocrine carcinoma and it is reported that distant metastases are rare and found in just 0.98-2% cases.

Objective
The present study aimed to analyze the clinical characteristics of typical carcinoid tumors diagnosed by bronchoscopy and accompanied by metastases at diagnosis.

Methods
Typical carcinoid cases diagnosed by bronchoscopy from 2008 to 2015 and accompanied by lymph nodes and distant metastases at diagnosis were reviewed. And the clinical characteristics of these cases were analyzed.

Results
All four cases were women and the average age was 69.8 years old (39-84). The distant metastases were found in lung, lymph nodes, liver, and pancreas. Two cases showed high values of serum tumor marker Pro-GRP (3200-7560), and the immunostaining of biopsy specimens demonstrated Pro-GRP expression in tumors. FDG-PET was performed in 3 cases, and all cases showed high FDG uptake in the lesions. Only one case of patients was treated with chemotherapy, and the effect was evaluated as “stable disease (SD)” for 5 years. Other three cases were followed up without chemotherapy due to advanced ages. One patient has maintained SD for 7 years, one survived for 2 years and one became unknown.

Conclusions
There are cases presenting lymph node and distant metastases, even if biopsy specimens demonstrate histologically typical carcinoid patterns. It is suggested that typical carcinoid tumors could show better prognosis even if there are lymph nodes and distant metastases.

Bibliography
Fink G, et al. CHEST 2001; 119:1647-1651. Ferguson MK, et al. Eur J Cardiothorac Surg. 2000; 18(2):156-161.

id 339

19th WCBIP / WCBE World Congress
JOINT MEETING OF THE WORLD ASSOCIATION FOR BRONCHOLOGY AND INTERVENTIONAL PULMONOLOGY & THE INTERNATIONAL BRONCHOESOPHAGOLOGICAL SOCIETY
www.wcbipwcbe2016.org
Fortezza da Basso
May 8-11, 2016
Florence (Italy)

Successful management of congenital tracheal stenosis with balloon-expandable metallic stents

Anxia Jiao, Fang Liu, Xiaochun Rao, Yuyan Ma, Chenfang Meng, Yuena Pan, Xicheng Liu

Interventional Pulmonology, Beijing Children's Hospital, Capital Medical University - China

Introduction

Congenital tracheal stenosis is a rarely congenital disease, influence on the survival rate and the quality of life seriously in infant. The management methods of it included surgery and interventional lung surgery. Bronchoscopy has the advantages of minimally invasive, strongly intuitive, can observed the stenosis within airway. Stent placed by bronchoscopy have shown advantage on the treatment of congenital airway stenosis. The airway diameter in children is narrower, metallic stent have more operability compared with Dumon stent and so on.

Objective

To assess the effectiveness of and complications associated with metallic stent placement for treatment of congenital tracheal stenosis in children.

Methods

A 11-months-old girl, had severe congenital tracheal stenosis, result from bridging bronchus and pulmonary artery sling. After the corrective surgery with pulmonary artery sling, she still could not spontaneous breathing because of tracheal stenosis. So the balloon-expandable metallic stents placed by bronchoscopy is very essential. The agreement about the operation risk was signed by the parent. Three stents came from vascular stent were placed on the position of tracheal stenosis respectively. There were 15mm in length and 4mm in diameter, 15mm in length and 6mm in diameter and 20mm in length and 6mm in diameter. Then balloon dilation was performed in it until the metallic stents perfect expanded.

Results

In this case the stent relieved the symptoms of obstruction, and follow up for 6 months at least, it have be effective treatment, no complications and quality of life improved.

Conclusions

This case confirms that balloon-expandable metallic stents may represent an effective treatment for congenital tracheal stenosis in children.

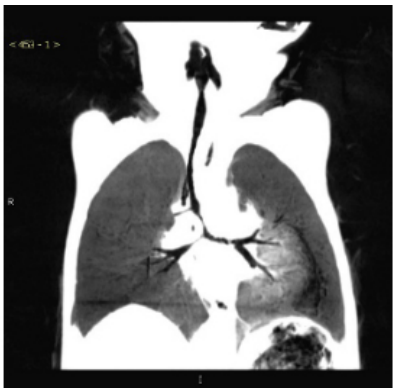

The management of congenital tracheal stenosis with stents placement by bronchoscopy in children

Anxia Jiao[1], Jun Tai[2], Fang Liu[1], Xiaochun Rao[1], Chenfang Meng[1], Yuena Pan[1], Xicheng Liu[1]

[1]Interventional Pulmonology, Beijing Children's Hospital, Capital Medical University - China
[2]Otolaryngology, Head and Neck Surgery, Beijing Children's Hospital, Capital Medical University - China

Introduction

Double aortic arch is rare cardiovascular malformation. It has extremely high mortality rate combined with tracheal stenosis in infant, must be operated as soon as possible. Vascular ring be release after the surgery, but airway stenosis caused by external pressure is still exists, even appeared tracheomalacia. The stents placement is effective on the prevention and treatment of tracheal stenosis or tracheomalacia. But the choice of stent type and the complications after stent placement need to be explored continually.

Objective

To assess the effectiveness and complications associated with stents placement for management of congenital tracheal stenosis combined double aortic arch.

Methods

A 6-months-old infant, male, had severe congenital tracheal stenosis combined double aortic arch. After the vascular ring release operation with double aortic arch, he still could not spontaneous breathing because of tracheal stenosis or tracheomalacia. The agreement about the operation risk of stents placement was signed by the parent. Then, the Dumon stent with 35mm in length and 8mm in diameter was placed by rigid bronchoscope. Ventilation of the patient were markedly improved.

Results

The Dumon stent relieved the symptoms of obstruction, but the stent was coughed after 3 days. So additional agreement about the following operation risk of balloon-expandable metallic stent placement was signed by the parent to deal with the stricture and relieve the symptoms. In this case we placed balloon-expandable metallic stents with 30mm in length and 8mm by bronchoscope instead it. Follow up one month, there is no complications.

Conclusions

This case shows that balloon-expandable metallic stents may be more comfortable for congenital tracheal stenosis in children.

id 341

Diagnosis of peripheral pulmonary lesions using radial-EBUS. A Single TB center first experience

Irina Shabalina (shumskaya)[1], Ilya Sivokozov[1], Galina Evgushenko[2], Yurij Berezovsky[2], Olga Lovacheva[1]

[1]Endoscopy, Central TB Research Institute - Russia
[2]Pathology&Cytology, Central TB Research Institute - Russia

Introduction
Radial-EBUS allows the observation and sample of peripheral lung nodules that can not be imaged with conventional bronchoscopy and increase the diagnostic yield.

Objective
To assess the diagnostic yield of radial-EBUS for the diagnosis of peripheral lung lesions in patients of TB clinic.

Methods
125 patients aged from 13 to 80 years underwent radial-EBUS in our clinic between January 2014 and December 2015 for the diagnosis of peripheral lung nodules and masses. All patients with suspected benign and malignant PPL had negative tests of sputum for TB. The R-EBUS was performed with a radial 20 MHz miniprobe (Olympus UM-3R) passed through the working channel of the 4.0mm - 4.8mm bronchoscope (Olympus BF-180, Olympus BF-Q190) and advanced in to the bronchus adjacent to the PPL. A guide sheath was left in the lesion in performing forceps biopsy and bronchial brush, obtained repeatedly and easily (bronchial brushing and transbronchial biopsy). Bronchoalveolar lavage (BAL) – (40 patients) or Bronchial washing (BW) – (37 patients) was also routinely performed after the biopsy and brushing techniques and removing GS in patients with TB suspicious nodules for microbiological culture study (Bactec MGIT 960) and TB PCR (GenoType MTBDRplus/GenoType MTBDRsl)). We performed standard histological exam. on the biopsy specimens and cytological exam. on the brushing and BW or BAL specimens.

Results
One hundred and twenty five patients (53.6% female) were enrolled in the study. R-EBUS found 79 nodules (2.1±0.73cm) and 41 masses (3.9±0.83cm) (120/125 (96%)). All procedures were performed under local anesthesia. No adverse event was reported. Diagnosis of the PPLs were found in 99 of 120 (82.5%) patients including 39 tuberculosis (39,4%), 21 adenocarcinoma and 10 squamous cell carcinoma (31,3 %), 18 (18,2%) benign lesions (organizing pneumonia, sarcoidosis) and 11 (11.1%) other diseases (angioperitsitoma, pulmonary Hodgkin's Lymphoma, carcinoid). The bronchial brushes, biopsy, and BAL (BW) were diagnostic in 35 (89.7%), 29 (74.4%), and 6 (15,4%) patients with malignancy and in 54 (90.0%), 30 (50%), and 38 (63.3%) patients with benign diseases, respectively. In all TB patients diagnosis tuberculoma with caseating necrosis and acid-fast mycobacterium (cytologically) supported by microbiological evaluation (besides revealed 2 cases Mycobacterium kansasii). Interest is the fact that in 5 patients treated with anti-TB therapy from 6 months to 1 year, the diagnosis was changed to a malignant tumor

Conclusions
The use of radial - EBUS allows receive the biopsy directly from the target lesions in patients with sputum-negative pulmonary TB that important for treatment and avoiding yatrogenic damage.

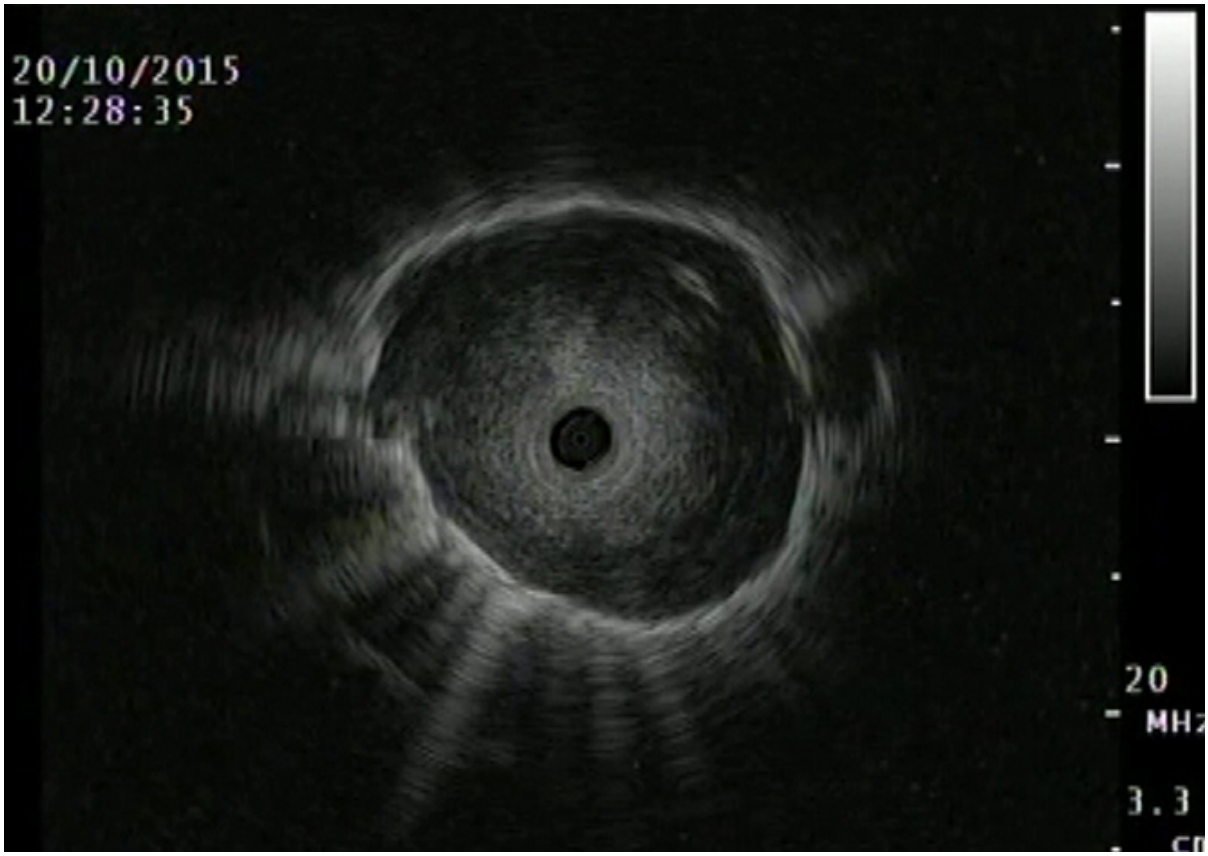

id 342

19th WCBIP / WCBE World Congress
JOINT MEETING OF THE WORLD ASSOCIATION FOR BRONCHOLOGY AND INTERVENTIONAL PULMONOLOGY & THE INTERNATIONAL BRONCHOESOPHAGOLOGICAL SOCIETY
www.wcbipwcbe2016.org
Fortezza da Basso
May 8-11, 2016
Florence (Italy)

Vascular Leiomyoma of the Larynx: A Case Report

Takashi Kojima

Otorhinolaryngology, Machida Municipal Hospital - Japan

Introduction
Vascular leiomyoma is known as a subcutaneous tumor that commonly occurs with pathognomonic pain in the lower limbs of middle-aged women. Laryngeal vascular leiomyoma is extremely rare, with this being the 28th case of its kind in the literature worldwide.

Objective
To show a case of vascular leiomyoma in larynx that was treated by modified submucosal transhyoidal pharyngotomy.

Methods
We report a case of a 65-year-old male patient with a vascular leiomyoma in the larynx, a benign tumor that is rare in this organ. Chief complaints were odynophagia and muffled voice. Flexible laryngoscopy revealed a spherical tumor measuring 2.5cm and covered with normal mucosa on the left aryepiglottic fold.

Results
We immediately admitted the patient and performed tracheostomy under local anesthesia. Inspection of images showed the tumor border was regular and was well enhanced by iodinated contrast medium. Laryngomicrosurgery was carried out under general anesthesia. Histological examination resulted in a diagnosis of vascular leiomyoma. A modified transhyoid pharyngotomy procedure was performed. A horizontal incision was made over the hyoid bone, and the suprahyoid muscles were cut at the site of the attachment. We exfoliated the submucosal layer of the tongue root and aryepiglottic fold, and then extirpated the tumor completely. The postoperative course was uneventful and the patient was discharged 14 days after the operation.

Conclusions
This surgical technique can be considered a useful procedure in reducing postoperative complications such as pharyngeal fistulae or problems in swallowing.

Bibliography
Xu Y, Zhou S, Wang S: Vascular leiomyoma of the larynx: a rare entity. Three case report and literature review. ORL J Otorhinolaryngol Relat Spec 70(4): 264-7, 2008

19th WCBIP / WCBE World Congress
JOINT MEETING OF THE WORLD ASSOCIATION FOR BRONCHOLOGY AND INTERVENTIONAL PULMONOLOGY & THE INTERNATIONAL BRONCHOESOPHAGOLOGICAL SOCIETY
www.wcbipwcbe2016.org
Fortezza da Basso
May 8-11, 2016
Florence (Italy)

Cryotherapy in prevention and treatment of benign tracheobronchial stenoses-single center experience

Spasoje Popevi?[1], Živka Uskokovi?-strefanovi?[2], Milan Gruji?[2], Branislav Ili?[2]

[1]Interventional Pulmonology Unit, University Hospital for Pulmonology, Clinical Center of Serbia, School of Medicine, University of Belgrade - Serbia
[2]Interventional Pulmonology Unit, University Hospital for Pulmonology, Clinical Center of Serbia - Serbia

Introduction

Cryotherapy is based on tissue destruction by freezing. It's used mainly in palliation of central airway tumors (recanalisation) , for cryobiopsy and foreign body removal, but also in treating benign conditions, such as granulation tissue removal (stent owergrowth, after lobectomy/pneumonectomy, etc)

Objective

The aim of the study is to present our experience in treatment of granulation tissue reaction using cryoprobe.

Methods

In period of 2011-2014. in Bronchoscopy Department of University Hospital for Pulmonology in Belgrade, we performed 32 such interventions for benign tracheobronchial disorders via flexible bronchoscope in local anaesthesia with conscious sedation, or by rigid bronchoscope in general anaesthesia, using both flexible and rigid cryoprobe.

Results

In 16 patients foreign body extraction was done (herbal in 8 patients, tablets in 4, bones in 4 patients and in one patient inorganic matherial (glass)); out of them, 10 patients developed granulation tissue reaction . In 8 patients it was successfully treated with repeated cryotherapy and no significant fibrostenosis occured, while in 2 patients, in whom foreign body remained undiscovered for 3.5 and 7 months, respectively, ireversible stenosis occured, despite cryotherapy after extraction. In one of these patients, the tip of the mercury thermometer was causing obstruction. In 2 patients with silicone and polyflex stents, we treated moderate, partially obstructive granulation tissue overgrowth, with success. Also, in 4 patients with endobronchial tuberculosis (EBTB) (2 with active caseating (1 in trachea), 1 with edematous hyperemic and 1 tumorous form), after careful recanalisation with flexible bronchoscope and forceps, cryotherapy was done mainly in order to maintain airway patency and to prevent fibrostenotic EBTB. All patients received corticosteroid and antituberculous therapy. In all of them bronchial /tracheal lumen remained sufficiently patent, including one with tumorous form, who underwent repeated treatments for 7 months.

Conclusions

Patients with benign tracheobronchial disorders can also benefit from cryotherapy, if granulation tissue is present.

id 344

Bronchoscopy as rescue-therapy for non-invasive ventilation failure in acute respiratory failure

Raffaele Scala, Uberto Maccari, Giuseppina Ciraleglio, Valentina Granese, Claudia Maggiorelli, Chiara Madioni, Francesco Costa, Roberta Di Grazia

Pulmonology and RICU, S. Donato Hospital - Italy

Introduction

An excessive burden of secretions is one important cause of on invasive ventilation (NIV) failure in acute respiratory failure (ARF)

Objective

To Evaluate feasibility, safety and effectiveness of fiberoptic bronchoscopy (FBO) in enlarging the success of NIV in ARF-patients at risk of failure due to excessive bronchial

Methods

All consecutive ARF patients who were failing NIV because of ineffective spontaneous clearance secretions in our 4-bed Respiratory Intensive Care Unit (RICU) in the years 2013-2015 were recruited. NIV failure was defined as need of endotracheal intubation (ETI) or death in do-not-intubate (DNI) patients. Timing of FBO, technical issues (route of access vs interface), ancillary bronchoscopic techniques, length of procedure, type of sedation were analyzed. Primary outcome was: success of FBO+NIV procedure as rescue strategy of NIV failure. Secondary outcomes were: 1) complications (within 24 hrs): a) worsening of PaO2/FiO2 ratio and/or PaCO2 >20% vs baseline; b) cardiovascular events requiring treatment (arrhythmias, acute coronary syndromes, pulmonary edema, hypertensive pousse', shock); c) severe haemoptysis; d) bronchospasm requiring treatment; e) pneumothorax. 2) hospital mortality.

Results

48 out 608 ARF-patients requiring NIV in the study time were recruited: 28 of them with acidotic hypercapnia (pH 7,28+/-0,07; PaCO2 69,4+/-7,1 mmHg) and 19 of them with hypoxemia (PaO2/FiO2 173+/-50) under ventilation. FBO was performed 3,4+/-3,6 after hours of ventilation (n. 24/48 <24 hrs of NIV) with BAL (all cases) and transbronchial biopsy (n.3 cases with diffuse lung disease) The most used interface to deliver NIV was total-face mask (n.38) vs oronasal mask (n.8) and vs helmet (n.3); in the larger amount of cases FBO was introduced via the oral (n.35) vs the nasal route (n.13). Length of FBO-procedures was of 12+/-5 minutes. FBO was needed >1 time in 16/48 pts (33%). Sedation was performed with bolus of propofol (n.35), midazolam (n.13), petidine combined with propofol (n.22) or midazolam (n. 5). Transitory hypoxemia occurred in 3/48 cases with no other complications. Combination of NIV+FBO succeeded in avoiding NIV failure in 34/48 cases (70,8%). ETI was performed in 7/14 cases while the other 7 patients shared DNI decisions with physicians; hospital mortality was of 27% (13/48).

Conclusions

According to our RICU's experience, FBO is a feasible, effective and safe rescue strategy in case of NIV failure due to an excessive burden of secretions in ARF.

Bibliography

Scala R et al, Critical Care 2010, 14:R80 Scala R. Shortness of Breath 2015; 4 (2): 47

19th WCBIP / WCBE World Congress
JOINT MEETING OF THE WORLD ASSOCIATION FOR BRONCHOLOGY AND INTERVENTIONAL PULMONOLOGY & THE INTERNATIONAL BRONCHOESOPHAGOLOGICAL SOCIETY
www.wcbipwcbe2016.org
Fortezza da Basso
May 8-11, 2016
Florence (Italy)

Prevalence of fissure integrity assessed byabsence of collateral ventilation in advanced emphysema

Mauro Novali[1], Pierfranco Foccoli[1], Federico Quadri[1], Carlo Toninelli[1], Michela Bezzi[2]

[1]Endoscopia Respiratoria, Spedali Civili di Brescia - Italy
[2]Interventional Pulmonology, University Hospital Careggi - Italy

Introduction

In late stage emphysema hyperinflation contributes to symptoms, functional impairment and inflammation. Endoscopic lung volume reduction (ELVR) may be proposed to improve dyspnoea, exercise capacity, pulmonary functions, and walk distance in symptomatic patients with marked hyperinflation. Several devices have been developed to achieve ELVR: blocking devices, such as one-way endobronchial valves, and non-blocking devices such as lung volume reduction coils. Blocking devices act deflating lung blocking inspiratory flow while allowing expiratory flow. This promotes atelectasis of the target lobe. Non-blocking devices reduce lung volume by increasing the elastic recoil of the lung There is agreement that for blocking devices to work fissure integrity is needed as it predicts efficacy of ELVR with endobronchial valves.

Objective

Two methods are currently available to evaluate fissure: CT scans with direct observation of fissure completeness and Chartis system to assess the absence of collateral ventilation as the functional result of fissure integrity. The absence of collateral ventilation (CV-) is a predictor of success of endobronchial valves treatment but the prevalence of CV- among patients with late stage symptomatic emphysema is not known.

Methods

94 consecutive patients (Age 68,8; 73 males) with emphysema suitable for ELVR with endobronchial valves (FEV1 < 50% pred; TLC > 100% pred; RV > 180% pred) were evaluated with perfusion scintigraphy to evaluate the heterogeneity of emphysema and with Chartis system to assess collateral ventilation. Scintigraphy data are available for 51 patients and demonstrate heterogeneity in 70%. Chartis assessment was performed in intubated patients under general anaesthesia with negative intermittent pressure ventilation.

Results

In 60 patients (63.8%) fissure integrity was documented by the absence of collateral ventilation in at least one lobe. In this group the emphysema was heterogeneous in 65% In 34 patients (36.2%) collateral ventilation was present bilaterally and was heterogeneous in 77%. No difference in age or sex prevalence was found in the two groups.

Conclusions

In almost 2/3 of the patients evaluated with chartis fissure integrity was documented in at least one lobe. Enfisema heterogeneity doesn't seem to affect fissure integrity.

id 346

19th WCBIP / WCBE World Congress
JOINT MEETING OF THE WORLD ASSOCIATION FOR BRONCHOLOGY AND INTERVENTIONAL PULMONOLOGY & THE INTERNATIONAL BRONCHOESOPHAGOLOGICAL SOCIETY
www.wcbipwcbe2016.org
Fortezza da Basso
May 8-11, 2016
Florence (Italy)

Does EBUS prior to PET-CT scanning impact PET interpretation?

M. Ghanem Aldik, Timothy Howell, Cyrus Daneshvar

Respiratory Medicine, Plymouth Hospitals NHS Trust - United Kingdom

Introduction

Current practice suggests that there should be an interval between biopsy and PET-CT scanning to prevent erroneous FDG avidity. However, this may lead to a delay in patients undergoing additional staging investigations, particularly in those requiring mediastinal staging with endobronchial ultrasound (EBUS).

Objective

To determine whether there is any evidence that EBUS nodal sampling impacts on the PET-CT result.

Methods

All patient undergoing an EBUS and PET-CT were retrospectively identified. Patients were grouped into those having a PET-CT before, within a week following or after a week following EBUS. The positive and negative predictive values (PPV and NPV respectively) were calculated. Comparisons were performed using Chi-squared test. A significance of $p<0.05$ was considered significant.

Results

Over a 14 month period, 180 patients under went EBUS. Of these 91 (51%) patients had a PET-CT scan, with 61, 14 and 16 patients before (group 1), within a week (group 2) and after 1 week (group 3) of the EBUS respectively. A total of 167 nodes were sampled (group 1- 106, group 2 - 24, group 3 - 37). Overall, the PPV and NPV for PET-CT were 47% and 86% respectively. There was no significant difference across groups 1-3 for EBUS +ve FDG avidity ($p=0.9$) or EBUS –ve FDG avidity ($p=0.1$). Overall 14% of FDG negative lymph nodes were positive for malignancy, while 52% of FDG avid nodes were benign.

Conclusions

No significant difference was found between patients undergoing EBUS prior or following EBUS. A recent EBUS should not delay patients from undergoing PET-CT scanning. Further this reflects that EBUS provides a more definitive diagnosis, whilst PET-avidity has a poor PPV for nodal involvement.

id 347

Lung cancer histological types and diagnostic yield combining standard bronchoscopy biopsy methods

Nikolay Yanev, Valeri Andreev, Stefan Stanimirov, Yavor Ivanov

Department of Pulmonary Medicine, Medical University Pleven - Bulgaria

Introduction

The combination of forceps biopsy and cytological methods improves the yield in diagnostic bronchoscopy of lung cancer.

Objective

Our aim was to study the change of the diagnostic yield when combining forceps biopsy with cytology methods (brush and catheter biopsy) and to present the most common histological variants of lung cancer diagnosed by bronchoscopy in our clinical centre.

Methods

Bronchoscopy was performed on 209 consecutive hospitalised patients (mean age 62,6 ± 8.1, 80,3% males) admitted for diagnostic evaluation for lung cancer during the period of 18 months.

Results

Forceps biopsy was performed in 87.2% of all cases, showing diagnostic yield of 61,2%. It was combined with catheter biopsy in 56,5% and brush biopsy in 38,8% of the cases. Diagnostic success when forceps biopsy was combined with catheter was 64,0% and with brush biopsy it was 68,1%. The frequency of squamous cell carcinoma was 50%, adenocarcinoma 22,2%, small-cell carcinoma 20,4% and other variants in 7,4%.

Conclusions

In our study we found that combining forceps biopsy with cytology methods improves significantly ($p<0.05$) the diagnostic yield of bronchoscopy in diagnostic evaluation of lung cancer. The most common histological variant of lung cancer in our study group was squamous cell carcinoma, followed by adenocarcinoma and in 1 of 5 patients small-cell carcinoma.

id 348

19th WCBIP / WCBE World Congress
JOINT MEETING OF THE WORLD ASSOCIATION FOR BRONCHOLOGY AND INTERVENTIONAL PULMONOLOGY & THE INTERNATIONAL BRONCHOESOPHAGOLOGICAL SOCIETY
www.wcbipwcbe2016.org
Fortezza da Basso
May 8-11, 2016
Florence (Italy)

Diagnostic utility of Probe-based Confocal Laser Endomicroscopy for Peripheral Pulmonary Lesions

Yuji Matsumoto, Takehiro Izumo, Yoshihisa Hiraishi, Takaaki Tsuchida

Department of Endoscopy, Respiratory Endoscopy Division, National Cancer Center Hospital - Japan

Introduction

Since the application of radial endobronchial ultrasound (R-EBUS), diagnostic yield of bronchoscopy for peripheral pulmonary lesions (PPLs) has improved. Although the obtained EBUS findings are known to relate diagnostic outcome, even if the findings indicate reaching the target, we sometimes fail to diagnose. Meanwhile, probe-based confocal laser endomicroscopy (pCLE) is a novel technique which provides in vivo real-time image of the contacted surface structures. We hypothesized that pCLE complements R-EBUS for the identification of the precise biopsy site.

Objective

The objectives of this study were as follows; a) establishment of pCLE findings of PPLs and b) assessment of reachability by pCLE in comparison with R-EBUS.

Methods

Consecutive patients who have undergone bronchoscopy for PPLs in National Cancer Center Hospital from June to September 2015 were prospectively enrolled. R-EBUS with a guide sheath (EBUS-GS) was performed under virtual bronchoscopy and X-ray fluoroscopy guidance. Where an adequate EBUS finding (within or adjacent to) was obtained, the first pCLE image was scanned. If the first image was estimated at abnormal, biopsies were performed through the GS. Conversely if not, the position of the GS was adjusted to the second site where an abnormal image was estimated, and then biopsies were performed. These abnormal pCLE images were analyzed exploratorily, and the rate of the position adjustment after pCLE scan was calculated.

Results

Bronchoscopically diagnosed cases were 48 of enrolled 55 (the diagnostic accuracy was 87.3%). The diagnoses included 45 malignant tumors and 3 infectious diseases. Whereas fine and well-regulated elastic fibers formed grid-like structures in normal alveoli, thickened, distorted or obscure fibers formed discontinuous or collapsed alveoli in 38 malignant tumors. Besides, if there were further alveolar destruction, dark hollow including particulate fluorescence was observed in 32 malignant cases (both findings overlapped in 25 cases). The latter finding was also seen in all infectious diseases. However, withered fibers formed unbroken alveoli in 2 benign cases in contrast to malignancy. On the other hand, as many as 22 cases (45.8%) showed the normal first pCLE image and needed the position adjustment. When divided into each EBUS findings, the position adjustment was needed more in adjacent to than within cases (55.6% vs 40.0%).

Conclusions

The pCLE findings of PPLs were apparently differed from normal alveoli. Although further investigation is needed, pCLE has the potential to lead us to the more precise biopsy site.

19th WCBIP / WCBE World Congress
JOINT MEETING OF THE WORLD ASSOCIATION FOR BRONCHOLOGY AND INTERVENTIONAL PULMONOLOGY & THE INTERNATIONAL BRONCHOESOPHAGOLOGICAL SOCIETY
www.wcbipwcbe2016.org
Fortezza da Basso
May 8-11, 2016
Florence (Italy)

Laryngeal and Tracheobronchial Tuberculosis

Ilir Peposhi[1], Perlat Kapisyzi[1], Stefano Gasparini[2], Hasan Hafizi[1], Ornela Nuredini[1]

[1]Pulmonology, University Hospital of Lung Diseases - Albania
[2]Pulmonology, Azienda Ospedaliero-Universitaria "Ospedali Riuniti" Via Conca, 71 ,60020 - Italy

Introduction

Introduction: Endobronchial tuberculosis is defined as tuberculosis infection of tracheobronchial tree and it is not often seen in adult population. In the absence of parenchymal disease endobronchial tuberculosis is less well- recognized and can lead to difficulties in diagnosis. Our aim is to introduce a rare form of tuberculosis that is important because of high probability of developing severe bronchostenosis during its course.

Methods

Case Presentation: We report a 48-year-old man from Kosovo who presented with four -month history of severe non-productive cough, shortness of breath, and chest pain. After clinical and radiological evaluation, computed tomography could not demonstrate the presence of endobronchial lesions and pulmonary lesions. Sputum for Mycobacterium Tuberculosis was negative .The flexible video-bronchoscopy showed multiple tumorous lesions that were seen in larynx, trachea, main carina down to the both main bronchus. The biopsy samples revealed TB diagnosis and tuberculosis therapy was given. In patients with endobronchial tuberculosis healing without any complication could be achieved with timely diagnosis and commencement of early treatment.

Results

Discusion :Airway Tuberculosis is relatively uncommon manifestation of a common disease. Diagnosis of airway tuberculosis is frequently delayed until the onset of serious bronchial stenosis with resultant atelectasis and bronchiectasis. Inflamed mucosa is the most common bronchoscopic finding. Therefore tuberculosis is often not taken into consideration in the differential diagnosis of endobronchial lesions.

Conclusions

Conclusion:This case concludes that flexible fiberoptic bronchoscopy is a useful tool in diagnosis of pulmonary tuberculosis in sputum smear negative patients. Bronchoscopy reveals a higher histological confirmation of diagnosis in patients with strong clinical and radiological evidence suggestive of pulmonary tuberculosis and those having more risk factors.

Bibliography

1-Adesh Kumar et al. Flexible Fiberoptic Bronchoscopy in Suspected Sputum Smear Negative Pulmonary Tuberculosis
2-Levent Dalar, Sinem Nedime Sökücü, Ahmet Levent Karasulu, Sedat Alt?n.Tuberculosis Can Mimic Lung Cancer:

id 350

Successful treatment "Carcinoid Endobronchial" with Laser Therapy

Ilir Peposhi[1], Perlat Kapisyzi[1], Yalcin Karakoca[2], Ornela Nuredini[1]

[1]Pulmonology, University Hospital of Lung Disases - Albania
[2]Pulmonology, Medical Park Hospital Cancer Istanbul Turkey - Turkey

Introduction

Bronchial carcinoid tumors are rare, good –difference classified as malignant neuroendocrine tumors and account for 5% of all lung neoplasms. Standard treatment of carcinoid tumors has been surgical resection. Different techniques of Interventional bronchoscopy are available for intraluminal treatment of carcinoid tumor. One of these new techniques with less complication is laser therapy.

Objective

In this presentation, we presented a carcinoid tumor case a large endobronchial with placement in the primary left bronchus in end parts, confirm with biopsy. The tumor was treated successfully with laser therapy resections in April 2010. The patient continues to be very good, with no local or systemic relapse over a period of 5 years.

Methods

A 21-year-old female law student, nonsmoking, which is presented with dyspnea, productive cough, chest angina, sweat .Patients was about 2 years that clinic Allergy treated for bronchial Asthma and in the last 2 months she complained to gradual growth of dyspnea, productive cough, sub febrile temperature, anorexia. Did not refer to past disease, she was admitted to the hospital 2 times in the last 2 months we allergy for asthma. Cardiac rhythmic were normal, BP- 110/80 mmHg. Auscultation respiration missing almost sinister. Chest –X ray, pulmonary slight increase diaphragms in the left. CT -scan thorax: Endobronchial mass the primary left bronchus, no adenopaty. In flexible bronchoscopy, endobronchial mass with regular contours, very vascularized, that complete stenosis primary left bronchus. Biopsy: typical carcinoid .Patients treatment with laser therapy and mechanical removal becomes rigid bronchoscopy total tumor mass.

Results

Patients treatment with laser therapy and mechanical removal becomes rigid bronchoscopy total tumor mass.

Conclusions

Bronchial carcinoid has tendency for polypoid growth, central localization,a low rate of local and distant metastases, and a high survival rate in the patients with carcinoid tumors suggest that bronchoscopic treatment is an effective initial treatment. Results of mini-invasive techniques such as bronchoscopy interventional endoscopic local treatment methods can potentially be a first line option.

Bibliography

1-Kirill Neyman, MD,*w Arve Sundset, MD et al .J Bronchol Intervent Pulmonol 2012;19:29–34)

id 351

A case of Pneumomediastinum after Endobronchial Ultrasound - Guided Transbronchial Needle Aspiration

Ines Maria Grazia Piroddi

Respiratory Diseases Unit, Hospital of Sestri Levante - Italy

Introduction

Endobronchial ultrasound-guided transbronchial needle aspiration (EBUS-TBNA) is a safe and effective technique for the sampling of mediastinal and hilar adenopathies. (1) We report a case of pneumomediastinum following EBUS-TBNA of mediastinal lymph nodes stations.

Methods

A 42-year-old woman appeared at outpatient pneumology for persistent cough for about one month without fever. She complained with chest pain since the week before. Her chest x ray showed a left massive perihilar opacity. Her medical history had been negative until that moment. Antibiotic therapy was prescribed with levofloxacin and she performed computerized tomography (CT) scan that showed a big left upper lobe solid mass 10x12 cm of diameter with superior mediastinal and aortopulmonary lymph nodes. PET was positive for pulmonary eteroplasia (SUV 31) and lymph node mediastinopathy. Fibrobronchoscopy and an EBUS-TBNA were done in day hospital regimen with the intention of diagnosing and staging the probable lung tumor. She underwent bronchoscopy with EBUS-TBNA of subcarinal lymph node station (nodal stations 7) and suspected pathological tissue at upper left bronchus. The procedure was performed under deep sedation with midazolam and propofol but resistant cough occurred. After the completion of the exam the patient presented acute chest pain immediately regressed. The physical examination was negative so she returned home. Cytologic results of all biopsies from EBUS-TBNA were negative. During a CT–fine-needle aspiration (FNA) in the next week a pneumomediastinum was diagnosed (FIGURE 1). The patient was admitted for four days, conservative management was enough to solve. The anamnestic report of a mild chest pain already existing before the procedure was her only complaint. Cytological samples of the FNA were positive for non Hodking diffuse large B-cell lymphoma then staged as 4 because of extranodal spreading (lung infiltration,pericardial effusion).

Conclusions

Complications of EBUS-TBNA are similar to those of conventional TBNA. Pneumomediastinum, mediastinitis, bleeding and rare complications have been reported in literature. So far, complications of the pneumothorax, several cases of infection and airway alterations have been reported in exceptional cases.(2)

Bibliography

1)Asano et all, Complications associated with endobronchial ultrasound-guided transbronchial needle aspiration, Respiratory Research 2013, 14:50 2)Botana-Rial et all, Intramural Hematoma of the Pulmonary Artery and Hemopneumomediastinum after Endobronchial UltrasoundGuidedTransbronchialNeedleAspiration;Respiration 2012;83:353–356

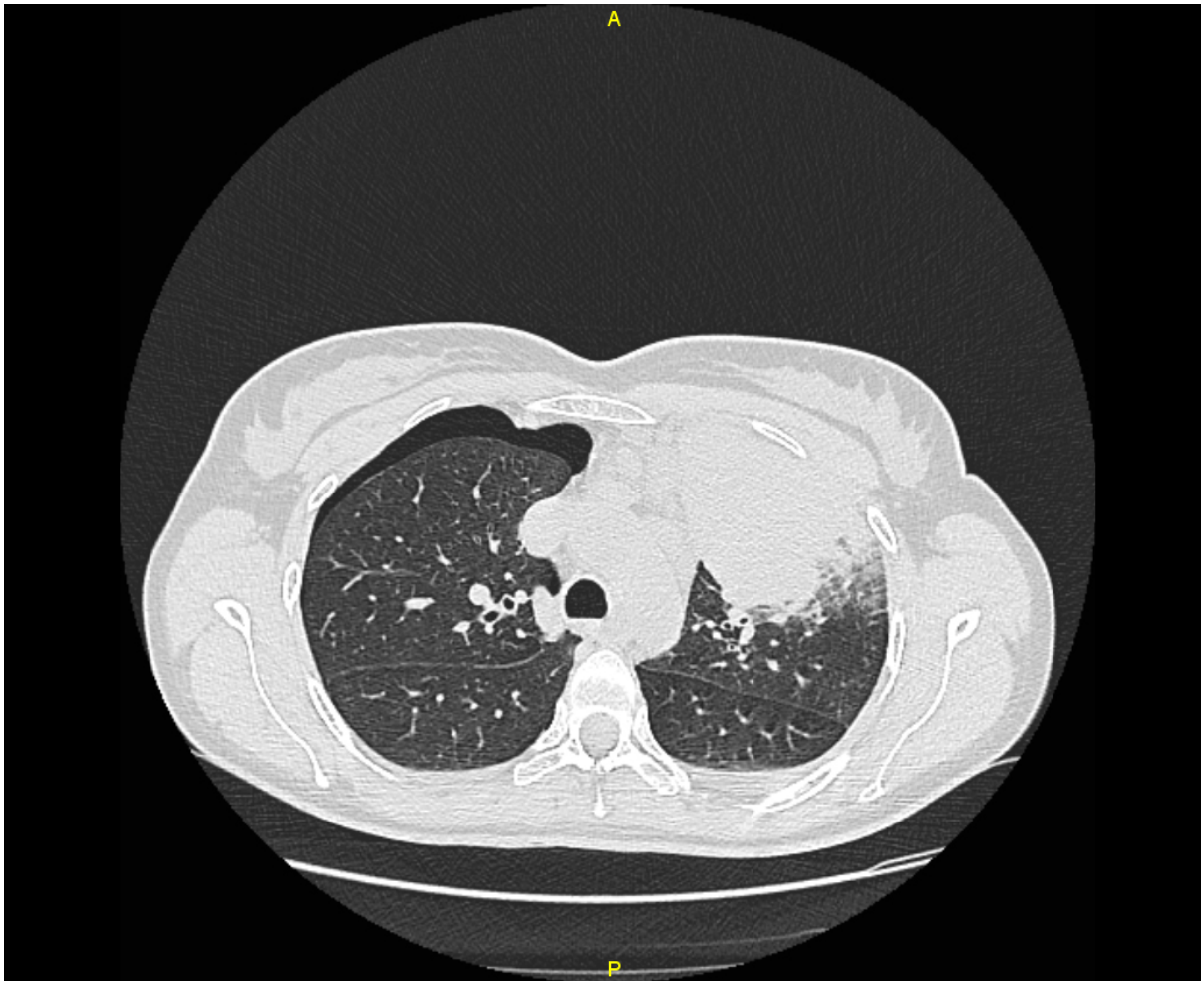

id 352

Successful management of enzyme-targeting and radiosensitization treatment for a lung cancer

Nanae Sugasaki[1], Akitoshi Kinoshita[1], Yasuhiro Umeyama[1], Tomayoshi Hayashi[2], Siro Obata[3], Hiroshi Mukae[4]

[1]Respiratory Medicine, Nagasaki Prefecture Shimabara Hospital - Japan
[2]Diagnostic Pathology, Nagasaki Prefecture Shimabara Hospital - Japan
[3]Radiology, Nagasaki Prefecture Shimabara Hospital - Japan
[4]Respiratory Medicine, Nagasaki University Hospital - Japan

Introduction

The enzyme-targeting and raiosensitization treatment, Kochi Oxydol-Radiation Therapy for Unresectable Carcinomas, typeII (KORTUC II), enhances the radiotherapeutic effect of various type of carcinoma. The injection of hydrogen peroxide and sodium hyaluronate into a tumor induces inactivation of peroxidase and production of oxygen, convert tumors from radioresistant to radiosensitive. We reported a case of lung cancer, tumor was localized in right B3 bronchus, while had declined surgical treatment because of low lung capacity. Using KORTUC II under bronchoscopic examination guidance, the tumor was significantly reduced with no complications.

Methods

A 77-year-old man was diagnosed with stageIA squamous cell lung carcinoma after presentation with exertional dyspenia and wheezing. Chest computed tomography (CT) confirmed a stenosis of right B3 bronchus and peripheral micronoduls. Bronchoscope revealed a localizing tumor in the entry of B3 bronchus and peripheral obstruction. He had left pneumonectomy 10 years ago to cure lung cancer and get well with no recurrence till then. We introduced him to the hospital where he had left pneumonectomy 10 years ago. Right upper lobe resection was not recommended because of low lung capacity. Heavy ion radiotherapy was not also recommended, because it might induce lung injury related to radiation pneumonia. He and his family wished to get over lung cancer, we held cancer board in our hospital to decide his therapy. In the conference, KORTUC II was suggested and we decided to proceed KORTUC II with his consent. A radiosensitizing agent was injected into right B3 bronchus once a week under bronchoscopic examination guidance. For radiotherapy, ultra selective stereotactic body radiotherapy was administered, and total radiation dose was 3.22Gy x 22fraction. After the therapy, tumor in right B3 bronchus markedly reduced and right B3 stenosis got well.

Conclusions

KORTUC II for the patient with bronchus malignant tumor, who had declined surgical treatment was safe and effective.

Bibliography

Ogawa Y, et al. Cancer 2015, 7, 2277-2289

id 353

Predictors of success of lobar collapse therapy using EB valves to treat cavities in tubercolosis

Lorenzo Corbetta[1], Pier Giorgio Rogasi[2], Ariela Tofani[1], Lucio Michieletto[3], Flavio Montinaro[1], Valeria Pasini[1], Loris Ceron[3]

[1]Interventional Pulmonology Unit, University Hospital of Careggi - Italy
[2]Department of Infectious Diseases, University Hospital of Careggi - Italy
[3]Pulmonology Unit, Angel's Hospital of Venice - Italy

Introduction

Before the advent of anti-TB drugs, lung collapse treatments were used in selected cases and they may still play a role in the management of TB. We hypothesized that a recent form of lobar collapse therapy using one-way endobronchial valves may be effective in the treatment of TB with cavities, especially in MDR-TB.

Methods

Seven patients with difficult to treat TB and Atypical Mycobacteriosis with cavities were treated with the authorized off-label insertion of EBV (endobronchial valves), in order to obtain a collapse of the affected lobe from the lesion and healing of the cavity. Eight procedures were done. We considered therapeutic success the complete healing of the cavities and the negativization of the sputum.

Results

The insertion of Zephyr valves was achieved in 7 patients by 8 standard bronchoscopic procedures and without complications. We achieved therapeutic success in 4 of 5 patients (5 out of 6 procedures) who concluded the study protocol. Failure to collapse the cavity was seen only in a noncompliant patient with productive cough who continued to smoke after the valve implant. Nevertheless an improvement of oxygenation and health status occurred. 2 patients are currently in follow-up and will be reported. At the moment, one of these patients with a history of asthma firstly collapsed but then re-ventilated the lobe. After repositioning the valves, the cavity is slowing closing. The second patient still in follow up, previously treated with a lobectomy, is not improving because of lack of atelectasis due to fissures discontinuity.

Conclusions

Our early clinical experience shows that creating a hypoventilation and hypo- oxygenation zone by closing the TB cavities using Zephyr endobronchial valves is feasible and appears to provide long term clinical benefits. Predictors of success are the possibility to obtain atelectasis and the absence of concomitant inflammatory diseases such as asthma and chronic bronchitis. These early results need to be confirmed in a larger patient cohort and with longer follow up.

Bibliography

Corbetta L, et al. Int J Tuberc Lung Dis 2013;17: 850-1

Table 1: Summary outline cases

PATIENT	Sex	INDICATION	AGE	CAVITY LOCATION	DATE OF IMPLANT	Lobar Atelectasis	CLOSURE OF CAVITY	TIME TO SPUTUM NEGATIVE	LATEST SPUTUM TEST	Note
1 VN	F	MDR-TB	31	1. RML 2. Posterior of LUL	05/19/2011 01/11/2012	Y N	Y Y	5 mo	negative	Segmental occlusion in the 2nd implant
2 FB	M	M.xenopi	69	RUL	06/06/2012	Partial	Y	N.A.	negative	Smoker COPD
3 NM	M	MDR-TB	50	LUL	11/21/2013	Partial	partial	4 mo	negative	Smoker Chronic bronchitis
4 CD	F	Difficult to treat TB	54	LUL	04/30/2014	Y	Y	3 mo	negative	
5 PL	F	TB w/ DRESS	59	LUL	10/22/2014	Y	Y	N.A.	Negative	
6VHJP	F	TB	43	LUL	26/05/2015	Partial	To be evaluated	N.A.	Negative	Need to repositioning . Asthmatic
7LGG	F	MDR-TB	33	RLL	26/05/2015	N	To be evaluated	N.A.	Negative	Previous lobectomy. Fissure discontinuation

id 354

Patients' collaboration and satisfaction during bronchoscopy in different sedation strategies

Lorenzo Corsi

Interventional Pulmonology, Department of CardioThoracic and Vascular disease, University Hospital Careggi - Italy

Introduction

Flexible bronchoscopy is a very important medical procedure for the diagnosis of many chest and systemic disease: pulmonary and bronchial neoplasms, lower respiratory tract infections, interstitial lung diseases. To assess a correct diagnosis patients' collaboration is required. In the last years there has been a sensible improvement of sedation tecniques.

Objective

After the bronchoscopy we evaluated the patients' collaboration degree and satisfaction with two different questionnaires: patients questionnaire (PQ) to evaluate satisfaction and operator questionnaire (OP) administred to the endoscopist to evaluate patients' collaboration degree, furthermore the time of upswing in the three different sedation strategies.

Methods

We considered 120 patients scheduled for flexible bronchoscopy with endoscopical procedures such as conventional TBNA, bronchoalveolar lavage, transbronchial and/or endobronchial biopsy and bronchial aspirations. These patients were randomly assigned to three groups: • Group A: local anesthesia with lidocain 1% 3 ml in nose and mouth; • Group B: local anesthesia with lidocain 1% 3 ml in nose and mouth plus midazolam (maximum 5 mg iv); • Group C: llocal anesthesia with lidocain 1% 3 ml in nose and mouth plus a combination of midazolam and remifentanyl (continuous infusion).

Results

Variable in patients and not strictly connected with the kind of medication stategy.

Conclusions

A good diagnosis and the patients' satisfaction depends from a numerous factors such as patients' motivation, a correct explanation by the endoscopist, mental status of the patient.

id 355

Hemiplegia as a rare complication of Transbronchial Needle Aspiration

Marco Trigiani, Valentina Luzzi, Rosamaria Piperio, Michela Bezzi

Interventional Pulmonology, Department of CardioThoracic and Vascular disease, University Hospital Careggi - Italy

Introduction

Hemiplegia following transbronchial needle aspiration (TBNA) is extremely rare, only few cases have been described and its causes are not well understood.

Methods

We report a case of a 61-year old woman affected by systemic hypertension well controlled by medical therapy. In August 2015 she developed rebellious chest pain. The chest x-ray and CT scan showed a right lower lobe lesion with bilateral lymphadenopathy and bone lysis (spine, pelvis, right iliac wing). Bronchoscopy with transbronchial needle aspiration (TBNA) of station 7 could lead to the diagnosis of adenocarcinoma (ALK and EGFR negative, ROS-1 non conclusive). The patient received symptomatic radiotherapy on the right iliac wing and first line chemotherapy with cisplatin and pemetrexed. In November 2015 another bronchoscopy was performed to obtain more tissue for ROS-1 mutation analysis through TBNA of station 7. During the exam the patient developed high blood pressure with spontaneous resolution. Few minutes after the end of the procedure left hemiplegia with dysarthria, deviation of mouth and eyes were detected. While the patient was waiting for brain CT scan partial regression of clinical signs was observed, only left arm weakness and dysarthria remained. The brain CT scan performed 6 hours later didn't show any sign of ischemia. Complete regression of symptoms occurred within 48 hours when the CT scan was again uneventful as well as Doppler examination of the carotids. One month later the patient was completely asymptomatic and brain MRI didn't report any cerebral abnormality.

Conclusions

According to our neurologists, the rapid onset and clinical evolution, in the absence of any radiological sign of cerebral ischemia, lead to the differential diagnosis between cerebral gas embolism in the course of TBNA (as previously reported) versus side effect due to Midazolam being the letter less likely.

Bibliography

Azzola A, et al. Respiration 2010;80:569-572 Perinel Ragey S, et al. Respiration. 2013;86:504-507

id 356

19th WCBIP / WCBE World Congress
JOINT MEETING OF THE WORLD ASSOCIATION FOR BRONCHOLOGY AND INTERVENTIONAL PULMONOLOGY & THE INTERNATIONAL BRONCHOESOPHAGOLOGICAL SOCIETY
www.wcbipwcbe2016.org
Fortezza da Basso
May 8-11, 2016
Florence (Italy)

Independent risk factors for early complications following interventional pulmonology procedures

Junjun Huang, Guangfa Wang

Respiratory Department, Peking University First Hospital - China

Introduction
Interventional pulmonology procedures are important treatments for pulmonary diseases.

Objective
The major aim of this study was to investigate the complication rate and identify clinical risk factors for complications in patients following interventional pulmonology procedures.

Methods
In the period from December 2014 to December 2015, data sufficient for analysis were identified in 221 subjects. The procedures were carried out in general anesthesia. Early complications occurring within 48 hours after interventions were defined as respiratory failure(including type I and II), arrhythmia requiring treatment, infection, severe hemorrhage(requiring systemic treatment including blood transfusion and intravascular interventional procedure), pneumothorax, mediastinal emphysema, pulmonary edema, fistulae, acute coronary syndrome,acute cerebral accident and death. Risk factors were defined as acute cerebral accident within 6 months before treatment, coronary heart disease, arterial hypertension, chronic arrhythmia, chronic obstructive pulmonary disease (COPD), diabetes mellitus, cirrhosis, chronic kidney disease(III stage or more)?smoking status, malignant disease, and previous interventional pulmonology procedure.

Results
There was 57.0% male and 43.0% female subjects in this study. There were 11.3% current smokers, 22.7% former smokers, and 62.0% non-smokers. The overall complication rate was 8.6%. Statistically significant risk factors were coronary heart disease (P = 0.009), COPD (P = 0.043), current smoking status (P = 0.001), and malignant disease (P = 0.046). Independent clinical risk factors were coronary heart disease (P = 0.009), COPD (P = 0.043), current smoking status (P = 0.000), and malignant disease (P = 0.046).

Conclusions
Closer monitoring of patients with identified risk factors is advisable prior and immediately after interventional pulmonology procedures. In order to avoid or minimize complications, special attention should be directed toward patients who are current smokers, with coronary heart disease, COPD, or malignant disease.

Conscious sedation with propofol/remifentanil for bronchial thermoplasty in severe asthma patients

Julia N.s. D'hooghe[1], Susanne Eberl[2], Jouke T. Annema[1], Peter I. Bonta[1]

[1]Pulmonology, Academic Medical Center - The Netherlands
[2]Anaesthesiology, Academic Medical Center - The Netherlands

Introduction

Bronchial thermoplasty (BT) is a rapidly emerging bronchoscopic treatment for patients with moderate-to-severe asthma. The treatment consists of 3 separate procedures during which >2 mm airways are treated with ablative radio-frequent energy. Different sedation strategies are currently used, ranging from mild midazolam-induced sedation (drawbacks: cough and lower patient tolerance [1]) to general anesthesia requiring tracheal intubation (drawbacks: invasive increased risk and higher costs due to the requirement of an anesthesiologist). We hypothesize that specialized anesthesia nurse-administrated propofol and remifentanil sedation is a feasible, safe, and well tolerated sedation strategy that allows BT treatment under spontaneously breathing at low costs.

Objective

To assess the feasibility, safety and satisfaction of specialized anesthesia nurse-administrated propofol and remifentanil sedation in severe asthma patients during bronchial thermoplasty.

Methods

Prospective observational cohort study in severe asthmatic patients of the TASMA study (Clin.Trials.gov nr:NCT02225392). Patients were asked to rate their procedure satisfaction and tolerance with target controlled infusion (TCI) propofol/remifentanil sedation using a visual analogue scale (VAS) ranging from 0 to 10. Endoscopists were asked to rate the cooperation and tolerance of the patient during the procedure. Sedation-associated adverse events and bronchial thermoplasty activations were recorded.

Results

24 BT procedures in 9 severe asthmatic patients were performed under conscious sedation with TCI propofol/remifentanil. Patient's VAS scores were: overall satisfaction 8.8 (SD ± 1.3), dyspnoea 1.0 (SD ± 1.7), anxiety 0.7 (SD ± 1.1), pain 0.8 (SD ± 1.4) and cough 1.7 (SD ± 2.0). Endoscopist's VAS scores were: overall patient cooperation 8.9 (SD ± 0.8), pain 0.7 (SD ± 0.9) dyspnea 0.5 (SD ± 0.8) discomfort 0.9 (SD ± 0.9) cough 1.6 (SD ± 1.1) (Figure 1). All patients were willing to undergo the procedure again and would recommend this form of sedation to their best friend. Desaturation events occurred in total 4 times (Sp02 < 90% for > 30 seconds). Except for one case of desaturation, that required conversion to general anesthesia, all other events restored with supportive care. The mean numbers of activations during BT of the right, left and both upper lobes were 48 (±SD 3.6), 56 (±SD 7.4) and 69 (±SD 6.6) respectively (comparable to large RCTs).

Conclusions

Specialized nurse administrated propofol/remifentanil sedation for BT is feasible and safe and results in high satisfaction rates by both patients and endoscopists Implications: Conscious sedation with propofol and remifentanil might qualify as the sedation strategy of choice for performing bronchial thermoplasty.

Bibliography

1. Lo, Y.L., et al.,PLoS One, 2011. 6(11): p. e27769.

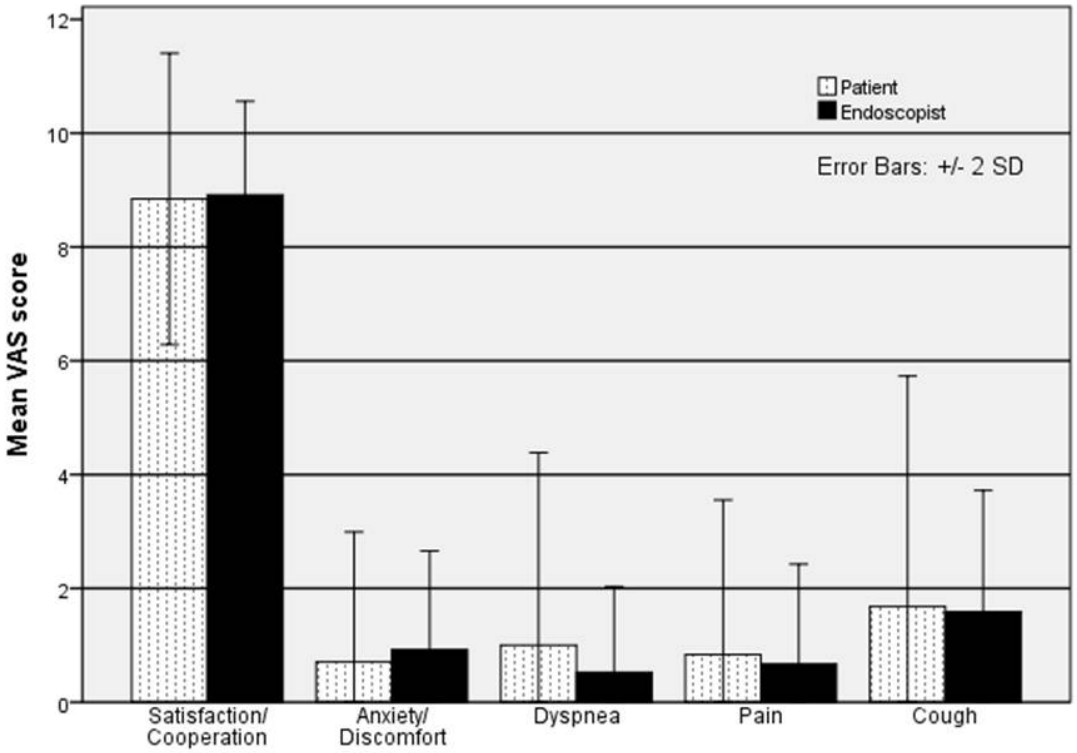

Figure 1. Patient and endoscopist VAS scores during a BT procedure with propofol and remifentanil sedation

id 359

Optical coherence tomography for human in vivo airway wall layer identification and quantification

Julia D'hooghe[1], Daniel De Bruin[2], Joris Roelofs[3], Jouke Annema[1], Peter Bonta[1]

[1]Pulmonology, Academic Medical Center - The Netherlands
[2]Biomedical Engineering & Physics Radiology, Academic Medical Center - The Netherlands
[3]Pathology, Academic Medical Center - The Netherlands

Introduction

Several airway diseases are characterized by airway remodeling. The current available techniques to assess airway wall layers/airway remodeling - including high resolution computed tomography (low resolution) and airway wall biopsies taken during bronchoscopy (invasive /only local information) - have limitations. Optical coherence tomography (OCT) is a high-resolution optical imaging technique which is able to generate real-time, minimally invasive, high- detailed, near histology images of airway segments when combined with bronchoscopy. How airway wall OCT images relate to airway histology is largely unknown.

Objective

In vivo identification and quantification of human airway wall layers by OCT and correlate this to histology.

Methods

In 3 patients with lungcancer, a total of 10 airways were imaged with OCT during bronchoscopy. An OCT catheter (St. Jude Medical Illumien Optis System and Dragonfly catheter) was inserted into the periphery of the lung and an automatic pullback over 5.4 cm was performed of each airway segment. After lobectomy the previous imaged airways were dissected, fixed in formalin and embedded in paraffin. Hematoxylin and Eosin stainings were used to visualize airway wall structure and desmin staining was used to identify airway smooth muscle layer. Airway wall thickness was measured by tracing the luminal perimeter (luminal area (LA)) and airway smooth muscle outer perimeter (total airway (TA)) based on different OCT intensities. Airway wall area (WA (mm2)) and airway wall area percentage (WA%) for both OCT and histology where calculated by WA=TA-LA and WA%=WA/TA x100% respectively.

Results

10 matched OCT- histology airway cross sections were analyzed. The following separate airway wall layers were identified on OCT imaging; respiratory epithelium, basal membrane, lamina propria surrounded by smooth muscle, glands, vessels and cartilage. Airway wall area (WA) and the airway wall area percentage (WA%) measured by OCT correlated with histology (N=10; R 0.94 95% CI 0.77-0.99, $p<0.0001$ and N=10; R 0.95 95% CI 0.81-99, $p<0.0001$ respectively) (figure 1A+B).

Conclusions

In vivo OCT imaging correlates well with histopathology both for identification of airway wall layers and quantification of airway wall thickness. Implications: OCT imaging might qualify as the imaging technique of choice to assess airway wall remodelling, for instance the airway smooth muscle content.

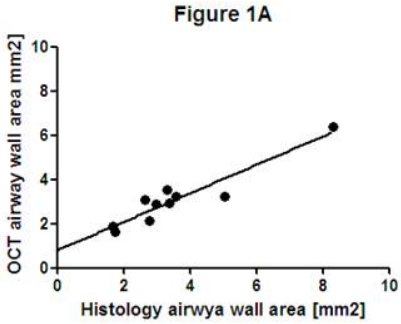
Figure 1A
OCT airway wall area mm2]
Histology airwya wall area [mm2]
0
2
4
6
8
10

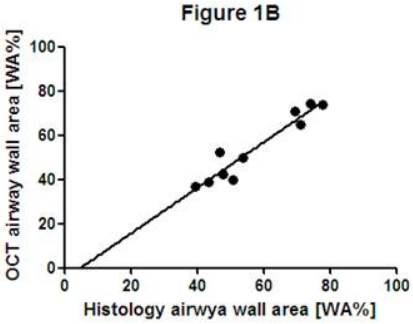
Figure 1B
OCT airway wall area [WA%]
Histology airwya wall area [WA%]
0
20
40
60
80
100

id 360

Active Endobronchial Wegener's Granulomatosis

Ilir Peposhi, Perlat Kapisyzi, Milda Nanushi, Hasan Hafizi, Loreta Karaulli(Agolli)

Pulmonology, University Hospital of Lung Diseases - Albania

Introduction

Wegener’s granulomatosis (WG) is a form of systemic vasculitis that involves primarily the upper and lower airways, lungs, and the kidneys. The most common manifestations include subglottic stenosis, airway inflammation and bronchial stenosis.

Objective

The endobronchial involvement could be in the form of active inflammation and ulceration of the mucosa called ‘‘ulcerating tracheobronchitis”. Endoscopic visualization of respiratory airways is the best tool for assessment, diagnosis and management of these changes.

Methods

A 52-year-old man presented in emergency room in our hospital with symptoms of cough, sputum with blood rowing and sprinkle hemoptysis, dyspnea and macroscopic hematuria. He recovered at our hospital with diagnosis: Right Atypical pneumonia. He has six months with hemoptysis, some phenomens of Rheumatoid arthritis (ANA et FR -negative) and diabetes mellitus type II. In the CT scan of thorax, pulmon dexter has infiltrative pneumonic lesions.

Results

The patient underwent flexible bronchoscopy, which revealed inflammation and ulceration of the epiglottis and numerous ulcerative erosions of tracheal and bronchial tree especially on the left, infiltrative mucosal area in distal part of left main bronchus. Bronchial biopsy revealed necrotizing granulomatosis with capillaritis. Cytoplasmic antinuclear antibodies (C-ANCA) were positive.The histopathological findings together with radiologic and laboratory reports, lead to the diagnosis of Wegener's granulomatosis (WG).

Conclusions

Wegener’s granulomatosis is a multisystemic, idiopathic, necrotizing granulomatous vasculitis, which mostly involves the upper and lower airways, and the kidneys. Approximately 85% of patients develop lung development during the course of the disease, and 45% have lung involvement at presentation. Endobronchial involvement occurs in up to 55% of the patients. Bronchoscopy has an important role in the diagnosis, monitoring and treatment of lesions of the airway WG, being a minimally invasive alternative.

Bibliography

1-Debasis H. Sahoo, MD and Atul C. Mehta, MB, BS, FCCP, FACP J Bronchol Volume 12, Number 3, July 2005

id 361

19th WCBIP / WCBE World Congress
JOINT MEETING OF THE WORLD ASSOCIATION FOR BRONCHOLOGY AND INTERVENTIONAL PULMONOLOGY & THE INTERNATIONAL BRONCHOESOPHAGOLOGICAL SOCIETY
www.wcbipwcbe2016.org
Fortezza da Basso
May 8-11, 2016
Florence (Italy)

Four cases of IgG4-related pleural disease diagnosed by medical thoracoscopy

Rinna Tei[1], Akihiro Takemasa[1], Kushima Yoshitomo[1], Ikeda Naoya[1], Takafumi Umetsu[1], Ryou Arai[1], Hidenori Takizawa[1], Kazuyuki Chibana[1], Masaaki Miyoshi[1], Yasuo Shimizu[1], Yoshimasa Nakazato[2], Yoshiki Ishii[1]

[1]Department of Pulmonary Medicine and Clinical Immunology, Dokkyo Medical University School of Medicine - Japan
[2]Department of Pathology, Dokkyo Medical University School of Medicine - Japan

Introduction
IgG4-related disease is a recently recognized disease entity with characteristic clinicopathological features by lymphoplasmacytic inflammation including IgG4-positive plasma cells. Although it can affect various organs, there are a few reports on IgG4-related diseases manifesting as pleuritis.

Objective
The present study aimed to analyze the clinical characteristics of IgG4- related pleural disease diagnosed by medical thoracoscopy.

Methods
We analyzed the clinical characteristics of 4 cases of IgG4-related pleural disease diagnosed by medical thoracoscopy.

Results
Four cases including 3 male and a female were analyzed in this study. Mean age was 70.5 years (57-80). As for the underlying disease, Sjögren's syndrome, benign asbestos pleurisy, and yellow nail syndrome were by one case each, and the other case had no comorbidity. All 4 cases presented exudative pleural effusions with lymphocyte predominance. Pleural biopsy was performed by medical thoracoscopy, which revealed pleuritis with lymphoplasmacytic inflammation including IgG4-positive plasma cells. All cases demonstrated elevated levels of serum IgG4. They were not accompanied by retroperitoneal fibrosis or pancreatitis. All showed a good response to corticosteroid therapy.

Conclusions
IgG4-related diseases have been reported with various organ complications such as retroperitoneal fibrosis or pancreatitis, however, our cases did not show other organ involvement except pleuritis. Future examination is needed to clarify whether IgG4-positive lymphoplasmacytic inflammation is related to etiology. IgG4-related disease should be considered in the differential diagnosis of unexplained pleuritic, and pleural biopsy by medical thoracoscopy is thought to be useful for the diagnosis.

id 362

19th WCBIP / WCBE World Congress
JOINT MEETING OF THE WORLD ASSOCIATION FOR BRONCHOLOGY AND INTERVENTIONAL PULMONOLOGY & THE INTERNATIONAL BRONCHOESOPHAGOLOGICAL SOCIETY
www.wcbipwcbe2016.org
Fortezza da Basso
May 8-11, 2016
Florence (Italy)

Clinical aspects of severe deep neck abscesses and mediastinitis

Masao Yagi

Otolaryngology and Head & Neck Surgery, Kansai Medical University - Japan

Introduction

Descending necrotizing mediastinitis (DNM) is one of the most serious and sometimes lethal forms of mediastinitis which caused by downward spread of deep neck infection. DNM arises as a complication of odontogenic, pharyngeal, and other cervicofacial foci. Although most of peritonsillar abscess are originated from the superior pole of the palatine tonsil and inferior pole peritonsillar abscesses are rare, inferior pole peritonsillar abscesses tend to progress to the descending soft tissues.

Objective

The purpose of this study was to analyze clinical data from cases with descending necrotizing mediastinitis originating from deep neck infection.

Methods

We retrospectively reviewed clinical data from 50 cases of deep neck abscess between 2006 and 2015 seen at the Hirakata hospital of Kansai medical university.

Results

The age of the patients ranged from to years old a mean age of 59 years old. Of the 50 cases, 31 cases were male and 19 cases were female. Approximately 35% of the cases had diabetes mellitus as an underlying disease. DNM was found in 10 cases. Six cases of DNM arose from the inferior pole peritonsillar abscess, 3 cases of DNM arose from the superior pole peritonsillar abscess, and one case of DNM arose from the retropharyngeal abscess.

Conclusions

As highly clinical suspicion and prompt diagnosis are critical to diagnosis DNM, computed tomography (CT) including neck and chest may be useful because of its ability to assess the origin, presence and extent of infection and to determine the appropriate surgical approach.

Bibliography

Ridder et al. Descending Necrotizing Mediastinitis: Contemporary Trends in Etiology, Diagnosis, Management, and Outcome Annals of Surgery 2010 251; 528- 534

id 363

Post-pneumonectomy and post-lobectomy syndroms. Case series-Diagnostic and Therapeutic challenges

Grigorios Stratakos[1], Vlasios Vitsas[1], Charalampos Zissis[2], Nikolaos Koufos[3], Phillip Emmanouil[3], Nikolaos Koulouris[3]

[1]1st Respiratory Medicine Department,, National and Kapodistrian University of Athens - Greece
[2]Thoracic and Cardiovascular Surgery Department,, “Evangelismos” Hospital, - Greece
[3]1st Respiratory Medicine Department, National and Kapodistrian University of Athens - Greece

Introduction

Postpneumonectomy syndrome (PPS) is a rare complication resulting from extreme shift and rotation of the mediastinum after right or (more seldom) left pneumonectomy. Bronchomalacia of the remaining central airways is also often encountered. Patients may present with progressive dyspnea, stridor and recurrent pulmonary infections. Less often a simple lebectomy may produce a similar post-lobectomy syndrome (PLS). Diagnosis is based on the medical history, symptoms, thorax CT scan and dynamic bronchoscopy findings.

Methods

a. Post - Right pneumonectomy syndrome A 70-year-old male with a history of right pneumonectomy 2 years ago due to non-small cell lung cancer (NSCLC) was diagnosed with PPS and bronchomalacia of the remaining left main stem bronchus. Noninvasive mechanical ventilation (NIMV) was initially applied to alleviate symptoms, followed by insertion of a self-expandable metallic stent. Due to persistent severe exertion dyspnea, he was referred to our unit and underwent rigid bronchoscopy. The stent had migrated and was partly occluded and thus was removed and replaced by a larger silicon one. After this intervention the patients’ symptoms recessed. b. Post- Left pneumonectomy syndrome A 27-year-old female with a history of a left pneumonectomy due to endobronchial carcinoid, was diagnosed with PPS. Dynamic bronchoscopy revealed mild excessive dynamic airway collapse (EDAC). The patient reported no other major symptoms apart from mild exertion dyspnea. After interdisciplinary discussion no surgical or other interventional treatment strategy was proposed to this patient. c. Post-Lobectomy syndrome A 75-years-old patient with a history of right upper lobectomy four years ago, presented with wheezing and recurrent infections. A CT scan revealed a slight shift and counterclockwise rotation of the mediastinum. The dynamic bronchoscopy revealed EDAC of the bronchus intermedius. He was inserted a self expandable metallic stent for six months until it migrated and was removed. A new dynamic bronchoscopy followed under NIMV mask which proved that EDAC of bronchus intermedius was corrected under positive pressure ventilation. The patient remains since under NIMV.

Conclusions

PPS and PLS are rare complications of lung resection procedures. Extreme shift of the mediastinum produces changes in lung mechanics and respiratory physiology leading to severe functional impairment. The treatment remains individualized according the type and the extent of the abnormality. Although surgical management by insertion of tissue expanders in the pleural cavity remains the main treatment, other options include stent insertion or NIMV. Prompt recognition and classification of the syndrome is the key for effective management.

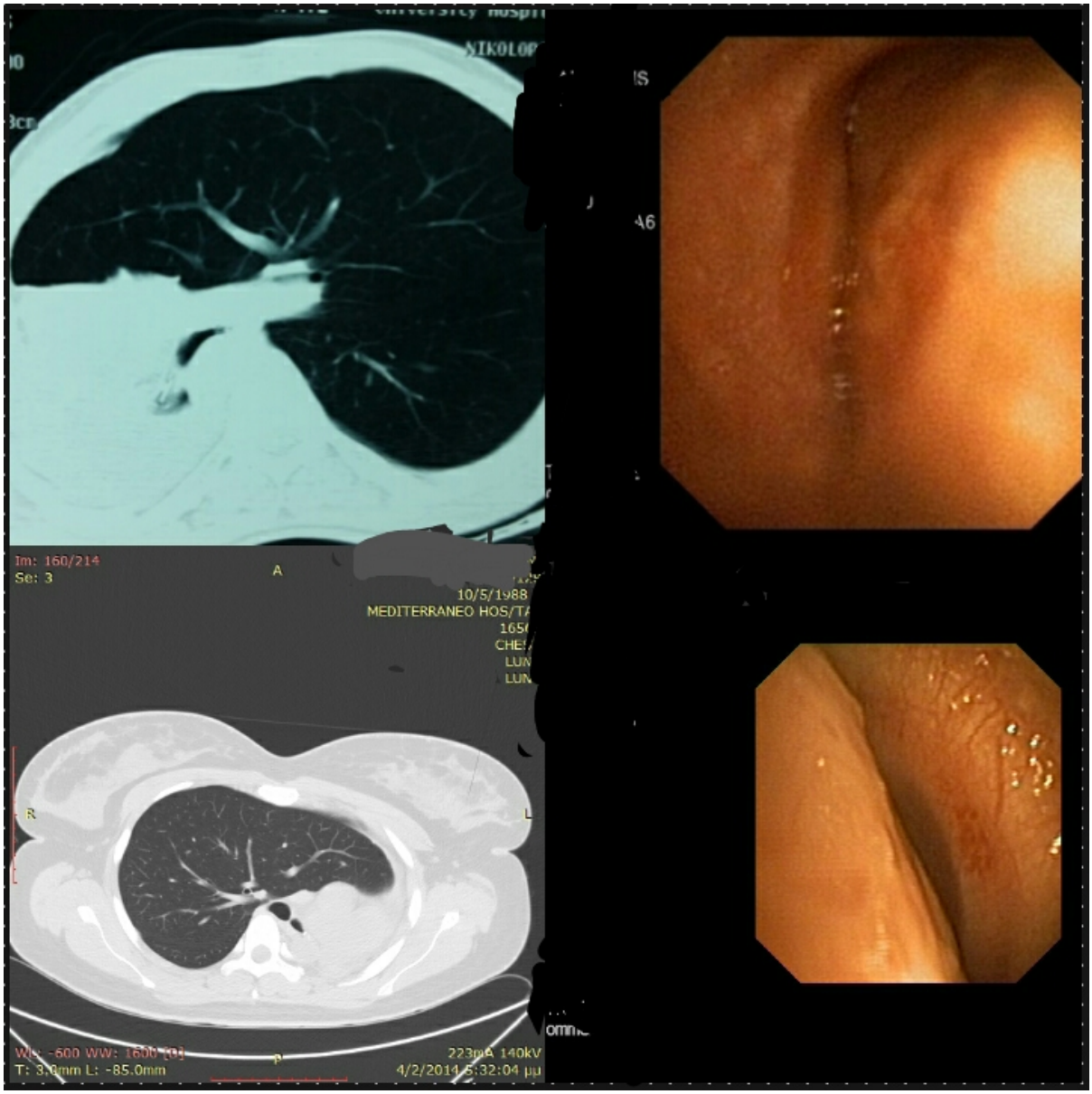
Im: 160/214
Se: 3
10/5/1988
MEDITERRANEO HOS/TA
223mA 140kV
4/2/2014 5:32:04 μμ
T: 3.0mm L: -85.0mm

id 364

19th WCBIP / WCBE World Congress
JOINT MEETING OF THE WORLD ASSOCIATION FOR BRONCHOLOGY AND INTERVENTIONAL PULMONOLOGY & THE INTERNATIONAL BRONCHOESOPHAGOLOGICAL SOCIETY
www.wcbipwcbe2016.org
Fortezza da Basso
May 8-11, 2016
Florence (Italy)

A case of recurret spindle cell lipoma in retropharyngeal and paratracheal space

Takuo Fujisawa, Masao Yagi, Koichi Tomoda

Otolaryngology, head and neck surgery, Kansai Medical University - Japan

Introduction

Lipomas are slow-growing benign soft-tissue tumors which are typically asymptomatic and occur in approximately 1% of population. Lipomas are often small and solitary lesions and can glow in any area of the body where adipose tissue is present. Spindle cell lipoma is a rare tumor of soft tissues, originally described in 1975 by Enzinger FM and Harvey DA. It is characterized by a mixture of mature adipocytes and undifferentiated spindle cells. Sometimes a histological examination is difficult differential diagnosis of liposarcoma.

Methods

A 66-year-old male initially presented to an outside hospital with a few months history of progressive dysphagia and throat discomfort. He was admitted and his workup include MRI of the neck showing a retropharyngeal and paratracheal mass(3.2cm anteroposterior, 6.2cm transverse, and 10.2cm craniocaudad). In 2010 transoral resection was performed, however it was incomplete resection. Residual tumor was gradually increased. Transoral resection was performed again in 2013. However second operation was incomplete too. He was referred our hospital and in 2013 transcervical resection was performed. In histologicaly tumor was total removed but spread lesion was existed. In 2015 recurrence tumor was revealed in initial operation area and Transoral Videolaryngoscopic Surgery was performed. He has been followed for over 1 year post-operatively without evidence of recurrent disease.

Conclusions

Incomplete resection is a major risk factor for repeating the recurrence. Spindle Cell Lipoma is an important differential diagnosis of Liposarcoma, in this case it was considered to be necessary in the future also strict observation.

id 365

Risk factor of pneumonia after bronchoscopy

Akira Sakurada[1], Fumihiko Hoshi[2], Yasushi Matsuda[2], Masafumi Noda[2], Yasushi Hoshikawa[2], Yoshinori Okada[2]

[1]Thoracic Surgery, Tohoku University - Japan
[2]Thoracic Surgery, Tohoku University Hospital - Japan

Introduction

Pneumonia is one of important complications after diagnostic bronchoscopy for lung nodule. Based on nation-wide questionnaire based survey conducted by Japanese Society of Respiratory Endoscopy, frequency of pneumonia is reported to be 0.07% in the patients those who underwent brushing cytology and 0.20% in the patients those who underwent forceps biopsy.

Objective

1. To understand the frequency of pneumonia after diagnostic bronchoscopy in our department. 2. To clarify significant risk factor(s) for pneumonia after bronchoscopy.

Methods

From 2010 to 2014, bronchoscopic brushing cytology and/or biopsy toward pulmonary nodule were performed for 488 patients in our department. Medical records of these examinations were retrospectively reviewed. Clinical information including age, gender, performance status, diagnostic procedure, bleeding on examination, consumption of anti-coagulation drugs, tumor size, tumor histology, smoking index, FEV1.0%, and %VC were collected. For statistical analysis, p value less than 0.05 was regarded as significant.

Results

Five patients (1.0%) had pneumonia within one week after diagnostic bronchoscopy and needed admission for treatment. All of these were diagnosed as lung cancer. Four were squamous cell carcinoma and one was adenocarcinoma. All of those were male and had high smoking index. Four showed disturbed pulmonary function; FEV1.0% to be less than 70. All of these patients recovered by intravenous administration of antibiotics. By multivariate analysis, disturbed pulmonary function was a significant risk factor of pneumonia after diagnostic bronchoscopy.

Conclusions

Frequency of pneumonia after bronchoscopy which is need to be treated by admission was 1.0% in our department. Intervention for high-risk patients, such as pulmonary rehabilitation, inhalation, and administration of antibiotics before examination, could be candidates of effective methods to reduce pneumonia after bronchoscopy. Further study is needed.

id 366

19th WCBIP / WCBE World Congress
JOINT MEETING OF THE WORLD ASSOCIATION FOR BRONCHOLOGY AND INTERVENTIONAL PULMONOLOGY & THE INTERNATIONAL BRONCHOESOPHAGOLOGICAL SOCIETY
www.wcbipwcbe2016.org
Fortezza da Basso
May 8-11, 2016
Florence (Italy)

Role of bronchoscopy in management of pulmonary complications in hematologic malignancies

Raffaella Felletti[1], Mercedes Pasquali[1], Alessandro Blanco[1], Emanuela Barisione[1], Malgorzata Mikulska[2], Anna Maria Raiola[3], Mario Salio[4]

[1]UOC Pneumologia, IRCCS AOU San Martino IST - Italy
[2]UO Clinica Malattia Infettiva, IRCCS AUO San Martino IST - Italy
[3]UOC Ematologia, IRCCS AUO San Martino IST - Italy
[4]UOC Pneumologia, IRCCS AUO San Martino IST - Italy

Introduction

Haematological patients, owing to the nature of disease and the frequent immunosuppression due to chemotherapy or different rescue of blood cell reconstitution, remain at risk of infectious or noninfectious pulmonary complications. Pulmonary infections are a major cause of morbidity and mortality in these patients and more likely occur during specific time periods following transplantation, reflecting the evolution of immune reconstitution. Otherwise noninfectious pulmonary complications may be early or late and equally affect the prognosis in patients especially after Bone Marrow Transplantation (BMT) or Hematopoietic Stem Cell Transplantation (HSCT). We know that about 40% to 60% of HSCT patients will be affected by pulmonary complications with a mortality rate of 30% (1)

Objective

Diagnosis of pulmonary complications, infectious or not , are essential in order to address management and treatment of this kind of patients nevertheless guidelines are not available .Despite lot of publications and reports have been published no systemic indication about kind and timing of diagnostic interventional pulmonary procedures is currently transported in clinical practice and until now choice of procedure depends on clinical suspicion and preference of chest physician operator: Guidelines to promote consistency in the approach the evaluation of lung infiltrates may improve clinical care of patients (2)

Methods

We present our experience in diagnostic approach to pulmonary complication in hematological patients, mainly transplanted patients (stem cells, bone marrow autologous or heterologous, cord blood) : from 2009 to 2014 we performed clinical evaluation and interventional procedures for pulmonary complications in 237 consecutive patients : the cohort described is an heterogeneous group including patients with different underlying diseases and conditioning regimes. Bronchoalveolar lavage (BAL) was the first diagnostic interventional chosen in order to distinguish infectious or noninfectious disease(NI)

Results

In 67% BAL was diagnostic for infectious disease (fig 1), 6 % for pathology (mainly lymphoma) and 27% for noninfectious disease. BAL and HRTC (High Resolution Computed Tomography) were diagnostic in few cases of DAH(diffuse alveolar hemorrhage), Radiation Pneumonia and Idiopathic Pneumonia but for the majority of cases the diagnosis in NI was consistent with GHVD

Conclusions

The correct microbiologic diagnosis allow the administration of appropriate therapy, discontinue inappropriate therapy and modifying timing and intensity of treatment. Although BAL is considered the first diagnostic procedure lung biopsy even with transbronchial cryobiopsy should be considered : future studies should be performed in order to establish safety and timing of more aggressive approach

Bibliography

1.Wahla A. et al. J Bronchol Intervent Pulmonol 2014;vol 21,1 Jan 2.Chellapandian DB et al. Journal of Clinical Oncology 2015; vol 33,5

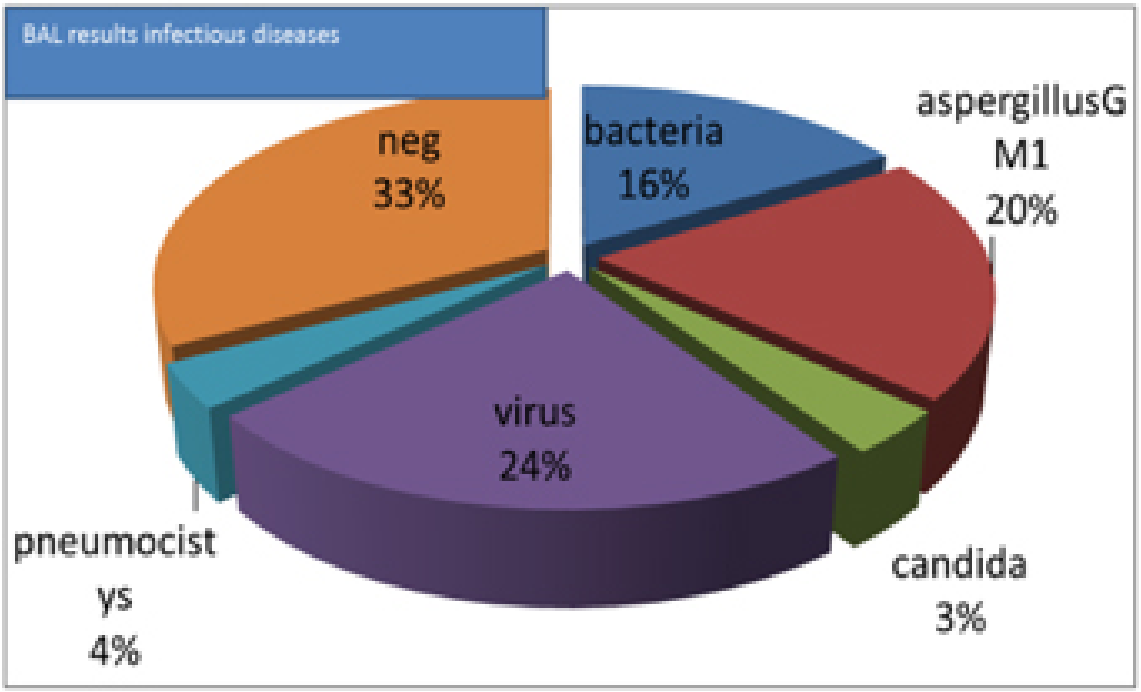
BAL results infectious diseases
bacteria
16%
aspergillusG
M1
20%
candida
3%
virus
24%
pneumocist
ys
4%
neg
33%

id 367

Clinical Experience of Rigid Bronchoscopy in Single Center

Jongmin Lee, Jick Hwan Ha, Hyeon Hui Kang, Chang Dong Yeo, Sung Kyoung Kim, Chan Kwon Park, Seung Joon Kim, Sang Haak Lee

Division of Pulmonary, Critical Care and Sleep Medicine, Department of Internal Medicine, The Catholic University of Korea, College of Medicine - Republic Of Korea

Introduction

Bronchoscopic intervention can provide immediate relief from suffocation and an opportunity for additional treatment in patients with airway obstruction.

Objective

The aim of this study was to analyze clinical situations requiring rigid bronchoscopy and evaluate usefulness of rigid bronchoscopic intervention in benign or malignant airway disorders.

Methods

We retrospectively reviewed 85 patients who underwent rigid bronchoscopy from November 2007 to July 2015 at St. Paul's Hospital, The Catholic University of Korea School of Medicine.

Results

Of the 85 patients, the most frequent underlying etiology was benign stenosis of trachea (n=64). Of those 64 patients, 35 had post-intubation tracheal stenosis (PITS), 14 had endobronchial stenosis due to tuberculosis and 5 had benign mass. Other etiologies were tracheal stenosis due to inhalation burn (IBTS, n=1), obstructive fibrinous tracheal pseudomembrane (OFTP, n=3), foreign body (n=3), tracheo-esophageal fistula (n=1). Patients with malignant obstruction were 21. 10 patients of 21 had non-small cell lung cancer, which was the most frequent cause of obstruction. Other causes were adenoid cystic carcinoma (n=2), papilloma with squamous cell carcinoma (n=2), esophageal cancer with direct invasion (n=1), malignant lymphoma (n=2), sarcoma (n=1), thyroid cancer (n=1), malignancy of unknown origin (n=2). For treatment, silicone stent insertion was done in 42 cases. Electrocauterization (52.6%), mechanical dilatation (37.8%), balloon dilatation (27.7%), topical application of mitomycin (3.9%) were done with silicone stent insertion. Pulmonary function was significantly improved and complications were tolerable. Granulation tissue formation was the most common complication (34%).

Conclusions

Rigid bronchoscopy is a useful option in the management of benign and malignant central airway obstruction associated with non-life threatening stent-related complications that were easily managed.

id 368

19th WCBIP / WCBE World Congress
JOINT MEETING OF THE WORLD ASSOCIATION FOR BRONCHOLOGY AND INTERVENTIONAL PULMONOLOGY & THE INTERNATIONAL BRONCHOESOPHAGOLOGICAL SOCIETY
www.wcbipwcbe2016.org
Fortezza da Basso
May 8-11, 2016
Florence (Italy)

The Role of Lung Transplantation for Excessive Dynamic Collapse in COPD

Carli J. Lehr, M.d., Atul C. Mehta, M.b.b.s, F.a.c.p., F.c.c.p.

Respiratory Institute, Cleveland Clinic - United States

Introduction

The presence of excessive dynamic collapse (EDC) in patients with chronic obstructive pulmonary disease (COPD) is often encountered in the pre-lung transplant population. The incidence of EDC in COPD patients who undergo transplant is unknown and its impact on outcomes following sequential bilateral lung transplantation remains understudied. The preservation of the recipients dysfunctional central airways after transplant makes this an important topic to address. Current treatment options for EDC are often unsuccessful and we propose that lung transplant may provide a therapeutic option for patients who fail conventional therapy.

Objective

It is our aim to identify the incidence of EDC in patients undergoing transplantation for COPD. We hypothesize that transplant will improve expiratory collapse of the central airways despite the persistence of loss of integrity of the pars membranacea of the central airways by replacing dysfunctional peripheral airways with healthy allografts.

Methods

EDC is defined as narrowing of the airway lumen by more than 50% on expiratory computed tomography (CT) of the chest or flexible bronchoscopy. All patients who underwent bilateral lung transplant for COPD from December 1, 2011 to December 31, 2014 will be included in the analysis. Demographic data including patient age, comorbidities, lung allocation score (LAS), and waitlist time will be collected for each patient. Pre- and post-transplant pulmonary function data including flow volume loop, CT scans, and bronchoscopy results will be obtained. Descriptive statistics will be performed and one year survival data will be evaluated in the analysis

Results

Sixteen patients underwent bilateral lung transplant for COPD between December 1, 2011 to December 31, 2014. One patient expired within one year of transplant. Complete normalization of the flow volume loop occurred in two patients despite loss of integrity of the pars membranacea.

Conclusions

Based on early analysis, patients with EDC before transplant experience normalization of flow volume loops, symptomatic improvement, and may no longer require the previously required nocturnal positive pressure ventilation. Further evaluation of these patients will provide valuable clinical data to guide clinical decision making surrounding the utility of lung transplantation to overcome central airway dysfunction in EDC.

id 369

Comparison of Medazolam, Fentanyl, Combined sedation and Propofol for transnasal Bronchsocohoscopy

Varunkumar Patel, Milan Bhanderi, Mukesh Patel, Amrish Patel

Intervention Pulmonary Medicine, Chest Disease Clinic, Sparsh Hospital - India

Introduction

Since the introduction of fiberoptic bronchoscope by Ikeda in 1968, fiberoptic bronchoscopy is one of the most commonly performed procedures by chest physicians. Variety of diagnostic and therapeutic interventions can be performed under direct visualization of airway. Proper procedural sedation is an important aspect of the procedure to increase patient comfort and tolerance and to also for ease of performance by the bronchoscopist. However, there are no standards set for use of pharmacological sedatives & anxiolytics, and some physicians even prefer to perform the procedure without any premedication. In this study we have compared the use of Midazolam, Fentanyl, combined Midazolam – Fentanyl and Propofol sedation in respect to oxygen desaturation, hemodynamic changes, Physician satisfaction, patient tolerance and feasibility of procedure.

Objective

To compare the midazolam, fantanyl, combined fantanyl- midazolam & propofol sedation for diagnostic bronchoscopy with respect to 1) oxygen desaturation, 2) hemodynamic changes, 3) Physician satisfaction & 4) patient tolerance.

Methods

120 consecutive patients undergoing diagnostic bronchoscopy at Sparsh Chest Disease center were enrolled in the study. After initial evaluation and consents: patients were randomized to receive Midazolam, Fentanyl, combined Fentanyl – Midazolam sedation or Propofol administered just prior to the procedure. All patients also receives local anesthesia as per standard protocol. Patients were continuously monitored for blood pressure, oxygen saturation by infrared pulse oxymetry and heart rate.

Results

The ends points selected for the study was oxygen desaturation, rise in systolic blood pressure and tachycardia. Physician reported feasibility was highest for combined sedation group. Physician's level of satisfactions scores were best for combined sedation group. Lower cough scores were associated with better physician satisfaction scores. Patient reported tolerance of bronchoscope insertion was best for Propofol group and overall procedure satisfaction scores were best for combined sedation group.

Conclusions

In present study, sedation using Propofol had better hemodynamic outcomes in terms of rise in systolic blood pressure and tachycardia. However, mean oxygen desaturation did not differ significantly across study groups. Combined Midazolam and Fentanyl sedation offers better physician satisfaction and cough scores probably because of its antitussive properties. Complications like bleeding appear to be associated with disease process rather than sedatives used. Cough is the most troublesome manifestation for the bronchoscopist as it interferes with biopsies and needle aspirations. Lower cough scores were associated with better physician satisfaction scores. Patients in Propofol group exhibited better tolerance of bronchoscope insertion and overall procedure satisfaction scores were best for combined sedation group.

Bibliography

1) American Society of Anaesthesiologists physical status classification; Indian J Anaesth.2011 Mar-Apr;55(2:111–115. 2) Horn E, Nesbit SA. Pharmacology and pharmacokinetics of sedatives and analgesics. Gastrointestinal Clinics of North America 2004;14(2):247-268.

	Sedative regime	Mean Lowest Oxygen Saturation	Mean value of maximum heart rate during the procedure	Mean value of maximum heart rate 1 hr after the procedure	Mean value of maximum systolic blood pressure during procedure	Mean value of maximum systolic blood pressure 1hr after the procedure	Cough Score	Overall satisfaction Score
1	Midazolam	89.6	141.3	89.3	151.8	121.3	4.32	3.76
2	Fentanyl	90.5	146.5	90.2	157.3	121.7	3.21	4.98
3	Combined	90.9	145.7	90.6	148.3	120.4	2.96	6.69
4	Propofol	89.1	135.6	89.4	145.7	119.9	5.67	5.71

id 370

19th WCBIP / WCBE World Congress
JOINT MEETING OF THE WORLD ASSOCIATION FOR BRONCHOLOGY AND INTERVENTIONAL PULMONOLOGY & THE INTERNATIONAL BRONCHOESOPHAGOLOGICAL SOCIETY
www.wcbipwcbe2016.org
Fortezza da Basso
May 8-11, 2016
Florence (Italy)

Lung cancer: differences between men and women

Hugo Esteva[1], Alejandro Newton[2], Tomas Nuñez[2], Tamara Portas[2], Juan Antonio Mazzei[2], Mariano Mazzei[2]

[1]Hospital de Clinicas (Head of Thoracic Surgery Division - retired), Universidad de Buenos Aires - Argentina
[2]Hospital de Clinicas, Universidad de Buenos Aires - Argentina

Introduction
Frequency of lung cancer has been progressively increasing among women since the last years of the XXth Century.

Objective
To show our experience suggesting differences between men and women in several aspects of this illness.

Methods
Retrospective analysis of public (Hospital de Clínicas, Universidad de Buenos Aires) and private patients (from two of the authors, HE & TN, in the same city) between 1981 and 2010 previously discussed et the Academia Argentina de Cirugía but never published , adding the experience of a group of purely private patients (high social and cultural level) consulting to one of us (HE). The numbers are not as high to always arrive to statistically significant results, but can suggest interesting lines for further investigation.

Results
Social and cultural differences can lead to different results in late survival among patients. Male and female private patients show differences in pathologic type, stage at diagnosis, smoking habits, bronchoscopic aspects, resectability and type of operation.

Conclusions
Lung cancer have several different aspects between women and men. Diagnostic and therapeutic strategies should be adapted to these differences.

Bibliography
Esteva H, Newton AT, Núñez T, Portas T. El cancer del pulmón en la mujer. Presentación en la Academia Argentina de Cirugía (no publicada) el 27/VII/2011

19th WCBIP / WCBE World Congress
JOINT MEETING OF THE WORLD ASSOCIATION FOR BRONCHOLOGY AND INTERVENTIONAL PULMONOLOGY & THE INTERNATIONAL BRONCHOESOPHAGOLOGICAL SOCIETY
www.wcbipwcbe2016.org
Fortezza da Basso
May 8-11, 2016
Florence (Italy)

The expression of TGF-?, VEGF, ?-SMA in the tissue of cicatricial central airway stenosis

Kunyao Yu, Nan Li, Hong Zhang, Wei Zhang, Guangfa Wang

Dept of reapiratory and critical care medicine, Peking University First Hospital - China

Introduction

Cicatricial central airway stenosis is caused by a variety of reason, such as tuberculosis, intubation, injury and so on. Cicatricaial stenosis has a high recurrent rate. Most of the patients need multiple treatment. Nevertheless, there is no concensus or accepted guideline for its treatment. Therefore it remaines a great challenge to the interventional pulmonologist. The granulation tissue proliferation and cictricial stricture are the key machinism of its recurrency. Cytokines or growth factors may involve in its pathogenesis.

Objective

To analyze the expression of TGF-?1, VEGF, ?-SMA in the tissue extracted from cicatricial central airway stenosis.

Methods

Patients who had accepted endoscopic interventional treatment for cicatricial central airway stenosis in our hospital and had reserved specimen from the stenostic site was recruited.Immunohistochemical analysis was used to detect the expression of TGF-?1, VEGF and ?-SMA. Wax blocks are used to isolate RNA and detect the level of TGFB1, VEGFA, ACTA2 by Real-time RT-PCR. Normal tracheobronchial tissues, obtained from patients who had accept surgical resection, were used as a control.

Results

33 patients were enrolled with 52 times of endoscopic intervention. There were 8 cases in the control group. There was a significantly increased expression of TGF-?1, VEGF and ?-SMA in stenosis group. Real-time RT-PCR shows that the expression of TGFB1, VEGFA and ACTA2 are significantly higher in stenosis group.The cases of stenosis group were divided into three subgroup: granulation proliferation type, cicatricial contration type and mix type according to the endoscopic observation. There was no significant difference on the expression of TGF-?1, VEGF and ?-SMA among the subgroups. However, there is a trend of higher expression of ?-SMA in cicatricial contration group. Correlation analysis showed statistically significantly positive correlation between TGF-?1 and VEGF(RR=0.35). The level of VEGF is higher in 2-8 weeks after cryotherapy.

Conclusions

Cicatricial central airway stenosis may be related to the up regulated expressions of TGF-?1, VEGF and ?-SMA. These growth factors may be as a target for the treatment of cicatricial central airway stenosis. Further studys are needed in the future to clarify the molecule mechanism and develop potential drugs.

id 372

19th WCBIP / WCBE World Congress
JOINT MEETING OF THE WORLD ASSOCIATION FOR BRONCHOLOGY AND INTERVENTIONAL PULMONOLOGY & THE INTERNATIONAL BRONCHOESOPHAGOLOGICAL SOCIETY
www.wcbipwcbe2016.org
Fortezza da Basso
May 8-11, 2016
Florence (Italy)

Role of bronchoscopy in sputum smear negative pulmonary tuberculosis

Varunkumar Patel, Gaurav Phale, Mukesh Patel, Gopal Raval, Tushar Patel

Intervention pulmonology, Chest Disease Center, Sparsh Hospital - India

Introduction

Diagnosis of sputum/smear-negative pulmonary tuberculosis patients can be both challenging and time consuming with many patients being put on empirical anti- tubercular treatment. About 31% of the new cases may be smear-negative for AFB. Difficulties arise when a patient who is suspected of active tuberculosis, both clinically and radiologically, does not produce sputum or when it is available AFB may be negative. Flexible bronchoscopy offers a mean of investigation whereby bronchial secretion and washing can be collected from the most likely abnormal site under direct vision.

Objective

1) To study the role of bronchoscopy in suspected sputum smear negative pulmonary tuberculosis. 2) For early diagnosis of pulmonary TB and to start effective treatment as early as possible. 3) For early alternative diagnosis in which clinical & radiological picture look like TB.

Methods

100 patients aged above 14 years old who were suspected of having pulmonary tuberculosis based on clinical and radiological appearances were prospectively studied. All subjects had sputum smear examination which were negative for acid fast bacilli or He/She was unable to produce sputum for examination. The bronchoscopy was performed and a thorough examination of bronchial tree was carried out and bronchoalveolar lavage (BAL) and/or Transbronchial lung biopsy (TBLB) and/or Transbronchial needle aspiration(TBNA) were collected. The specimens obtained were placed on slides for Ziehl-Nielsen stain, for GeneXpert and for AFB culture by MGIT. Biopsy was performed from diseased segments of lung bronchoscopically for Histopathological examination and / or Gene x-pert and AFB culture.

Results

In total 100 sputum smear negative suspected pulmonary tuberculosis cases, at Sparsh Hospital, Ahmedabad, early diagnosis of pulmonary tuberculosis was established in 44 cases and in 2 cases diagnosis of malignancy was established, While 5 cases of Sarcoidosis, 4 cases of organizing pneumonia and 7 cases of Bacterial pneumonia other than TB was made. 38 patients remain undiagnosed.

Conclusions

Flexible bronchoscopy is a useful procedure to establish the diagnosis of pulmonary tuberculosis when sputum smear examination does not show acid fast bacilli. This allows appropriate treatment to be started with confidence in those patients whom the diagnosis have been confirmed by either smear, culture, CB-NAAT or by histological examination. For patient treatment decision depends on the clinical consideration and Pts usually wrongly treated for tuberculosis while having some other disease which can miss without bronchoscopy such as Malignancy, Sarcoidosis, Pneumonia which required different treatment.This helps to redirect the course of the disease when diagnosed at an early stage.

Bibliography

Bachh, et al.: Fibre-optic bronchoscopy in diagnosis of smear negative pulmonary tuberculosis; Lung India , Vol 27, Issue 2, Apr - Jun 2010.

Lung deflation and perfusion after ELVR with valves in pigs using electrical impedance tomography

Vinicius Torsani[1], Paulo F. G. Cardoso[2], Cristopher K. Nagao[2], Andrea F. Cruz[3], José P. Otoch[4], Carlos R.r. Carvalho[5], Paulo M. Pêgo-fernandes[2], Marcelo B.p. Amato[5]

[1]Division of Pneumology, Faculty of Medicine of the University of Sao Paulo - Brazil
[2]Division of Thoracic Surgery, Heart Institute (InCor) - Hospital das Clinicas, Faculty of Medicine of the University of São Paulo - Brazil
[3]Biomedical Engineering Laboratory, Polytechnical School, University of São Paulo - Brazil
[4]Discipline of Operative Technique and Experimental Surgery, Faculty of Medicine of the University of Sao Paulo - Brazil
[5]Division of Pneumology, Heart Institute (InCor) - Hospital das Clinicas, Faculty of Medicine of the University of São Paulo - Brazil

Introduction

Electrical impedance tomography (EIT) is a noninvasive, radiation-free monitoring method that allows real-time measurement of ventilation and perfusion at the bedside. We have demonstrated previously in a pig model of poor collateral ventilation that EIT can show redistribution of ventilation and perfusion across the lungs after endoscopic lung volume reduction with one-way valves (ELVR), however it was not confirmed by other imaging method.

Objective

This study focused on the EIT and CT findings after endoscopic lobar deflation using with baloon occlusion and one-way valves in pigs.

Methods

Six Landrace pigs were anesthetized, placed on pressure-controlled ventilation via tracheostomy. The EIT electrode belt was positioned around the chest and connected to the EIT machine (DX1800, Dixtal Biomedica, Brasil). Two protocols were performed sequentially in each animal at two different FiO2 (0,5 and 1,0) in a randomized fashion. The first protocol assessed the collateral ventilation using a baloon occlusion catheter (Chartis™, Pulmonx, USA) connected to a pressure sensor and viewed in a LabView environment. The catheter was placed via flexible bronchoscopy in the LLL bronchus during 15 minutes. In the second protocol, the LLL was occluded by one-way valves (EBV Zephyr™, Pulmonx, USA). Hemodynamics, gas exchange and lung mechanics were measured along with EIT readings at 15 minute intervals during 45 minutes. Perfusion was assessed by EIT using hypertonic saline (NaCl 20%; 6mL IV). Lung deflation was assessed by CT scan in two pigs in a similar protocol using a 15-minute lobar occlusion.

Results

: There was no collateral ventilation in the LLL of all animals. EIT detected the decrease of aeration in left lower lung field during both protocols. It was greater and faster during baloon occlusion and under high FiO2. There was a faster decrease in perfusion on the left side at both FiO2 regimens. Lung deflation occurred faster under FiO21.0 during both baloon occlusion and after valve placement. PaO2 reduced while PaCO2 and shunt fraction increased. CT scans in two animals confirmed the EIT findings in both protocols (figure).

Conclusions

In this animal model of low collateral ventilation, EIT detected lung deflation in both protocols. Higher FiO2 concentration was related to a faster decline in left lung volumes. CT scan confirmed lung deflation in both protocols.

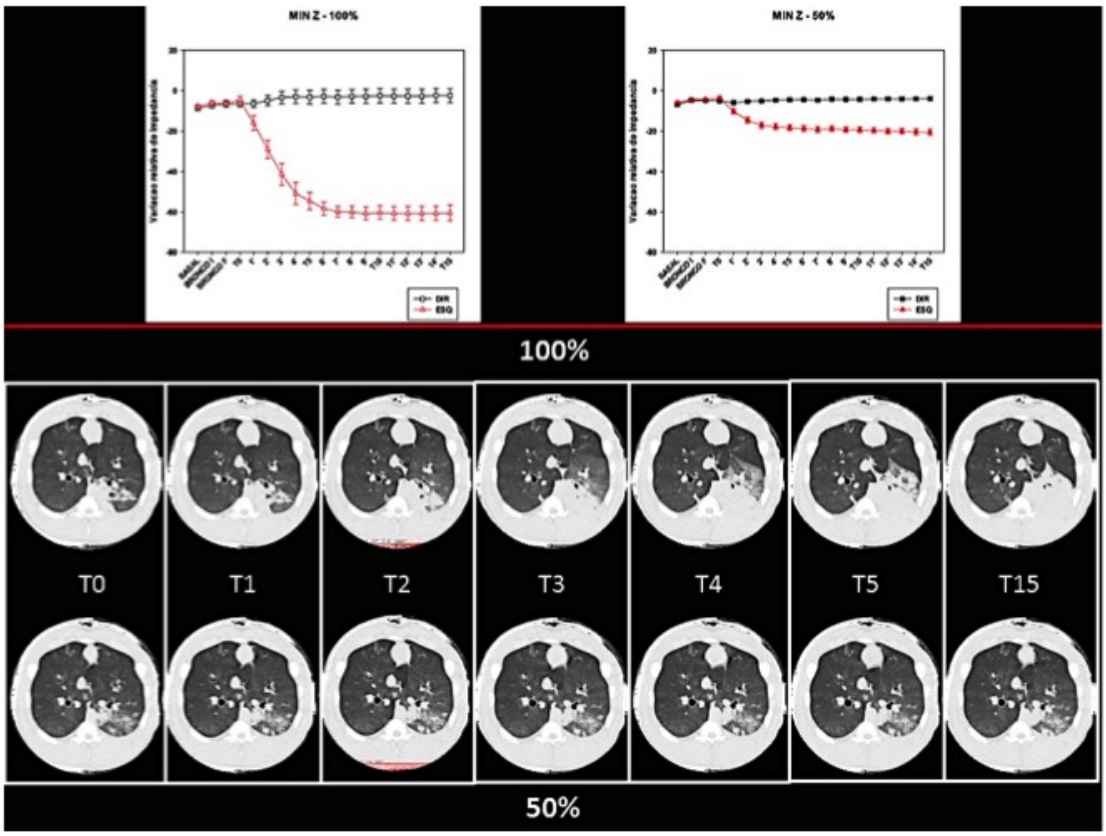

The presenting author has the following conflicts of interest that relate to this abstract: *Disclosure of funding source (Paulo F.G.Cardoso): FAPESP (Fundação de Amparo a Pesquisa do Estado de Sao Paulo; 2012/05009-3).*

id 374

19th WCBIP / WCBE World Congress
JOINT MEETING OF THE WORLD ASSOCIATION FOR BRONCHOLOGY AND INTERVENTIONAL PULMONOLOGY & THE INTERNATIONAL BRONCHOESOPHAGOLOGICAL SOCIETY
www.wcbipwcbe2016.org
Fortezza da Basso
May 8-11, 2016
Florence (Italy)

Acute Respiratory failure secondary to histoplasmosis in case of Acute Leukemic Leukemia

Varunkumar Patel, Suraj Verma, Bharat K, Harjit Dumra

Intervention Demonology, Chest Disease Center, Sparsh Hospital - India

Introduction

Histoplasmosis is a granulomatous fungal disease caused by Histoplasma capsulatum , which is found in soil rich with excreta of bats and birds. This disease has variable clinical features. Pulmonary presentations commonly include acute pneumonia with lung consolidation, chronic cavitary pulmonary histoplasmosis, and pleural effusion. Complications from pulmonary histoplasmosis can include pericarditis, arthritis, erythema nodosum, mediastinal fibrosis, mediastinal lymphadenitis, mediastinal granuloma, and pulmonary nodules. Acute pulmonary histoplasmosis is generally a benign disease. Rarely it can cause fulminating life-threatening illness. The following presentation recounts a case of histoplasmosis with acute respiratory failure.

Objective

Sensitizing pulmonologist to thick about non epidemic invective etiology with background of travel history in case of respiratory failure without obvious etiology

Methods

A 36y-old male case of ALL on oral anti cancer drugs was admitted, with chief complaints of high grade fever, cough with expectoration, breathlessness and skin eruptions on face since 7 days. Pt consulted Dermatologist and diagnosed as chicken pox. For cough and breathlessness chest x-ray done showed infiltration in B/L lower zone (LT > RT)? Leukemic infiltrates; oncologist opinion taken, advised admission Anemia with normal leucocytosis in periphral semar and bone marrow biopsy shows 6% blast cells. Pt started on antibiotics and nasal O2 with supportive treatment. Repeat CXR on 12/9 suggestive of mild regressions compared to previous one, repeat smear shows leucocytosi.Liver function mild derance with hyperbilirubinemia. CT SCAN THORAX showed multiple variable sized nodular alveolar lesions, bilateral lung parenchyma in basal segments with minimal pleural effusion represent leukemic infiltrates rather than viral infective pneumonitis. For continues respiratory distress pulmonologist opinion taken pt shifted in ICU and started on NIV support.Negative blood culture and negative CMV load sputum shows few GPCs. Bronchoscopy was done in ICU with continues NIV support, BAL and TBLB taken and sent for evaluation. Pt continued on NIV in ICU BAL genexpert negative. After 3 days on histopathological examination of TBLB shows alveolar tissue with mixed inflammatory cell infiltrate composed of lymphoplasmacytic cells, histiocytes with many intracellular thin walled yeast forms surrounded by unstained capsule, s/o HISTOPLASMOSIS.

Results

Histoplasmosis is not a endemic in INDIA, Once travel to endemic area person can harbor spore of fungus and can stay in hibernate status and reactivate when host's immunity status comes down.

Conclusions

Travel history is important when dealing with bilateral parenchymal shadows with respiratory failure in immuno-compromised status, definitely give clue for the diagnosis and correct line of treatment started.

Bibliography

Diagnosis of acute pulmonary histoplasmosis by antigen detection. Swartzentruber S1, Rhodes L, Kurkjian K et al. Clin Infect Dis. 2009 Dec 15;49(12):1878-82. doi: 10.1086/648421.

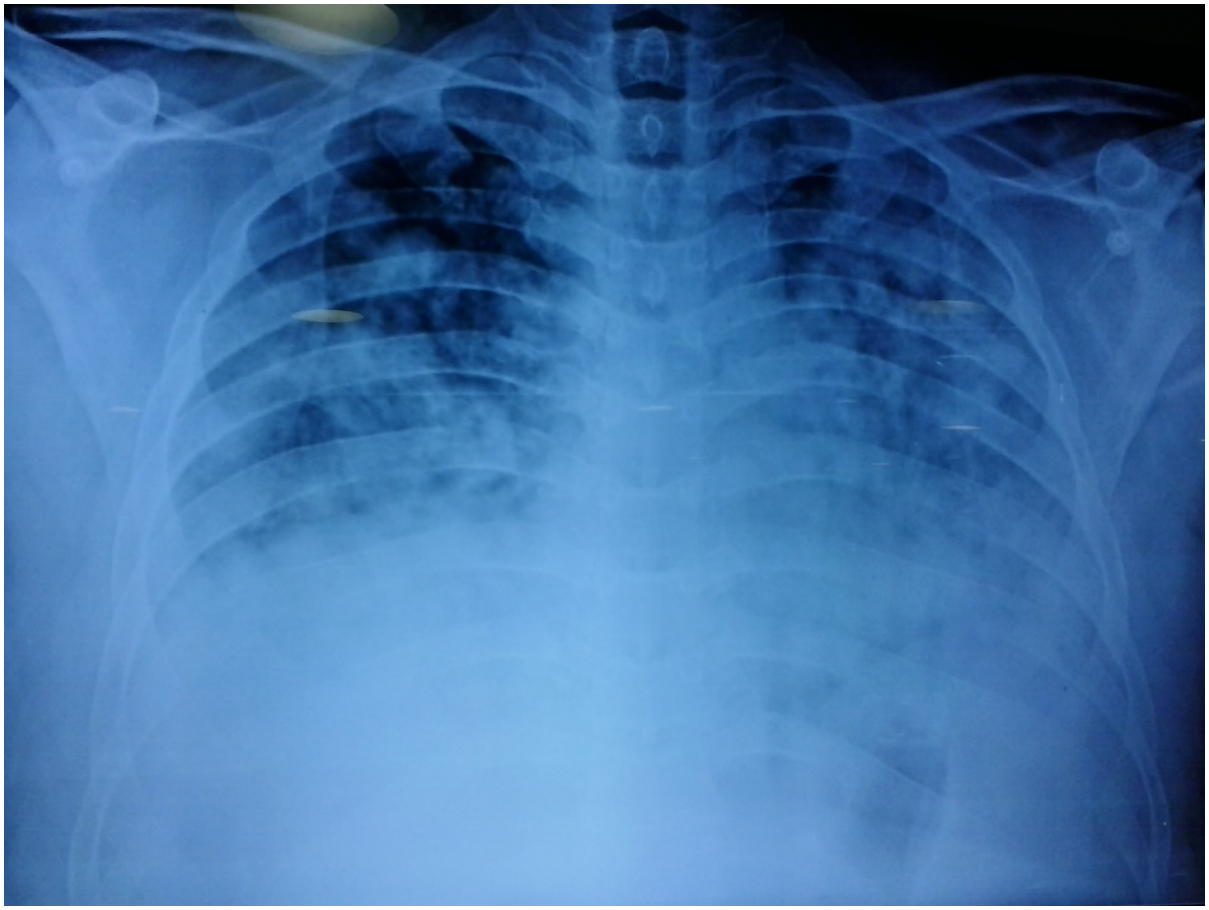

id 375

Biofilm of Montgomery T-tube for benign tracheal stenosis: preliminary results and new insights

Daniel F. Lima Neto[1], Paulo F. G. Cardoso[2], Oswaldo Gomes Junior[2], João P.c. Macêdo[2], Helio Minamoto[2], Jose P. Otoch[3], Paulo M. Pêgo-fernandes[2], Paolo M.a. Zanotto[1]

[1]Laboratory of Molecular Evolution and Bioinformatics-ICB2, University of São Paulo - Brazil
[2]Division of Thoracic Surgery, Heart Institute (InCor) - Hospital das Clinicas, Faculty of Medicine of the University of São Paulo - Brazil
[3]Discipline of Surgical Technique and Experimental Surgery, Faculty of Medicine of the University of São Paulo - Brazil

Introduction

The Montgomery T-tube (MTT) is used to maintain airway patency in patients with tracheal stenosis. Biofilm formation inside and outside the T-tube surface can potentially perpetuate the bacterial, viral and fungal colonization. Polimicrobial population of the biofilm may change according to local factors such as pH, humidity and temperature causing damage to the surrounding tracheal tissue and adversely affecting the airway healing process.

Objective

To evaluate the microbial contents of MTT obtained from patients with benign tracheal stenosis in order to propose new silicone coating strategies.

Methods

Cross-sectional study including patients with benign tracheal stenosis submitted to prolonged stenting with a MTT. The MTT change was carried out in the operating room with the patient under general anesthetic or deep sedation, using flexible bronchoscopy or suspension laryngoscopy to guide the procedure. During the MTT change, culture samples collected from the distal 2 centimeters of the T-tubes removed from the patients. Cultures were processed for aerobes, anaerobes and fungi. Results were compared to trachea RNASeq public database. Sequences were downloaded from the NCBI GenBank, trimming and quality filtering were done with trim_galore for paralelization and assembly was made with Velvet. Scaffolds were the evaluted with a ribosome database (RDP project) and then compared with a pre-compiled database of complete genomes of viruses. The outputs were converted with Krona Tools for html visualization.

Results

23 patients (12 males; mean age 37,3 years) with post-intubation stenosis were included. Mean MTT use was 12months. Cultures revealed a predominance of pseudomonas aeruginosa followed by polymicrobial growth and proteus mirabilis. Comparison with a metagenomic data base revealed correlations with our experimental results. Pseudomonadales family accounted for 0.3% of the hits within the RDP database, 0.5% of Enterobacteriacea but no hits were found for Proteus mirabilia nor Serratia marcescens. The most representative viruses found are depicted in the Figure along with the bacteria and fungi. Numerous hits were associated with the Caudovirales family and Endogenous retroviruses as well. Figure summarizes these results.

Conclusions

Biofilm of MTT are populated by multiple organisms. Ordinary cultures probably underestimate the number of bacteria that can be found within a given sample and conventional methods are time-consuming and restrictive to some viral families alone, therefore it does not take into account the viral populations that colonize such a region. Using Metagenomics may be an alternative to clarify other microbial populations able to impact on airway stenosis healing process.


root
Viruses
dsDNA viruses, no RNA stage
Herpesvirales
Herpesviridae
Alphaherpesvirinae
Gammaherpesvirinae
Rhadinovirus
Cyprinivirus
Betabaculovirus
Caudovirales
unclassified Myoviridae
unclassified Mimiviridae
Chordopoxvirinae
unclassified dsDNA viruses
Alpharetrovirus
Orthoretrovirinae
Retroviridae
Gammaretrovirus
unclassified Gammaretrovirus
Lactococcus
Phthorimaea operculella granulov
Plutella xylostella granulovirus
Choristoneura occidentalis granul
Bacillus phage CampHawk
Pseudomonas phage PaBG
Erwinia phage phiEaH2
Cyprinid herpesvirus 1
Cyprinid herpesvirus 3
Falconid herpesvirus 1
Papiine herpesvirus 2
Suid herpesvirus 1
Equid herpesvirus 2
Bovine herpesvirus 4
Saimiriine herpesvirus 2
Megavirus lba
Megavirus terra1
White spot syndrome virus
Phaeocystis globosa virus
Goatpox virus
Orthopoxvirus
Thermus phage P23-77
Micromonas pusilla virus 12T
Pandoravirus salinus
Fujinami sarcoma virus
Avian myelocytomatosis virus
Woolly monkey sarcoma virus
Abelson murine leukemia virus
Baboon endogenous virus
Human endogenous retrovirus K
Enterobacteria phage phiX174 ser
Festivirus
Streptococcus phage 20617
No hits

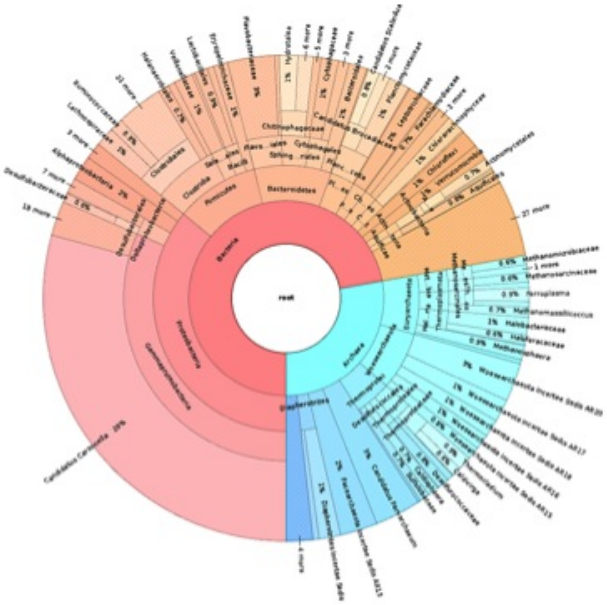
root
Bacteria
Proteobacteria
Gammaproteobacteria
Candidatus Carsonella 38%
Firmicutes
Bacteroidetes
Clostridia
Bacilli
Chitinophagaceae
Cytophagales
Sphing...
Candidatus Brocadiaceae
Clostridiales
Paenibacillaceae 2%
Erysipelotrichaceae 2%
Lactobacillaceae 0.9%
Veillonellaceae 1%
Alphaproteobacteria 2%
Desulfobacteraceae 0.9%
Deltaproteobacteria
Actinobacteria
Chloroflexi
Aquificales
Actinomycetales
27 more
18 more
7 more
9 more
31 more
Archaea
Euryarchaeota
Thaumarchaeota
unclassified
Methanomicrobiaceae
Methanosarcinaceae
Ferroplasma
Methanomassiliicoccus
Halobacteriaceae
Haloferacaceae
Methanosphaera
Woesearchaeota Incertae Sedis AR20
Woesearchaeota Incertae Sedis AR17
Woesearchaeota Incertae Sedis AR18
Woesearchaeota Incertae Sedis AR16
Woesearchaeota Incertae Sedis AR13
Candidatus Nitrosopumilus
Pacearchaeota Incertae Sedis AR13
Diapherotrites Incertae Sedis
4 more

id 376

19th WCBIP / WCBE World Congress
JOINT MEETING OF THE WORLD ASSOCIATION FOR BRONCHOLOGY AND INTERVENTIONAL PULMONOLOGY & THE INTERNATIONAL BRONCHOESOPHAGOLOGICAL SOCIETY
www.wcbipwcbe2016.org
Fortezza da Basso
May 8-11, 2016
Florence (Italy)

Laparoscopic fundoplication in tracheal stenosis patients with gastro-esophageal acid reflux

Edno T. Bianchi[1], Paulo F. G. Cardoso[2], Helio Minamoto[2], Sergio Szacnowicz[1], Francisco Seguro[1], Julio M. Rocha[1], Rubens Sallum[1], Ary Nasi[3], Angela M. Falcão[3], Ivan Cecconello[1], Paulo M. Pêgo-fernandes[2]

[1]Department of Gastroenterology, Discipline of Surgery of the Digestive Tract, Hospital das Clinicas, Faculty of Medicine of the University of Sao Paulo - Brazil
[2]Division of Thoracic Surgery, Heart Institute (InCor) - Hospital das Clinicas, Faculty of Medicine of the University of São Paulo - Brazil
[3]Discipline of Surgery of the Digestive Tract, Esophageal Function Laboratory, Hospital das Clinicas, Faculty of Medicine of the University of Sao Paulo - Brazil

Introduction
We demonstrated that patients with benign airway stenosis have a high prevalence of pathologic gastroesophageal acid reflux (GER) with supine and upper esophageal acid exposure that can occur in the absence of typical reflux symptoms. Surgical treatment of GER in this setting can potentially improve the management of airway stenosis.

Objective
To evaluate the impact of anti-reflux surgery in the outcome of patients with benign tracheal stenosis and pathologic GER detected by esophageal pH study.

Methods
Retrospective analysis of patients with benign tracheal stenosis and GER submitted to esophageal manometry with a perfused catheter and a dual probe 24-hour pH study, regardless of the presence of typical GER symptoms. Inclusion criteria were the presence of subglottic, or recurrent tracheal stenosis and an abnormal esophageal 24-hour pH study. Patients with previous gastrectomy or esophagectomy were excluded. Patients were submitted to a laparoscopic Nissen fundoplication. The outcome was considered satisfactory when airway stenosis was successfully managed either by resection, no need for further dilatation or use of a tracheal appliance. Results were compared with patients with GER and tracheal stenosis that underwent conservative treatment with proton pump inhibitors (omeprazol 40mg, BID) and anti-reflux measures.

Results
Twenty-two patients (15 males; 33,8±13years; BMI 23,8±2; typical GER symptoms 14 patients) underwent laparoscopic Nissen fundoplication and 42 were treated conservatively (29 males; 46±15years; BMI 27,8±4; typical GER symptoms 18 patients). In the laparoscopic group, 16 patients were followed for more than 1 year after the fundoplication (median follow up=20 months). There were no peri-operative or late complications related to the fundoplication. As far as the outcome was concerned, of the 16 patients submitted to fundoplication, 15 (94%) had a satisfactory outcome (11 were deccanulated and 4 were submitted to successful tracheal resection with good airway patency). One (6%) patient submitted to tracheal resection had an unsatisfactory outcome because airway patency still requires stenting. The conservative treatment group (n=42), only 11 (26%) were deccanulated and 31 (74%) had an unsatisfactory outcome and still require dilatation and tracheal appliances to ensure airway patency. The relative risk for unsatisfactory outcome in the conservative treatment group was 11.8 (CI (6.51-17.09) if compared to the fundoplication group.

Conclusions
Laparoscopic Nissen fundoplication was safe and effective in patients with tracheal stenosis and pathologic acid reflux. Control of the airway stenosis was superior after laparoscopic fundoplication if compatred to conservative treatment of GER in this small cohort.

Second malignancy risk in patients with bronchial carcinoid tumor: epidemiological results from AIRTUM

Filippo Lococo[1], Claudia Galeone[1], Claudio Sacchettini[2], Massimiliano Paci[1], Cristian Rapicetta[1], Tommaso Ricchetti[1], Giorgio Sgarbi[1], Lucia Mangone[2]

[1]Unit of Thoracic Surgery, IRCCS-Arcispedale Santa Maria Nuova - Italy
[2]Inter-institutional Epidemiology Unit, IRCCS-Arcispedale Santa Maria Nuova - Italy

Introduction
Neuroendocrine tumors (NET) are frequently associated with secondary primary malignancies [1-2], but no data are available concerning Bronchial Carcinoid tumors (BCs).

Objective
The aim of this epidemiological study is to determine the prevalence and characteristics of additional primary malignancies in patients with BCs.

Methods
The data of neuroendocrine tumors (NET) coming from the AIRTUM registry (1975- 2011) were used for the present analysis. Among 32325 pulmonary-NET, we focused our analysis on 3205 patients (9.9%) affected by BCs. The overall STs number and incidence were calculated. The number of STs was compared with the expected cancer number (ECN) in healthy Italian population, and the standardized incidence ratio (SIR) and 95% confidence intervals were calculated.

Results
There male/female ratio was 3:1, while mean age was 61.7 yrs (range 7-94). A total of 640 STs were observed with an overall incidence of about 20%. In details, 419 tumors were metachronous, 23 synchronous and 198 detected before the diagnosis of BCs. Among all STs, the most common tumors (see Figure 1A) associated with BCs were bladder tumors (12.2% of all STs) followed by breast tumors (11.1%) and prostate tumors (10.2%). The number of observed thyroid tumors were significantly higher than ECN (estimated SIR of 3.88) in female patients (see Figure 1B), with a remarkably higher frequency of thyroid tumors synchronously detected with BCs (SIR=61.39). On the other hand, we noted in male patients an increased frequency of tumors of the urinary system with an higher number of metachronous STs at the level of kidney and renal pelvis (SIR=3.34) and synchronous STs at the level of urinary bladder tumors (SIR=3.34).

Conclusions
According with our data patients with bronchial carcinoids presented with an high risk of STs. In particular, in female patients we observed an increased frequency of synchronous thyroid tumors (SIR=61.39) while in male patients an higher frequency of kidney and renal pelvis tumors (SIR=3.34). Further prospective investigation should be performed to confirm these preliminary observations with the aim of recommending a tailored clinical and radiological surveillance in patients with diagnosis of BCs.

Bibliography
[1] Prommegger R, et al Anticancer Res. 2004 Mar-Apr;24(2C):1049-51. [2]Reina JJ, et al. Clin Transl Oncol. 2014 Oct;16(10):921-6.

A

	All STs		Sts diagnosed before BC		Synchronous Ss		Metachronous STs	
	n°	%	n°	%	n°	%	n°	%
Digestive system	136	21,1%	76	18,1%	7	30,4%	62	26,3%
colon	58	9,1%	32	7,6%	6	26,1%	20	10,1%
stomach	17	2,7%	11	2,6%	0	0,0%	6	3,0%
pancreas	11	1,7%	4	1,0%	0	0,0%	7	3,5%
other	49	7,7%	29	6,9%	1	4,3%	19	9,6%
Respiratory System	51	8,0%	40	9,5%	3	13,0%	8	4,0%
lungh and bronchus	33	5,2%	28	6,7%	3	13,0%	2	1,0%
pleura	3	0,5%	2	0,5%	0	0,0%	1	0,5%
other	15	2,3%	10	2,4%	0	0,0%	5	2,5%
Breast (only female)	71	11,1%	58	13,8%	0	0,0%	13	6,6%
Female reproductive system	24	3,8%	18	4,3%	0	0,0%	6	3,0%
Male reproductive system	69	10,8%	46	10,7%	1	4,3%	23	11,6%
prostate	65	10,2%	42	10,0%	1	4,3%	22	11,1%
other	4	0,6%	3	0,7%	0	0,0%	1	0,5%
Urinary system	113	17,7%	75	17,9%	4	17,4%	34	17,2%
bladder	78	12,2%	56	13,4%	3	13,0%	19	9,6%
kidney	35	5,5%	19	4,5%	1	4,3%	15	7,6%
Thyroid	16	2,5%	6	1,4%	4	17,4%	6	3,0%
Hematopoietic system	28	4,4%	17	4,1%	3	13,0%	8	4,0%
Brain and Nervous System	13	2,0%	4	1,0%	0	0,0%	9	4,5%
Skin	104	16,3%	69	16,5%	1	4,3%	34	17,2%
Miscellanous	16	2,5%	11	2,6%	0	0,0%	5	2,5%
	640	100,0%	419	100,0%	23	100,0%	198	100,0%

B

	Male						Female					
	Synchronous		Metachronous		Total		Synchronous		Metachronous		Total	
	Observed	O/E	Observed	O/E	Observed	O/E	Observed	O/E	Observed	O/E	Observed	O/E
Oral Cavity and Pharynx	0	0.00	6	2.06	6	1.90	0	0.00	1	1.00	1	1.06
Esophagus	0	0.00	0	0.00	0	0.00	0	0.00	0	0.00	0	0.00
Stomach	0	0.00	8	0.94	8	0.91	0	0.00	0	0.00	0	0.00
Small Intestine	0	0.00	0	0.00	0	0.00	0	0.00	0	0.00	0	0.00
Colon and Rectum	5	0.58#	14	0.83	19	1.09	1	4.41	9	0.96	10	0.93
Liver and Intrahepatic Bile Duct	0	0.00	4	0.74	4	0.71	0	0.00	2	0.98	2	0.96
Gallbladder and other Biliary	0	0.00	2	1.53	2	1.46	0	0.00	1	0.74	1	0.73
Pancreas	0	0.00	4	1.19	4	1.14	0	0.00	3	1.11	3	1.09
Nose, Nasal Cavity and Middle Ear	0	0.00	0	0.00	0	0.00	0	0.00	0	0.00	0	0.00
Larynx	1	9.27	4	1.46	5	1.79	0	0.00	0	0.00	0	0.00
Lung and Bronchus	4	4.57#	4	0.19#	8	0.37#	1	9.91	0	0.00#	1	0.21
Pleura	0	0.00	0	0.00	0	0.00	0	0.00	0	0.00	0	0.00
Bones and Joints	0	0.00	0	0.00	0	0.00	0	0.00	0	0.00	0	0.00
Soft Tissue including Heart	0	0.00	0	0.00	0	0.00	0	0.00	0	0.00	0	0.00
Melanoma of the Skin	0	0.00	2	1.00	2	0.97	0	0.00	1	0.67	1	0.65
Breast	0	0.00	0	0.00	0	0.00	0	0.00	13	0.85	13	0.83
Cervix Uteri	0	0.00	0	0.00	0	0.00	0	0.00	0	0.00	0	0.00
Corpus Uteri	0	0.00	0	0.00	0	0.00	0	0.00	3	0.80	3	0.79
Ovary	0	0.00	0	0.00	0	0.00	0	0.00	3	1.30	3	1.27
Prostate	1	1.00	22	0.89	23	0.89	0	0.00	0	0.00	0	0.00
Testis	0	0.00	0	0.00	0	0.00	0	0.00	0	0.00	0	0.00
Urinary Bladder	4	11.43#	13	1.45	17	1.77#	1	29.52	1	0.63	2	1.24
Kidney and Renal Pelvis	1	6.82	13	3.34#	14	3.47#	1	25.58	2	1.14	3	1.67
Eye and Orbit	0	0.00	0	0.00	0	0.00	0	0.00	1	9.58	1	9.28
Brain and Other Nervous System	0	0.00	2	1.29	2	1.24	0	0.00	2	1.75	2	1.71
Thyroid	1	37.24	1	1.32	2	2.58	3	81.39#	5	2.48	8	3.68#
Hodgkin Lymphoma	0	0.00	0	0.00	0	0.00	0	0.00	0	0.00	0	0.00
Non-Hodgkin Lymphoma	1	7.47	3	0.83	4	1.07	0	0.00	2	0.72	2	0.71
Myeloma	0	0.00	1	0.62	1	0.60	1	37.74	0	0.00	1	0.80
Leukemia	1	10.26	1	0.38	2	0.73	0	0.00	1	0.84	1	0.83
Mesothelioma	0	0.00	1	1.05	1	1.02	0	0.00	0	0.00	0	0.00
Kaposi Sarcoma	0	0.00	1	3.16	1	3.05	0	0.00	0	0.00	0	0.00
Miscellaneous	1	7.69	3	0.94	4	1.68	0	0.00	2	0.83	2	0.82
Other and unspecified	0	0.00	3	1.68	3	1.62	0	0.00	0	0.00	0	0.00

Excess risk is per 10.000
Confidence intervals are 95%
P < 0.05

id 379

19th WCBIP / WCBE World Congress
JOINT MEETING OF THE WORLD ASSOCIATION FOR BRONCHOLOGY AND INTERVENTIONAL PULMONOLOGY & THE INTERNATIONAL BRONCHOESOPHAGOLOGICAL SOCIETY
www.wcbipwcbe2016.org
Fortezza da Basso
May 8-11, 2016
Florence (Italy)

Single-center prospective study on clinical evolution of non-specific pleuritis

Maria Cristina Paonessa[1], Marica Caruso[1], Federico Mei[2], Martina Bonifazi[3], Francesca Barbisan[4], Lina Zuccatosta[2], Michele Sediari[2], Stefano Gasparini[3]

[1]Pulmonary Diseases Unit, Department of Internal Medicine, Azienda Ospedali Riuniti, Ancona, Italy - Pulmonary Diseases Unit,University Magna Graecia,Catanzaro, Italy, Azienda Ospedali Riuniti- Università Politecnica delle Marche - Università Magna Graecia,Catanzaro - Italy
[2]Pulmonary Diseases Unit, Department of Internal Medicine, Azienda Ospedali Riuniti, Ancona, Italy, Azienda Ospedali Riuniti- Università Politecnica delle Marche - Italy
[3]Pulmonary Diseases Unit, Department of Internal Medicine, Azienda Ospedali Riuniti, Ancona, Italy - Department of Biomedical Sciences and Public Health, Università Politecnica delle Marche, Azienda Ospedali Riuniti- Università Politecnica delle Marche - Italy
[4]Pathology Unit , Azienda Ospedali Riuniti, Ancona, Italy, Azienda Ospedali Riuniti- Università Politecnica delle Marche - Italy

Introduction

Pleural effusions are a common presenting feature of a wide range of pleural, pulmonary and systemic diseases. Medical thoracoscopy is recommended in the diagnostic work-up of patients with exudative pleural effusions. The histological finding of ‘nonspecific pleuritis/fibrosis’ is common in thoracoscopic biopsies and presents a challenge for clinicians and patients as the long-term outcome of these patients is unclear, and anxieties about an underlying malignancy persist.

Objective

The present study aimed to prospectively examine the long-term outcomes of patients with diagnosis of “nonspecific pleuritis” on thoracoscopic pleural biopsies in order to assess whether this condition can be really considered as an idiopathic specific disease or, rather, it just represents a 'false- negative' sampling in the context of different underlying unrecognized disorders (Ethical Committee approval number 209458).

Methods

Every patients, referred to the Pulmonary Diseases Unit (Azienda Ospedaliero- Universitaria Ospedali Riuniti of Ancona, Italy), who underwent medical thoracoscopy in a 2-years enrollment period (from January 2011 to December 2013) and received a diagnosis of “nonspecific pleuritis” was enrolled in the present study, if they did not present any features of alternative diagnosis, assessed through a detailed medical evaluation, including echocardiography, bacteriological and virological tests, and autoimmune serology. The longitudinal follow up included visits and radiographic evaluation at 3, 6, 12 and 24 months in order to assess potential relapses and clinical evolution.

Results

Overall, 37 patients (mean age 70.9±13.9 years) were included in the present study. Complete 2-years follow-up information was obtained in 22 patients; 15 patients have completed 1-year follow up. At 2 years, 2 (10%) patients were ultimately found to have underlying pleural malignancy on follow-up; 3 (13%) patients were subsequently diagnosed with benign conditions (1 autoimmune diseases, 2 hearth failures). The remaining 17 (77%) patients did not develop any features suggestive for other diseases, and they were ultimately deemed as cases of idiopathic pleuritis. Overall, the relapse rate was 46%. Eight patients (22%) have subsequently diagnosed with malignant conditions, while 9 subjects (24%) developed non-malignant conditions.

Conclusions

Idiopathic benign pleuritis occurs in approximately 50% of patients with histological finding of nonspecific pleuritis, suggesting that it could be really considered as a separate entity. However, both benign and malignant conditions were ultimately found in the remaining subjects, underlying the importance of a close follow-up in these patients.

19th WCBIP / WCBE World Congress
JOINT MEETING OF THE WORLD ASSOCIATION FOR BRONCHOLOGY AND INTERVENTIONAL PULMONOLOGY & THE INTERNATIONAL BRONCHOESOPHAGOLOGICAL SOCIETY
www.wcbipwcbe2016.org
Fortezza da Basso
May 8-11, 2016
Florence (Italy)

Indwelling Pleural Catheter In Managing Hepatic Hydrothorax: A Case Series

Nurul Yaqeen Esa, Mohd Arif Mohd Zimm, Ahmad Izuanuddin Ismail, Mohamed Fauzi Rani

Internal Medicine, Universiti Teknologi MARA - Malaysia

Introduction

The usage of indwelling pleural catheters (IPCs) in the management of malignant pleural effusion (MPE) are well established. However, there is little data on their usage in non-malignant conditions, especially the one associated with liver cirrhosis or also called as hepatic hydrothorax. The current management of recurrent hepatic hydrothorax entails optimization of medical treatment, which seldom produce favourable outcome. An alternative treatment is the usage of indwelling pleural catheter (IPC). However, the data on utilization of IPC for the treatment of hepatic hydrothorax in Malaysia are still limited.

Objective

We aimed to analyse our experience and evaluate the safety and feasibility of using IPCs for non-malignant pleural effusion associated with liver cirrhosis.

Methods

We constructed a cohort of patients who underwent IPC insertion for recurrent hepatic hydrothorax, from January till December 2015. The IPCs were inserted as a palliative measure in patients who had thoracentesis twice within the preceding 2 months, no evidence of infection and either failure to respond, complications or intolerance to maximal medical therapy, or if IPC insertion would enable discharge when the patient was hospitalized mainly for dyspnoea due to pleural effusion.

Results

We inserted 2 IPCs in patients presented with recurrent transudative pleural effusion associated with liver cirrhosis from January till December 2015. Both patients were females, aged 36 and 53 years old. Their diagnoses were Primary Biliary Cirrhosis and Cryptogenic Liver Cirrhosis. The duration of hospital stay were shortened from 10 and 14 days to 4 and 6 days. Both patients achieved good results with symptoms resolution after IPC insertion. One patient developed empyema secondary to blocked IPC, however, upon removal of the IPC, successful spontaneous pleurodesis occurred.

Conclusions

IPC is an alternative treatment for the management of patients with symptomatic recurrent non-malignant pleural effusions associated with liver cirrhosis. The advantages of the IPC are that it shortened hospital stay with good initial success rate. However, long term outcome remain undetermined. Larger studies are needed, particularly regarding the impact of this intervention on quality of life.

Bibliography

Potechin R, et al. Ther Adv Respir Dis. 2015 Feb;9(1):22-7

Semi-rigid thoracoscopy in diagnosing pleural effusion: Institute of Respiratory Medicine experience

Syazatul Syakirin Sirol Aflah

Respiratory, Institute of Respiratory Medicine - Malaysia

Introduction

Approximately 25% of pleural abnormalities remain unexplained after repeated thoracocenthesis and/or closed pleural biopsies. Pleuroscopy provides an accurate diagnosis in effusions of unknown aetiology. Pleuroscopy is also referred to as medical thoracoscopy is generally described as the evaluation of the pleural space and it is a minimal invasive technique which allows direct visualization of the pleura, removal of the pleural fluid and biopsy of the pleura through single skin incision

Objective

1.To find the diagnostic yield of a pleuroscopic pleural biopsy 2.To find pleuroscopy complication rates.

Methods

A retrospective study was conducted among patients referred to our institute underwent pleuroscopic procedure using semi rigid thoracoscopic under sedation and local anaesthesia from January 2014 until June 2015. Data obtained from pleuroscopy reports and clinical notes.

Results

A total of 71 patients (43 males and 28 females; mean age 49 years) underwent pleuroscopy . Overall yield in the present study was 88.8% (63 out of 71).Majority of patients had histopathology examination (HPE) confirmed malignancy (46.5%) followed by 42.3% were infective origin and the rest were normal (11.2%). Of the malignancy subtype, adenocarcinoma (85%) was the highest to report on pleuroscopy findings followed by squamous cell carcinoma (9%) and metastatic carcinoma (6%). Tuberculosis remained the most common cause of infective pleural effusion (90%) as Malaysia is endemic for tuberculosis and followed by empyema (10%)which was bacterial origin. However not all parietal pleura nodules were malignancy as we found 9 patients confirmed infective origin from HPE findings. 9 patients found to have sago like appearance in the parietal pleura were 100% confirmed tuberculosis. In term of post pleuroscopy complication, 85.9% had no complications, 9 patients had minor complication such as subcutaneous emphysema (6 patients), infection (3 patients) and prolonged air leak (one patient).

Conclusions

Semi rigid thoracoscopy is a safe, simple, and valuable tool in the diagnosis of undiagnosed exudative pleural effusion with minimal complication rates. It has a high diagnostic yield and good safety profile, and is well tolerated.The benefit of doing pleuroscopy also it will experdite the treatment especially in tuberculosis.

Bibliography

1. Debeljak A et al Endosk Rev 1998; 3: 135-9. 2. Rozman A Zdrav Vestn 2011; 80: 546-52.

Variable	n (%)
Malignancy	
Adenocarcinoma	28 (39.4)
Squamous Cell Carcinoma	3 (4.2)
Metastases	4 (2.8)
Infection	
Tuberculosis	27 (38)
Bacterial	2 (2.8)
Benign disease	
Pleuritis	1 (1.4)
Unsatisfactory	4 (5.6)
Normal	4 (5.6)
Complications	
Subcutaneous emphysema	6 (8.5)
Persistent air leak	1 (1.4)
Infection	3 (4.2)
Nil	61 (85.9)

Table 1 - Final diagnosis and complication from semi rigid thoracoscopy procedure in Institute Respiratory Medicine, Kuala Lumpur, Malaysia.

id 382

A diagnosis of idiopathic pulmonary fibrosis and lung cancer with transbronchial lung cryobiopsy

Federico Mei[1], Martina Bonifazi[2], Donato Lacedonia[3], Maria Pia Foschino[3], Lina Zuccatosta[1], Michele Sediari[1], Stefano Gasparini[2]

[1]Pulmonary Diseases Unit, Department of Internal Medicine, Azienda Ospedali Riuniti - Italy
[2]Pulmonary Diseases Unit, Department of Internal Medicine / Department of Biomedical Sciences and Public Health, Azienda Ospedali Riuniti / Università Politecnica delle Marche - Italy
[3]Department of Surgical and Medical Sciences, University of Foggia - Italy

Introduction

An accurate diagnosis of idiopathic pulmonary fibrosis (IPF) is a challenging process, as it requires an integrated multidisciplinary approach, involving pulmonologists, radiologists, and, in case of inconclusive results, also pathologists. Due to the limited role of transbronchial lung biopsy in obtaining a proper tissue sample and the appreciable risks related to surgical lung biopsy (SLB), more recently, transbronchial lung criobiopsy (TBLC) has been proposed as valuable alternative tool for the pathologic assessment of LDs. Moreover, a higher prevalence of lung cancer (LC) in IPF patients, as compared to control subjects, has been shown in a number of studies, suggesting a potential relationship between an exuberant collagen deposition and neoplastic change. Diagnosis and treatment of LC in IPF are burdened by an increased incidence of severe complicating events, apparently as lethal as the cancer itself.1 In this context, TBLC may offer the advantage to diagnose both the disease, sampling different lobes, in the same session, avoiding a more invasive and risky surgical procedure. Here, we report a case of a man simultaneoulsy diagnosed with IPF and lung cancer though TBLC.

Methods

A sixty-eigth-years-old man, never smoker, without occupational exposure to toxic matter, living in urban context, presented to our istitution with a one-year long mild exertional dyspnea. Functional respiratory test showed severe sign of restrictive disease with a moderate DLCO reduction. HRCT scan revealed a diffuse interlobular septal thickening with honey combing changes, mainly in basal, subpleural areas, associated with traction bronchiectasis and a parenchymal consolidation in lower left lobe. We carried out TBLC (2.4 mm-diameter cryoprobe) during rigid bronchoscopy in intubated patient under general anesthesia and fluoroscopic guidance, performing four samples, two in the left upper lobe and two in the lower lobe. No pneumothorax and/or major bleeding occurred. The histological features were suggestive to UIP-pattern in the upper lobe and to Mucionous Adenocarcinoma in the lower lobe. Figure 1 report these different histological findings and the relative radiological appearance.

Conclusions

This case suggests that TBLC may play a major role in the diagnostic work up of IPF, guaranteeing an excellent diagnostic and safety profile. In particular, TBLC allows the sampling two or more different lobes in the same session, obtaining distinct diagnoses. Moreover, this case further underlies the importance of carefully considering the higher likelihood of lung cancer in IPF, due its significant impact on management and survival of patients.

Bibliography

Tommassetti S, et al. The Impact of Lung Cancer on Survival of Idiopathic Pulmonary Fibrosis. Chest 2015; 147(1):157-164

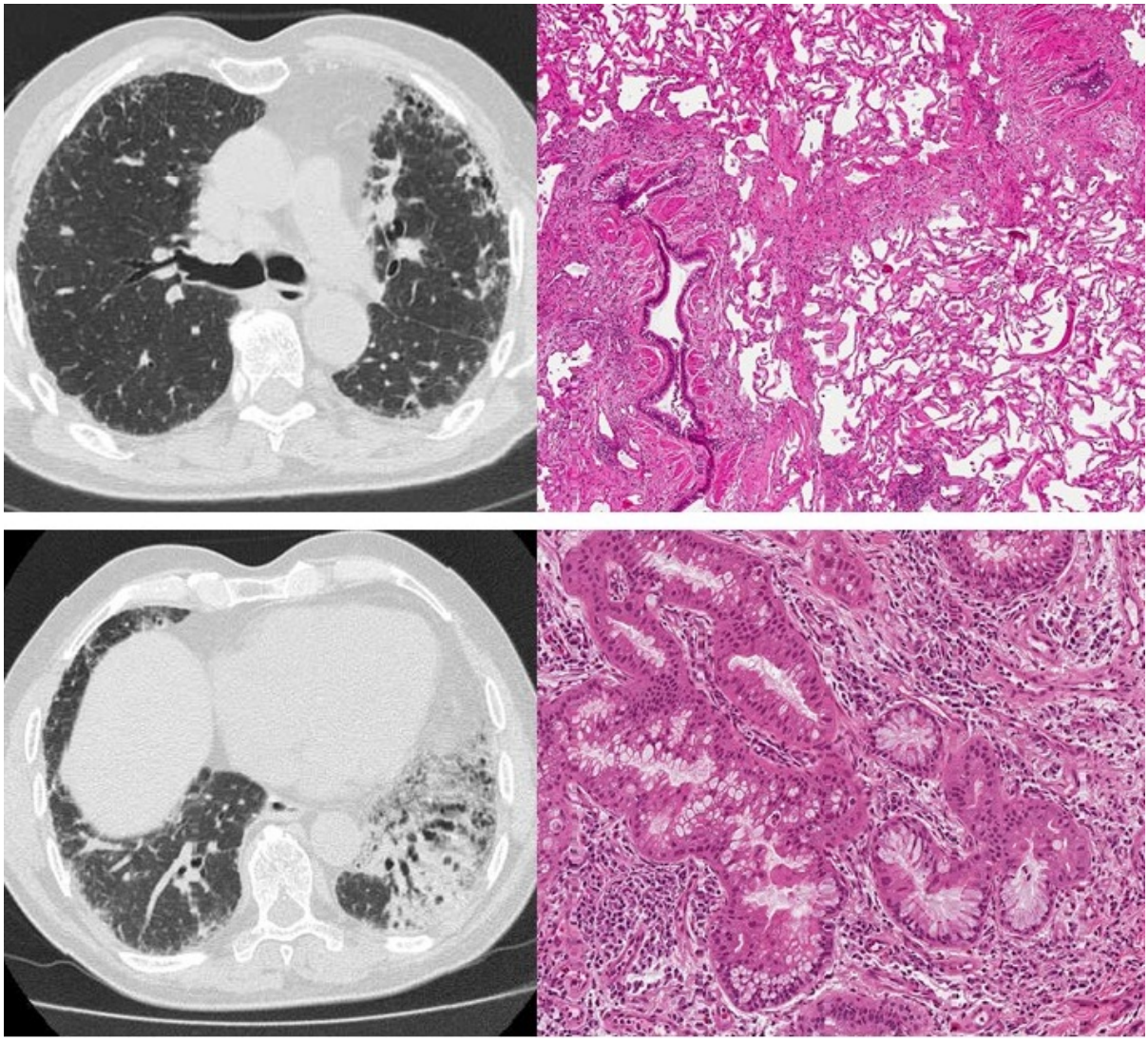

id 383

Pneumothorax detected by electrical impedance tomography during ELVR for emphysema

Paulo F. G. Cardoso[1], Vinicius Torsani[2], Ricardo H.o.b. Teixeira[2], Silvia V. Campos[2], José E. Afonso Junior[2], Rafael M. Carraro[2], Andre N. Costa[2], Lucas M. Fernandes[1], Luis G. Abdalla[1], Viviane R. Figueiredo[3], Marcos N. Samano[1], Filippe M. Gouvêa[1], Carlos R. R. Carvalho[2], Paulo M. Pêgo-fernandes[1], Marcelo B. P. Amato[2]

[1]Division of Thoracic Surgery, Heart Institute (InCor) - Hospital das Clinicas, Faculty of Medicine of the University of São Paulo - Brazil
[2]Division of Pneumology, Heart Institute (InCor) - Hospital das Clinicas, Faculty of Medicine of the University of São Paulo - Brazil
[3]Service of Respiratory Endoscopy, Heart Institute (InCor) - Hospital das Clinicas, Faculty of Medicine of the University of São Paulo - Brazil

Introduction
Pneumothorax is a feared complication following endoscopic lung volume reduction for emphysema (ELVR). Conversely, it has been associated with better long-term outcomes. Electrical impedance tomography (EIT) is a noninvasive, radiation-free, bedside method capable of measuring regional ventilation in real time and early detection of pneumothorax. To date there have been no reports of pneumothorax detected by EIT after ELVR.

Objective
To report a case in which EIT detected pneumothorax after ELVR

Methods
A 71 year-old male underwent left lung transplantation for emphysema in 2007. Within the last 3 years he experienced a progressive loss of pulmonary function attributed to chronic graft dysfunction aggravated by native lung hyperinflation. ELVR was considered since the patient was clinically unfit for surgery. After assessment by HRCT scans (figure-left), pulmonary function tests, dyspnea score, exercise capacity and optoelectronic plethismography, one-way valves (EBV-Zephyr, Pulmonx, CA-USA) were placed in the target lobe (right lower lobe-RLL) using flexible bronchoscopy. EIT data was acquired by a functional monitor (DX-1800 Timpel, São Paulo-Brazil) using a 32-electrode belt placed circumferentially around the chest between the 5th and 6th intercostal space at a sample rate of 50 images/second. EIT monitoring and data recording were obtained continuously and in real time while the patient is in supine position during valve placement. EIT measurements included impedance waveform and percentage of ventilation distribution for each side. The hyperinflated RLL was treated with 3 valves.

Results
Approximately five minutes after completion of the procedure there was a sudden change both in EIT waveform and the ventilation distribution suggesting right-sided pneumothorax confirmed by clinical examination and the deterioration of the ventilation parameters. A right-sided chest tube was then placed immediately with relief of dyspnea and return to homogeneous ventilation distribution (right-57%;left-43%) (figure-center). At 2 months after the procedure one valve had to be replaced. At 3 months post-ELVR right lung volume decreased 292mL. PFts showed improvement in FEV1 from 0,66L (28%) pre-ELVR to 1,22 (41%) 18 months post-ELVR; HRCT scan performed 18 months after ELVR showed atelectasis of the RLL (figure-right; arrow). SGRQ was 43 points pre-ELVR and reduced to 19 points at 18 months post-ELVR (24 point reduction).

Conclusions
EIT can be used as a tool for online monitoring of ELVR particularly in high risk patients for pneumothorax allowing early by detection and expedite and successful treatment. Sustained atelectasis of the RLL was obtained and it was associated with long-term improvements in pulmonary function and quality of life.



HRCT pre-ELVR EIT during ELVR HRCT 18 months post-ELVR

The presenting author has the following conflicts of interest that relate to this abstract: *Disclosure of funding source: FAPESP (Fundação de Amparo a Pesquisa do Estado de Sao Paulo, Brazil ; 2012/00100-2)*

id 384

19th WCBIP / WCBE World Congress
JOINT MEETING OF THE WORLD ASSOCIATION FOR BRONCHOLOGY AND INTERVENTIONAL PULMONOLOGY & THE INTERNATIONAL BRONCHOESOPHAGOLOGICAL SOCIETY
www.wcbipwcbe2016.org
Fortezza da Basso
May 8-11, 2016
Florence (Italy)

Intervention Bronchoscopy to Diagnose An Ancient Disease: 4 case series

Syazatul Syakirin Sirol Aflah

Respiratory Medicine, Institite of Respiratory Medicine - Malaysia

Introduction

Thoracic tuberculous lymphadenopathy remains a common presentation in patients originating from countries of high tuberculosis prevalence.Without parenchymal lung abnormalities, inaccessible isolated thoracic lymphadenopathy often poses a diagnostic challenge due to low diagnostic yield of sputum studies. Given the emerging issue of drug-resistant tuberculosis, it is good practice to isolate the Mycobacterium tuberculosis bacillus and seek compatible histologic evidence of caseation granulomas before commencing treatment. To diagnose a miliary TB and isolated mediastinal lymphadenitis is uncommon in immunocompetent adults, can be a challenge that can perplex even the most experienced clinicians.

Methods

We report 4 cases of immunocompetent patients diagnosed with tuberculosis with transbronchial lung biopsy and EBUS-TBNA under sedation. Case 1 A 16 year old girl presented with 3 months of cough and fever with constitutional symptoms. Her chest X-ray showed diffuse nodular opacities and treated for smear negative pulmonary tuberculosis. There was no radiological improvement whilst on 2 months intensive treatment. She underwent a bronchoscopy and trans bronchial lung biopsy (TBLB) and HPE reported as chronic necrotizing granulomatous inflammation suggestive of tuberculosis and culture sensitive to first line anti tuberculous therapy. Case 2 A 23 year old Indian man, asymptomatic with incidental findings of CXR abnormalities during medical check-up. His CXR showed miliary shadows bilaterally, sputum AFB were negative and tuberculin skin test (TST) was 10mm. A trans bronchial lung biopsy was done which showed a chronic granulomatous changes on histology examination. Case 3 A 29 year old Malay lady presented with haemoptysis for 1 week with constitutional symptoms. Her CXR showed bilateral hilar enlargement and TST was 4mm with negative sputum AFB. CT Thorax showed multiple matted enlarged necrotic mediastinal and right hilar lymph node. EBUS-TBNA lymph node station 10 showed necrotizing granulomatous inflammation suggestive of tuberculous lymphadenitis. Case 4 21 year old Indonesian lady presented with fever 3 months and constitutional symptoms. Her TST was 15mm and sputum AFB negative. CT Thorax showed multiple supraclavicular and mediastinal lymph nodes with necrotic caseating centre. EBUS-TBNA done at station 7, aspiration showed a cytology of chronic granulomatous inflammation suggestive of tuberculosis.

Conclusions

In our case series which involved immunocompetent adults, tuberculosis should be considered as a possible aetiology and diagnosis with confirmed histology and culture of specimens are crucial to guide in patients' management.

Bibliography

1. Steinfort DP et al J Infect 2009;58:309e11 2. Lin SM J Thorac Cardiovasc Surg 2009;138:179–184.

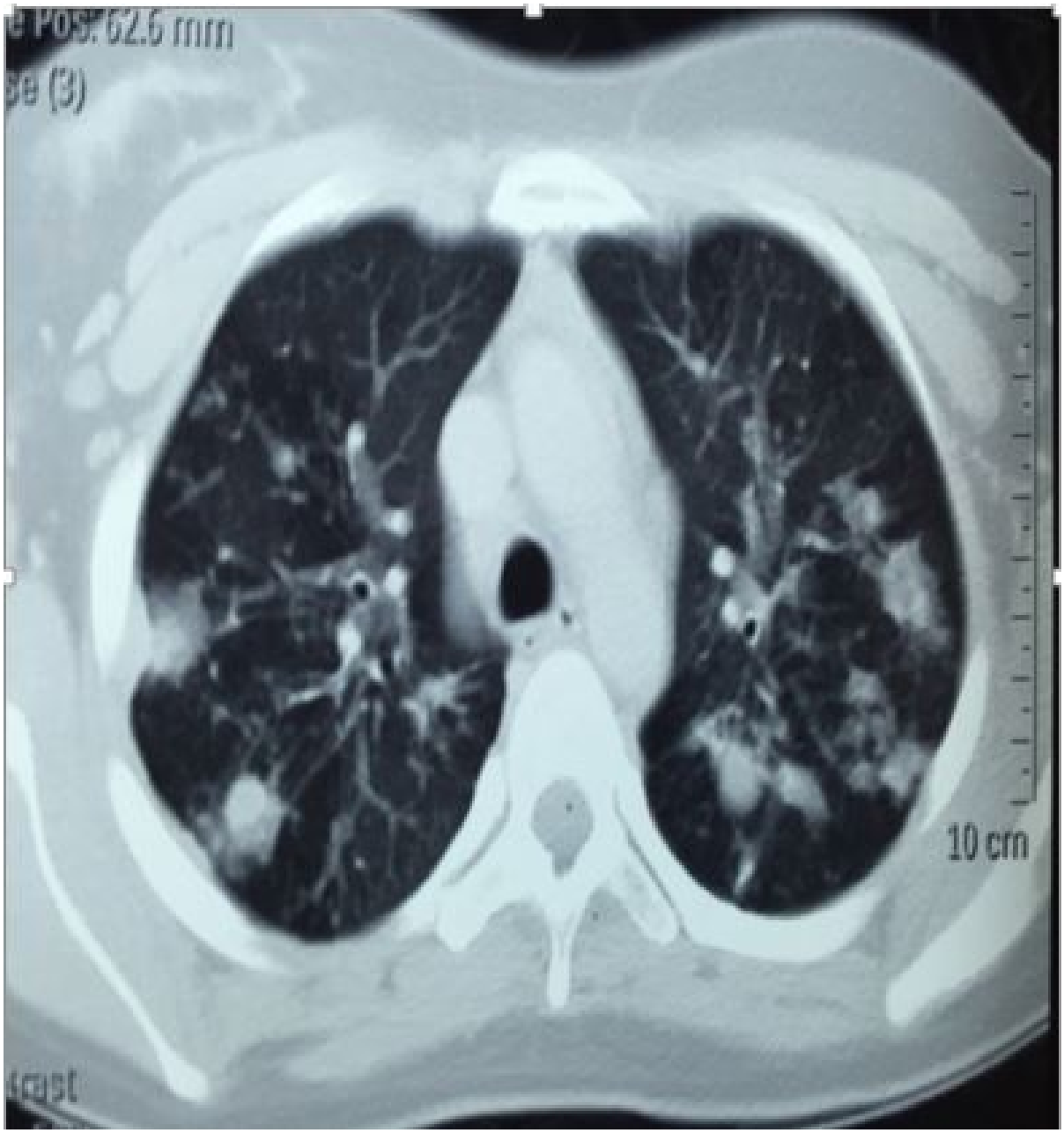

id 385

19th WCBIP / WCBE World Congress
JOINT MEETING OF THE WORLD ASSOCIATION FOR BRONCHOLOGY AND INTERVENTIONAL PULMONOLOGY & THE INTERNATIONAL BRONCHOESOPHAGOLOGICAL SOCIETY
www.wcbipwcbe2016.org
Fortezza da Basso
May 8-11, 2016
Florence (Italy)

Safety and Histological Effect of RejuvenAir Spray Cryotherapy in the Lung

Slebos D.j.[1], Breen D[2], Coad J[3], Irshad K[4]

[1]Department of Pulmonary diseases, University Medical Center Groningen - The Netherlands
[2]Interventional Respiratory Unit, Galway University Hospitals - Ireland
[3]Department of Pathology, West Virginia University - Usa
[4]thoracic Surgery, William Osler Health System - Canada

Introduction

The RejuvenAir System is designed to deliver liquid nitrogen (LN2) spray cryotherapy via a radial spray catheter through a bronchoscope with the intention to treat the airways of chronic bronchitis patients.

Objective

We hypothesize that a controlled amount of LN2, delivered from the first segmental airways to the base of the trachea will ablate abnormal airway epithelium and submucosa and regenerate to a less mucous producing, less inflamed tissue without associated airway scarring. In this initial study, we assessed the safety and feasibility of this therapy. Specifically LN2 was not previously delivered this distally in the lung and the associated intra- bronchial pressure gradient resulting from the transition of liquid nitrogen to gaseous nitrogen has not been tested. In addition, the histological effect of treatment on the tissue was examined.

Methods

Patients with (presumed) lung cancer undergoing lobectomy or pneumonectomy were potential candidates and assessed for inclusion/exclusion criteria. Prior to the surgical resection a 4.4 mm OD bronchoscope was delivered through an 8.5 mm (minimum) endotracheal tube and the catheter was positioned at either the first segment or lobular bronchi at least 2 cm distal to the intended lobectomy resection margin. The amount of spray was determined by the diameter of the airway and controlled by administration time. Gas egress was achieved by disconnecting the anesthesia circuit and deflating the endotracheal tube cuff. Each case received two admistrations of spray to separate locations. Once treatment was completed, surgery continued as scheduled, and the treated area was sent in for histopathological examination.

Results

Fifteen subjects (9 male, 6 female; mean FEV1 81.6 ± 26.5% of predicted, range of 46 to 132% of predicted; 11 had smoking history) each received 2 sprays of LN2. There were no device related adverse or serious adverse events, and especially no pneumothoraxes. In total twelve subjects had tissue submitted from LN2 treated areas. Histology review demonstrated that there was no involvement deeper to the submucosal layer with minimal inflammatory changes.

Conclusions

This initial study using the RejuvenAir System in the distal central airways in a population of patients who were scheduled to undergo a planned lobectomy or pneumonectomy was found to be feasible and safe with no device related adverse events or pneumothorax observed. Furthermore, histology to date noted cryothermic changes that were not deeper than the submucosa with minimal inflammation.

The presenting author has the following conflicts of interest that relate to this abstract: *Participated in the trial presented, and his hospital was reimbursed for study related expenses.*

id 386

Validation of GOLD Staging by Optical Coherence Tomography

Yu Chen, Ming Ding, Changhao Zhong, Shiyue Li, Nanshan Zhong

Interventional Pulmonary, The first affiliated hospital of GuangZhou Medical University - China

Introduction

It remains unclear that to what extent the FEV1 based COPD staging interprets the severity of small airway disorders ; Small airway disease might be the sole manifestation of early-stage COPD; The association between the overall well-beings and the magnitude of distal airway disorder has been difficult to establish by using conventional tools such as spirometry or radiology;OCT may be useful demonstrating airway disorders in COPD.

Objective

Using endobronchial optical coherence tomography(EB-OCT) to assess the association between the airway remodeling and the various COPD stages and detect the morphological changes of heavy smokers with normal FEV1.

Methods

We recruited 149 subjects between January 2015 and October 2015, consisted of 80 COPD patients of varying stages (stage ?,n=13; stage ?, n=34; stage ?- ?, n=34), 39 heavy smokers(>20 pack year) with normal FEV1, and 29 subjects without smoking history (control group). For all subjects, assessments included inquiry of smoking history, spirometry, chest CT, bronchoscopy and EB-OCT. Measurement of the parameters of Dmean (mean luminal diameter), Ai (inner luminal area), Aw (airway wall area) and Aw% [Aw/(Ai+Aw)×100%] from the 3rd to 9th generation bronchi was performed by EB-OCT, and evaluate the association between the results of EB-OCT with the staging of COPD (FEV1.)

Results

From generation 7th to 9th , the mean diameter was larger in smokers (2.16±0.29mm) than in COPD patients in stage ?(1.75±0.28mm, P<0.001) , stage ? COPD(1.55±0.15mm, P<0.001) and stage ?-? COPD(1.35±0.15mm, P<0.001), and Aw% was significant lower in smokers(26.98±7.88%) than in stage ? COPD (39.27±12.98%, P<0.001), stage ? COPD(39.82±3.97%, P<0.001) and stage ?-? COPD(46.46±3.52%, P<0.001). While there were larger mean diameter in normal subjects than smokers (3.57±0.14mm vs. 3.33±0.2mm, P<0.001), the airway wall percentage of Smokers was greater than healthy subjects (26.98±7.88% vs. 11.56±2.63%, P<0.001). The mean diameter from gen 7th to 9th correlated significantly with FEV1% predicted in stage? and ?-?COPD patients (r=0.48, P=0.004 and r=0.581, P<0.001 respectively). There were significant negative correlations between Aw% (gen 7th to 9th)and FEV1% predicted in stage ? and stage ?-? COPD (r=0.403, P=0.018 and r=0.744, P<0.001, respectively).

Conclusions

OCT as anuseful tool in detecting small airway disorders in COPD patients; Heavy smokers with normal FEV1 had apparent morphological changes in small airways from normal subjects, and it was similar to the COPD patients but in less severity. The characteristics of airway remodeling was more obvious to the peripheral lung.

Bibliography

Yu Chen,et al,Validation of human small airway measurements using endobronchial optical coherence tomography,Respiratory Medicine 109 (2015);1446-1453.

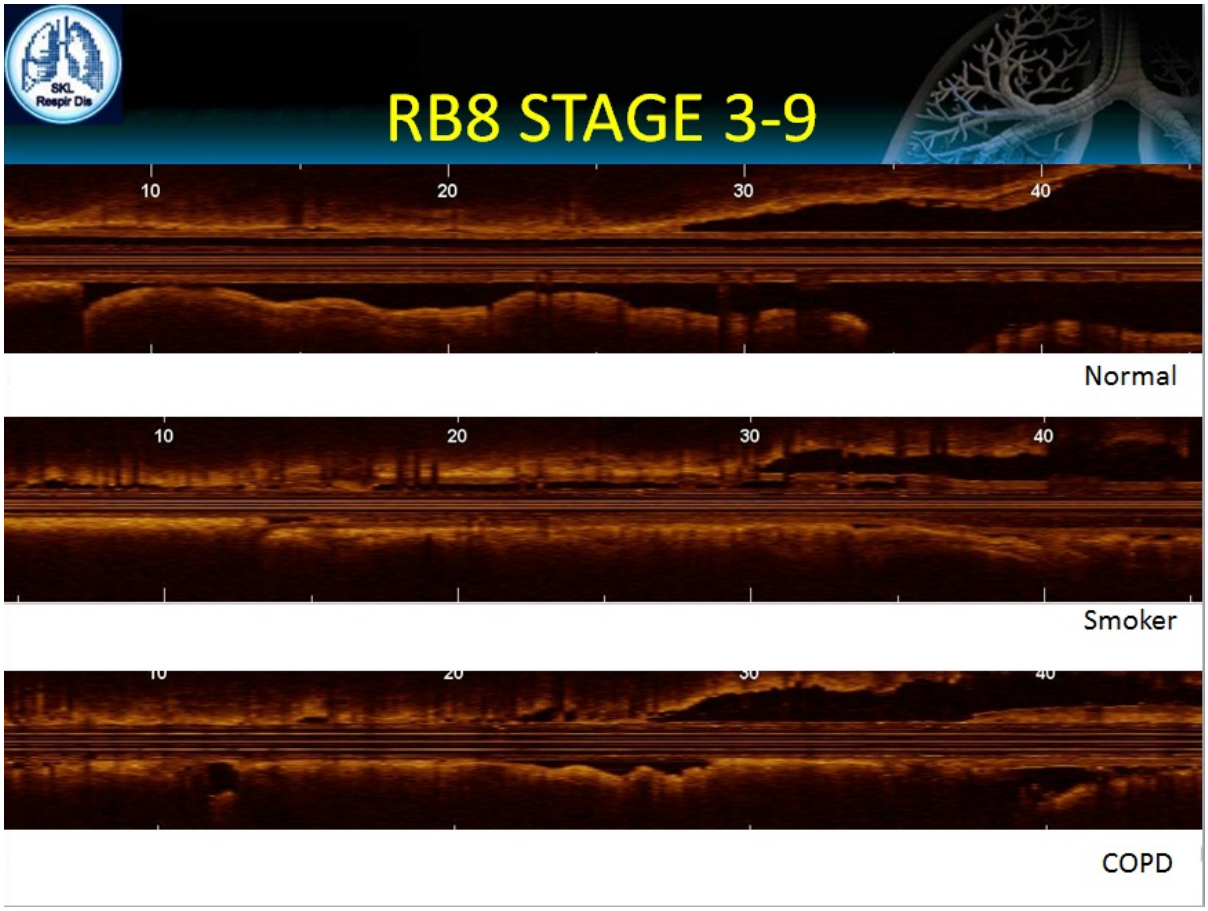

id 387

Identifying and quantifying characteristics of ILD by CLE

Lizzy Wijmans[1], Daniel Martijn De Bruin[2], Peter Bonta[1], Renee Jonkers[3], Joris Roelofs[4], Inge Van Den Berk[5], Jouke Tabe Annema[3]

[1]Pulmonology, University of Amsterdam, AMC - Holland
[2]Biomedical engineering and physics, University of Amsterdam, AMC - Holland
[3]Pulmonology, University of Amsterdam - Holland
[4]Pathology, University of Amsterdam - Holland
[5]Radiology, University of Amsterdam - Holland

Introduction

Diagnosing the different disease entities of interstitial lung disease (ILD) is challenging as high resolution computed tomography (HRCT) imaging and bronchoalveolair lavage (BAL) outcomes are frequently not sufficient to determine a specific diagnosis. In these cases a tissue diagnosis is required. However, open lung biopsy by video-assisted thoracoscopy (VATS) is – when at all possible – associated with a high morbidity. Confocal laser endomicroscopy (CLE) is a novel imaging technique that, when combined with bronchoscopy, provides high detailed images of the alveolar compartment.

Objective

To identify and quantify characteristics of ILD on CLE images and compare normal lung tissue with alveolar sections affected by ILD .

Methods

In ILD- patients scheduled for bronchoscopy (n=3), areas of interest were identified on the HRCT scan and subsequently imaged by CLE (laser 488 nm, resolution 3,5 µm, field of view 600 µm, Mauna Kea Technologies, France). CLE measurements of the alveolar compartment of ‘non-suspected’ and for ILD ‘suspected’ areas were obtained, based on sites selected by high-resolution computed tomography. Frame by frame analysis of image density defined as the greyscale intensity of the CLE image, ranging from 0(black) to 255(white) and measuring alveolar septum thickness (µm) of the CLE images using FIJI software.

Results

With CLE, the architecture of the alveolar compartment was well depicted and visual characteristics such as: overall density, alveolar septum thickness and filling of the alveolar space were clearly identified. Frame by frame analysis of the CLE images (n=30) showed higher densities in diseased lung areas [34,7 (range 22,6-46,3)] compared to normal appearing alveolar areas [19,8 (range 15,7-23,6)]. Alveolar septum thickness (n=18) varied within diseased areas [27,2 um (range 17-40)] and normal areas [22,8 um (range 12-42)].(Figure 1)

Conclusions

Lungparenchymal CLE images can be quantified by measuring alveolar density and septum thickness. CLE imaging during bronchoscopy in ILD patients can discriminate normal alveolar compartments from diseased parts by differences in greyscale intensity. Quantification of CLE images of the alveolar compartment might qualify as a minimally invasive and safe way to distinct different ILD patterns at bronchoscopy. Possibly, “optical biopsy” by CLE imaging may result in targeted or diminished need of tissue acquisition.

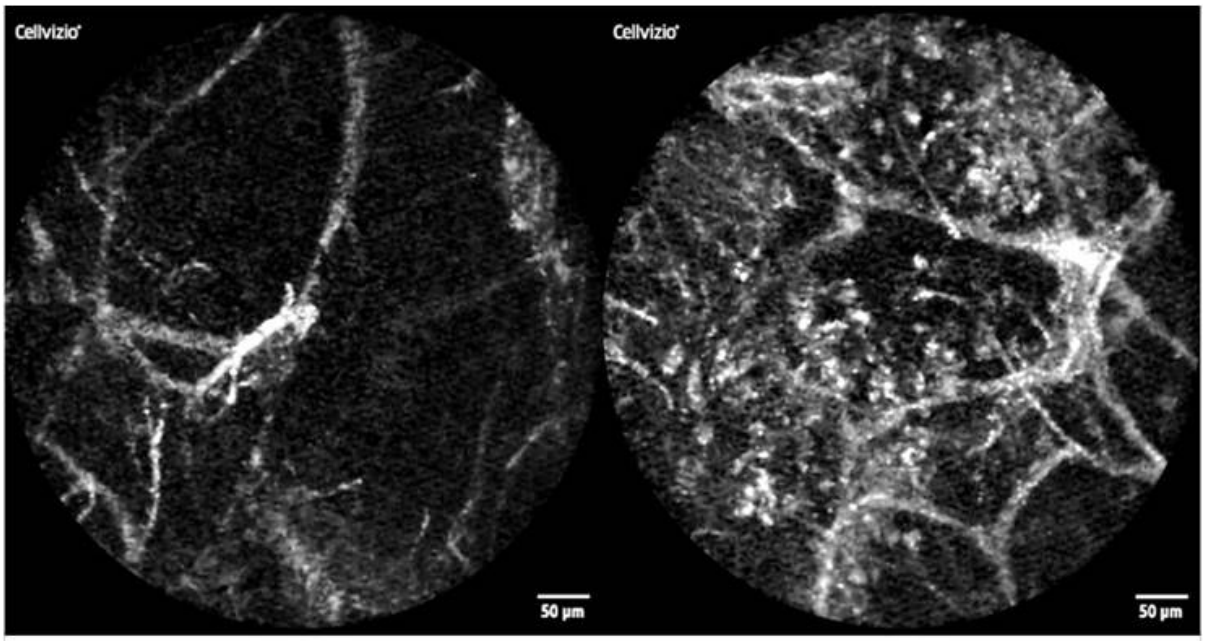
Cellvizio
Cellvizio
50 µm
50 µm

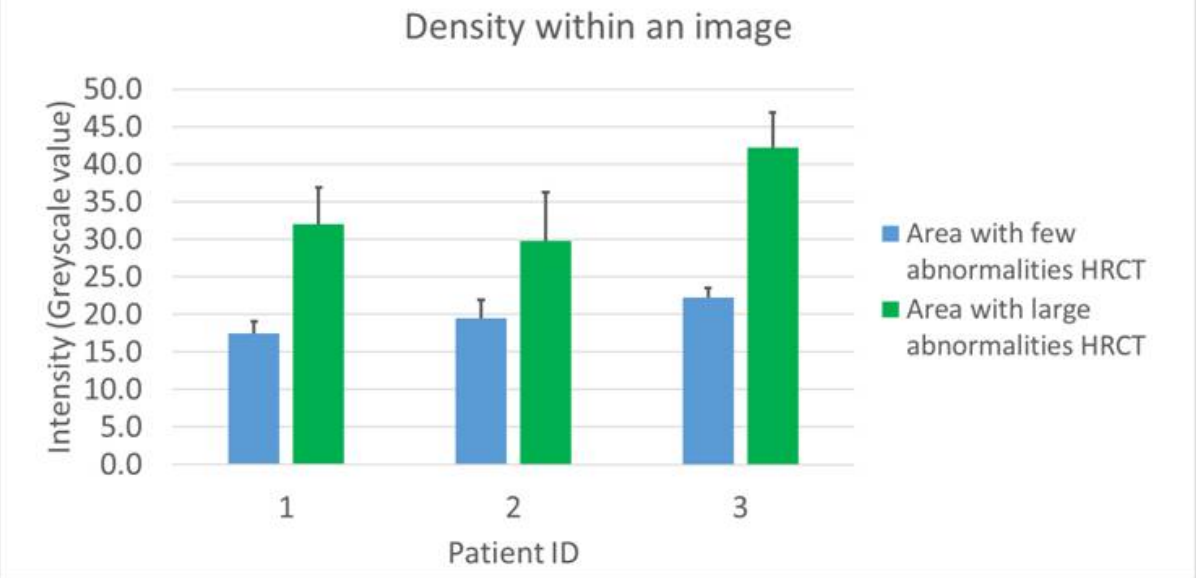
Density within an image
Intensity (Greyscale value)
50.0
45.0
40.0
35.0
30.0
25.0
20.0
15.0
10.0
5.0
0.0
1
2
3
Patient ID
Area with few abnormalities HRCT
Area with large abnormalities HRCT

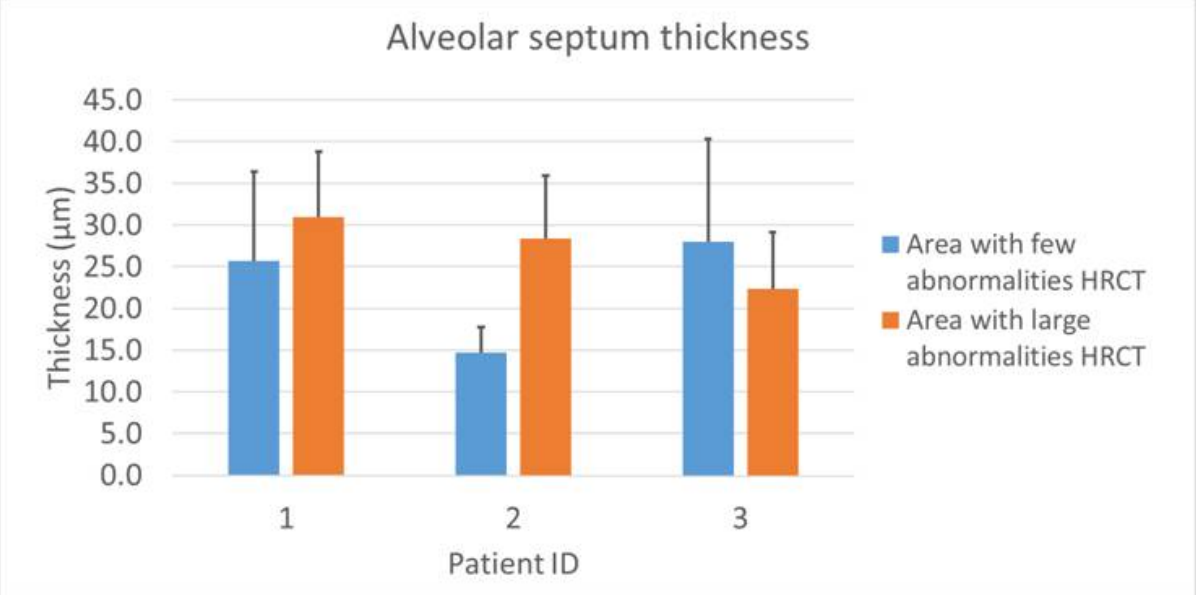
Alveolar septum thickness
Thickness (µm)
45.0
40.0
35.0
30.0
25.0
20.0
15.0
10.0
5.0
0.0
1
2
3
Patient ID
Area with few abnormalities HRCT
Area with large abnormalities HRCT

id 388

Is there any utility in visually inspecting samples during EBUS-TBNA?

M.ghanem Aldik[1], Timothy Howell[1], Katherine S Syred[2], Cyrus Daneshvar[1]

[1]Department of Respiratory Medicine, Plymouth Hospitals NHS Trust - United Kingdom
[2]Department of Pathology, Plymouth Hospitals NHS Trust - United Kingdom

Introduction

Endobronchial ultrasound with transbronchial needle aspiration (EBUS-TBNA) is a valuable tool in the diagnosis of mediastinal and hilar lymphadenopathy. Rapid on site evaluation of samples during EBUS has been studied. There is little data on the utility of visually inspecting a sample obtained during the procedure and whether this is of any value in defining an adequate or a representative sample?

Objective

The main objective was to determine whether the macroscopic appearance can be used as a guide in determining a representative lymph node sample.

Methods

Consecutive patients undergoing EBUS-TBNA (Fujifilm EB-530US /SU-8000; Cook EBUS-22G-O/C needles) under conscious sedation were prospectively assessed. Histological samples were placed in formalin to be processed as a cell block. Slides were not prepared. Following sampling of each nodal station the sample pots were independently inspected by two examiners. The visual characteristics of each sample pot were recorded including the presence of visible sample, coils, particle colour (white/black/red), clots and formalin colour. The association between features and representative sampling, diagnosis were calculated and inter-observer reliability was determined by the Cohen's Kappa (?) score.

Results

Over a six week period 25 patients had a total of 48 lymph nodes sampled. The macroscopic appearance for visual sample, coils, white, black and red fragments were 48 (100%), 40 (83%), 19 (40%), 2 (4%) and 45 (96%) respectively. Representative sampling was confirmed in 47 (98%) samples [13 negative; 26 malignant; 8 granulomatous]. The non-representative sample showed minimal volume with red material plus clots. Descriptive features did not correlate with representative sampling or diagnosis. Whilst there was agreement between observers over the presence of visible sample and coils (? score 1/0.8 respectively), additional features were inconsistent (? score 0.42-0.65). In five patients (10%) sampling was switched to a core needle at the discretion of the physician after an initial poor return from the standard FNA needle. Despite this, the initial FNA samples were all positive and core needle sampling added no additional value.

Conclusions

Macroscopic inspection of lymph node samples obtained by EBUS-TBNA adds little value in assessing the adequacy of the sample or any potential diagnosis. Furthermore, inter-observer variability is high to a degree that renders this method unreliable. Finally the use of core needles did not appear to add any value despite the perception of visually low yield sampling in this small sample size.

id 389

19th WCBIP / WCBE World Congress
JOINT MEETING OF THE WORLD ASSOCIATION FOR BRONCHOLOGY AND INTERVENTIONAL PULMONOLOGY & THE INTERNATIONAL BRONCHOESOPHAGOLOGICAL SOCIETY
www.wcbipwcbe2016.org
Fortezza da Basso
May 8-11, 2016
Florence (Italy)

Bronchoscopic appearance of endobronchial tuberculosis in Serbia in 13-year period

Spasoje Popevi?[1], Natalija Samardzi?[2], Živka Uskokovi?-stefanovi?[3], Milan Gruji?[3], Dragana Jovanovi?[4]

[1]Interventional Pulmonology Unit, University Hospital for Pulmonology, Clinical Center of Serbia, School of Medicine, University of Belgrade - Serbia
[2]University Hospital for Pulmonology, Clinical Center of Serbia, University Hospital for Pulmonology, Clinical Center of Serbia - Serbia
[3]Interventional Pulmonology Unit, University Hospital for Pulmonology, Clinical Center of Serbia, University Hospital for Pulmonology, Clinical Center of Serbia - Serbia
[4]University Hospital for Pulmonology, Clinical Center of Serbia, School of Medicine, University of Belgrade - Serbia

Introduction

Endobronchial tuberculosis (EBTB) is chronic, progressive tuberculous infection with infiltration of mucosa of bronchi and/or trachea which is characterized with: hyperemia, swelling, granulomatous tissue formation, occasionally ulcerations and finally, bronchostenosis, as a result of scarring formation process. Bronchoscopy plays pivotal role both in diagnosis and treatment of this condition.

Objective

The aim: To assess bronchoscopic features of endobronchial tuberculosis (EBTB) in population of Serbia in 13-year period.

Methods

Prospective clinical study is ongoing at the University Hospital for Pulmonology, Clinical Center of Serbia. In the period from 01/02/2002. to 01/12/2015. 123 cases of patients (pts) with bronchoscopy verified EBTB were analyzed.

Results

There were more men (56.9%) than women, mainly of young and middle age. In most cases endoscopic findings were not specific for tuberculosis (edematous- hyperemic, and chronic-bronchitic forms). In only 13% of pts (who had active caseating EBTB) bronchoscopic finding was indicative towards tuberculosis. In 6.5% of pts tumorous form was seen, while fibrostenotic (late) forms were present in less than 8% of pts. In 3 pts with tracheal stenosis repeated mechanical dilatation was performed, followed by stent placement in one patient with contraindications for surgery and tracheal wall involvement. In 2 patients severe inflammation lead to tracheomalatia, treated with non invasive mechanical ventilation.

Conclusions

In our population, single most frequent form of EBTB was nonspecific bronchitic one, with excellent prognosis after antituberculous treatment and complete sanation of lesions. The most complicated form, fibrostenotic, was rare, but with severe clinical course, requiring interventional procedures to maintain major airway patency.

id 390

Yield of EBUS in the normal appearing mediastinum

María Teresa Pérez-warnisher[1], Alba Naya[1], Pilar Carballosa[1], Elena Cabezas[1], Andrés Giménez[1], Iker Fernández-navamuel[2], Luis Seijo[2], Javier Flandes[2]

[1]Pulmonology, Fundación Jiménez Díaz - Spain
[2]Unit of Bronchoscopy and Interventional Pulmonology, Fundación Jiménez Díaz - Spain

Introduction
The yield of EBUS in patients with a normal-appearing mediastinum by CT or PET CT is uncertain.

Objective
To evaluate the role of EBUS in the work up of PET negative and/or subcentimeter lymph nodes in an unselected group of patients with suspected lung cancer.

Methods
We conducted a retrospective study of all EBUS procedures performed at out center between January 2010 and June 2014, including patients with subcentimeter lymph nodes and PET negative adenopathy (SUV max < 2,5). All CT studies were reviewed and maximum short axis diameter remeasured for the current study.

Results
360 patients underwent EBUS during the study period accounting for a total of 570 lymph nodes sampled. FDG uptake was available for 297 lymph nodes. Most were FDG avid (237) and only 60 sampled lymph nodes showed no FDG uptake, including 23 subcentimeter lymph nodes. Malignancy was present in 14 PET negative lymph nodes (5% of the total, and 23% of PET negative lymph nodes sampled), including: 6 lung adenocarcinomas, 3 squamous cell carcinomas, 2 undifferentiated carcinomas, 1 breast cancer metastasis, 1 neuroendocrine tumor, and 1 mesothelioma. Three of those were subcentimeter lymph nodes. An adequate sample with abundant lymphocytes was obtained in 12 of 23 subcentimeter PET negative lymph nodes.

Conclusions
EBUS is useful in the normal appearing mediastinum, detecting a significant number of malignancy in PET negative and/or subcentimeter lymph nodes.

id 391

Convex probe endobronchial ultrasound (CP-EBUS) - expanding diagnostic horizons beyond conventional

Rahul Kumar Sharma, Arjun Khanna, Vidya Nair, Deepak Talwar

Metro Centre for Respiratory Diseases, Metro Multispeciality Hospital - India

Introduction

Convex probe endobronchial ultrasound(CP-EBUS) guided transbronchial needle aspiration(TBNA) is widely accepted modality for mediastinal lymphadenopathies and central masses enabling both histopathological diagnosis and staging of malignancy. However, beyond the known indications, CP-EBUS may be used for exploration of other pathologies around central airway. We present four such cases describing unconventional clinical application of CP-EBUS.

Methods

Patient-1: A 59-year-old diabetic female, presented with breathlessness, orthopnea, cough and fever for 15days with significant weight loss over 8months. Chest X-ray showed cardiomegaly with posteriorly located pericardial effusion on echocardiography(ECHO), not amenable for ECHO guided diagnostic aspiration. EBUS guided aspiration of pericardial effusion was done by localizing the pericardium with EBUS doppler probe through anterior wall of left lower lobe bronchus above the left atrium. Straw colored pericardial fluid was aspirated using EBUS-TBNA needle(Figure 1A) which revealed lymphocytic exudative effusion with adenosine deaminase levels 92IU/L confirming the diagnosis of Tuberculosis. Patient improved on antitubercular therapy with steroids started based on EBUS guided pericardiocentesis. Patient-2: A 72-year-old female, uncontrolled diabetic, presented with cough, fever and breathlessness for 2 months. Chest X-ray revealed large cavitary lesion in right mid zone. Sputum stains and culture was negative for tuberculosis and pyogenic organisms. PET-CT revealed FDG avid thick walled cavitary lesion(8 x 7.1 x 5.3cm) with air fluid level in right upper lobe(Figure 1B). CP-EBUS guided FNA technique was applied at right secondary carina and samples were obtained directly from cavity wall after visualization, along with surrounding nodes.Cytopathology revealed reactive lymph nodes but lung cavity wall cellblock showed classical histopathological picture consistent with Mucormycosis thus clinching the diagnosis. Patient-3: A 67-year-old male, known case of diabetic nephropathy, presented with fever, hemoptysis, breathlessness and unilateral leg swelling for 6 days. Lower limb doppler showed deep vein thrombosis involving popliteal vein. ECHO showed features of corpulmonale. Due to patient's critical condition with renal failure, EBUS bronchoscopy was done. An echogenic mass was visualized in both pulmonary arteries suggestive of massive pulmonary thromboembolism(PE) and patient was thrombolysed with alteplase. Patient showed significant clinical improvement with repeat EBUS showing partial recanalization of thrombus(Figure 1C &D) thus stressing utility of EBUS in managing PE in critically ill patients.

Conclusions

CP-EBUS is a revolutionary technique with high diagnostic value and low complication risk thus enabling its use in prompt diagnosis of diverse thoracic conditions. This case series highlights innovative clinical application of CP-EBUS, thus providing a platform for exploring its potential prospects in clinical practice.

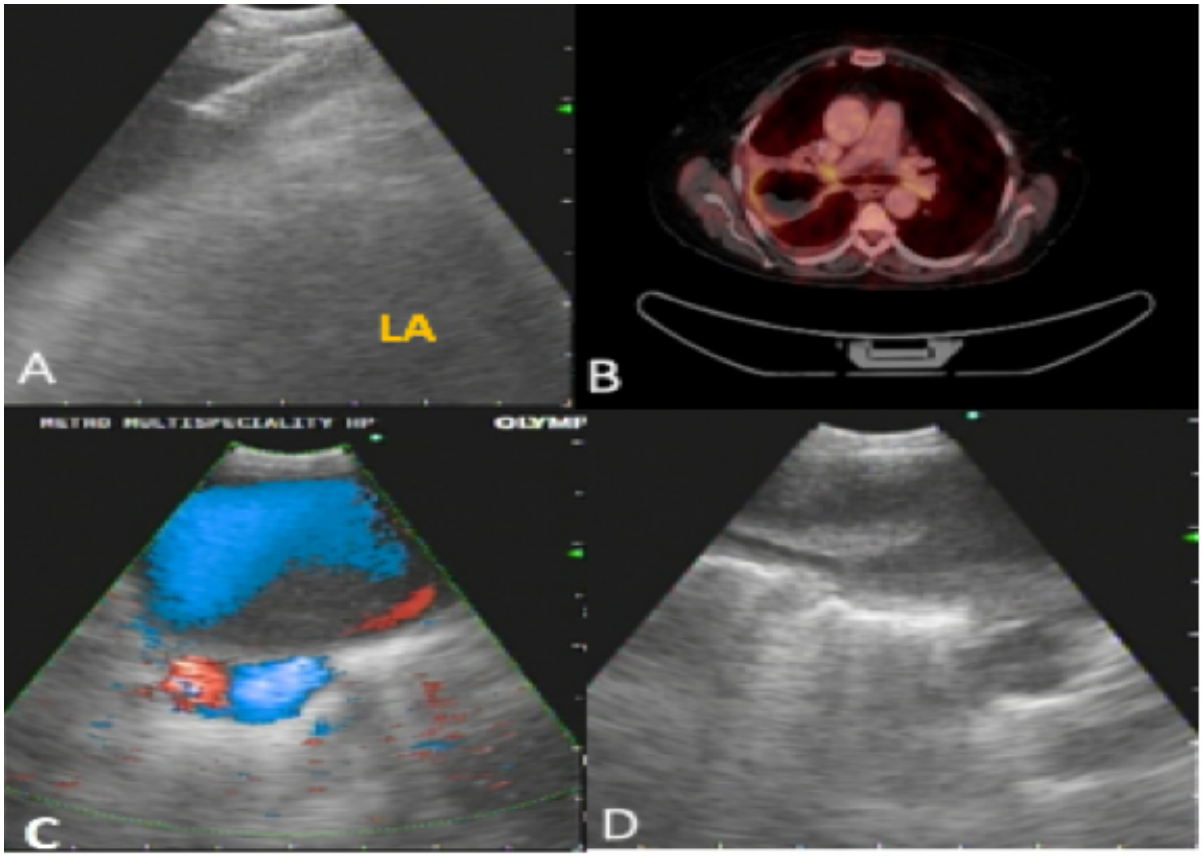

FIGURE 1: A) EBUS image of pericardial effusion seen above left atrium (LA) with EBUS-TBNA needle in-situ. B) PET-CT image showing PET avid thick walled cavity abutting the right main bronchus. C) EBUS doppler image showing inhomogenous opacity in pulmonary artery suggestive of thrombus & D) its partial resolution after thrombolysis.

id 393

Validation of classification system for ROSE performed during lung and mediastinal needle biopsy

Alessandro Di Marco Berardino[1], Martina Bonifazi[2], Maurizio Ferretti[3], Lina Zuccatosta[2], Federico Mei[2], Michele Sediari[2], Stefano Gasparini[2]

[1]Struttura Complessa di Pneumologia, Ospedale S. Bassiano - Italy
[2]Pulmonary Diseases Unit, Department of Internal Medicine, Azienda Ospedali Riuniti - Italy
[3]Departement of Cytology, Azienda Ospedali Riuniti - Italy

Introduction

Rapid On-Site Evaluation (ROSE) of transbronchial and percutaneous aspirations plays a relevant role in the diagnostic work-up of lung lesions and mediastinal lymph nodes/masses. To date, the only available classification system for cytological specimens of respiratory tract was proposed by the Papanicolau Society in 1999, identifying 5 diagnostic categories (C1-C5, C1: not diagnostic specimen/inadequate material; C2: specific benign lesion; C3 doubt, probably benign; C4 doubt, suspicious of malignancy; C5: malignant lesion lesion), however, the role of this classification for definite cytological diagnosis as well as for ROSE evaluation has yet to be established.

Objective

The purpose of the present study is to evaluate the concordance between the ROSE evaluation and definitive cytological diagnosis, according to the classification system C1-C5.

Methods

This is an observational retrospective study, based on electronic medical records review. Every patient who was referred to the Pulmonary Diseases Unit (Azienda Ospedaliero-Universitaria Ospedali Riuniti of Ancona, Italy) between January 2000 and December 2013 for transbronchial or percutaneous diagnostic approach and underwent ROSE evaluation of specimens was enrolled in the study. The concordance between ROSE and the final cytological diagnosis, both expressed according to C1-C5 by an experienced cytopathologist, was analyzed through Cohen’s Kappa statistics.

Results

Overall, 2127 patients (mean age 66.83) were included in the present study. The The overall unweighted and weighted Cohen's kappa coefficient between ROSE and and final diagnosis was good, respectively 0.79 and 0.88. Results by cat categories showed the best Cohen’s Kappa for C5 (0.9). According to histotype ass assessment, Cohen’s Kappa was 0.72. Concordance between ROSE and definitive diagnosis, in order to define the pr presence of malignity, is negatively influenced by presence of squamous cell ca carcinoma (p: 0.004; OD: 0.29); non-small cell lung cancer (p: 0.033; OD: 0. 0.46) and large cell lung cancer (p: 0.014; OD: 0.26). Concordance of “ ROSE C1-C5 classification” and definitive C1-C5 c classification, is positively influenced by the presence of non-diagnostic p pattern (p: 0.005; OD: 1,90, and negately by performing two or more p procedures during the same exam (p: 0.015; OD: 0.58), the use of EBUS (p: 0 0.052; OD: 0.46) and the diameter of parenchymal lesions (p: 0.049; OD: 0.99).

Conclusions

In conclusion, the present study suggests that the classification system C1-C5 may represent a reliable and valuable tool for providing standardized information on cytological evaluation in the context of ROSE. Further studies are needed to better explore the potential role of this system in a decision- making process, as it happens in other specialties.

id 394

Experience in airway stenting for malignancy

Syazatul Syakirin Sirol Aflah

Respiratory Department, Hospital Alor Setar - Malaysia

Introduction

The service of intervention bronchoscopy which involve rigid scope is still a newbie performed by respiratory physician in Northern part of Malaysia. Interventional therapeutic bronchoscopy with airway stenting provides an immediate and effective palliation and therefore is essential to improve quality of life in advanced malignancy cases. Ultimately the gold standard treatment for airway obstruction is surgical resection and reconstruction. However, most patients with airway obstruction due to malignancy are poor surgical candidates due to the basis of advanced disease.

Methods

We report our experience with 2 cases which undergone rigid bronchoscopy and airway bronchial stenting using silicon stent under general anaesthesia. Case 1 A 53 year old man who was an ex smoker presented with cough,fever and constitutional symptoms. His chest X Ray showed a mass on the right upper lobe. CT thorax showed a mass on the right upper lobe and compressing right main bronchus with ribs infiltration. He was treated for obstructive pneumonia in view of fever with antibiotics. A flexible bronchoscopy was done which showed a narrowed lumen of the right main bronchus and scope managed to pass through the partially obstructed right main bronchus and demonstrated patent of middle and lower lobes. A bronchus airway silicon stent was inserted to right main bronchus under rigid bronchoscopy. He did not developed any immediate complication post stent insertion.The result of histopathological examination read as squamous cell carcinoma. Post stent insertion he undergone two surveillance bronchoscopy in which showed the patency of the airway stent. He was planning for local radiotherapy to the mass then subsequently palliative chemotherapy. Case 2 A 59 year old Malay Male who was an ex smoker , diagnosed with squamous cell carcinoma of the oesophagus. On the CT Thorax showed left bronchus invasion besides esophageal tumor. A flexible bronchoscopy done noted narrowed lumen in left main bronchus. An airway silicon stent was inserted on the left main bronchus under rigid bronchoscopy.His chest XRay showed left lung collapse. A bronchoscopy done post stent insertion which the stent had blocked at the left lower lobe. Subsequently stent readjustment was done and patient had undergone treatment for the oesophagus cancer treatment.

Conclusions

Due to the aetiology especially malignancy causing airway obstruction, the patients are often poor surgical candidates .Fortunately, non-resectable lung cancer can be successfully treated with interventional rigid bronchoscopy to restore airway patency using debulking and/or dilatation techniques mainly for symptoms relief.

Bibliography

1. Chin CS Airway stents. Ann Thorac Surg 2008;85:S792-S796 2. Stohr S, Bolliger CT. Stents in the management of malignant airway obstruction Dis 1999;54:264-268.

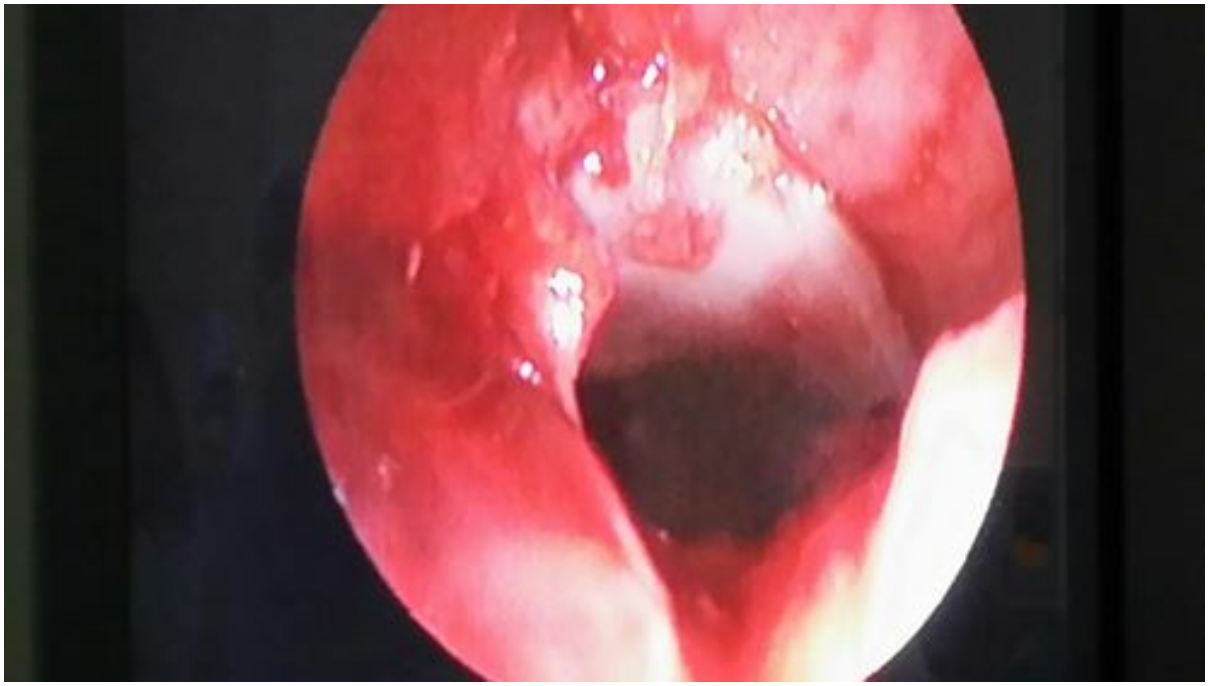

id 395

TBNA/TBB in peripheral pulmonary lesion: 1 year experience in a Hub Italian Hospital (Udine)

Paolo Vailati[1], Giuseppe Morana[1], Salvatore Distefano[1], Alessandro De Pellegrin[2], Emilio Lugatti[1]

[1]Pneumology, General University Hospital "Santa Maria della Misericordia" - Italy
[2]Anatomic Pathology, General University Hospital "Santa Maria della Misericordia" - Italy

Introduction

TransBronchial Needle Aspiration (TBNA) alone vs. TransBronchial Biopsy (TBB) in the diagnosis of peripheral pulmonary nodules/masses is highly debated due to the variability between centers and the non-uniform access to dedicated technologies (eg. ultrasound probe, fluoroscopy). In our Institution, all peripheral lesions are investigated with an endobronchial approach; if a convincing image (eco and/or radiological) is detectable, TBNA is performed first. The adequacy judgement given with the Rapid On Site Evaluation (ROSE) by the pathologist allows to omit the TBB. Nevertheless, when material seems to be not adequate for pathologist or bronchoscopist, TBB is performed.

Objective

The aims of this study is to assess the results of one year experience in our Institution, in order to compare us to the literature and to optimize the operational choices in the Integrated Care Pathway (ICP), especially for the goal of molecular panel.

Methods

We performed a retrospective study focused on the activities of the last year considering all TBNA alone or TBNA plus TBB. We extracted 69 patients distributed as follows: 20F and 49M (average age 69.26; range: 46-89); average size of lesions was 41.6 mm (range: 5-120). The following diagnostic tools were used: bronchovideoscope (Olympus), radial ultrasongraph probe, image intensifier, rapid cytology stains.

Results

In table, final histopathology diagnosis has been shown. The overall diagnostic accuracy was 81.16% (77.42% with ROSE; 84.21% without ROSE) with a sensitivity of 100% and specificity of 86%. For TBB+TBNA alone, diagnostic accuracy was of 87.18%. For the only TBNA, diagnostic accuracy was of 73.33% (76.47% with ROSE; 69.23% without ROSE). When TBB was performed, a diagnosis has been established in 6 cases of 11 with non-diagnostic cytology report. In all case diagnosed as non-squamous NSCLC was possible to run the full molecular panel expected by ICP (EGFR-KRAS-ALK). In none case were highlighted major complications due to the procedure.

Conclusions

In our experience, TBNA as single procedure is safe and reliable in order to get all the data required for current standard of care (target-therapy); the best accuracy is obtained with ROSE. In non diagnostic aspiration cytology, TBB allowed to have a definitive diagnosis, in over one half of all cases. The routine use of TBNA and ROSE for the sampling of peripheral pulmonary lesions may be sufficient to obtain a correct and complete diagnosis and to reduce the known risks related to TBB.

Adeno	Carcinoid	LCNEC	Metastasis	Negative	Not diagnostic	NSCLC	SCLC	Susp.	SCC	Total
30	1	1	3	7	13	3	2	3	6	69

id 396

19th WCBIP / WCBE World Congress
JOINT MEETING OF THE WORLD ASSOCIATION FOR BRONCHOLOGY AND INTERVENTIONAL PULMONOLOGY & THE INTERNATIONAL BRONCHOESOPHAGOLOGICAL SOCIETY
www.wcbipwcbe2016.org
Fortezza da Basso
May 8-11, 2016
Florence (Italy)

Cryobiopsy increases EGFR detection rate in endobronchial visible non-small cell lung cancer

Hetzel Juergen[1], Boeckeler Michael[1], Ehab Ahmed[1], Wagner Robert[2], Spengler Werner[1], Oberle Almut[1], Steger Volker[3], Boesmueller Hans[4], Bonzheim Irina[4], Fend Falko[4], Kanz Lothar[1], Haentschel Maik[1]

[1]Department of Internal Medicine II, University of Tuebingen - Germany
[2]Department of Internal Medicine IV, University of Tuebingen - Germany
[3]Department of Thoracic and Cardiovascular Surgery, University of Tuebingen - Germany
[4]Institute of Pathology and Neuropathology, University of Tuebingen - Germany

Introduction

Detection of activating epidermal growth factor receptor (EGFR) mutation is crucial for individualized treatment of advanced non-small-cell lung cancer (NSCLC), leading to an improved overall survival in some cases. Apart from sensitive detection techniques for EGFR mutation sufficient and representative tumor tissue forms the basis for correct analysis. Nevertheless the comparison of different sampling techniques is limited. Today forceps biopsy is the most often used bronchoscopic biopsy technique while bronchoscopic cryobiopsy excels with its higher diagnostic yield.

Objective

We conducted a retrospective single center study to evaluate the detection rate of EGFR mutations obtained by different sampling techniques. In this setting we focused on the comparison of bronchoscopic forceps biopsy with bronchoscopic cryobiopsy with a glance on centrally localized NSCLC.

Methods

We analyzed 420 consecutive specimens between 3/2008-7/2014 of pathologically confirmed NSCLC and determined EGFR mutation status by Sanger sequencing. Excluding surgical and imaging guided transthoracic techniques as well as bronchoscopic fine needle aspiration cytology 99 cases of bronchoscopic forceps biopsy were compared with 126 cases of bronchoscopic cryobiopsy. In addition we focused on different localizations of the tumor.

Results

Cryobiopsy in the central airway detected 23 (21.3%) activating EGFR mutations in in 108 patients while forceps biopsy detected only 3 (6.4%) in 47 patients with central airway tumors (p=0.0332). There was no difference in the detection rate between both techniques in the case of transbronchial tumor biopsies (cryobiopsy 27,8% vs. forceps 26,9%).

Conclusions

These results indicate that the biopsy technique plays a central role in the detection of EGFR mutations. Especially in central localized tumors cryobiopsy increased mutation detection significantly compared to forceps biopsy. This may explain response to tyrosine kinase inhibitor (TKI) treatment of EGFR wild type declared NSCLC patients. As a consequence further prospective studies are needed focusing on differences in tumor tissue sampling techniques to assure correct EGFR mutation detection for optimized individualized treatment of patients with advanced tumors.

The presenting author has the following conflicts of interest that relate to this abstract: *Honorarium for presentation and workshop (Erbe Elektromedizin GmbH, Tuebingen, Germany)*

Endobronchial Stents in malignancy and 1 month post-procedure survival

Carla Simao, Carolina Sousa, Luciana Bento, Rui Costa, Hedi Liberato, Jose Boleo-tome, Fernando Rodrigues

Pulmonology Department, Hospital Prof. Doutor Fernando da Fonseca EPE - Portugal

Introduction

Advances in interventional bronchology have allowed for better palliative care of patients with malignancies and endobronchial obstruction. Although bronchial stenting is not a curative therapy, it can improve dyspnoea and quality of life.

Objective

The primary endpoint of this study was to evaluate survival at one month after stenting of the airways in patients with malignant neoplasms. The secondary endpoints were to characterize patients submitted to airway stenting and to evaluate intervention-related complications.

Methods

Descriptive, retrospective study case files of patients submitted to endobronchial stent placement due to malignant airway obstruction, in a 3-year period (2013-2015).

Results

Forty-two patients were included, with a mean age of 63 years-old and male predominance (80,9%). Most patients (78,6%) had a previous lung cancer diagnosis, and the most frequent histologic type was squamous cell carcinoma. The remainder patients had gastrointestinal tract malignancies, mainly squamous cell esophageal carcinoma. The majority of cases (76,2%) were stage IV ate the time of the procedure. The trachea was involved in 17 cases (40,5%). Concerning survival, 71% of patients were still alive one month after the procedure. All patients with less than 1 month survival all had luminal obstruction of more than 70%. Of these, six patients had the stent placed at the time of diagnosis. The main complications (21,4%) were moderate local bleeding in close association with the tumor (n=4), global respiratory failure (n=2) that resolved with non-invasive ventilation, and bronchial wall laceration (n=3) which in two cases led to pneumomediastinum and need for mechanical ventilation. Fifteen patients (35,7%) needed reintervention and the main indications were hemoptysis (n=5) and tenacious secretions needing aspiration (n=5). The remainders were tumor progression (n=4) and stent displacement (n=1).

Conclusions

Endobronchial stenting is a palliative procedure that should be offered to patients with significant or symptomatic malignant bronchial obstruction. Survival at one month post-procedure was high. Mortality within the first month may be related to advanced stage of the disease ate the time of diagnosis and intervention.

id 399

19th WCBIP / WCBE World Congress
JOINT MEETING OF THE WORLD ASSOCIATION FOR BRONCHOLOGY AND INTERVENTIONAL PULMONOLOGY & THE INTERNATIONAL BRONCHOESOPHAGOLOGICAL SOCIETY
www.wcbipwcbe2016.org
Fortezza da Basso
May 8-11, 2016
Florence (Italy)

New endoscopic technique for the treatment of complete tracheal stenosis

Mauricio Cespedes Roncancio3, Mauricio Gonzalez Urrea, Manuel Conrado Pacheco, Alberto Franco, Jose Luis Blanco, Diana Neitza Aristizabal

Pneumology and Respiratory Endoscopy, RESPIREMOS SAS. Clinica Comfamiliar - Pereira (Colombia). Clinica San Rafael – Pereira (Colombia). Clinica Saludcoop – Pereira (Colombia) - Colombia

Introduction

Tracheal stenosis is a frequent complication following orotracheal intubation and/or tracheostomy. It results from the repair and healing effects of the injured mucosa. This process gives rise to tissue proliferation and narrowing of the tracheal lumen, which determines symptom severity. In the event of complete stenosis, a definitive tracheostomy is required, and the only option is end-to-end tracheal resection, but this procedure may be contraindicated, depending on the location, extent and comorbidities, among other things. Endoscopic techniques are the treatment of choice in referral centres where interventional pulmonology is available, but reports supporting their use as primary options are still lacking.

Methods

Our series consists 38 adult cases and 1 paediatric case of complete subglottic stenosis and aphonia, followed between 2009 and 2016 in three hospitals in Pereira, Colombia. All patients had undergone definitive tracheostomy and lost their ability to speak. A rigid bronchoscope was passed underneath the vocal cords and above the complete tracheal stenosis. After removal of the tracheostomy cannula, a Schieppati needle was used to perforate the centre of the occluding membrane, and an initial proximal- to-distal communication was obtained. Jackson dilators were then used for dilatation and the residual tissue was removed with the help of laser and the rigid bronchoscope, achieving complete airway patency. A Dumon subglottic tracheal stent was placed immediately under the vocal cords, maintaining the tracheal lumen and covering the tracheostomy orifice at the same time.

Results

All patients were treated successfully, they all recovered speech right away, and the patency of the airway was maintained. No relevant complications were observed (6 out of 38 patients developed tracheitis late into the postoperative period and they were treated on an outpatient basis). Follow-up ranged between 6 years (first patient) and 1 month (last patient) and included clinical assessment, computed tomography, bronchoscopy and pulmonary tests.

Conclusions

This procedure is effective, less invasive, free of contraindications, and requires less surgical time. It entails a lower surgical risk, minimal operative complications, and allows recovery of airway patency, speech, and neck cosmesis. It improves quality of life and lowers costs. The complications of open surgery may be life-threatening. A review of the literature was conducted, no reports were found of series using this method or any similar method to the one reported here. More patients are expected to enter the study with a longer follow-up period that will enable us to obtain additional data and confirm the data collected thus far.

id 400

19th WCBIP / WCBE World Congress
JOINT MEETING OF THE WORLD ASSOCIATION FOR BRONCHOLOGY AND INTERVENTIONAL PULMONOLOGY & THE INTERNATIONAL BRONCHOESOPHAGOLOGICAL SOCIETY
www.wcbipwcbe2016.org
Fortezza da Basso
May 8-11, 2016
Florence (Italy)

Endoscopic treatment of tracheomalacia: new technique using electrocautery and/or laser

Mauricio Cespedes Roncancio3, Mauricio Gonzalez Urrea, Alberto Franco, Manuel Conrado Pacheco Gallego, Jose Luis Blanco, Diana Neitza Aristizabal

Pulmonology and respiratory endoscopy, RESPIREMOS SAS. Clinica Comfamiliar. Clinica San Rafael. Clinica Saludcoop - Colombia

Introduction

Tracheobronchomalacia is a disease characterized by narrowing of the tracheal and bronchial lumen secondary to wall weakness and airway collapse during the different respiratory phases. Common chronic symptoms include cough, expectoration, dyspnea, recurrent respiratory infections and chest tightness. It is associated with hypoxemia, hypercapnia and alveolar hypoventilation, and may progress to severe respiratory failure and death. It is observed in adults and elderly patients with a history of smoking who have been misdiagnosed. Diagnosis requires a high degree of suspicion and it is confirmed using fiberoptic bronchoscopy or dynamic computed tomography. Standard treatment includes pharmacological management of the associated disorders. Tracheobronchoplasty of the posterior wall using polypropylene mesh reinforcement is a high-risk surgical procedure, rarely performed at present. Tracheal and tracheobronchial silicone stents have been used in patients with high surgical risk. However, this procedure is associated with complications such as dislodgement, obstruction and over infection.

Methods

Between 2009 and 2016, 42 adults were diagnosed with tracheobronchomalacia type III-IV in three institutions in Pereira, Colombia. Electrofulguration with monopolar electrode at 15 watts or continuous Diode laser therapy at 10 watts were used to treat the posterior membranous wall of the trachea and bronchi under general anaesthesia and bronchoscopy. The objective of this technique is to create scarring and fibrosis of the wall to make it stronger. Oxygen supplementation was used at FiO2 <40% as a precaution to prevent fire in the airway.

Results

Immediate improvement of the disease was observed in all patients during the procedure with reduced collapse, a reduction in the cross-sectional diameter and increase in the anteroposterior diameter of the trachea and bronchi. Moreover, there was a significant reduction in posterior wall movement. Patients were transferred to the intensive care unit by protocol, but no ventilation support was required. Clinical follow-up, blood gases, pulmonary function tests, dynamic computed tomography and bronchoscopy were used as the gold standard approach to diagnosis and follow-up. There were no serious complications affecting the airway, such as tracheoesophageal fistula or pneumomediastinum, for example.

Conclusions

This technique helps achieve clinical, tomographic, endoscopic, functional and spirometric improvement in all treated patients. It is performed in one surgical stage, reducing anaesthetic and surgical risk. It is safer and has a lower incidence of complications when compared to stenting and tracheobronchoplasty, which are associated with a high incidence of morbidity and mortality. Quality of life and respiratory function were also shown to improve.

id 401

19th WCBIP / WCBE World Congress
JOINT MEETING OF THE WORLD ASSOCIATION FOR BRONCHOLOGY AND INTERVENTIONAL PULMONOLOGY & THE INTERNATIONAL BRONCHOESOPHAGOLOGICAL SOCIETY
www.wcbipwcbe2016.org
Fortezza da Basso
May 8-11, 2016
Florence (Italy)

Endoscopic treatment of supraestomal tracheal granuloma

Mauricio Cespedes Roncancio3, Mauricio Gonzalez Urrea, Alberto Franco, Manuel Conrado Pacheco Gallego, Jose Luis Blanco, Diana Neitza Aristizabal

Pulmonology and respiratory endoscopy, RESPIREMOS SAS. Clinica Comfamiliar. Clinica San Rafael. Clinica Saludcoop - Colombia

Introduction

Tracheostomy is performed in patients with multiple indications including, among others, prolonged mechanical ventilation, severe respiratory failure and compromised consciousness. Conventional open surgery or different percutaneous techniques are used at present. The implantation of the tracheostomy cannula is associated with complications such as granuloma formation on the upper edge of the tracheostomy orifice. Granulomas may be of different sizes, and lead to partial or complete obliteration of the tracheal lumen and failed cannula removal.

Methods

Retrospective and descriptive study conducted between 2009 and 2016 in 28 patients with tracheostomy occlusion and failed cannula removal in three institutions in Pereira, Colombia. The presence of peristomal granulomas and tracheal lumen obstruction was confirmed under bronchoscopy. The granulomas occluded the prosthetic fenestration of the prosthesis preventing speech and removal of the cannula. The first management option was endoscopic treatment consisting of advancement of the rigid bronchoscope down to the subglottic region, immediately above the granuloma. Granulomas were removed completely in all the patients using a combination of Diode laser photocoagulation or electrocoagulation with monopolar electrode and resection/cutting with the distal (bevelled) end of the rigid bronchoscope (video). Definitive removal of the tracheostomy cannula was then achieved. The main objective is to analyse the results obtained using the endoscopic technique.

Results

With our technique, thermal cytoreduction of the granuloma was achieved with the use of electrocautery or laser, and tissue coagulation. Moreover, there was less bleeding during sharp resection. Immediate improvement of the tracheal obstruction was observed, restoring 100% of the tracheal lumen, and the tracheostomy cannula was removed successfully. There were no serious complications, respiratory failure, bleeding or death. All patients recovered adequate speech and they only reported mild cervical pain. Spirometry was normal in those patients that were able to perform it, and the one-month follow- up bronchoscopy was practically normal, showing no recurrent granulomas or significant stenosis from the scar. (Video)

Conclusions

Peristomal tracheal granulomas are a frequent complication following tracheostomy, regardless of the technique used. There is variability regarding the percentage of their occurrence in the published reports. However, this complication is notoriously underdiagnosed, making it our duty to improve postoperative follow-up in order to recognize the severity and frequency of its occurrence. Diagnostic bronchoscopy is mandatory. The technique proposed is safe and effective, with a good success rate. No recurrences or significant stenosis were observed on endoscopic follow-up.

id 402

19th WCBIP / WCBE World Congress
JOINT MEETING OF THE WORLD ASSOCIATION FOR BRONCHOLOGY AND INTERVENTIONAL PULMONOLOGY & THE INTERNATIONAL BRONCHOESOPHAGOLOGICAL SOCIETY
www.wcbipwcbe2016.org
Fortezza da Basso
May 8-11, 2016
Florence (Italy)

Optimising the specificity of PET-CT for mediastinal and hilar lymph nodes to guide EBUS-TBNA

Koliarne Tong[1], Peter Wu[1], Socrates Angelides[2]

[1]Department of Respiratory and Sleep, Westmead Hospital - Australia
[2]Department of Nuclear Medicine, PET and Ultrasound, Westmead Hospital - Australia

Introduction

Endobronchial ultrasound-guided transbronchial ultrasound (EBUS-TBNA) and positron emission tomography-computed tomography (PET-CT) are critical in the staging the mediastinum in non- small cell lung cancer (NSCLC). However, the specificity of PET-CT in assessing the malignancy status of a mediastinal or hilar lymph node is relatively low at around 81%1. Improving the specificity of PET-CT for malignancy status of mediastinal and hilar lymph nodes would reduce false positives, and hence facilitate the avoidance of unnecessary EBUS-TBNA procedures. Total lesion glycolysis (TLG), which is the metabolic tumour volume (MTV) multiplied by the SUVmean, has proven to be useful in prognostication of NSCLC, but to our knowledge has not been used to predict malignancy status of lymph nodes2.

Objective

To determine if the use of TLG can improve the specificity of PET-CT analysis in predicting the malignancy status of mediastinal and hilar lymph nodes in NSCLC.

Methods

A retrospective analysis of patients with NSCLC who underwent EBUS-TBNA and PET-CT between January 2012 and December 2014 was performed. An experienced nuclear medicine physician measured the PET-CT MTV and TLG of mediastinal and hilar lymph nodes sampled via EBUS- TBNA. The malignancy status of the lymph node was determined by the EBUS-TBNA histopathology, or results of surgical sampling when this was performed. A receiver operating characteristic curve was generated to determine the optimal TLG cut-off, and the accuracy of the test.

Results

A total of 40 patients who met the study criteria were identified. Three patients were excluded because of insufficient tissue sampled, and one was excluded because the mediastinum was not FDG-avid on PET-CT. A total of 39 mediastinal and hilar lymph nodes were included for analysis. Using a cut-off TLG of 5,000, the diagnostic sensitivity of PET-CT was 93% and the specificity was 92%. The positive predictive value was 88%, while the negative predictive value was 96%. A receiver operating characteristic curve generated showed good accuracy of TLG, with an area under the curve of 0.85.

Conclusions

The TLG may be a helpful tool in determining the malignancy potential of mediastinal and hilar lymph nodes in NSCLC, in particular by increasing the positive predictive value and specificity of PET-CT analysis. This in turn would facilitate the avoidance of unnecessary EBUS-TBNA procedures and the associated healthcare costs. Prospective studies will be required to for further evaluation of this novel tool.

Bibliography

1. Fischer BM et al. Thorax 2011; 66(4): 294-300. 2. Chen HH et al. Radiology 2012; 264(2): 559-66.

Takotsubo syndrome after flexible bronchoscopy

Fausto Leoncini, Stefano Corsi, Marco Trigiani, Michela Bezzi

Interventional Pulmonology, Department of CardioThoracic and Vascular disease, University Hospital Careggi - Italy

Introduction

Takotsubo cardiomyopathy (TCM) is a transient cardiac syndrome that mimics acute myocardial infarction and is characterized by acute apical ballooning with systolic left ventricular (LV) dysfunction in the absence of significant coronary artery disease. It occurs predominantly in postmenopausal women following intense emotional or physical stress. We report a case of acute anterior ST-segment elevation and transient LV failure during diagnostic flexible bronchoscopy.

Methods

A 75 year-old female without history of heart disease was admitted to our hospital for increasing dyspnea, cough and transient right-sided chest pain. Mild hypoxemia was detected and laboratory tests revealed only mild signs of systemic inflammation, no troponin elevation. Electrocardiogramand echocardiogram were normal,the chest CT-scan showed a mediastinal mass (15x10x8 cm) extended along the visceral, mediastinal and costal pleura. The tumor caused compression of the inferior caval vein (preatrial tract), as well as of the right broncho-vascular structures. Routine premedications (midazolam, 2 mg IV; 2% lidocaine gargling) were administered before the procedure. During the procedure vital functions were monitored and remained stable. The bronchoscopy showed infiltration of the right main bronchus and of the right upper lobe bronchus while the middle lobe bronchus was obstructed by avegetationTransbronchial needle aspiration (TBNA) in station 4R was performed, followed by moderate bleeding and the middle lobe lesion was biopsied with considerable bleeding. The procedure was interrupted for the sudden onset of chest pain, cold sweat and wheezing with transient ST-T elevation in ECG leads V4-V6.After about 30 minutes the ECG was normal, but the patient still hadprecordial pain. A transthoracic echocardiogram revealed apical ballooning and a severely reduced left ventricular ejection fraction (EF 35%).Troponin peak reached 1.34 µg/L. Coronary angiography was then performed which ruled out significant coronary disease. Several echocardiograms were then performedwith progressive recovery of left ventricular systolic function(EF 60%). Histological examination revealed small-cell lung cancer.

Conclusions

Takotsubo cardiomyopathy is a rare complication of flexible bronchoscopy and has an excellent prognosis. Patients present with signs and symptoms similar to acute coronary syndrome with normal coronary angiography. Catecholamine cardiotoxicity is the most likely causative mechanism. Typically, echocardiography shows acute left ventricular systolic dysfunction sparing only the base of the heart and may be complicated by heart failure. Supportive treatment is the mainstay of therapy.

Bibliography

Kyeong Sam Ok, et al. Heart, Lung and Circulation 2011;20:476–478 Guerrero J, et al. Chest. 2007;132(4_MeetingAbstracts):674a.

id 404

Bronchial obstruction following inhalation of an Iron pill

Astrid Bertier[1], Stephanie Cousse[2], Samy Lachkar[2], Mathieu Salaun[2], Luc Thiberville[2]

[1]Clinique Pneumologique, Charles Nicolle - Frnace
[2]Clinique Pneumologique, Charles Nicolle - France

Introduction

Bronchial inhalation of a ferrous sulfate pill leads to severe caustic lesions of the bronchial wall due to local liberation of cytotoxic oxidants radicals. The lesions can be responsible for bronchial stenosis or even necrosis with bronchial perforation.

Methods

We report the case of a 79 year-old woman presenting a thoracic pain following inhalation of a ferrous sulphate pill. Initial chest radiography showed a basal right atelectesis that was confirmed by CTscan. Initial bronchoscopy showed an extensive inflammatory stenosis with black iron deposits lesion of the intermediate bronchus and origin of the medial bronchus. Abondant bronchial lavage completed by mecanical removal of iron deposits was realized. The endoscopic controls at week 1, 2 and 6 were initially favorable with stability of the bronchial lesion under corticosteroids, antibiotic therapy and mucolytics. The evolution was marked by recurrence at 5 months , on the control CTscan and bronchoscopy, of a complete occlusion of the intermediate bronchus due to an inflammatory fibrinous process with metallic deposits, leading to the middle bronchus atelectasis. Corticosteroid treatment was re-introduced for a 2 weeks period, reversing the atelectasis, whereas the bronchial stenosis required endoscopic balloon dilatiaton. Endoscopic control after dilatation was satisfactory allowing passage of a 5mm fiberoptic bronchoscope and reversal of the atelectasis, with a 3 month follow-up without further intervention.

Conclusions

Extensive bronchial stenosis and wall perforation after ferrous pill inhalation often leads to surgery (1). The favorable outcome of the bronchial stenosis in this case was probably related to the early bronchoscopic intervention

Bibliography

Babatasi G, The Journal of Thoracic and Cardiovascular Surgery ;112 :1397-9.

id 405

19th WCBIP / WCBE World Congress
JOINT MEETING OF THE WORLD ASSOCIATION FOR BRONCHOLOGY AND INTERVENTIONAL PULMONOLOGY & THE INTERNATIONAL BRONCHOESOPHAGOLOGICAL SOCIETY
www.wcbipwcbe2016.org
Fortezza da Basso
May 8-11, 2016
Florence (Italy)

The role of rigid bronchoscopy in the diagnosis and treatment of lung central tumors

Domenico Aronne[1], Luciano B.g. Montella[1], Paola Martucci[1], Raffaela Giacobbe[1], Ediva Myriam Borriello[1], Gianluca Guggino [2], Roberto Monaco[3], Maria Miano[4], Bruno Del Prato[1]

[1]Endoscopia bronchiale ed urgenze broncopneumologiche, Ospedale Antonio Cardarelli - Italia
[2]Chirurgia Toracica, Ospedale Antonio Cardarelli - Italia
[3]Anatomia Patologica, Ospedale Antonio Cardarelli - Italia
[4]Anestesia e Rianimazione, Ospedale Antonio Cardarelli - Italia

Introduction

Laser-assisted rigid bronchoscopy has shown worldwide utility in the treatment of malignant neoplasm growing inward the airways. In fact rigid bronchoscopy is helpful in recanalize obstructed tracheobronchial airways, identify site attachment to tracheobronchial wall, address any surgical procedure, in addition to characterize the histological features of the lesion.

Objective

The aims of the present report is to provide a contribute to therapeutic effectiveness of rigid bronchoscopic procedures in the treatment of endobronchial tumors.

Methods

We describe the case of a 74 years old woman, no-smoker, not affected by other relevant pathologies, who came to our attention in October 2015 complaining chest pain and exertional dyspnea arisen from few weeks. X-rays and thoracic CT scan revealed complete lung atelectasis of the upper right lobe. We performed a flexible bronchoscopy in which we observed an extended exofitic mass with moriform aspect. This lesion appeared to develope from the upper right bronchus, infiltrate its walls, and obstruct the main right bronchus totally. Therefore, flexible bronchoscopy was converted into a rigid procedure. Laser devascularisation was realized and the mass was successfully extracted after debulking. At the end of the procedure, main right bronchus, intermediate, middle, and lower right bronchi were recanalized while right upper bronchus remained persistently obstructed by the lesion. Approximately 2 weeks later, patient underwent surgical intervention of right upper lobectomy. It is noteworthy that histological examination of endoscopic specimens showed a bronchial papilloma with angiomatoid aspects, while surgical specimens revealed a combined carcinoma NSCLC (squamous and adenocarcinoma).

Results

In this case, the endoscopic resection of the endobronchial mass has allowed a limited surgical intervention of lobectomy instead of pneumonectomy. Indeed, the endoscopic cytoreduction of the neoplasm has permitted the access to surgery with radical intent.

Conclusions

About 30% of all lung cancers present with neoplastic bronchial obstruction, and about 35% of all lung cancer patients will die from local intrathoracic complications, such as hemoptysis, respiratory infections and asphyxia. Local tumor control by endoscopic procedures with rigid bronchoscope should therefore not only lead to palliation, but also to improved survival, and, if possible, allow access to surgery with radical intent.

Bibliography

Bollinger C.T., et al. Therapeutic bronchoscopy with immediate effect: laser, electrocautery, argon-plasma coagulation and stent. Eur. Resp. J. 2006; 27 (6:1258-71).

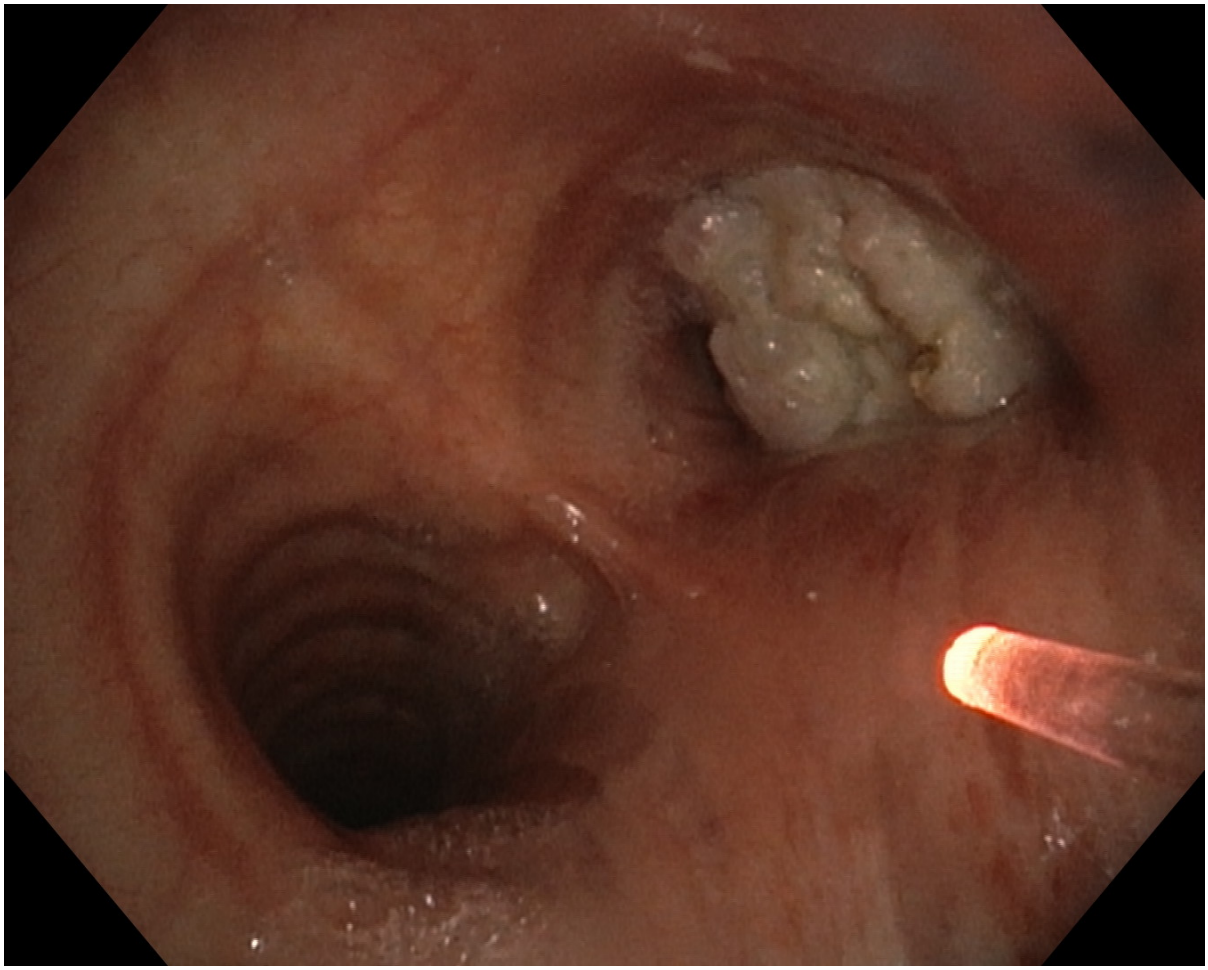

id 406

19th WCBIP / WCBE World Congress
JOINT MEETING OF THE WORLD ASSOCIATION FOR BRONCHOLOGY AND INTERVENTIONAL PULMONOLOGY & THE INTERNATIONAL BRONCHOESOPHAGOLOGICAL SOCIETY
www.wcbipwcbe2016.org
Fortezza da Basso
May 8-11, 2016
Florence (Italy)

Echographic difference of benign and malignant mediastinal lymph node in patients with lung cancer

Marco Damin[1], Silvia Zagallo[2], Umberto Fantoni[3]

[1]Pneumologia, unità di pneumologia interventistica, Azienda ospedaliera Università di Padova - Italia
[2]Pneumologia, Azienda Ospedaliera Università di Padova - Italia
[3]Pneumologia Unità di Pneumologia Interventistica, Azienda Ospedaliera Università di Padova - Italia

Introduction

The therapeutic approach of lung cancer involves the measurement of tumor (T), lymph nodes (N) and metastases (M). Endobronchial ultrasound (EBUS) and transbronchial needle aspiration (TBNA) are techniques used for ilar and mediastinal lung cancer staging.

Objective

To compare the EBUS characteristics of metastatic or not-metastatic lymph node in patients with lung cancer

Methods

This observational study has been conducted in lung cancer patients underwent to EBUS-TBNA for diagnosis and staging. EBUS size (short axis), shape (triangular, oval, round, confluent) , ecogenecity (hypo-, iso-, hyper-), margin (distinct-indistinct) were examined. This EBUS variables were compared in patients with positive TBNA and negative TBNA.

Results

The study includes 22 patients. At the CT scan size of the lymph nodes are variable: short axis from <1 cm to > 4 cm. Lymph node stations include 4R, 4L , 7, 10R and 10L stations. In 19 patients (86%), EBUS-TBNA is diagnostic, 12 cases of metastasis (group 1) and 7 metastatic-free (group 2); TBNA is not diagnostic in 3 patients (13.6%). There is a good correlation between CT scan and EBUS size of lymph nodes. There are no differences between the two groups about the shape (triangle, oval, round); the confluent shape of lymph nodes was found in two cases in the group 1, in 0 cases in the group 2. There are no echogenicity difference in the 2 groups except for a trend of hypo-echogenicity in malignant and of iper-echogenecity in group 2. There is no difference about margin: even if in the group 1 there are more cases of undefined margin. The only difference between the two groups is the size of lymph node, bigger in the group 1.

Conclusions

The size of the lymph nodes is the most predictive variable for malignancy. Metastatic lymph nodes have a trend to a confluent shape . In this staudy echogenicity and margin do not appear predictors for metastatic involvement. The limit of the study is the low number of patients evaluated. Further studies are needed to identify EBUS variables useful to interventional pulmonologist to evaluate better the mediastinal lymph nodes.

id 407

Characteristics of endobronchial tuberculosis in children

Carolina Sousa, Carla Simão, Luciana Bento, Rui Costa, José Pedro Boléo-tomé, Fernando Rodrigues

Pneumology Department, Professor Dr. Fernando Fonseca Hospital - Portugal

Introduction

Endobronchial tuberculosis (EBTB) is defined as a tuberculous infection of the tracheobronchial tree with microbial or histopathological evidence. Most cases of primary infection remain asymptomatic. However, with progression of the disease, lymph nodes located in hilar and paratracheal regions become enlarged and may encroach upon the regional bronchus. Although an inflamed mucosa is the most common bronchoscopy finding in adults, the evolution of the disease is unpredictable with frequent progression to bronchostenosis. Nevertheless, there is still little information regarding children endobronchial tuberculosis.

Objective

The primary endpoint of this study was to evaluate endobronchial manifestations of Mycobacterium tuberculosis in children.

Methods

Retrospective and observational analysis, of <18 years old patients with a suspected or confirmed diagnosis of Mycobacteria tuberculosis, over a 10 year period (2006-2015), based on medical records. The diagnosis was established by the isolation of microorganism in cultures. Bronchoscopy lesions were classified according to Chung et al1 classification (actively caseating, fibrostenotic, edematous-hyperemic, tumorous, ulcerative, granular, and nonspecific bronchitic).

Results

EBTB was found in 26 children, between ages of 2 and 18 years old, with a male predominance (61,5%) and a mean age of 10,6 years. Imunossupression by HIV was confirmed in 19,2% of the patients and 23% had an epidemiological history. Most common imaging findings were: mediastinal lymph nodes (66,7%), consolidation/infiltrates (38,9%), cavitary lesions (22,2%) and atelectasis (22,2%). Bronchoscopy was performed for diagnostic purposes in 69% of total patients. Therefor in the remaining 31% it was performed due to unfavorable clinical/radiologic progression in patients already diagnosed and under treatment. Bronchoscopic findings were: edematous-hyperemic mucosa (46,1%), granular (30,8%), fibrostenosis (15,4%), ulcerative (3,8%) and tumorous (3,8%). The prominent lymph nodes had been seen as grayish-yellow masses through the bronchial mucosa in two patients. Two patients with bronchial stenosis underwent a Fogarty balloon dilatation obtaining good results. Three other patients with endobronchial granulomas, there were removed through laser photocoagulation followed by balloon dilatation with lumen restoration.

Conclusions

EBTB causes in children the same bronchoscopical findings as the ones described in adults, being the edematous-hyperemic the most common manifestation. It is important an EBTB diagnosis and endoscopic follow-up in order to prevent and treat possible complications. Bronchial stenosis is an important one, also in this age range, with effective lumen restoration per balloon dilatation.

Bibliography

Chung HS, et al. Classification of endobronchial tuberculosis by the bronchoscopic features. Tuberc Respir Dis 1991;38:108-15

id 408

A Interventional pulmonology unit experience with Thulium Laser in management of Subglottic stenosis

Vijay Kumar Chennamchetty

Department of Interventional Pulmonary Medicine, Apollo Hospitals - India

Introduction

Subglottic stenosis can be managed by many interventional pulmonology modalities. We have studied the role of Thulium Laser in dealing with such cases, either alone or in combination with balloon tracheoplasty or silicone stenting.

Objective

The sub-glottic stenosis can be managed with diffferent interventional pulmonology techniques. To evaluate whether sub-glottic stenosis can be managed effectively with Thulium Laser or not.

Methods

Fiber-based lasers have facilitated a new style of Tracheo-bronchial Laser surgery. When performing therapeutic airways endoscopies there is the possibility of good control of lesions and adequate visualization of the surgical field using the bronchoscopy. We have used Thulium Laser in 11 cases of Sub glottic stenosis of various causes & in various ages. The youngest, we have used is 6yrs & eldest used is 80 years. We have used the Thulium laser in simple web like stenosis on one hand & on the other hand, we used in complex stenosis as well.Except one case, all other cases required an additional modalty of care like Balloon tracheoplasty & stenting. (find the details in table 2)

Results

Thulium Laser is an very good treatment modality to deal with sub-glottic stenosis.

Conclusions

Thulium Laser is an very good treatment modality to deal with sub-glottic stenosis.

id 409

19th WCBIP / WCBE World Congress
JOINT MEETING OF THE WORLD ASSOCIATION FOR BRONCHOLOGY AND INTERVENTIONAL PULMONOLOGY & THE INTERNATIONAL BRONCHOESOPHAGOLOGICAL SOCIETY
www.wcbipwcbe2016.org
Fortezza da Basso
May 8-11, 2016
Florence (Italy)

Endoscopic treatment of severe tracheal papillomatosis

Mauricio Cespedes Roncancio3, Mauricio Gonzalez Urrea, Alberto Franco, Manuel Conrado Pacheco Gallego, Jose Luis Blanco, Diana Neitza Aristizabal

Pulmonology and respiratory endoscopy, RESPIREMOS SAS. Clinica Comfamiliar. Clinica San Rafael. Clinica Saludcoop - Colombia

Introduction

Recurrent laryngotracheal papillomatosis is a disease caused by the human papilloma virus. More than 100 types are known. Neonates become infected as they pass through the birth canal. Initial symptoms include cough, dyspnea and stridor during the first months of life, and they may be mistaken for episodes of bronchiolitis and asthma. Diagnosis requires a high degree of suspicion and is made on the basis of fiberoptic nasolaryngoscopy, bronchoscopy and biopsy of the lesions. The disease is found mainly on the mucosa of laryngeal structures, epiglottis and vocal cords. The main marker of severity and poor prognosis is the involvement of the trachea, bronchi and lung parenchyma. Spread into the airway and malignant degeneration depend on the infecting serotype. Progression results in airway obstruction, respiratory failure and death. Current medical treatment includes resection of the lesions and use of interferon alpha, cidofovir and indole-3-carbinol. However, in the more severe cases involving the airway, patient response is lower and other options are required, like the endoscopic treatment we propose.

Methods

Combined treatment with endoscopic resection, Diode-laser photocoagulation, intralesional cidofovir, interferon alpha and indole-3-carbinol was used between 2009-2015 in 25 patients of three institutions in Pereira, Colombia. The expected results were not achieved in 4 patients, in whom advanced endoscopic treatment was required, with the implantation of a “Y” tracheobronchial stent and a subglottic tracheal stent placed immediately below the vocal cords. The objective was to achieve silicone lining of the full extent of the trachea, carina and main bronchi, preventing papilloma proliferation, ensuring airway patency, and avoiding respiratory failure and death.

Results

There was noticeable clinical improvement, reduced respiratory symptoms, stridor and dyspnea in the 4 patients who underwent the procedure. Dual tracheobronchial and tracheal stenting helped maintain the tracheal lumen, acting as a barrier that lined the extent of the trachea and stem bronchi, improving symptoms and preventing respiratory failure. There were no complications during the procedure.

Conclusions

This technique resulted in clinical, endoscopic, functional and spirometric improvement in all treated patients. Surgery was performed in one stage, avoiding monthly reinterventions and anaesthetic risk, improving quality of life, and reducing therapeutic surgical procedures, with only the need for follow- up bronchoscopy. Cost and length of stay also dropped significantly. In view of the above, we believe that the endoscopic treatment of disseminated papillomatosis is of great value, as shown in this paper.

id 410

19th WCBIP / WCBE World Congress
JOINT MEETING OF THE WORLD ASSOCIATION FOR BRONCHOLOGY AND INTERVENTIONAL PULMONOLOGY & THE INTERNATIONAL BRONCHOESOPHAGOLOGICAL SOCIETY
www.wcbipwcbe2016.org
Fortezza da Basso
May 8-11, 2016
Florence (Italy)

Spray Cryotherapy in Benign Tracheobronchial Disease: An Illustration of Procedural Techniques

Scott Parrish[1], J. Francis Turner[2], Robert Browning, Jr[1]

[1]Interventional Pulmonary Division, Walter Reed National Military Medical Center - Usa
[2]Division of Pulmonary and Critical Care Medicine, University of Tennessee Graduate School of Medicine - Usa

Introduction

Spray cryotherapy (SCT) is a relatively new tool in bronchoscopy where liquid nitrogen is used to flash freeze unwanted tissue at -196 degree Celsius. The majority of experience is in malignant airway disease, but the technique has been reported in benign airway disease. We describe some of our experience using SCT in benign airway disease. Six patients with benign airway strictures underwent bronchoscopic SCT using the TruFreeze cryotherapy system approved for general tissue ablation. Four patients had idiopathic subglottic stenoses. One patient had granulomatous tissue partially obstructing the bronchus intermedius. Another patient had a history of tuberculous tracheitis which caused a 7 cm long tracheal stenosis with a 5 mm diameter lumen.

Methods

All patients except one underwent rigid bronchoscopy under general anesthesia. Three patients with subglottic stenosis underwent 3 applications of SCT under normal flow for 5 seconds each followed by balloon dilation. Following dilation another application of SCT was given. One patient had a very proximal subglottic stenosis and SCT was performed with suspension laryngoscopy instead of rigid bronchoscopy. In that patient 2 applications of SCT on low flow for 10 seconds were followed by balloon bronchoplasty. Another two applications of low flow for 10 seconds was performed following dilation. In the patient with granulomatous tissue SCT was applied with normal flow for 5 seconds for 2 sprays followed by one application of 10 seconds at low flow near the distal end of the mass close to the right middle lobe followed by manual debulking. In the initial procedure in the patient with post tuberculosis stenosis the stenosis was too long and narrow to allow for acceptable gas egress. Therefore she underwent radial cuts with an electrocautery knife followed by balloon and rigid dilation. She was brought back for three additional procedures using a combination SCT and balloon and rigid dilation resulting in a normal caliber trachea. All six patients had resolution of their dyspnea.

Conclusions

These cases are examples of the efficacy of SCT in benign airway disease. Previous reports with SCT were with an older generation device in which the use in the airways was off label. This is one of the first reports in which the new device has been used in benign disease. SCT has the advantage over heat ablative techniques of preserving underlying architecture and allowing for normal mucosal healing which makes its use in benign airway disease ideal.

id 411

19th WCBIP / WCBE World Congress
JOINT MEETING OF THE WORLD ASSOCIATION FOR BRONCHOLOGY AND INTERVENTIONAL PULMONOLOGY & THE INTERNATIONAL BRONCHOESOPHAGOLOGICAL SOCIETY
www.wcbipwcbe2016.org
Fortezza da Basso
May 8-11, 2016
Florence (Italy)

From morphological to lobar ventilatory criteria for selection of target lobe in LVR

Hetzel Juergen[1], Boeckeler Michael[1], Ehab Ahmed[1], Horger Marius[2], Kloth Christopher[2], Häntschel Maik[1]

[1]Department of Internal Medicine II, University of Tuebingen - Germany
[2]Department of Diagnostic and Interventional Radiology, University of Tuebingen - Germany

Introduction

Reduction of hyperinflation is the pathophysiological rationale of lung volume reduction (LVR) in patients with lung emphysema. This ability of expiration is insufficiently reflected by inspiratory parameters. However the selection criterion for lobes with regard to LVR is mainly based on high resolution CT (HRCT) scans in inspiratory position. Yet it's unclear whether the most emphysematous lobe in inspiration contributes most to hyperinflation. The common HRCT parameters to evaluate the extent of emphysematous areas are mean lung density (MLD), low attenuation value (LAV) as proportion of lung tissue with HU <-950 and the HU at the 15 % percentile (15%P) in inspiration. It has never be shown, to what extent these parameters predict the least deflation of a certain lobe during expiration. Instead, the expiration of a particular lobe can be measured by using the lobar expiration index (LEI) calculated as (inspiratory volume – expiratory volume)/inspiratory volume.

Objective

We compared the functional deflation parameter LEI with the established HRCT density parameters in the same lobe in inspiration and expiration.

Methods

36 patients were included in the study. The LEI of each lobe was calculated, additionally MLD, LAV and 15%P were determined for each lobe in inspiration and expiration. We calculated how often the lowest LEI matched with the lowest MLD, highest LAV and lowest 15%P for each patient respectively and compared results for upper and lower lobe.

Results

Lowest LEI matched with lowest MLD, highest LAV and lowest 15%P in 18 (50.0%), 13 (36.1%) and 12 (33.3%) patients in inspiration respectively, while in expiration match with MLD, LAV and 15%P was seen in 18 (50.0%), 16 (44.4%) and 17 (47.2%) cases respectively. The mismatch between morphological criteria (MLD, LAV, 15%P) and the functional parameter LEI was the same for both, the upper lobes and the lower lobes. There was a tendency towards reduced mismatch in the expiratory scan compared with the inspiratory CT.

Conclusions

In comparison to the function parameter LEI, the morphological criteria MLD, LAV and 15%P based on inspiratory HRCT scan weakly reflect deflation of a certain lobe during expiration. This insufficient prediction is similar in upper and lower lobes. There was a better match between LEI and morphological parameters in expiratory than in inspiratory position. Considering pathophysiological aspects, the additional use of the functional parameters e.g. LEI likely improves the prediction of successful LVR treatment of a certain lobe.

id 412

Positive airway pressure-enhanced CT to improve virtual bronchoscopic navigation

Marta Diez-ferrer[1], Debora Gil[2], Elena Carreño[3], Susana Padrones[1], Samantha Aso[1], Vanessa Vicens[1], Noelia Cubero[1], Rosa Lopez-lisbona[1], Carles Sanchez[2], Agnes Borras[2], Antoni Rosell[1]

[1]Department of Respiratory Medicine, Hospital Universitari de Bellvitge - Spain
[2]Computer Vision Center, Universitat Autònoma de Barcelona - Spain
[3]Department of Radiology, Hospital Universitari de Bellvitge - Spain

Introduction

The bronchoscopic study of the peripheral pulmonary nodule (PPN) represents a major challenge in current pulmonology. The use of virtual bronchoscopic navigation (VBN) in combination with different endoscopic techniques has improved the diagnostic yield of PPN. We have found in our daily practice that the CT-based automated segmentation of the tracheobronchial tree by the VBN system is often limited to lesser distal divisions thus limiting the potential of VBN for PPN achievement. We hypothesized that the application of a continuous positive airway pressure (CPAP) system during CT acquisition could improve visualization of peripheral bronchi and therefore segmentation.

Objective

The aim of the present pilot study is to compare the segmentations obtained with different CT acquisitions: inspiration, expiration, and both with CPAP.

Methods

A total of 5 patient candidates for bronchoscopic study of PPN were included. 320-dectector row CT scans (Aquilion ONE™, Toshiba Medical Systems, Otawara, Japan) with slice thickness of 0.5 mm were performed in inspiration and expiration without CPAP, and inspiration and expiration with EzPAP® (Smiths Medical, Grasbrunn, Deutschland) with pressures ranging from 6 to 10 cmH2O during 3'. Automated segmentations were obtained and compared with a VBN system (LungPoint®, Broncus Medical, CA, USA). Luminal diameters at 4 different levels (proximal trachea, distal trachea, right main bronchus, subsegmentary bronchus) were extracted from VBN data and areas calculated (mm2). Two paths were selected in every lobe and bifurcations counted manually (total of 12 pathways per patient and CT acquisition). Friedman's test was used to compare all the paired means, and Student's t-test was performed to compare paired results with and without CPAP data.

Results

In the table areas per each level and in total, as well as the mean of bifurcations are presented.

Conclusions

- CT acquisition at 6-10 cmH2O CPAP increases significantly main airways' areas without affecting distal bronchi. - Mean division achieved with or without CPAP is not affected by 6-10 cmH2O CPAP. - Acquisition in inspiration obtains better results than expiration both in lumen enlargement and in number of divisions segmented. In summary, this pilot study does not favor the use of 6-10 cmH2O CPAP for 3' during CT acquisition to increase 3D reconstruction for virtual bronchoscopy navigation systems.

Table 1. Areas and bifurcations for every CT acquisition

	Expiration	Expiration-CPAP	Student's t-test	Inspiration	Inspiration-CPAP	Student's t-test	Friedman test
Trach. proximal (mm^2)	225,9	261	0,02	235,4	274	ns	ns
Trach. distal (mm^2)	248,9	273,7	0,01	330	316	ns	0,004
Right Main Bronchus (mm^2)	139,3	153,7	0,01	199,5	239	ns	0,002
Subsegment bronchus (mm^2)	11,5	11,5	ns	10,5	12,4	ns	ns
TOTAL area (mm2)	627,5	700	0,05	775,6	841,9	ns	0,014
Divisions (mean)	4,98	5,42	ns	6,87	6,63	ns	0,004

id 413

Foreign Body Aspiration in Adults - Experience of a Pulmonology Interventional Unit

Luis Martins, Christine Costa, Salvado Feijó, Paula Monteiro, José Rosal Gonçalves, Cristina Bárbara

Serviço de Pneumologia, Centro Hospitalar Lisboa Norte - Hospital de Santa Maria - Portugal

Introduction

Foreign body aspiration (FBA) is frequent in children but uncommon in adults. Clinical presentation in adult varies from life-threatening distress to subtle signs and symptoms. The aim of our study was to describe our 7-year experience with FB aspiration in adults.

Objective

The aim of our study was to describe our 7-year experience with FB aspiration in adults.

Methods

We retrospectively collected data from all suspected foreign-body aspiration in adults that underwent a bronchoscopy in our unit from November 2008 to October 2015. Population demographics, referral service, type and location of FB were analysed.

Results

In this period, 70 patients were submitted to bronchoscopy, 64,3% were male, mean age was 62,8 years. 30,0% came directly from the emergency department and 21,4% from other hospitals. Rigid bronchoscopy was performed in 41 patients (58,6%) and fiberoptic bronchoscopy in 29 patients (41,4%). 77,1% were patients with a high index of suspicion and 14,3% presented complications of aspiration as pneumonia (10,0%) and atelectasis (4,3%). In 24,3% of the patients no foreign-body was found, therefore 53 (75,7%) FBs were extracted. The nature of FB found in the airway was inorganic in 52,8% cases, in particular 3 cases were objects used to clean tracheostomies (brushes) and 2 voice prosthesis. The majority of FBs were lodged in the right bronchial tree (60,4%), especially in the right lower lobe bronchus (20,8%). There were no major complications or need for surgery referral.

Conclusions

The diagnosis of FBA in adults is challenging because patients do not always recall a history of choking, despite this, a large number of patients were submitted to a bronchoscopic procedure due to a high level of suspicion of FB aspiration. In our series, tracheostomy was a risk factor for FB aspiration. Bronchoscopic approaches are effective to decrease mortality and morbidity for the diagnosis and treatment of foreign body aspirations in adults. Fiberoptic bronchoscopy was the initial diagnostic and therapeutic procedure in 29 patients, showing that fiberoptic bronchoscopy is also suitable. However, rigid bronchoscopic approach continues to remain the procedure that offers better manipulation of FB.

id 414

19th WCBIP / WCBE World Congress
JOINT MEETING OF THE WORLD ASSOCIATION FOR BRONCHOLOGY AND INTERVENTIONAL PULMONOLOGY & THE INTERNATIONAL BRONCHOESOPHAGOLOGICAL SOCIETY
www.wcbipwcbe2016.org
Fortezza da Basso
May 8-11, 2016
Florence (Italy)

Bronchial Electrocautery for treatment of untractable bronchopleural fistula

Stephanie Cousse, Astrid Bertier, Samy Lachkar, Jean Marc Baste, Mathieu Salaun, Luc Thiberville

Clinique Pneumologique, Charles Nicolle - France

Introduction

Bronchopulmonary fistula (BPF) with pyothorax is a rare but severe complication of lung parenchymal infection. The endobronchial occusion using biological compounds, watanaboe Spigots or valves has been described as an alternative to surgery. We describe a case of successful treatment of a a large endobronchial fistulae using bronchial wall electrocautery of a proximal bronchus.

Methods

We report the case of a 51-year old woman, active smoker, who was hospitalized at the intensive care unit of the Rouen University Hospital for a pneumococcal pneumonia with acute respiratory distress syndrome acute (ARDS). She developed multiple lung abscesses superinfected by Candida albicans, requiring medical and surgical drainage through a right thoracotomy, washing, as well as middle and lower lobe necrosectomy, and thoracostomy associated with vacuum assisted closure (VAC) therapy. Four weeks after surgery a chest CT scan revealed a BFP interesting the paracardiac and latero- basal bronchi, while infection was controled by antibiotic and antifungal therapies, leading to ventilatory weaning and extubation. Endoscopic treatment of fistula was achieved by circumferential thermocoagulation of the middle lobe broncus (Rb4+Rb5) using the rigid bronchoscope. The thorax CT scan performed two days after the second session showed the BPF resolution. Control bronchoscopy showed a complete stenosis or middle lobe. VAC therapy could be removed within two weeks. The patient was followed up for 8 months without symptoms.

Conclusions

Bronchial thermocoagulation associated with VAC therapy can be considered as an endoscopic treatment option of large BPF due to necrotizing pneumonia

id 415

19th WCBIP / WCBE World Congress
JOINT MEETING OF THE WORLD ASSOCIATION FOR BRONCHOLOGY AND INTERVENTIONAL PULMONOLOGY & THE INTERNATIONAL BRONCHOESOPHAGOLOGICAL SOCIETY
www.wcbipwcbe2016.org
Fortezza da Basso
May 8-11, 2016
Florence (Italy)

Spray Cryotherapy (SCT) in Pulmonary Disease: Interim analysis of a multi-center registry

Robert Browning[1], Costas Bizekis[2], Scott Parrish[1], Michael Zervos[2], Ashutosh Sachdeva[3]

[1]Interventional Pulmonology, Walter Reed National Military Medical Center - Usa
[2]Cardiothoracic Surgery, New York University Langone School of Medicine - Usa
[3]Pulmonary and Critical Care Medicine, University of Maryland School of Medicine - Usa

Introduction

Spray Cryotherapy (SCT) was initially developed for gastroenterologists use in the esophagus in 1999. Over the next decade, some centers began to use SCT in the airways. Significant differences in the management of the nitrogen gas venting exist between esophageal and airway application. In 2012, a retrospective multi-institutional review of use of the early SCT device in the airways reported promising treatment results of SCT but also a relatively high complication rate. In November 2012 a new generation SCT device (TruFreeze, by CSA Medical, USA) that provided improved uniform delivery and adjustable flow rate of liquid nitrogen delivery to the target tissue was first used in the airways. We report the interim results (JUL13-JAN16)) of a prospective multi-institutional registry using SCT in pulmonary disease.

Objective

The primary objective of this registry is to collect, safety, spectrum of use, efficacy and specific patient data related to patient selection the use of tr?Freeze® SCT in pulmonary disease.

Methods

Patients enrolled prospectively from 3 institutions using tr?Freeze® SCT to ablate benign or malignant unwanted tissue in the central airways or pleura. Spectrum of use, safety and limited efficacy data were collected and interim analysis performed using SPSS software.

Results

43 adult patients from 3 institutions were enrolled and followed in the registry. SCT was used in 34 (79%) patients to ablate malignant and in 9 (21%) patients to ablate benign pulmonary disease. SCT was used in 66 separate procedures. SCT was used to achieve hemostasis in endobronchial bleeding in 23% of cases and reported to have complete success in 99% of those cases. In 16% of cases, SCT was used around silicone or silicone covered stents. One pneumothorax, unlikely related to device use, occurred and was resolved uneventfully with simple aspiration.

Conclusions

SCT can be safely used in benign and malignant central airway diseases. Unlike thermal ablation technologies, this novel modality can be safely and effectively used to ablate tumor or granulation tissue near silicone and silicone covered stents in high oxygen concentrations. In our cohort, SCT was effective in achieving hemostasis in bleeding central airway lesions.

The presenting author has the following conflicts of interest that relate to this abstract: *This registry is funded by CSA medical who manufactures the TruFreeze device. I am the principal investigator for the Pulmonary arm of the TruFreeze multi-center registry. I am a consultant for CSA medical.*

19th WCBIP / WCBE World Congress
JOINT MEETING OF THE WORLD ASSOCIATION FOR BRONCHOLOGY AND INTERVENTIONAL PULMONOLOGY & THE INTERNATIONAL BRONCHOESOPHAGOLOGICAL SOCIETY
www.wcbipwcbe2016.org
Fortezza da Basso
May 8-11, 2016
Florence (Italy)

Laryngeal suspension in combination with cricopharyngeal myotomy for severe oropharyngeal dysphagia

Takaharu Nito, Takao Goto, Rumi Ueha, Tatsuya Yamasoba

otolaryngology, the univerity of Tokyo - Japan

Introduction

Severe oropharyngeal dysphagia and aspiration are life-threatening conditions. Laryngeal suspension (LS) and cricopharyngeal myotomy (CPM) are surgical procedures for restoring oral intake with a functional larynx. LS in combination with CPM (LS and CPM) has been performed for severe oropharyngeal dysphagia since the 1970s in Japan. However, such procedures are as yet not commonly practiced worldwide.

Objective

The purpose of this study is to elucidate the effectiveness of LS and CPM.

Methods

Data of 21 patients (18 male and 3 female) who required tube feeding owing to severe oropharyngeal dysphagia (function oral intake scale (FOIS): 1-2) and underwent LS and CPM at the University of Tokyo Hospital from 2006 to 2015 were retrospectively collected and analyzed.

Results

The average overall age was 61.3 years (21 to 79 years). Thirteen patients had brainstem involvement due to celebrovascular diseases, three patients had lower cranial nerve paralysis due to skull base tumor or neck tumor, and fivc patients had other diseases. Twenty patients were able to take food or puree orally after the LS and CPM at various degrees. A patient after resection of esophageal cancer had laryngotracheal separation because of severe aspiration of saliva. Gastrostomy tubes were removed in eight patients (FOIS: 4-7). Patients with cognitive dysfunction, respiratory dysfunction, ataxia of the trunk or impaired sensation of the larynx were not able to obtain sufficient oral intake. None of the patients had severe gastroesophageal reflux nor severe complications.

Conclusions

The combination of LS and CPM is effective for restoring oral intake with a functional larynx in selected cases.

id 417

Morphometric analysis of cell blocks obtained by endobronchial ultrasound in lung cancer

Carmen Centeno Clemente[1], Felipe Andreo García[1], Marta Avila Terzi[2], Enric Carcereny Costa[3], Ana María Muñoz-mármol[2], José Ramírez Serrano[3], Juan Ruiz Manzano[4]

[1]Pulmonology, Hospital Universitario Germans Trias i Pujol - Spain
[2]Pathology, Hospital Universitario Germans Trias i Pujol - Spain
[3]Oncology, Hospital Universitario Germans Trias i Pujol - Instituto Catalán de Oncología - Spain
[4]Pulmonology, Hospital Universitario Germans Trias i Pujol - Instituto Catalán de Oncología - Spain

Introduction

The quantitative composition of cytological samples processed as biopsies is important to perform immunohistochemical analysis and determination of multiple molecular studies in advanced lung cancer. It is not known exactly the tissue distribution of cell blocks (CB).

Objective

Determine the composition of microscopic pathologic CB obtained by fine needle aspiration guided by endobronchial ultrasonography (EBUS) or endoscopic ultrasonography (EUS), using objective methods of analysis of microscopic images.

Methods

Prospective study, which included CB, obtained by EBUS-TBNA or EUS-FNA needle 22G (NA2015X-4022, Olympus Optical Co.), of patients with suspected or study of NSCLC in advanced stage. Imaging for morphometric analysis was performed using a light microscope (Axioskop2) with 5x objective. They were digitized and photomicrographs of the areas of interest were obtained and analyzed with the ZEN-Blue 2011 software through the use of a metering module, which extrapolates to metric dimensions. All images were evaluated by a cytologist and the total area, the tumor area, and the tumor area to the total area was calculated. Furthermore, PCR techniques and immunohistochemistry were performed on samples to analyze molecular mutations (EGFR, KRAS, HER2, BRAF, ALK and ROS1).

Results

We were included 12 CB of 9 patients, mean age 65.22 ± 8.6 years. 5 EBUS-TBNA. We were punctured 8 mediastinal lymph and 1 posterior mediastinal mass. The most punctured stations: 4R (2) and 4L (2). In all cases the diagnosis was adenocarcinoma, 1 in stage IIIA, IIIB stage 2 and 6 in stage IV. The average number of punctures was 3.13. 6 genetic alterations determination was performed in 3 CB. For cell block: the total area average was 2.43 mm2 (range 0.53 to 6.85), total tumoral area average was 0.51 mm2 (0.01 to 2.76), and porcentage of tumor area average was 12.79%. The results for each case exposed in table nº 1.

Conclusions

The use of morphometric analysis in BC obtained by EBUS or EUS allows accurate calculation of tumor areas and could be useful for comparative studies with other types of samples and different techniques to obtain tumor tissue.

CASE	NUMBER OF CELL BLOCKS	TOTAL AREA $(mm)^2$	TOTAL TUMORAL AREA (mm^2)	TOTAL TUMORAL AREA (%)	NUMBER OF MUTATIONS PERFORMED	ALK - ROS
1	1	1,32	0,14	10,65	4	YES/INSUF
2	2	2,41	0,06	2,49	6	YES
3	2	1,28	0,09	7,03	2	YES
4	1	3,52	0,08	2,27	5	YES
5	2	11,55	5,28	45,71	2	YES
6	1	0,53	0,01	1,88	2	YES
7	1	2,37	0,18	7,59	6	YES
8	1	4,36	0,04	0,92	4	YES
9	1	1,85	0,29	15,68	2	NP

id 418

19th WCBIP / WCBE World Congress
JOINT MEETING OF THE WORLD ASSOCIATION FOR BRONCHOLOGY AND INTERVENTIONAL PULMONOLOGY & THE INTERNATIONAL BRONCHOESOPHAGOLOGICAL SOCIETY
www.wcbipwcbe2016.org
Fortezza da Basso
May 8-11, 2016
Florence (Italy)

Bronchoscopy in intensive care unit-bronchoscopist's point of view

Živka Uskokovi?-stefanovi?[1], Spasoje Popevi?[2], Milan Gruji?[1], Branislav Ili?[1]

[1]Interventional Pulmonology Unit, University Hospital for Pulmonology, Clinical Center of Serbia, University Hospital for Pulmonology - Serbia
[2]Interventional Pulmonology Unit, University Hospital for Pulmonology, Clinical Center of Serbia, School of Medicine, University of Belgrade - Serbia

Introduction

In intensive care unit, bronchoscopy has become one of essential tools for the management of patients. There are many diagnostic and therapeutic indications. Despite the wide use of the bronchoscopy, especially fiberoptic, it must never be forgotten the importance of the bronchoscopist’s expertise in this highly specific field of application, in order to avoid risks and to prevent life- threatening consequences for the critically-ill patient.

Objective

To describe our experience, main indications, clinical results, complications, risks and benefits associated with bronchoscopy in the Intensive Care Unit.

Methods

Our retrospective study evaluated 760 bronchoscopic interventions that were made in various intensive care units in Clinical Center of Serbia, during 2015.

Results

Bronchoscopy and Interventional Pulmonology Department of University Hospital of Pulmonology, covers different intensive care units (ICU) - (cardiovascular, methabolic, pulmonary, neurological, surgical, and trauma ICU) and annually performs more than 700 interventions. During 2015, 760 interventions were done,both diagnostic and therapeutic. Therapeutic interventions were done in 71,89% of patients and indications were:airway management (difficult intubations, double-lumen tube placement, extubation in 43 pts, atelectasis and excess airway secretions in 379,massive haemoptysis in 31, foreign bodies in 17, bronchopleural fistula (application of fibrin glue therapy) in 2pts. Endobronchial obstruction was treated with laser,APC or cryotherapy in 46 patients, strictures and stenoses (dilatation and stents)in 27 patients. Primarily diagnostic indications were present in 213 patients(pneumonia ,diffuse or focal lung disease (infiltrates or mass lesions), airway trauma (intubation injury, blunt thoracic injury, postoperative), acute inhalational injury or burn,localised wheeze or stridor, tracheoesophageal fistula …). Many indications required both diagnostic and therapeutic bronchoscopy in the same act and choice of the instrument, experience of bronchologist had an extremely important role. Endoscopic findings were very often surprising: in 31% -234 pts some kind of interventional procedure was indicated along with bronchial aspiration.

Conclusions

Bronchoscopy in ICU provides valuable diagnostic information and has therapeutic utility. It can be performed in almost all critically ill patients with clinical indications. However, it should be performed by experienced bronchoscopists who are skilled in the use of this versatile instrument and can deal with potential complications.

19th WCBIP / WCBE World Congress
JOINT MEETING OF THE WORLD ASSOCIATION FOR BRONCHOLOGY AND INTERVENTIONAL PULMONOLOGY & THE INTERNATIONAL BRONCHOESOPHAGOLOGICAL SOCIETY
www.wcbipwcbe2016.org
Fortezza da Basso
May 8-11, 2016
Florence (Italy)

Percutaneous endoscopic tracheostomy in patients outside the indications: case series

Mauricio Cespedes Roncancio3, Fernando Montoya Navarrete, Alberto Franco, Manuel Conrado Pacheco, Mauricio Gonzalez Urrea, Jose Luis Blanco, Diana Neitza Aristizabal

Pneumology and respiratory endoscopy, RESPIREMOS SAS. Clinica Comfamiliar. Clinica San Rafael. Clinica Saludcoop – Pereira - Colombia

Introduction

Tracheostomy, procedure performed frequently in critically ill patients. Percutaneous techniques, with or without bronchoscopic visualization, are preferred, the former being the recommended approach in order to avoid complications. The technique has precise indications and relative and absolute contraindications, including, among others, coagulopathy, urgent tracheostomy, tracheal tumour, difficult anatomy, and prior cervical radiotherapy.

Methods

Retrospective and descriptive study conducted between 2009-2016 in 25 patients with indication for tracheostomy in three institutions in Pereira, Colombia. There were absolute contraindications in 6 patients and relative contraindications in the remaining 19. All the patients were scheduled for the procedure following assessment by the airway team. Because of the complexity, the procedure was performed in the operating room using the technique described by Ciaglia under constant bronchoscopic visualization, and the Blue Rhino kit (Cook). As a group, the authors have performed more than 800 percutaneous procedures, prompting extension of the technique to patients with relative or absolute contraindications, provided patients are thoroughly assessed and the team is prepared to manage any potential intraoperative complications. Airway management equipment is available, including cricothyroidectomy equipment, fast intubation devices, videolaryngoscopy, videobronchoscopy, rigid bronchoscopes, diode laser and argon plasma coagulation in order to control potential complications in complex cases.

Results

In the majority of patients, the indication was failed weaning from mechanical ventilation. Following assessment, percutaneous tracheostomy was performed using the Ciaglia conventional technique under bronchoscopy. All the necessary equipment was made ready in event an emergency occurred, but percutaneous tracheostomy was performed successfully with no serious complications. There was significant bleeding only in one patient with a pretracheal tumour invading the tracheal wall, but it was controlled with endoscopic laser photocoagulation. Endoscopic control was found to improve the safety of the procedure because transillumination and entry into the trachea under direct vision are critical. There were no other minor or major complications, and no increase in operative time was observed.

Conclusions

Percutaneous tracheostomy is a safe, fast and low-cost procedure. Like most other endoscopic procedures, it has relative and absolute contraindications. With adequate patient assessment and the availability of equipment and devices to solve potential complications, it is possible to expand the indications for this technique. Endoscopic guidance is mandatory for airway assessment and for ensuring accuracy and safety. The availability of equipment for managing complications is also mandatory. Therefore, relative and absolute contraindications depend on the experience of the team, endoscopic control, and the availability of the equipment for managing complications.

id 420

19th WCBIP / WCBE World Congress
JOINT MEETING OF THE WORLD ASSOCIATION FOR BRONCHOLOGY AND INTERVENTIONAL PULMONOLOGY & THE INTERNATIONAL BRONCHOESOPHAGOLOGICAL SOCIETY
www.wcbipwcbe2016.org
Fortezza da Basso
May 8-11, 2016
Florence (Italy)

Cytologic examination of pleural fluid in the management of recurrent pleural effusion

Marco Damin, Umberto Fantoni

Pneumologia Unità di Pneumologia Interventistica, Azienda Ospedaliera Università di Padova - Italia

Introduction

Medical thoracoscopy (MT) is an important diagnostic procedure in the management of recurrent pleural effusion. In the pneumological centers where MT is not performed, a patient with pleural effusion is treated with thoracentesis and cytologic analysis of pleural fluid.

Objective

To assess the diagnostic accuracy of cytology of the pleural fluid than histological examination of pleural biopsy obtained with MT.

Methods

This is a retrospective analysis of 87 patients with recurrent pleural effusion, already undergoing to thoracentesis. All of them were subjected to MT in our Interventional Pneumology Unit. The diagnostic power of pleural fluid cytology obtained from thoracentesis compared to histology of pleural biopsies obtained with MT is evaluated in terms of sensitivity (SE) , specificity (SP), positive predictive value (PPV) and negative predictive value (NPV).

Results

The diagnosis has been obtained in all patients undergoing MT, with 20.6% of mesothelioma , 51.7% pleural metastasis from tumors of other origin (42% lung, 18% breast , 16% gastro- intestinal tract, 13% urogenital system, 11 other cancers), of 27.5 % nonspecific pleurisy . Cytological analysis of pleural effusion has allowed this results: SE 55.5 % , SP 91.6 % , PPV 94.5 % , NPV 44 % . Of 87 patients , 37 patients has a history of previous neoplasia (group 1) while 50 patients don't have a history of neoplastic diseases (group 2). In the group 1 SE is 43.3 %, SP is 100 %, PPV is 100 %, NPV is 29.1 %; in this group MT confirms the presence of neoplasia in all patients, however in 15.4 % of patients the pleural histology is different from previous neoplasia In the group 2, SE is 66.6 %, SP is 88.2 % histologic examination confirms the result of cytology in 91.6 % (PPV) with a NPV of 57.6 % .

Conclusions

In the managment of recurrent pleural effusion, MT is safe and effective. MT has an higher diagnostic power in comparison of cytological analisis of pleural fluid obtained by thoracentesis even in patients with a history of previous malignancy .

id 421

Needle based optical coherence tomography for mediastinal lymph nodes, an ex-vivo study

Lizzy Wijmans, Daniel M De Bruin, Joris Jth Roelofs, Jouke T Annema

Pulmonology, University of Amsterdam, AMC - Holland

Introduction

Endosonography has limitations in excluding mediastinal nodal metastases in non small cell lungcancer (NSCLC) staging. Needle based optical coherence tomography (OCT) generates high resolution images within organs and has been shown to discriminate benign from metastatic involved axillary nodes in patients with breast cancer (1). Its value in NSCLC staging is unknown.

Objective

To compare the attenuation coefficient (mm-1) of reactive with metastatic mediastinal lymph nodes in patients with NSCLC.

Methods

Ex –vivo measurements - immediately following lobectomy for NSCLC- of benign (n=4) and malignant (n=4) mediastinal and hilar lymph nodes and a malignant lung tumour (n=1) . OCT imaging (pullback of 54mm, 540 images) was performed following puncturing of the lymph node with a 16G biopsy needle and fitting the OCT probe (Dragonfly catheter diameter 0.9 cm, St Jude) through the protectional sleeve after removing the needle. 48 measurements of the attenuation coefficient (mm-1) were obtained in 3 different tissue-types; reactive (n=29) and malignant (n=26) lymph nodes tand an adenocarcinoma (n=12). Within the lymph node , fatty lymph node tissue (n=11) (recognizable by its honeycombing structure) could be distinguished as the fourth tissue type. Attenuation coefficients were extracted from OCT pullback images at 3 different levels (25%, 50% and 75% of the pullback) and at 4 measuring points in a single OCT image at 0, 90, 180 and 270 degrees (Figure). Histopathology findings was the reference standard. Analysis was performed with dedicated software (FIJI),by assessment of the decay of the slopes and corrected for the refractive index of tissue.

Results

Attenuation coefficients were significantly different in benign compared to both fatty (IQR 0.907-1.249, IQR 1.311-1.973 p=0.0005) and malignant lymph node tissue (IQR 1.311-1.973, IQR 2.277-3.105 p=0.0001). Attenuation coefficients from malignant lymph nodes were similar to those of the lung tumour itself (IQR 2.277-3.105, IQR 2.836-3.650).

Conclusions

Ex-vivo needle based OCT clearly discriminates between reactive, fatty and metastatic involved lymph node tissue by measuring attenuation coefficients (m-1). Future OCT research should, in n addition to measuring physiological features (e.i. the attenuation coefficient) also correlate OCT morphology to histology.

Bibliography

McLaughlin R, et al. Cancer res 2010; 2579-2584 Imaging of human lymph nodes using optical coherence tomography: potential for staging cancer

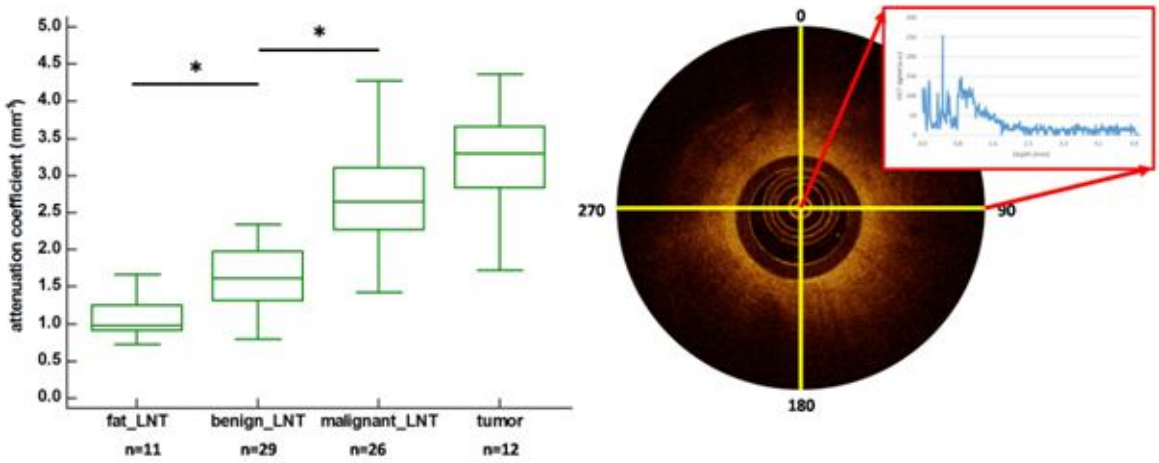

Figure 1: Left panel: Attenuation coefficients (mm-1) for different tissue types by Mann-Whitney test. Fatty lymph node tissue (fat_LNT), benign lymph node tissue (benign_LNT), malignant lymph node tissue (malignant_LNT) and malignant lung tumour tissue (tumor) Right panel: example of measure points in OCT pull back image with a graph of the extracted OCT signal at the 90 degrees measure point.

id 422

Factors affecting accuracy of EBUS-TBNA for malignant/benign mediastinal lymph node involvement

Nicola Rotolo[1], Giorgio Crosta[2], Elisa Nardecchia[1], Maria Cattoni[1], Cinzia Gambarini[3], Stefano La Rosa[4], Lorenzo Dominioni[1], Andrea Imperatori[1]

[1]Departement of Surgical and Morphological Sciences, Center for Thoracic Surgery - University of Insubria - Italy
[2]Department of Specialistic Medicine, Unit of Pulmunology - Hospital of Varese - Italy
[3]Department of Specialistic Medicine, Unit of Pneumology - Hospital of Varese - Italy
[4]Department of Pathology, Ospedale di Circolo - Italy

Introduction

Endobronchial ultrasound-guided transbronchial needle aspiration (EBUS-TBNA) is increasingly used for minimally invasive diagnosis of disease involvement of mediastinal lymph nodes in patients with malignancy/granulomatous disease

Objective

Prospective evaluation of factors influencing diagnostic accuracy of EBUS-TBNA during the initial two-year experience in a single institution

Methods

We prospectively evaluated 199 consecutive patients (71% male; mean age 61±15 SD years) undergoing EBUS-TBNA of mediastinal/hilar lymphadenopathy [suspect lung cancer/other malignancy metastasis: n=139 (70%); suspect granulomatous disease: n=60 (30%)] referred to our interventional endoscopy unit in 2012- 2014. All EBUS-TBNA procedures were performed under sedation, alternatively by two experienced bronchoscopists (1 thoracic surgeon, 1 pulmonologist) with 3 passes/lymph node. In sequential order over the study period, five specimen- processing techniques were used: 1) cytology slides (n=42 patients); 2) cell- block (n=25); 3) core-tissue (n=60); 4) combination of cytology slides+core tissue (n=51); 5) combination of cytology slides+cell-block (n=21). Rapid on site evaluation was not done. For cases with cancer-negative EBUS-TBNA finding, we used as diagnostic gold standard respectively the surgical N status in operated patients, or 1-year follow-up. Needle gauge, lymph node size, type of specimen processing technique, malignant/benign suspected diagnosis, surgeon/pulmunologist bronchoscopist, and progressive group of cases were tested as predictors of diagnostic accuracy by logistic regression analysis.

Results

Mean size of sampled lymph node was 27±13 SD mm. Sampled lymph node station was: #7 in 60% of patients; #4R/4L in 32%; #10R/11R/10L/11L in 7%; #2R/2L in 1%. No peri-procedure complications occured. Multivariate analysis showed that the only independent predictor of diagnostic accuracy was the sample processing technique ($p<0.01$). Our two experienced bronchoscopists rapidly achieved good proficiency with EBUS-TBNA, as shown by no difference in diagnostic accuracy of malignant/benign disease when comparing the sequential groups of 50 consecutive patients (Table). Accuracy of the specimen-processing techniques respectively was: cytology slides, 80%; cell-block, 33%; core-tissue, 99%; cytology slides+core tissue,100%; cytology slides+cell-block, 100%.

Conclusions

In our single-institution experience of the first 199 EBUS-TBNA cases, specimen preparation technique was the only independent factor influencing the accuracy of malignant/benign diagnosis. Our finding of the cell-block method low-accuracy (33%) contrasts with other authors' experience (1,2); this suggests that the optimal EBUS-TBNA specimen preparation technique may depend on the local pathologists' expertise/preference

Bibliography

1. Sanz-Santos J, et al. BMC Cancer 2012;12:34; 2. Van der Heijden E. et al. Respiration 2014;88:500-517

Tab. 1: Predictors of diagnostic accuracy

	Univariate			Multivariate		
	OR	**95% CI**	***p***	**OR**	**95% CI**	***p***
Progressive group of cases (1-50 v 51-100 v 101-150 v 151-199)	1.14	0.75-1.74	0.52	1.25	0.74-2.11	0.41
Lymph node size (> 10 mm)	1.01	0.98-1.04	0.49	1.01	0.98-1.04	0.37
Needle gauge (21G v 22G)	1.52	0.66-3.50	0.32	1.83	0.72-4.62	0.21
Thoracic surgeon v pulmonologist	1.28	0.64-2.54	0.48	1.26	0.59-2.66	0.55
Specimen processing method 1) v 2) v 3) v 4) v 5)	0.62	0.44-0.87	**0.01**	0.54	0.37-0.78	**<0.01**
Disease (malignant v benign)	1.29	0.64-2.61	0.47	1.26	0.74-2.11	0.59

id 423

An unusual case of hemoptysis: echinococcal cysts in lungs and thoracic vertebrae

Katja Adami?, Aleš Rozman, Mateja Marc Malovrh

Interventional pulmonology, University Clinic of Pulmonary and Allergic Diseases Golnik - Slovenia

Introduction

Hydatid disease (HD) is a worldwide parasitic disease. Echinococcosis may involve many organs but affect most commonly liver and lungs. HD of the bone occurs in 0.5-3% of all the cases, the vertebral column is involved in 50% of these. Involvement of the lungs produces chronic cough, dyspnoea, pleuritic chest pain and haemoptysis. Expectoration of cyst membranes and fluid is observed with intrabronchial rupture.

Methods

A 76-year-old man, after more surgical treatments of echinococcus cysts in lungs and columnae vertebrae in the history, presented with haemoptysis in the last six months. In the sputum were histologically confirmed hyaline membranes of the echinococcus cysts. Computed tomography and magnetic resonance imaging showed large area of inflammation with destruction of thoracic vertebrae (spondylodiscitis) and the communication with right lower lobe (RLL). In the laboratory results the C-reactive protein was 30mg/l. The bronchoscopy confirmed acute bronchitis with pus secretion and parts of echinoccus hyaline membranes in RLL. The Staphylococcus aureus and Haemophylus parainfluenzae were cultured from the lavage. The multidisciplinary team with thoracic surgeon, orthopaedic surgeon, pneumologist and infectious disease specialist decided to treat the patient conservatively with antibiotics without surgical procedures.

Conclusions

Although it is one of the less common causes of haemoptysis, HD of the lung requires attention also in countries, in which hydatid cyst disease is rare.

id 424

19th WCBIP / WCBE World Congress
JOINT MEETING OF THE WORLD ASSOCIATION FOR BRONCHOLOGY AND INTERVENTIONAL PULMONOLOGY & THE INTERNATIONAL BRONCHOESOPHAGOLOGICAL SOCIETY
www.wcbipwcbe2016.org
Fortezza da Basso
May 8-11, 2016
Florence (Italy)

Endobronchial ultrasound-guided transbronchial needle aspiration for the diagnosis of lymphoma

Takafumi Umetsu[1], Akihiro Takemasa[1], Rinna Tei[2], Yoshitomo Kushima[1], Naoya Ikeda[1], Ryou Arai[1], Hidenori Takizawa[1], Kazuyuki Chibana[1], Masaaki Miyoshi[1], Yasuo Shimizu[1], Yoshimasa Nakazato[3], Yoshiki Ishii[1]

[1]Pulmonary Medicine and Clinical Immunology, Dokkyo Medical University School of Medicine - Japan
[2]dokkyomedical center, Pulmonary Medicine and Clinical Immunology - Japan
[3]Pathology, Dokkyo Medical University School of Medicine - Japan

Introduction
It has not yet been fully defined whether endobronchial ultrasound-guided transbronchial needle aspiration (EBUS-TBNA) could accurately diagnose malignant lymphoma in patients with mediastinal lymphadenopathy.

Objective
We reviewed our clinical data and pathological findings on EBUS-TBNA in patients with mediastinal lymphadenopathy diagnosed as malignant lymphoma ultimately.

Methods
The patients who underwent EBUS-TBNA, whose final diagnoses were malignant lymphoma, were retrospectively reviewed between April 2006 and November 2015. Mediastinal biopsy specimens were taken by the ultrasonic bronchoscope (Olympus BF-UC 260F) and 21/22-gauge cytology needles (NA-201 SX-4021/SX-4022 Olympus) with on-site cytopathological support. We examined clinical data, pathological findings and diagnostic accuracy by EBUS-TBNA.

Results
We reviewed 26 cases of malignant lymphoma. In 20 of 26 patients (76.9%), atypical cells were found in EBUS-TBNA specimens with hematoxylin and eosin staining. Thirteen cases (50%) were ultimately diagnosed as malignant lymphoma by EBUS-TBNA, with the combination of immunohistochemistry. The main causes for false negative diagnoses in 7 cases were due to inadequate amount of samples and/or poor conditions of specimens. Additional biopsies, from other sites were required in 4 cases of superficial lymph node biopsy, one of open lung biopsy, one of pleural biopsy and one of bone marrow biopsy.?The mean sizes were 20.1mm in atypical cell positive lymph nodes and 15.9mm in negative lymph nodes, respectively.

Conclusions
EBUS-TBNA is a safe and useful diagnostic tool in the case that malignant lymphoma is suspected, if adequate amount samples are taken and ancillary studies like immunocytochemistry could be applied. In those cases, it may diminish the need for more invasive procedures such as lymph node resections. It is suggested that it is important to get adequate amount samples by multiple needle aspirations for the better diagnostic accuracy.

id 425

19th WCBIP / WCBE World Congress
JOINT MEETING OF THE WORLD ASSOCIATION FOR BRONCHOLOGY AND INTERVENTIONAL PULMONOLOGY & THE INTERNATIONAL BRONCHOESOPHAGOLOGICAL SOCIETY
www.wcbipwcbe2016.org
Fortezza da Basso
May 8-11, 2016
Florence (Italy)

Pleurodesis rates for indwelling tunneled pleural catheters in heart failure effusions

Isaac C. Meier[1], Joseph H. Skalski[2], John J. Mullon[2], Francis C. Nichols, Iii[3], Ryan M. Kern[2]

[1]Internal Medicine, Mayo Clinic - Usa
[2]Pulmonary and Critical Care Medicine, Mayo Clinic - Usa
[3]Thoracic Surgery, Mayo Clinic - Usa

Introduction

Management of non-malignant pleural effusions (NMPE) focuses on treatment of the underlying cause. NMPEs secondary to heart failure are usually amenable to medical therapy. However, there are instances of refractory cardiogenic effusions and treatment options for these are limited. Talc pleurodesis for NMPEs may produce pleurodesis rates around 77% (1). Studies are limited, but the success of pleurodesis with indwelling tunneled pleural catheters (IPC) for cardiogenic effusions is underwhelming with reported rates around 30% (2). We present the pleurodesis rates for the largest retrospective cohort of patients with IPCs placed for pleural effusions secondary to heart failure.

Objective

Our goal is to evaluate the efficacy of IPCs in achieving pleurodesis for patients with medically refractory heart failure effusions.

Methods

We performed a retrospective cohort analysis. A database of all Mayo Clinic patients was searched for the IPC procedure code yielding 1142 patients. This list was then filtered for patients with a diagnosis code for heart failure yielding 316 patients. Patients with a diagnosis code for lung malignancy were excluded, leaving 225 patients whose charts were individually reviewed. 145 patients were subsequently excluded for IPC placement with an indication other than primary heart failure. The remaining 80 patients' charts were reviewed for rate of pleurodesis, number of hospitalizations, adverse events, and death. Pleurodesis was defined as decreased output not attributable to catheter occlusion with subsequent removal of IPC.

Results

Initial analysis revealed 40 of 80 patients achieved pleurodesis (50%). The average time to catheter removal was 127 days (median 85.5 days). We also looked at pleurodesis rates excluding patients that died within 120 days of IPC placement because they may not have had enough time to achieve pleurodesis. This resulted in exclusion of 27 patients. Of patients who survived 120 days, 38 of the 53 patients (71.7%) achieved pleurodesis with a median time to pleurodesis also at 85.5 days. A total of 5 complications were found in 5 patients including: 3 infections (1 empyema); 1 hemothorax, and 1 tube occlusion requiring lytics.

Conclusions

Indwelling tunneled pleural catheter placement may be an effective means to achieve pleurodesis in the setting of pleural effusions secondary to heart failure.

Bibliography

1. Steger, Annals of Thoracic Surgery. 2007 June;83(6):1940-5 2. Srour N, et al. Chest. 2013 Nov;144(5):1603-8

Figure 1.

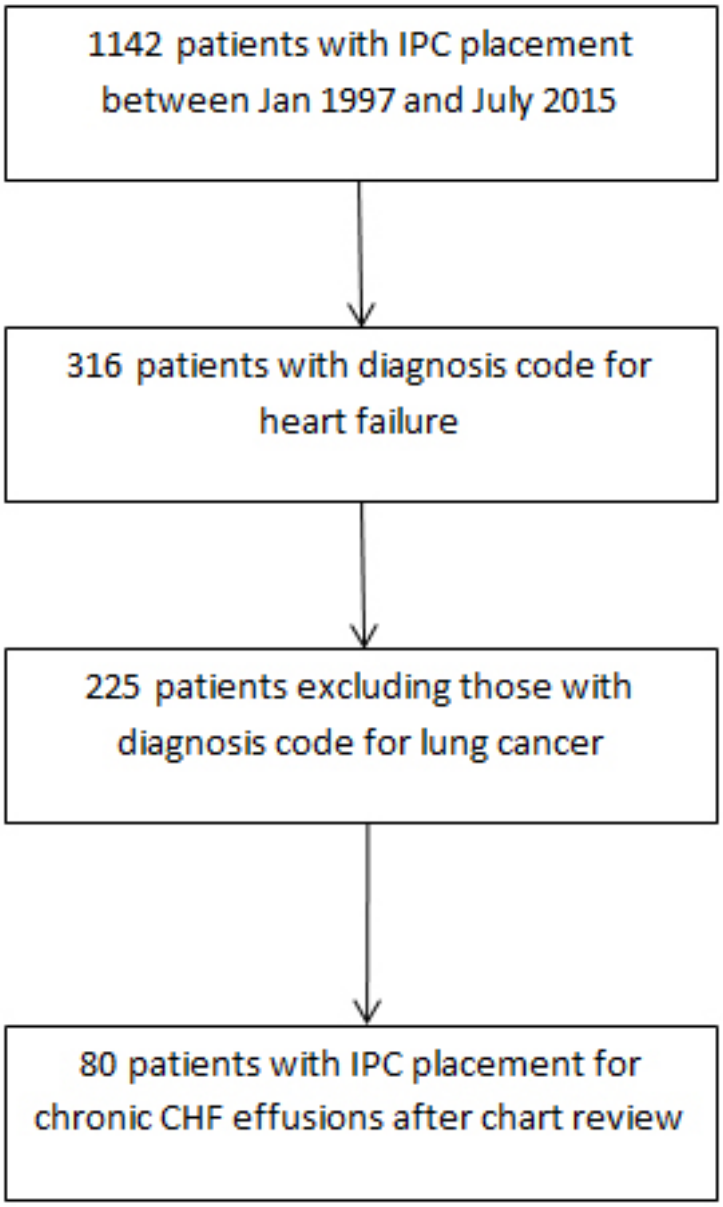

id 426

19th WCBIP / WCBE World Congress
JOINT MEETING OF THE WORLD ASSOCIATION FOR BRONCHOLOGY AND INTERVENTIONAL PULMONOLOGY & THE INTERNATIONAL BRONCHOESOPHAGOLOGICAL SOCIETY
www.wcbipwcbe2016.org
Fortezza da Basso
May 8-11, 2016
Florence (Italy)

Ectomesenchymal Chondromyxoid Tumor of the Trachea, a case report of an unique tumor

Margarida Aguiar[1], António Bugalho[2], Susana Clemente[1], Helena Oliveira[3], Sofia Tello Furtado[1]

[1]Pulmonology Department, Hospital Beatriz Angelo - Portugal
[2]Pulmonology Department, CUF - Portugal
[3]Pathology Department, Hospital Beatriz Angelo - Portugal

Introduction

Ectomesenchymal chondromyxoid tumour (ECT) is a rare, benign neoplasm of uncertain histogenesis. To our knowledge there are only 45 cases reported in the English literature.

Objective

We present a case of a patient with an ECT in the trachea. We found no description of this type of tumour outside of the oral cavity.

Methods

A 37 year old female patient was referred to the outpatient clinic due to a history of breathlessness and worsening dyspnoea on exertion. Her complaints were going on for three years and were getting progressively worse. She had a 7 pack-year smoking history until the age of 30 years. On examination the patient had a low BMI, a slight stridor and an expiratory whistle. Pulmonary sounds were very light. Lung function tests revealed very severe bronchial obstruction with hyperinsuflation (FVC-3,48ml, FEV1-0,71ml, FEV/FVC-20.4%, FEF25/75-0,31L/seg, FEF 50-0,37L/seg). The patient underwent a computed tomography scan of the neck and chest that showed an endotracheal nodular polylobuled image, just above the carina, causing obstruction of about 80-90% of the trachea. The patient was submitted to a rigid bronchoscopy with total excision of the mass. The histological study showed a multilobuled mesenchymal lesion, localized in fragments of respiratory submucosa, occasionally entrapping acins and ducts of the respiratory glands. It was composed of fusiform cells with uniform small nuclei with no atypic cells. Imunohistochemistry was positive for CD 34 and protein S-100. The morphological characteristics associated with the imunohistochemistry profile were consistent with ECT.

Results

After excision of the mass the patient was free from any respiratory symptoms, she gained weight and there has been no recurrence after 12 months' follow-up bronchoscopy.

Conclusions

ECT is a rare benign neoplasm arising in the oral cavity, most frequently in the tongue. At the microscopic level, it is recognizable as a well- circumscribed unencapsulated proliferation of uniform round to fusiform cells embedded in a chondromyxoid matrix. Lastly, the immunohistochemistry profile is characterised by positivity for glial fibrillary acidic protein and frequent positivity for S-100 and cytokeratins. To our knowledge this is the first case of this type of tumour in the trachea.

id 427

EBUS-TBNA diagnostic value of patients with PET-positive lymph nodes. Single-center experience

Giorgio Crosta[1], Nicola Rotolo[2], Elisa Nardecchia[2], Silvia Casali[2], Sabrina Casagrande[3], Ilaria Schiorlin[3], Cecilia Sampietro[2], Lorenzo Dominioni[2], Andrea Imperatori[2]

[1]Department of Specialistic Medicine, Unit of Pneumology-Hospital of Varese - Italy
[2]Department of surgical and morphological sciences, Center for thoracic surgery- University of Insubria - Italy
[3]Department of Nuclear Medicine, University hospital-ospedale di Circolo - Italy

Introduction

Evaluation of intrathoracic lymph nodes in patients with known/suspect malignancy or undetermined lymphadenopathy is currently advocated with 18Fluorodeoxyglucose-positron emission tomography (18FDG-PET). However the value of this method for diagnosing malignancy is sub-optimal, especially because of high false-positive rate. Endobronchial ultrasound transbronchial needle aspiration biopsy (EBUS-TBNA) may be used to clarify the diagnosis of PET- positive mediastinal lymph nodes.

Objective

To assess the value of EBUS-TBNA in diagnosing malignancy of 18FDG-PET avid mediastinal lymph-nodes in patients with (suspect) malignancy or undetermined lymphadenopathy.

Methods

In 2014-2015, we prospectively evaluated 44 patients (82% male; mean age 67±16 SD years) who underwent 18FDG-PET for the evaluation of mediastinal/hilar nodes (known/suspect lung cancer, n=30; other malignancy, n=6; undetermined lymphadenopathy, n=8) and showed abnormal 18FDG-uptake [maximum standardized uptake value (SUVmax) >2.5]. Their lymph node mean SUVmax was 8.87±5.81SD. All patients subsequently underwent EBUS-TBNA (21/22G needle core biopsy) for assessment of 18FDG-avid lymph nodes' malignant involvement. We evaluated the sensitivity, accuracy and negative predictive value of EBUS-TBNA, considering as diagnostic gold-standard respectively the surgical N status in operated patients, or 1-year follow up.

Results

Mediastinal nodes (station 2, 4 or 7) were sampled in 28 patients; hilar nodes (station 10 or 11) in 10 patients; both hilar/mediastinal nodes in 4 patients. Mean size of all lymph nodes was 1.9 mm(range 0.8-5). The mean number of needle passes/lymph node was 2.4(range 2-5). EBUS-TBNA confirmed lymph node malignancy in 20 patients (PET true-positive cases), while it did not shown malignancy in 22 patients (50%); 2 patients were lost to follow-up. Among the 22 patients with non malignant biopsy at EBUS-TBNA, 7 cases (16% of the 44 PET-avid cases) had lung cancer and were operated showing negative N status (PET false-positive). Of the 15 patients who were not operated because primary tumor was not demonstrated, 2 cases are PET true-positive because they subsequently developed lung cancer metastases; 13 cases are currently in follow-up without evidence of malignancy.

Conclusions

Based on our experience, in 48% of patients the EBUS-TBNA demonstrated that 18FDG-PET was true-positive. In 16% of cases, 18FDG-PET was false-positive, as shown by EBUS-TBNA and confirmed by surgical N status. In 36% of cases the diagnostic value of EBUS-TBNA remains to be determined by extended follow-up.

id 428

19th WCBIP / WCBE World Congress
JOINT MEETING OF THE WORLD ASSOCIATION FOR BRONCHOLOGY AND INTERVENTIONAL PULMONOLOGY & THE INTERNATIONAL BRONCHOESOPHAGOLOGICAL SOCIETY
www.wcbipwcbe2016.org
Fortezza da Basso
May 8-11, 2016
Florence (Italy)

French survey on bleeding during flexible bronchoscopy

Febvre Michel

Service de pneumologie, Hopital Tenon - France

Introduction

Bleeding during flexible bronchoscopy (FB) can ben threatening. Also in the vast majority of the cases its only red on the screen, but sometimes it can be difficult to face it.

Objective

answers of experts position facing bleeding during FB

Methods

through September 2015 a questionnaire with 29 items (with Survey Monkey) was sent to the mailing list of the GELF (french speaking group of endoscopy) witch contains 300 mail addresses of MDs interested on bronchoscopy. Three rounds were sent.

Results

110 respondents (36.6%) ; 74.5% were men ; median age 41-50 ; median number of FB / year 201-400 have you personally had serious bleeding experience ? yes for 54.6 % ; if yes how many ? median 3 (1-10) ; do you personally practice interventional bronchoscopy ? yes for 63.5 % ; is the bleeding risk during FB somewhat bothering in your daily practice ? not at all 14.4%, a little 60.6%, a lot 25% ; what volume ? half an aspiration vial 13.4 %, one vial (30 ml) 47.1%, two vials 27.9%, more 9.6% ; other situation : persistence of bleeding 86.4%, desaturation 83.5%. Which type of endobronchial lesion is of concern ? recent exophytic mass 23.3%, suspicion of carcinoid tumor 69%, suspicion of vascular lesion 89.3% ; which type of sampling ? endobronchial biopsies 56.3%, transbronchial lung biopsies 77.7%, endobronchial brushing 16.5%, TBNA 19.4%. In case of a bleeding which treatment (drugs) do you use ? Rate them from 1 to n…. : waiting and surveying clot formation rated 1st for 55.1%, 2nd for 9.2%, 3d for 6.1% ; diluted epinephrine (1/10,000) rated 1st for 15.3%, 2nd for 21.4%, 3d for 23.5% ; cold saline rated 1st for 15.3%, 2nd for 37.8%, 3d for 17.3% ; lidocaine combined with epinephrine rated 1st for 7.1%, 2nd for 17.3%, 3d for 13.3% ; local terlipressin rated 1st for 0%, 2nd for 6.1%, 3d for 18.4%

Conclusions

bleeding during flexible bronchoscopy is a concern for the majority of respondent. But few severe bleeding events are reported through a lifetime of bronchoscopist. Whether or not biopsy at once an suspicion for endobronchial carcinoid tumor is still of debate. As treatments of bleeding the waiting attitude is proeminant, iced water and dituted epinephrine are commonly used, terlipressin is not used as a first line drug.

id 429

Assessing adequacy of EBUS-TBNA samples sent for Next Generation Sequencing in lung adenocarcinoma

Joseph Cicenia[1], Jordan Reynolds[2]

[1]Respiratory Institute, Cleveland Clinic - Usa
[2]Pathology & Laboratory Medicine Institute, Cleveland Clinic - Usa

Introduction

Next-generation sequencing (NGS) is a technology that allows for the evaluation of multiple molecular alterations in the same sample using a small amount of tissue. Traditional single-gene sequencing by a first-generation techniques (Sanger sequencing) has been replaced by NGS since it allows massive parallel sequencing with lower cost and higher throughput. NGS detects not only multiple mutations in different genes, but also amplifications and fusion genes. The use of NGS is expected to increase and gain importance in clinical and experimental approaches, since it can be used as a diagnostic tool for both clinically actionable genetic alterations and for future discoveries.

Objective

To determine if EBUS-TBNA samples of lung adenocarcinoma provide adequate material to routinely perform molecular testing using NGS. Secondary analyses were performed in cases of uninformative NGS to determine if extracted DNA amount was causal, and if there was adequate reserve tissue to perform traditional Sanger sequencing to determine EGFR status.

Methods

One year of pathologic findings at the time of EBUS were collected. During the procedure, additional EBUS-TBNA passes are submitted directly into Cytolyt preservative. After the final diagnosis of adenocarcinoma is rendered, the remaining fluid is prepared for DNA extraction and sequencing is performed using the Ion AmpliSeq Cancer Hotspot panel v2(CHPv2). The mutation hotspots of BRAF, EGFR, ERBB2, FGFR1, KRAS, MET and PIK3CA were analyzed using NextGENe and Torrent suite bioinformatics tools. In cases with insufficient DNA (typically <10ng/uL) for NGS testing, DNA libraries were analyzed using the EGFR allele-specific PCR kit (Qiagen).

Results

One year of case data was collected from 1/1/2015-12/31/2015. 1105 EBUS cases with adequacy were performed, of which 320 had diagnosis of non-small cell lung carcinoma. 75 cases were for non-thoracic adenocarcinomas, leaving 245 cases of primary lung adenocarcinomas diagnosed by EBUS. 29 cases were unable to be analyzed by NGS with an average DNA concentration by Qubit fluorometry of 4.27 ng/ul (range < 0.05 – 23.7 ng/ul). 9/29 (31%) cases remained uninformative after analysis with allele specific PCR. 88.1% (216/245) of cytologically obtained samples resulted an NGS result from the same procedure, while 96.3% (236/245) of cytologically obtained samples resulted at least an EGFR result.

Conclusions

In cases of lung adenocarcinoma EBUS sampling provided informative NGS results in almost 90% of cases when extra passes are provided. Having a robust backup method to detect clinically actionable mutations (ie EGFR) helps increase the yield of molecular testing from our cytologic samples.

id 430

19th WCBIP / WCBE World Congress
JOINT MEETING OF THE WORLD ASSOCIATION FOR BRONCHOLOGY AND INTERVENTIONAL PULMONOLOGY & THE INTERNATIONAL BRONCHOESOPHAGOLOGICAL SOCIETY
www.wcbipwcbe2016.org
Fortezza da Basso
May 8-11, 2016
Florence (Italy)

Quantitative assessment of airway remodeling in allergic asthma and healthy controls in vivo

Melissa J Suter, David C Adams, Lida P Hariri, Alyssa J Miller, Jasmin A Holz, Margit V Szabari, R. Scott Harris, Josalyn L Cho, Jason W Griffith, Daniel L Hamilos, Andrew D Luster, Benjamin D Medoff

Harvard Medical School and, Massachusetts General Hospital - Usa

Introduction

It has long been recognized that asthma is not a single disease, but rather a heterogeneous group of disorders that exhibit the clinical symptoms of reversible airway obstruction and hyperresponsiveness. Accurately phenotyping/subphenotyping asthmatic patients will likely become increasingly important as advances in novel targeted therapies and pharmaceuticals occur. Unfortunately, it is currently not possible to accurately and volumetrically assess early airway remodeling changes in vivo. We have developed a high-resolution optical catheter-based polarization sensitive optical coherence tomography (PS-OCT) imaging system that enables us to accurately assess airway wall microstructures, including airway smooth muscle (ASM) mass and 3D distribution, in vivo for the first time.

Objective

The goal of this study was to determine the ability of PS-OCT to assess early airway remodeling changes in allergic asthmatic (AA) and non-asthmatic (NA) study subjects in vivo.

Methods

We conducted endobronchial PS-OCT in n>50 mild AA and NA study subjects. A narrow diameter PS-OCT catheter was advanced through the access channel of a standard bronchoscope and volumetric imaging of airway segments 3cm in length was conduced in 30 seconds. Remodeling metrics were calculated from the PS-OCT images offline. Metrics included epithelial thickness, mucosal thickness, airway folding, mucus volume, mucus thickness, airway smooth muscle (ASM) volume, ASM thickness, and ASM band width.

Results

Mean ASM band thickness in the AA (70.3?m +/- 14.7?m) was significantly greater than in the NA subjects (31.8?m +/- 2.29?m). Similarly, the mean ASM band width was significantly greater in the AA (380.3?m +/- 8.145?m) compared to the NA subjects (316.3?m +/- 0.577?m), $p<0.05$ (figure 1). Statistically significant increases in the epithelial and mucosal thicknesses, mucosal folding, and mucus volume were additionally observed in the AA subjects when compared to the NA subjects.

Conclusions

These results demonstrate that we can safely perform PS-OCT imaging in AA and NA volunteers to quantitatively assess structural alterations to the airway wall including the assessment of epithelial and mucosal thickness, mucosal folding, mucus volume and thickness, and ASM fiber band thickness and width. Assessment of this collection of biomarkers is currently not evaluable with existing technologies. We believe that the ability to accurately assess airway remodeling in vivo may lead to improved patient phenotyping. If we are able to accurately phenotype/subphenotype asthma, we may be able to better match individuals to appropriate therapeutics, such as bronchial thermoplasty, and therefore reduce the high morbidity associated with this disease.



Figure 1: Assessment of ASM in AA and NA using PS-OCT. **(a)** Volume rendering of PS-OCT images obtained from an NA subject, and **(b)** and AA study subject. ASM thickness is encoded in color from black to yellow (0 - 120 µm). **(c)** and **(d)** show the isolated ASM layer from (a) and (b) unwrapped to highlight the banding structure of the ASM in the NA and AA subjects respectively.

The presenting author has the following conflicts of interest that relate to this abstract: *I am an inventor on Massachusetts General Hospital owned patents licensed to NinePoint Medical. I am a consultant for NinePoint Medical I receive sponsored research from Boston Scientific. I receive sponsored research from Biogen Idec.*

id 431

19th WCBIP / WCBE World Congress
JOINT MEETING OF THE WORLD ASSOCIATION FOR BRONCHOLOGY AND INTERVENTIONAL PULMONOLOGY & THE INTERNATIONAL BRONCHOESOPHAGOLOGICAL SOCIETY
www.wcbipwcbe2016.org
Fortezza da Basso
May 8-11, 2016
Florence (Italy)

Medical Thoracoscopy in the treatment of Pleural infection

Andreas Koulelidis, Stavros Anevlavis, Kostas Archontogeorgis, Kostas Kltsas, George Kouliatsis, Panos Boglou, Marios Froudarakis

Department of Respiratory Medicine, Medical School, Democritus University of Thrace - Greece

Introduction

The role of rigid thoracoscopy under local anesthesia in pleural infection is unknown as few studies reported results, none of them prospective and randomized.

Objective

The aim of our study was to evaluate the efficacy of medical thoracoscopy in comparison to the treatment with pleural drainage in pleural infection.

Methods

Between 01/2008 and 08/2013, 63 patients (median age 54, 52 males) with primary non-tuberculous pleural infection were treated in our department. We compared characteristics and outcome of patients with pleural infection, who underwent rigid thoracoscopy under local anesthesia only, versus classic chest tube drainage.

Results

All 63 patients initially received antibiotic treatment for their infection. 21 patients (18 early and 3 late) underwent thoracoscopy under local anesthesia and 42 chest tube drainage for the treatment of their pleural infection. No significant difference was observed in age, gender, presence of comorbidities, pleural pH, LDH, proteins, serum CRP, or amount of drained fluid between the two groups. Significant difference in favor of thoracoscopy was observed in total days of hospitalization (p=0.01), days of pleural drainage (p=0.02), referral to surgery (p=0.02). A trend towards a worst outcome of patients referred from another hospital was noted overall (p=0.09), but especially in relation to the classic treatment (p=0.06).

Conclusions

In this retrospective cohort study medical thoracoscopy provides better results than chest tube drainage in an experienced center of the management of patients with pleural infections. These results should be further confirmed by a prospective randomized study.

id 432

19th WCBIP / WCBE World Congress
JOINT MEETING OF THE WORLD ASSOCIATION FOR BRONCHOLOGY AND INTERVENTIONAL PULMONOLOGY & THE INTERNATIONAL BRONCHOESOPHAGOLOGICAL SOCIETY
www.wcbipwcbe2016.org
Fortezza da Basso
May 8-11, 2016
Florence (Italy)

PFT's and BALF changes of CD4+, CD8+ cells in lung cancer patients with different platinum associations

Vasilis Mihailidis, Georgia Karpathiou, Stavros Anevlavis, George Kouliatsis, Athanasia Pataka, Argyris Tzouvelekis, Paschalis Steiropoulos, Marios E. Froudarakis

Department of Respiratory Medicine, Medical School, Democritus University of Thrace - Greece

Introduction
Reports point out acute lung toxicity of chemotherapeutic agents in cancer patients.

Objective
The aim of our study was to assess BALF and lung function findings of the 3 most applied platinum-based regimens for the treatment of metastatic lung cancer.

Methods
Within one year period 20 patients (ECOG 0 , 1) agreed to participate the study, but 15 were evaluable (5 patients died from disease progression, before reassessment). Patients underwent lung function tests and BAL, of the opposite to the tumor lung, during diagnostic bronchoscopy before and after 6 chemotherapy courses. Platinum-based regimens were combination of vinolerbine (VN) 6 patients, gemcitabine (GEM) 4 patients and etoposide (EP) 5 patients.

Results
All patients, but one were males and smokers (93%). Median patients' age was 56 years (42-75) and median pack-years 80 (40-120). No significant difference was noted in the patients' age between the 3-treated groups. No significant changes in CD4+ and CD8+ cells were noted between the 3 groups of treatment. However, changes were noted within each group only for CD4+ cells: VN before vs after p= 0.05; GEM before vs after p=0.03; EP before vs after p=0.3. For CD8+ no significant changes were noted. Also no changes were noted in lung function tests (FEV1, FVC) between or within the groups.

Conclusions
Although our number of patients is small due to recruitment difficulties in such patient population, changes were noted in BALF CD4+ cells for the 3 most applied regimens.

id 433

Fluorescein-aided probe-based confocal laser endomicroscopy (pCLE) for detection of lung cancer

Kiyoshi Shibuya, Nao Okada, Jouji Horio, Hidehisa Hoshino, Naomichi Iwai, Hidemitsu Funabashi, Masahiro Noro, Bunshiro Akikusa, Ichiro Yoshino

Department of Chest Surgery, Respirology and Pathology, Matsudo City Hospital, Lung Cancer Treatment Center of Chiba University Hospital in JRC Narita Hospital - Japan

Introduction

We investigated the capabilities of a probe-based confocal laser endomicroscopy (pCLE) that enables microscopic imaging of the tracheobronchial tree including peripheral lung tumor during bronchoscopy after administration of 10% fluorescein.

Methods

Twenty-one patients with suspected lung cancer were underwent bronchoscopy with pCLE using fluorescein. CLE probes were selected both Alveoflex probe 1.4mm in diameter for the peripheral lung tumor and Gastroflex probe 2.5mm in diameter for the central airways tumor. Following localization of peripheral lung tumor with endobronchial ultrasonography-guided sheath (EBUS-GS) and of central airways tumor with white light, narrow band imaging (NBI) and autofluorescence imaging (AFI) bronchoscopy, pCLE was performed followed by bronchoscopic tumor biopsy. Histological examinations using haematoxylin and eosin staining were made of biopsied specimens. Analyzed pCLE images were compared with the corresponding histological examinations.

Results

Of the 21 patients, 16 lung cancers and 2 inflammatory tumors were identified pathologically. In adenocarcinoma, confocal images demonstrated large, irregular, dark or black tumor cells were visible and some of abnormal structures were also similar to acinar differentiated types. In squamous cell carcinoma, large, dark or black, polymorphic tumor cells showed increased cellular densities with irregular stratified patterns and capillary blood vessels, tumor vessels with flow of red blood cells also visible. Of 16 pathological diagnosed lung cancers, large, dark or black, tumor cells were visible in 13 lesions.

Conclusions

pCLE was useful for the detection malignant tumor cells during bronchoscopy in real time. This novel technology has an excellent potential to provide in vivo diagnosis during bronchoscopic examinations.

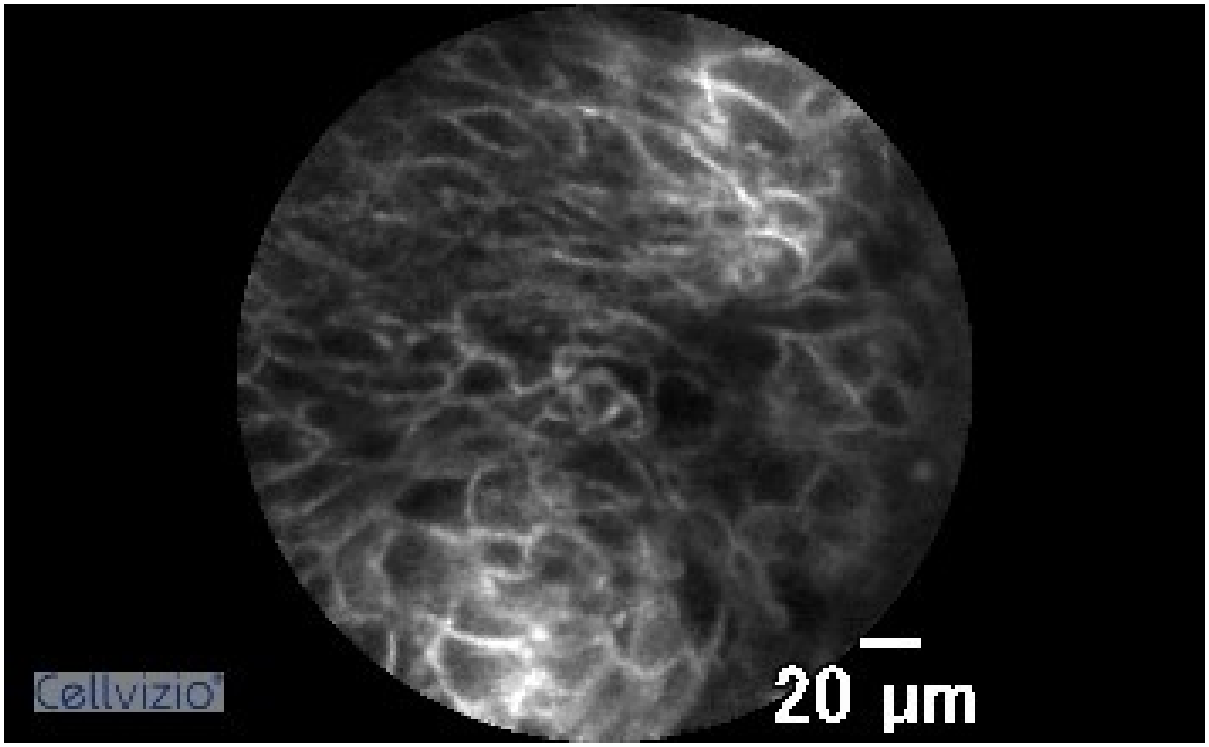

id 434

Photodynamic therapy (PDT) for lung cancers at peripheral parenchyma of the lung

Jitsuo Usuda, Tatsuya Inoue

Department of Thoracic Surgery, Nippon Medical School - Japan

Introduction

Ground-glass opacity (GGO) nodules at peripheral parenchyma of the lung noted at thin - section computed tomography (CT) scan have shown to have a histopathologic relationship with atypical adenomatous hyperplasia (AAH) and adenocarcinoma (AIS). These preinvasive lesions, which corresponds to type A or B adenocarcinoma according to Noguchi classification, are favorable prognosis. We hypothesize that those early lung cancers in peripheral parenchyma such as AIS, do not need surgical resection may be cured by interventional approach such as Photodynamic therapy (PDT). For peripheral type early lung cancer, it is unable to observe using bronchoscopy nor to treat by PDT. Therefore, we have developed a new minimally invasive laser device using a 1.0 mm in diameter composite-type optical fiberscope (COF), which could transmit laser energy and images for observation in parallel, consisting a laser Doppler blood-flow meter. The use of COF technology waspreviously used in the field of atomic energy. It enables the acquisition of an image while simultaneously performing laser treatment such as PDT, measuring the blood-flow, estimating the irradiational distance.

Objective

In this study, we aimed to develop a new endoscopical treatment for peripheral parenchymal cancer by NPe6-PDT and a COF.

Methods

We administered NPe6, 10mg/kg to pigs and we observed the peripheral parenchyma through the bronchus using COF. One h after the administration of NPe6, we irradiated 664 nm-laser (120 mW, 100J) for normal lesion of the peripheral lung using COF. Seven days after PDT, we extracted lungs and examined pathologically.

Results

We were able to introduce the 1.0 mm COF into pig peripheral parenchyma of the lungs and observed feasibly and clearly, and then we performed NPe6-PDT safely. We measured the blood-flow at the irradiated area by COF during PDT, and we observed gradually disappearance of the blood-flow. The mean diameter of necrosis in normal peripheral lung caused by NPe6-PDT was 16 mm.

Conclusions

The 1.0 mm COF was a very useful device of NPe6-PDT for peripheral parenchyma of the lung. In the future, for non-invasive adenocarcinoma such as AIS, NPe6-PDT using COF will become one option of standard treatment and play a important role for the treatment of synchonous or metachronous multiple primary lung cancer lesions.

id 435

19th WCBIP / WCBE World Congress
JOINT MEETING OF THE WORLD ASSOCIATION FOR BRONCHOLOGY AND INTERVENTIONAL PULMONOLOGY & THE INTERNATIONAL BRONCHOESOPHAGOLOGICAL SOCIETY
www.wcbipwcbe2016.org
Fortezza da Basso
May 8-11, 2016
Florence (Italy)

A new strategy for preoperative management of lung cancer patients with COPD

Tatsuya Inoue, Jitsuo Usuda

Department of Thoracic Surgery, Nippon Medical School - Japan

Introduction

Recently, it has been reported that the prognosis for patients with lung cancer with Chronic obstructive lung disease (COPD) was worse than that of patients with lung cancer without COPD. For lung cancer patients with COPD, the frequency of the postoperative complications should be reduced.

Objective

In lung cancer patients with COPD, it was examined whether it is possible to reduce the frequency of post-operative complications after surgical resection of the lungs by smoking cessation not only the introduction of inhaled long-acting anticholinergic (LAMA) or long-acting ?2-agonists (LABA)

Methods

Among 260 patients who underwent surgical resection for lung cancer from January 2013 to February 2015 in our hospital, COPD patients 77, non-COPD 183. We analyzed retrospectively the relationship between the introduction of inhaled LABA or LAMA and the frequency of the postoperative complications in lung cancer patients with COPD.

Results

In COPD patients 77 cases, male 62 cases, female 15 cases, age 60-85 years old (mean: 74). Current smokers were 39 cases, and former-smokers were 38 cases. Lung resection, partial resection 11 cases, segmental resection 1 case, lobectomy 64 cases, pneumonectomy 1 case. There were 17 postoperative complications in COPD (22.1%), prolonged air leak (more than 7 days) 9 cases, pneumonia 3 cases, arrhythmia 2 cases, chylothorax 2 cases, wound infection 1 case. The frequency of postoperative pulmonary complications such as prolonged air leakage and pneumonia, showed a significant high in COPD (12 cases, 15.6%) compared with non COPD (9 cases, 4.9%). Inhaled bronchodilators such as LAMA or LABA were prescribed to 22 cases in COPD, not to 50 cases. The pulmonary complications were significant lower in LAMA or LABA users (2 cases, 9.1%) than in no users (10 cases, 18.2%). Among current smoker 38 cases, which were preoperatively treated with smoking cessation and chest physiotherapy for more than one month, the inhalants with LABA or LAMA were prescribed before pulmonary resection in 18 cases, not prescribed in 20 cases.

Conclusions

For lung cancer patients with COPD, preoperative management using the inhalants with LABA or LAMA, and smoking cessation can reduce the frequency of the postoperative pulmonary complications after surgical lung resection. The inhalants with LAMA or LABA may be adapted for the management of not only perioperative care but also long-term survival of COPD patients after surgery.

id 436

Imbalance of autonomic nerve system to induce malignant transformation in oropharyngeal leukoplakia

Tetsuya Ikeda, Hidenori Yokoi, Naoyuki Kohno, Koichiro Saito

Department of Otolaryngology-HNS and Oral Surgery, Kyorin University School of Medicine - Japan

Introduction

Leukoplakia is a well-known premalignant lesion of the oral cavity. A wide array of conditions are implicated in the definition of premalignant leukopakia, including lichen planus, dysplasia, and hyperkeratosis/hyperplasia. Despite the clinical popularity of leukoplakia as a premalignant lesion, precise mechanism of its malignant transformation is unknown. The whitish line of buccal mucosa and trace of pressure of the tongue against the teeth signs are common findings to suggest the pressure of the soft tissue against the teeth (Fig.1). This mechanical pressure is suggestive of continuous mental stress to induce the imbalance of autonomous nerve system. Furthermore, recent reports proved the role of blood neutrophil-lymphocytes ratio (NLR) as a potential biomarker of cancer prognosis.

Objective

To assess the role of imbalance in the autonomic nerve system as a trigger of malignant transformation of oropharyngeal premalignant leukoplakia.

Methods

Twenty-seven oropharyngeal leukoplakia patients with their ages ranging from 29 to 86 yo were incorporated in this study. Leukoplakia patients consisted of lichen planus (n=23), hyperkeratosis (n=2), and dysplasia (n=2). Of these, 3 patients developed squamous cell cancer during our follow up. As reported before, extrathymic T cells are controlled by sympathetic nerve system, and to measure the activity of extrathymic T cells, expression of CD3 and CD57 were assessed using immunohistochemistry. Additionally, absolute neutrophil count and absolute lymphocyte count were examined to measure NLR of the patients.

Results

Mononuclear CD3 and CD57 were expressed in most of the leukoplakias, except those who developed cancers during our observation period. Lower NLR number (<5) was associated with better prognosis, and all the patients who developed cancers counted higher NLR numbers (>5).

Conclusions

Our study supported the idea that imbalance of autonomic nerve system could be a trigger of malignant transformation in oropharyngeal premalignant leukoplakia. Furthermore, potential role of blood NLR as prognostic biomarker for leukoplakia was suggested. Further studies to comparatively assess the levels of mental stress and imbalance of autonomic nervous system are warranted.

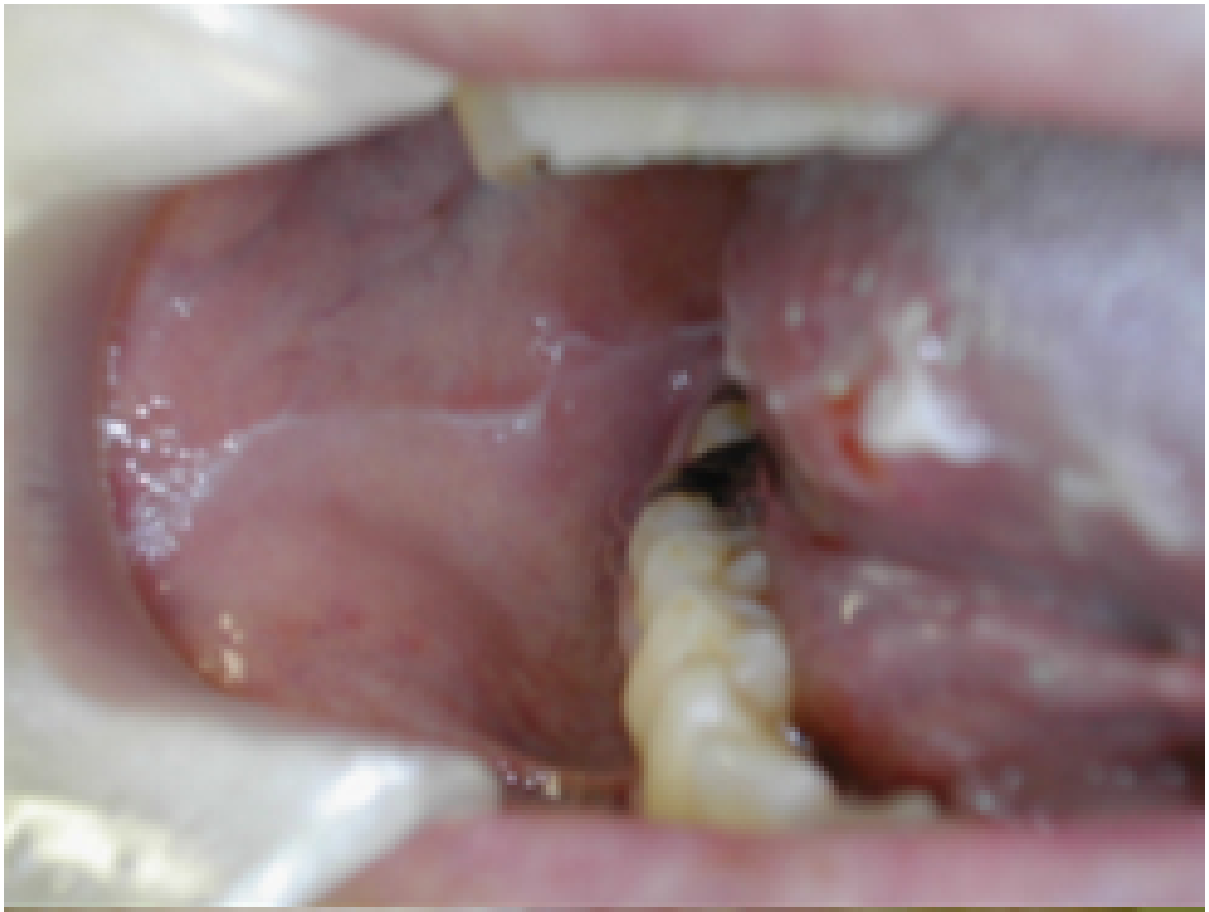

id 437

19th WCBIP / WCBE World Congress
JOINT MEETING OF THE WORLD ASSOCIATION FOR BRONCHOLOGY AND INTERVENTIONAL PULMONOLOGY & THE INTERNATIONAL BRONCHOESOPHAGOLOGICAL SOCIETY
www.wcbipwcbe2016.org
Fortezza da Basso
May 8-11, 2016
Florence (Italy)

Salvage phonosurgery after excessive injection of autologous fat into the vocal fold

Itaru Watanabe, Hideki Nakagawa, Ikuko Kubomura, Takehiro Matsuda, Naoyuki Kohno, Takeyuki Kohno, Koichiro Saito

Department of otolaryngology-HNS particular, Kyorin University School of Medicine - Japan

Introduction

Injection laryngoplasty is a widely accepted procedure for vocal fold augmentation to treat glottal insufficiency. While recent technologies have developed multiple artificial injection materials, classic autologous fat (AF) is still in use worldwide due to its biocompatible safety and proper viscoelasticity. However, AF has disadvantage in its longevity and requires intraoperative over-injection to overcome the postoperative absorption. Although barely matters, unpredictable absorption rate of AF carries the risk of over- or under-correction of the glottal insufficiency. Recently, we have encountered a patient who required salvage surgery to remove the excessively injected intracordal AF. We report this particular case to warn all phonosurgeons to consider the unpredictable variety of final glottal function after AF injection laryngoplasty.

Methods

A 50 yo male patient visited our department due to the exacerbation of his hoarseness after AF injection laryngoplasty. His AF injection had been performed with simultaneous removal of a laryngeal granuloma 5 years ago in other institution. Laryngeal stroboscopy detected the apparent swelling and loss of mucosal wave in the left vocal fold. CT imaging represented submucosal glottal lesions with fat intensity, especially in the left side. Clinical pathology of this patient was diagnosed as vocal disorder induced by excessively injected AF into left vocal fold. His voice was severely disturbed to measure the vocal quality as G3R3B1A0S1, with the values of maximum phonation time, jitter, shimmer, NHR, and VHI-10, as 11s, 5.739 %, 19.044 %, 0.415, and 19 points, respectively. Surgical removal of excessively transplanted AF was performed under the setting of microlaryngeal surgery, and incision was made on the lateral surface of left vocal fold parallel to the vibratory edge. Submucosal region was filled with fat tissue and partial removal was performed for vocal recovery. Postoperative stroboscopy presented the symmetric vibration of bilateral vocal folds. Satisfactory vocal quality was measured 3 months after surgery as G1R1B0A0S0, with the values of maximum phonation time, jitter, shimmer, NHR, and VHI-10, as 30 s, 3.546 %, 8.821 %, 0.030, and 3 points, respectively.

Conclusions

We reported a case who acquired severely impaired voice after AF injection laryngoplasty. Although successful recovery of his voice was possible after surgical removal of excessively injected AF, the patient had been enforced to use miserable voice for 5 years after AF implantation. Significant intra- and post-operative care should be taken for AF injection to consider the unpredictable AF survival.

19th WCBIP / WCBE World Congress
JOINT MEETING OF THE WORLD ASSOCIATION FOR BRONCHOLOGY AND INTERVENTIONAL PULMONOLOGY & THE INTERNATIONAL BRONCHOESOPHAGOLOGICAL SOCIETY
www.wcbipwcbe2016.org
Fortezza da Basso
May 8-11, 2016
Florence (Italy)

Bronchoscopic cryotherapy of endobronchial tuberculosis

Jianan Huang, Junhong Jiang, Jingyu Mao

Department of Respiratory Medicine, the First Affiliated Hospital of Soochow University - China

Introduction

Bronchial tuberculosis is the occurrence of tuberculosis in the airways caused symptoms and the incidence increased significantly in recent years in China. On the basis of routine anti tuberculosis therapy, a total of 29 cases on average age of 31, with granulation proliferation of bronchial tuberculosis were treated with cryotherapy from January 2012 to August 2015.

Objective

To investigate the therapeutic effectiveness of cryotherapy in treating endobronchial tuberculosis by used of bronchoscopy.

Methods

In addition to routine chemotherapy, endobronchial tuberculosis presented with proliferating type was enrolled to accept the endoscopic focal cryotherapy on 29 cases. Among them, 11 cases had balloon dilation and 15 patients injected isoniazid locally through bronchoscope by used of Wang's needle. The symptoms, endoscopic findings and CT imagine before and after treatment were evaluated.

Results

29 cases underwent cryotherapy once a week for 3.5 times on average during 1.5 months. The results showed the patients gained improvement in clinical symptoms, absorption of luminal focal lesions in bronchi and pulmonary lesions, scar stenosis but unobstructed lumen, recruitment of atelectasis; only 1 case of patient remained bronchial stenosis for his poor compliance. There were no specific adverse effects related with cryotherapy other than routine bronchoscope operation.

Conclusions

Cryotherapy combination with balloon and local injection is an effective way in treating endobronchial tuberculosis with endoscope.

id 439

19th WCBIP / WCBE World Congress
JOINT MEETING OF THE WORLD ASSOCIATION FOR BRONCHOLOGY AND INTERVENTIONAL PULMONOLOGY & THE INTERNATIONAL BRONCHOESOPHAGOLOGICAL SOCIETY
www.wcbipwcbe2016.org
Fortezza da Basso
May 8-11, 2016
Florence (Italy)

Detecting Epidermal Growth Factor Receptor Mutation in Transbronchial Needle aspiration of NSCLC

Jianan Huang, Lanlan Zhao, Yehan Zhu

Department of Respiratory Medicine, the First Affiliated Hospital of Soochow University - China

Objective
To explore the feasibility of detecting EGFR mutations in small specimens obtained by transbronchial needle aspiration (TBNA) from patients with NSCLC.

Methods
30 pathologically diagnosed NSCLC patients were enrolled From February 2013 to January 2015, whose cytological specimens and/or small tissues were gathered by either conventional transbronchial needle aspiration (C-TBNA) biopsy or EBUS-TBNA. EGFR mutations spectrums were finally detected by ARMS.

Results
EGFR mutations were detected in samples of 13 cases out of 30 patients, with a incidence of 43.3%, including 7 cases with mutations in exon 19, and 5 cases in exon 21. The other case carried double mutations of both exon 19 and 21, as show in his embedded cytological specimen, but exon 21 mutation alone as shown in small tissue sample. Five NSCLC patients with both embedded cytological specimens and small histological tissues were detected simultaneously. When compared to the result of conventional pathological examination, the concordance rate of ARMS assay in this cohort was 83.3%. EGFR mutation was detected by ARMS assay, instead of wildtype by conventional pathological examination in 1 patient.

Conclusions
Cytology specimens by TBNA could be available for EGFR muatation detecting. Feasibility of assessing the EGFR mutation status from TBNA small samples (embedded cytology specimens and small tissue specimens) of NSCLC patients was validated.

id 440

EBUS-TBNA with New Scope and New Needle

Yun Ma[1], Huizhen Yang[1], Lijun Ma[1], Ko-pen Wang[2]

[1]Respiratory and Critical Care Medicine, People's Hospital of Zhengzhou University - China
[2]Interventional Pulmonology, Johns Hopkins Hospital - Usa

Objective

TBNA has been developed more than 3 decades but underutilized. Development of EBUS-scope has revolutionized the use of TBNA due to its ability to visualize the needle position, it has made more physician able to perform TBNA with more uniform sensitivity. However conventional EBUS scope is more difficult to drive and EBUS needle is unnecessary complicated to use.

Methods

The EBUS scope is improved by reducing the visual angle by Fujifilm, made its usage similar to regular scope (Fig.1). Needle (DeTian Medical, Changzhou, China) is simplified by utilize the space between the stylete and inner tube for suction which eliminated the need to remove the wire completely in order to apply suction (Fig.2). Either original Wang needle or Olympus EBUS needle is inconvenient because the guide wire need to be completely removed for suction (Fig 3). Adjustment for outer catheter and needle length is also eliminated as it is not necessary. Scope length doesn't change and 2.0 cm length needle is more than adequate. This needle is for dual use in C-TBNA and E-TBNA, in one version the stylete is attached to the syringe, made it even more convenient to operate (Fig 4). Fujifilm EBUS scope and simplified needle were employed in a prospective analysis which was performed from 30 patients with enlarged mediastinal/hilar adenopathy referred for TBNA between July 2014 and December 2014.

Results

C-TBNA was performed in 53 LNs and 11 masses of 30 patients with enlarged mediastinal/hilar adenopathy. 22 malignancies and 8 benignancies were diagnosed through TBNA, including 20 primary lung cancers (10 adenocarcinoma, 2 squamous cell, 7 small cell, and 1 typical carcinoid), 1 primary mediastinal tumors, 1 metastatic lung cancer, 3 inflammation, 3 sarcoidosis,1 tuberculosis, and 1 mediastinal cysts.

Conclusions

It has proven to be effective and safe. Continue improvement of the scope, needle and technique is ongoing.

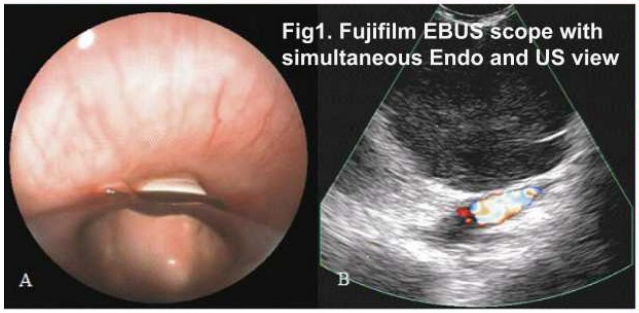

Fig1. Fujifilm EBUS scope with simultaneous Endo and US view

Fig2. Original Wang I A needle

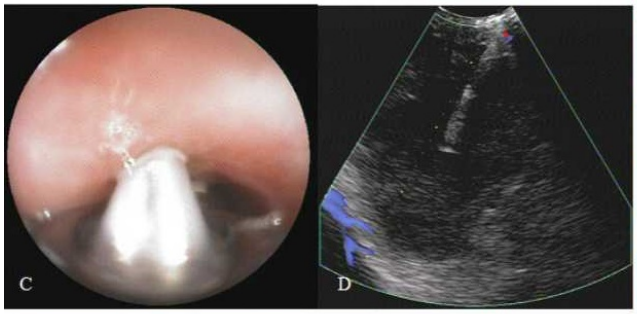

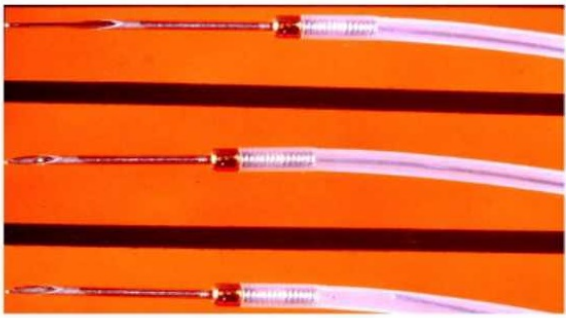

Fig3. Original Wang II A needle

Fig4. New EBUS Wang needle with and without stylet attached to syringe

id 441

www.wcbipwcbe2016.org

Venue

Fortezza da Basso
Viale Filippo Strozzi 1
Florence, Italy

Abstract Submission System
and Abstract Book design
Powered by:

sintex

SINTEX SERVIZI S.R.L.
Via Antonio da Recanate, 2
20124 Milano
Phone +39 02 66703640
www.sintexservizi.it